Journal of Gastrointestinal Surgery (2021) 25:16–27
https://doi.org/10.1007/s11605-020-04547-0

ORIGINAL ARTICLE

A Novel Valvuloplastic Esophagogastrostomy Technique for Laparoscopic Transhiatal Lower Esophagectomy and Proximal Gastrectomy for Siewert Type II Esophagogastric Junction Carcinoma—the Tri Double-Flap Hybrid Method

Takeshi Omori[1] · Kazuyoshi Yamamoto[1] · Yoshitomo Yanagimoto[1] · Naoki Shinno[1] · Keijirou Sugimura[1] · Hidenori Takahashi[1] · Masayoshi Yasui[1] · Hiroshi Wada[1] · Hiroshi Miyata[1] · Masayuki Ohue[1] · Masahiko Yano[1] · Masato Sakon[1]

Received: 12 October 2019 / Accepted: 13 February 2020 / Published online: 10 March 2020
© 2020 The Society for Surgery of the Alimentary Tract

Abstract

Mini-abstract We developed a novel technique for valvuloplastic esophagogastrostomy, named tri double-flap hybrid method (TDF). TDF is shown to be simple and useful for Siewert type II esophagogastric junction carcinoma.

Background Research has found valvuloplastic esophagogastrostomy using the conventional hand-sutured double-flap (CDF) technique to be a useful anti-reflux procedure after proximal gastrectomy. However, no study has focused on this reconstruction procedure after laparoscopic transhiatal lower esophagectomy and proximal gastrectomy (LEPG) for esophagogastric junction carcinoma primarily because of its profound difficulty. Thus, we devised a novel technique for valvuloplastic esophagogastrostomy comprising triangular linear-stapled esophagogastrostomy and hand-sutured flap closure, which we term the tri double-flap hybrid (TDF) method.

Methods After reviewing our institution's prospective gastric cancer database, 59 consecutive patients with Siewert type II esophagogastric junction carcinoma who underwent LEPG with valvuloplastic esophagogastrostomy from January 2014 to August 2018 were analyzed. Short- and mid-term surgical outcomes were then compared between the LEPG-TDF and LEPG-CDF groups to evaluate the efficacy of the TDF method.

Results The median operative time was 316 min (184–613 min) and blood loss was 22.5 ml (0–180 ml). In comparison between the two groups, the LEPG-TDF group had a significantly shorter operative time (298 vs. 336 min, $p = 0.041$) and significantly lower postoperative anastomotic leak/stenosis rates (0 vs. 14.2%, $p = 0.045$), compared to the LEPG-CDF group. No patient suffered from severe gastroesophageal reflux symptoms (Visick score ≥ III).

Conclusions This study showed that double-flap valvuloplastic esophagogastrostomy is safe and feasible for reconstruction after LEPG for Siewert type II esophagogastric junction carcinoma. Moreover, the TDF method is a simple and useful technique that offers a shorter operative time and lower morbidity compared to the CDF technique.

Keywords Laparoscopic surgery · Siewert type II esophagogastric junction carcinoma · Transhiatal approach · Double-flap technique · Proximal gastrectomy

Introduction

Recently, incidence rates of esophagogastric junction adenocarcinomas have been rapidly increasing despite the decreasing number of lower gastric cancers in Asian and Western countries.[1–5] Current trends in gastric surgery have focused on preserving function or less invasive procedures, even when treating esophagogastric junction adenocarcinoma, to provide patients with a better quality of life and acceptable oncologic outcomes.[6–9]

✉ Takeshi Omori
oomori-ta@mc.pref.osaka.jp

[1] Department of Gastroenterological Surgery, Osaka International Cancer Institute, 3-1-69 Otemae, Chuo-ku, Osaka 541-8567, Japan

Lower esophagectomy and proximal gastrectomy have now been accepted as the most suitable type of operation for esophagogastric junction carcinoma.[10–14] As to reconstruction, esophagogastrostomy is theoretically the most optimal considering its technical simplicity and preservation of normal bowel integrity.[10, 11, 13, 14] By contrast, esophagogastrostomy can potentially increase postoperative complications, such as reflux esophagitis and gastric stasis, especially when performed in the mediastinal space, due to the negative thoracic pressure, even if anti-reflux procedures such as fundoplication and His angle reconstruction were performed.[15–18] Therefore, a robust anti-reflux procedure is required for anastomosis.

Valvuloplastic esophagogastrostomy using the conventional hand-sutured double-flap technique has been reported to be a useful anti-reflux procedure after proximal gastrectomy.[19–21] However, no study has focused on this reconstruction procedure after laparoscopic transhiatal lower esophagectomy and proximal gastrectomy (LEPG) for esophagogastric junction carcinoma primarily due to its exceeding difficulty in the narrow lower mediastinal space.

To overcome the aforementioned issues, we have devised a new method for valvuloplastic esophagogastrostomy comprising triangular linear-stapled esophagogastrostomy and hand-sutured flap closure, which we term the tri double-flap hybrid (TDF) method. The present report analyzed the safety and feasibility of valvuloplastic esophagogastrostomy after LEPG for Siewert type II junction carcinoma while also describing in detail LEPG with the TDF method.

Methods

Study Design and Patient Selection

This cohort study was approved by the Human Ethics Review Committee of the Osaka International Cancer Institute (Protocol ID 1608169091). Written informed consent was obtained from all patients after being preoperatively informed of the surgical and oncologic risks.

According to a review of our prospective gastric cancer database, a total of 1002 consecutive patients with gastric cancer underwent gastrectomy at our institution from January 2014 to August 2018. Cases to be analyzed were identified using the following procedure (Fig. 1). First, we included 1002 patients who underwent gastrectomy. Of these, 248 underwent total gastrectomy and 636 underwent distal gastrectomy. The remaining 118 underwent proximal gastrectomy. Of these, 12 underwent open surgery and 1 underwent video-assisted thoracic surgery. The remaining 105 underwent laparoscopic proximal gastrectomy. Of these, 37 patients underwent surgery for Siewert type I or III esophagogastric junction cancer. The remaining 68 patients underwent laparoscopic transhiatal LEPG for Siewert type II esophagogastric junction adenocarcinoma. After excluding those who underwent LEPG with double tract reconstruction ($n = 9$), 59 patients (LEPG with valvuloplastic esophagogastrostomy using the double-flap method) were ultimately included herein. Accordingly, LEPG with the tri double-flap hybrid method (LEPG-TDF) and LEPG with the conventional hand-sewn double-flap technique (LEPG-CDF) were performed in 31 and 28 patients, respectively. The same surgical team operated on both groups.

Data Collection

Data were collected prospectively and recorded into our hospital's computer database. Accordingly, age, gender, tumor location, pathological findings, gastrectomy type, reconstruction method, lymph node dissection extent, operative outcomes, morbidity, and conversion to multiport or open procedures were determined. An open conversion was defined as any extension of the primary incision for reasons other than specimen extraction or the reconstruction procedure. Indications for conversion were also recorded. Morbidity was stratified as recommended by Dindo et al.[23] The 3rd English edition of the Japanese Classification of Gastric Carcinoma was used for TNM staging.[24]

Surgical Procedures

Laparoscopic Lower Esophagectomy and Proximal Gastrectomy

We had previously reported our surgical procedure for original double-flap reconstruction after laparoscopic proximal gastrectomy with perigastric and suprapancreatic lymph node dissection.[25–30] Briefly, a patient was placed in the reverse Trendelenburg position with his/her legs opened. The surgeon stood at the right side of the patient, while one assistant stood at the left side of the patient and between the patient's legs. A transumbilical laparotomy was created through a 2.5–3.0-cm vertical umbilical incision, after which a wound-sealing device was applied and covered by a commercially available access port (EZ access; Hakko, Nagano, Japan) to maintain pneumoperitoneum. A 12-mm trocar was then inserted via a laparoscopic access port. During the procedure, pneumoperitoneum was established using carbon dioxide insufflations at a pressure of 8 to 12 mmHg according to body type. A 10-mm flexible high-definition scope (Endoeye flexible HD camera system; Olympus Medical Systems Corp, Japan, Tokyo) or a 30° rigid high-definition scope (IMAGE 1 SPIES system, KARL STORZ, German, Tuttlingen) was used to visualize the surgical fields. Laparoscopic ultrasonic coagulation scissors (Harmonic

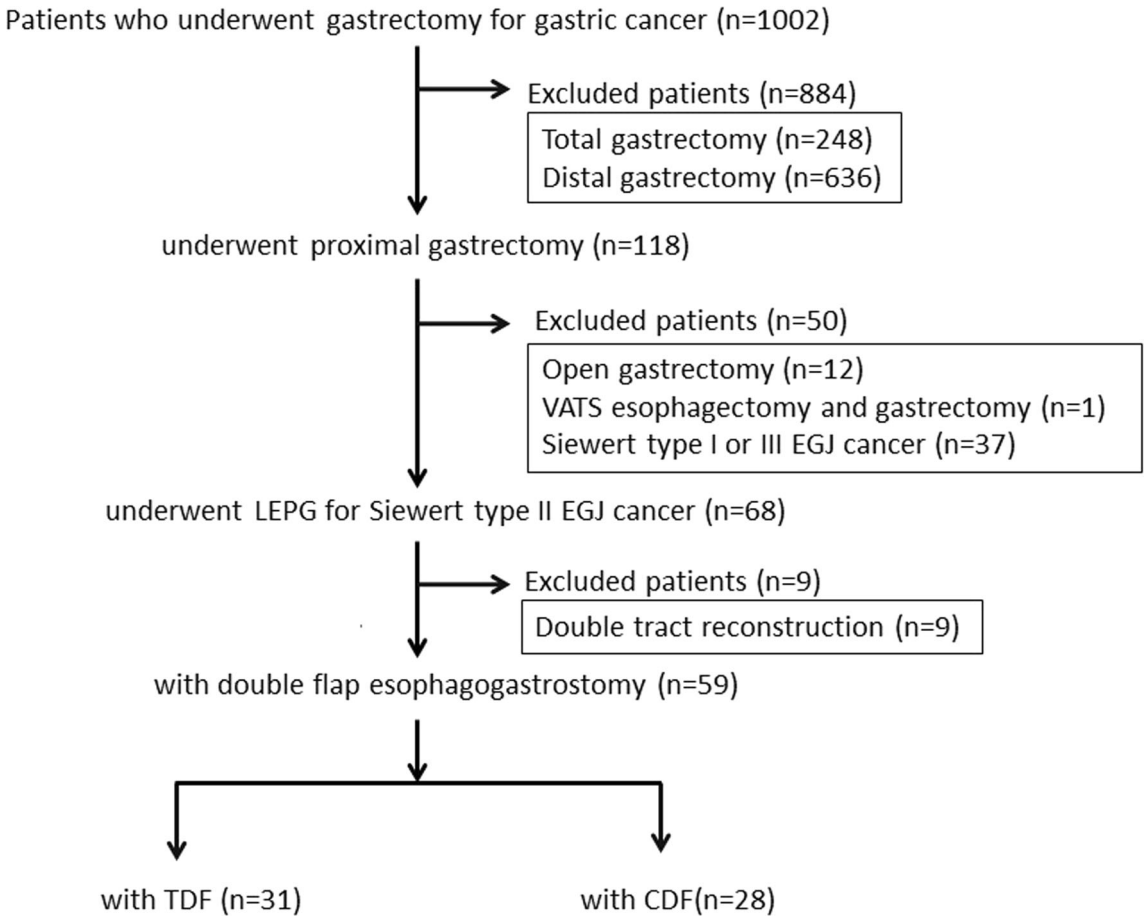

Fig. 1 Flowchart of patient selection. VATS, video-assisted thoracic surgery; LEPG, laparoscopic lower esophagectomy and proximal gastrectomy; CDF, conventional hand-sewn double-flap method; TDF, tri double-flap hybrid method

ACE, Ethicon Endosurgery, Cincinnati, OH) were mainly used for gastric mobilization and lymph node dissection. After dissection of perigastric and suprapancreatic lymph node, the right and left crura of the diaphragm were cut to improve lower mediastinal space visualization. The dissectable layer between the right crus and the lymphatic tissue was dissected toward the lower mediastinal space. After opening the infracardiac bursa, station 110 and 111 lymph nodes were dissected. The pericardium bordered the ventral side of station 110, while the inferior vena cava bordered the right side of station 111. Second, station 112Ao lymph node dissection was performed along the aorta. The proper esophageal artery was cut using energy devices if necessary. Third, station 112pul lymph nodes were dissected along the lungs until the inferior pulmonary vein was exposed (Fig. 2a). Finally, the esophagus was transected while securing adequate surgical margin (over 20 mm in length) using a linear stapling device (ECELON FLEX Powered ENDOPATH Stapler, Ethicon Endosurgery, Cincinnati, OH or Signia™ with a Tri-staple 60 mm purple cartridge, Medtronic, Ireland, Dublin), after which the resected specimen was extracted via a small incision (Fig. 2b).

Esophagogastrostomy Using the Conventional Double-Flap Technique

The original double-flap technique has been reported in several previous papers.[19–21] We have modified this technique and performed a conventional double-flap esophagogastrostomy using barbed sutures (V-Loc™ 90 Device, Medtronic, Minneapolis, MN) to simplify the procedures,[25] which we briefly describe as follows. An H-shaped seromuscular flap (2.5 × 3.5 cm), which was 5 cm from the top, was extracorporeally created on the anterior wall of the gastric remnant. The stomach was opened approximately 5 mm above the lower edge of the mucosal "window." The stomach was inserted into the peritoneal cavity, and pneumoperitoneum was re-established to perform intracorporeal anastomosis. First, the posterior wall of the esophagus 5 cm proximal from the esophageal stump was tied to the stomach at the cranial edge of the "window" using a barbed suture (V-Loc™ 90 Device, Medtronic, Minneapolis, MN). Second, esophagogastrostomy was performed through hand-sewn suturing. Finally, the anastomotic site and proximal esophagus were covered by the seromuscular flap using barbed sutures.

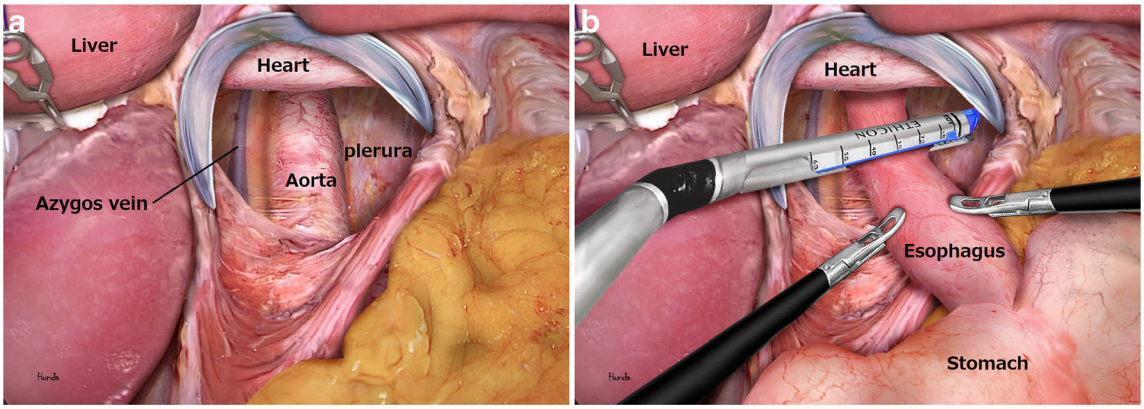

Fig. 2 **a** Completion of lower mediastinal lymph node dissection (nos. 108, 110, 111, 112Ao, and 112pul). **b** Transection of the esophagus. The esophagus was transected in the lower mediastinal space

Esophagogastrostomy Using the Tri Double-Flap Hybrid Method

First, an I-shaped flap (2.5 × 4.5 cm), which was vertically longer than the original double flap, was made on the anterior gastric wall (Fig. 3a). Second, esophagogastrostomy was performed using the intracorporeal triangular anastomotic technique (INTACT).[30, 31] A small hole was made 1 cm away from the distal edge of the open window case on the stomach (Fig. 3b) and at the left side of the esophageal stump (Fig. 3c). A linear stapling device (ECELON FLEX Powered ENDOPATH Stapler, Ethicon Endosurgery, Cincinnati, OH or a Signia™ with a Tri-staple 45 mm purple reinforced cartridge, Medtronic, Ireland, Dublin) was inserted into the stomach parallel to the distal edge of the window case via the small holes and into the esophagus parallel to the staple line of the esophageal stump (Fig. 3d), through which V-shaped esophagogastrostomy was performed. This first stapling was created 1 cm away from the staple line of the esophageal stump (Fig. 3e). Three stay sutures were placed at the right, middle, and left sides of the entry hole. To remove the ischemic area between the staple lines of the esophageal stump and the first anastomosis, the entry hole and the esophageal stump were simultaneously resected using a linear stapling device (ECELON FLEX Powered ENDOPATH Stapler, Ethicon Endosurgery, Cincinnati, OH or Signia™ with a Tri-staple 60 mm purple cartridge, Medtronic, Ireland, Dublin) (Fig. 3f). This anastomotic technique using INTACT provided a scalene triangle orifice and end-to-side anastomosis (Fig. 3g). Finally, the double flap was closed using barbed sutures (Fig. 3h), and the anastomotic orifice was completely wrapped with flaps.

When the dissection level of the distal esophagus was relatively high, three stay structures were placed at the esophageal stump to prevent the esophagus from retraction. Furthermore, the tissue surrounding the esophagus was sufficiently removed from the esophageal resection line to the 5-cm proximal esophagus for safe reconstruction. When the stapled transection or anastomosis fail due to high transection of the esophagus, the intrathoracic surgery should be performed

Evaluation of Operative Variables

Short- and long-term results, including short-term surgical outcomes, postoperative complications, hospital stay, and nutritional status, were compared among the cohorts.

Follow-Up Protocol

All cases underwent follow-up examination at 3, 6, and 12 months after surgery. Blood examinations and radiographs were obtained during all outpatient visits. Reflux symptoms were postoperatively evaluated using the modified Visick score at 6 and 12 months, and reflux esophagitis was assessed using the Los Angeles (LA) classification at 12 months after operation.[32, 33]

Fig. 3 **a** An I-shaped marking (25 × 45 mm) was made on the anterior wall of the stomach to create a seromuscular double flap. **b** A small hole was created 1 cm distal to the lower edge of the flap window case. **c** A small hole was created at the right edge of the esophageal stump. **d** A linear stapling device with a cartridge length of 45 mm was inserted into the esophagus and stomach, parallel to the staple line of the esophageal stump and the distal edge of the window cases, via the small holes to perform the first stapling for esophagogastrostomy. **e** Completion of the first stapling: The V-shaped anastomosis was performed 1 cm away from the staple line of the esophageal stump and the window of the stomach. **f** Closure of the entry hole: After three stay sutures were placed, the entry hole was closed using a 60-mm linear stapling device, and the ischemic area of the esophagus between the staple line of the esophageal stump and the staple line of the V-shaped anastomosis was simultaneously resected to maintain good blood flow toward the anastomotic site. **g** Completion of esophagogastrostomy using INTACT. INTACT practically allowed for end-to-side anastomosis in which the orifice was a scalene triangle in shape. **h** Completion of valvuloplastic esophagogastrostomy using the TDF hybrid method: The flaps were closed using continuous barbed suturing. The linear-stapled esophagogastrostomy using INTACT was completely wrapped into the flaps

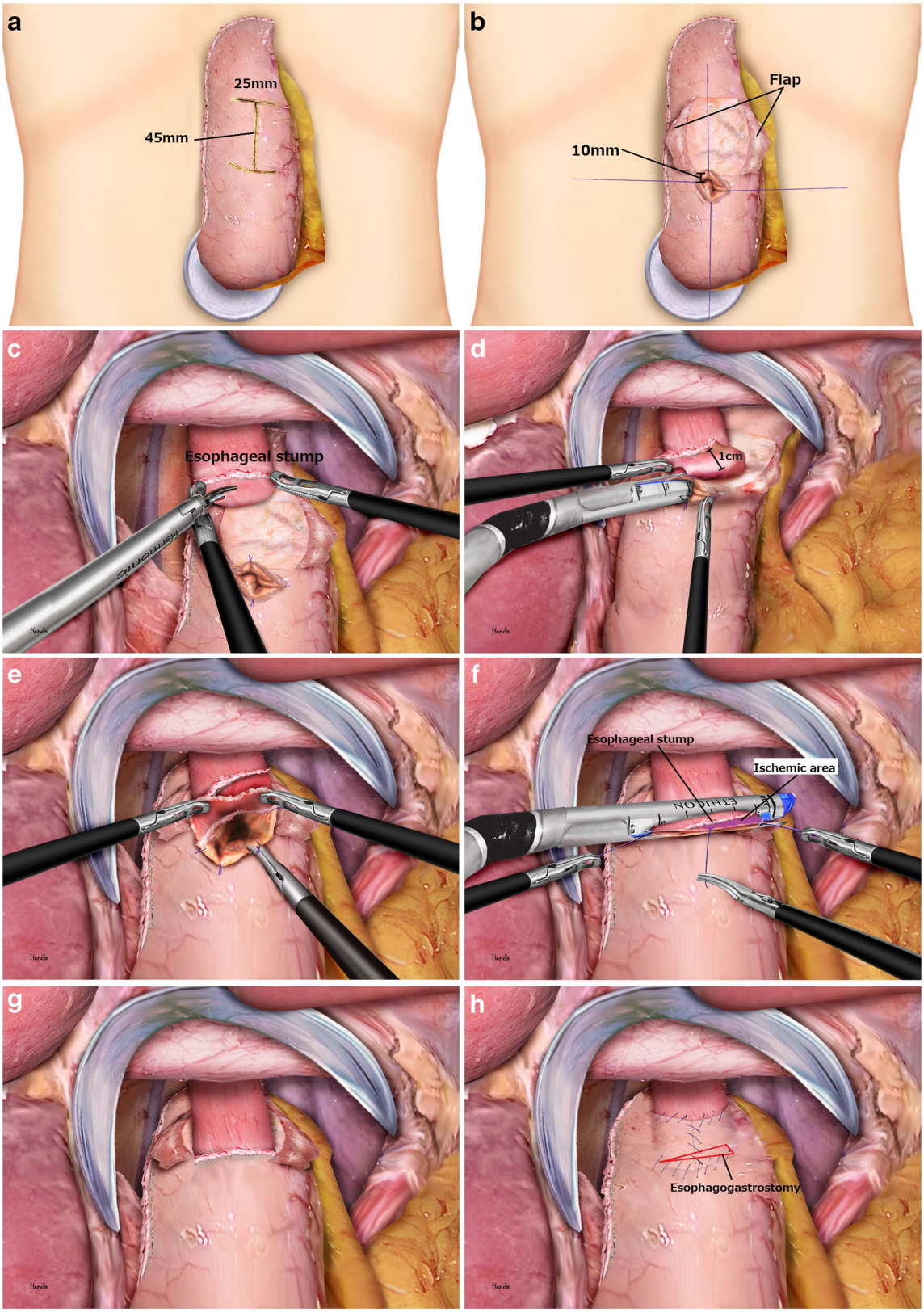
a
25mm
45mm
b
Flap
10mm
c
Esophageal stump
d
1cm
e
f
Esophageal stump
Ischemic area
g
h
Esophagogastrostomy

Postoperative Complications and Nutritional Outcomes

Clinical features [age, sex, performance status, American Society of Anesthesiologists (ASA) score, height, weight, body mass index (BMI), tumor size, histology], early postoperative complications (0–30 days), late postoperative complications (after 30 days), nutritional status, body weight, BMI, and laboratory data such as total lymphocyte count, total protein, serum albumin, and prognostic nutritional index (PNI) of patients were analyzed based on retrospectively collected data from our hospital's gastric cancer database.

Statistical Analysis

All statistical calculations were performed using the SPSS software package for Windows (SSPS version 23, Chicago, IL). Demographic and clinicopathological characteristics were summarized using descriptive analysis. All quantitative values are presented as medians and range, unless otherwise indicated. Student's *t* tests and Pearson's χ^2 tests were used to compare continuous and categorical variables. All values were two-tailed with those less than 0.05 being considered significant.

Results

Table 1 shows the demographic data of our cohort. All patients received double-flap esophagogastrostomy during LEPG with lower mediastinal lymph node dissection for the treatment of Siewert type II junction adenocarcinoma. The median length of the resected esophagus was 35 mm (5–70 mm). Table 2 outlines the surgical outcomes. All 59 cases of LEPG with valvuloplastic esophagogastrostomy were laparoscopically accomplished with no open conversion and transfusion. The median operative time was 316 min (184–613 min range), while the median blood loss was 22.5 ml (0–180 ml range). Liquid and soft diet were resumed at postoperative days 2 and 3, respectively. Contrast radiography on the third or fourth postoperative days revealed no contrast in media regurgitation into the esophagus in all 59 cases on a 30° head-down tilt position. With regard to early postoperative morbidities, although anastomotic leakage with pyothorax (Clavien–Dindo ≥ grade 3) was observed in one case (1.7%), no other complications were observed herein. The mean postoperative hospital stay was 8 days. With regard to late postoperative morbidities, anastomotic stenosis developed in three patients (5.1%) who received endoscopic balloon dilation therapy. Moreover, 51 patients (91.5%) had no reflux symptoms, whereas 5 (8.5%) complained of slight heartburn or acid regurgitation, which was controlled through medication (Visick score II). None of the patients suffered from postoperative gastroesophageal reflux symptoms (Visick score ≥ III) in both groups during 6 months of follow-up. Body weight at 3 and 6 months postsurgery was 91.3 and 88.6% that of the preoperative body weight, respectively. The incidence of reflux esophagitis was 10.5% for grade B or higher according to Los Angeles classification. Serum albumin levels at 3 and 6 months postsurgery were similar to preoperative levels. No mortality and recurrence were observed in this study.

Table 1 Patient characteristics

	LEPG-DF ($n = 59$)
Age, years, median (range)	68 (35–86)
Gender: male/female, n	12/47
BMI, kg/m^2	23.2 (15.3–31.6)
ASA physical status, *n*	
1/2/3	5/52/2
Main lesion, *n*	
Siewert type I/II/III	0/59/0
Type of tumor, *n*	
Intestinal/diffuse	43/16
Maximum tumor size, mm	40 (11–110)
Length of esophageal invasion, mm	10 (0–40)
Length of resected esophagus, mm	35 (5–70)
Neo-adjuvant chemotherapy	
Yes/no	4/55
Clinical T status, *n*	
T1/T2/T3/T4	28/16/14/1
Clinical N status, *n*	
cN0/N1/N2/N3	46/10/2/1
Clinical stage, *n*	
I/II/III/IV	39/16/3/1
Pathological T status, *n*	
pT1/T2/T3/T3	25/12/14/8
Pathological N status, *n*	
pN0	30
pN+ (N1/N2/N3)	29 (12/10/7)
Pathological stage, *n*	
I	31 (19/12)
II (IIA/IIB)	12 (6/6)
III (IIIA/IIIB/IIIC)	15 (8/3/4)
IV	1
Curability	
R0/R1	58/1
Adjuvant chemotherapy	
Yes/no	24/35

Values are presented as median (range). TNM staging was based on the Japanese Classification of Gastric Carcinoma, 3rd English edition[23]

LEPG-DF, laparoscopic lower esophagectomy and proximal gastrectomy with valvuloplastic esophagogastrotomy; *ASA*, American Society of Anesthesiologists; *BMI*, body mass index

Table 2 Short- and long-term outcomes

	LTEP-DF ($n = 59$)
Operative time, min, median (range)	316 (184–613)
Estimated blood loss, ml	22.5 (0–180)
Transfusion, *n*	0
Conversion, *n*	0
No. of lymph nodes retrieved, *n*	40 (13–80)
Early complication[a], *n* (%)	3 (5.1)
G2	2 (3.4)
Pulmonary infection	1 (1.7)
Pleural effusion	1 (1.7)
G3 or higher	1 (1.7)
Intra-abdominal fluid collection	0
Anastomotic leak	1 (1.7)
Pancreatic fistula/pancreatitis	0
Delayed gastric emptying	0
Postoperative hospital stay, days	8 (6–58)
Postoperative mortality	0
Late complication	
Anastomotic stenosis[b], *n* (%)	3 (5.1)
Reflux symptom	
Visick score I/II/III/IV	55/4/0/0
Body weight ratio	
Before surgery	100
3M	91.3 (77.6–108.7)
6M	88.6 (72.4–111.3)
1Y	88.4 (72.4–111.3)
Nutritional status	
Alb, g/dl	
Before surgery	4.2 (3.4–4.8)
3M	4.1 (3.3–4.9)
6M	4.1 (3.2–5.0)
1Y	4.2 (3.2–4.9)
Postoperative follow-up period	462 (119–1592)

Values are presented as median (range)

LEPG-DF, laparoscopic lower esophagectomy and proximal gastrectomy with valvuloplastic esophagogastrotomy; *POD*, postoperative day; *3M*, 3 months after surgery; *6M*, 6 months after surgery; *1Y*, 1 year after surgery

[a] Early complication is indicated by Clavien–Dindo classification grade ≥ 2

[b] Anastomotic stenosis is indicated by Clavien–Dindo classification grade ≥ 3

Comparison Between LEPG-TDF and LEPG-CDF

Patient backgrounds in terms of age, gender, BMI, ASA, tumor location, and TMN stage were almost well balanced in both groups (Table 3). The LEPG-TDF group had a significantly greater tumor size (45 vs. 31 mm, $p = 0.041$) and number of diffuse type tumors ($p = 0.009$) than the LEPG-CDF group (Table 3). These suggested that more advanced cancers were included in the TDF group. Table 4 compares surgical outcomes between both groups. The length of the resected esophagus was longer in the LEPG-TDF group than in the LEPG-CDF group (48.5 vs. 30 mm, $p = 0.026$) and the number of lymph nodes retrieved was significantly greater in the LEPG-TDF group than in the LEPG-CDF group (42 vs. 36, $p = 0.016$) because patients with more advanced cancer were included in the LEPG-TDF group. Despite such results, the median operative time was significantly shorter in the LEPG-TDF group than in the LEPG-CDF group (298 vs. 336 min, $p = 0.041$). When all cases were historically divided into two groups, the median operative time was comparable in the two groups (385 vs. 396 min) in the initial period (2014–2017 June), while the operative time was significantly shorter in the LEPG-TDF group than in the LEPG-CDF group (273 vs. 330 min, $p = 0.044$) in the late period (2017 July–2018 August). Blood loss did not significantly differ between the groups. Anastomotic leak was observed in one patient (3.5%) and anastomotic stenosis occurred in three patients (10.7%) in the LEPG-CDF group. On the other hand, no early and late postoperative complications, such as anastomotic leak and stenosis, were observed in the LEPG-TDF group. Early and late postoperative complications (Clavien–Dindo ≥ grade3) were significantly lower in the LEPG-TDF group than in the LEPG-CDF group ($p = 0.045$). The mean postoperative hospital stay was 8 days in both groups. The incidence of reflux esophagitis was 6.9% for grade B or over in the LEPG-TDF group, which was lower compared to in the LEPG-CDF group (14.3%), but there was no significant difference ($p = 0.341$). Postoperative gastroesophageal reflux symptoms were well controlled and comparable in both groups.

Table 5 compares postoperative body weight and nutritional status between the LEPG-TDF and LEPG-CDF groups. Accordingly, body weight was comparable in both groups 3 and 6 months postsurgery. Moreover, serum albumin levels, PNI values, and nutritional status were similar in both groups.

Discussion

The present study first analyzed the feasibility and safety of LEPG with double-flap valvuloplastic esophagogastrostomy under transhiatal laparoscopic approaches. Our results showed that LEPG with double-flap valvuloplastic esophagogastrostomy was safe and feasible given the low complication rates and absence of severe reflux symptoms with an acceptable long-term nutritional condition and body weight preservation. Particularly, the present study observed lower incidences of anastomotic leaks (1.7%) compared to previous reports (3.8–4.4%).[6, 7] The incidence of esophagitis at 12 months after surgery was 10.5% for grade B or higher, which was comparable or lower to a previous study that demonstrated the incidence of esophagitis was 18.2% in the

Table 3 Comparison of patient characteristics between the LEPG-TDF and LEPG-CDF groups

	LEPG-TDF ($n = 31$)	LEPG-CDF ($n = 28$)	p value
Age, years, median (range)	69 (35–86)	68 (40–81)	0.834
Gender: male/female, *n*	5/26	7/21	0.521
BMI, kg/m^2	23.4 (15.8–31.6)	22.5 (15.3–30.7)	0.387
ASA physical status, *n*			
1/2/3	3/26/2	2/26/0	0.358
Main lesion, *n*			
Siewert type I/II/III	0/31/0	0/28/0	1.000
Length of esophageal invasion, mm	14 (0–30)	5 (0–40)	0.602
Maximum tumor size, mm	45 (11–110)	31 (10–70)	0.044
Type of tumor, *n*			
Intestinal/diffuse	18/13	25/3	0.009
Neo-adjuvant chemotherapy			
Yes/no	1/30	3/25	0.337
Clinical T status, *n*			0.797
cT1	14	14	
cT2/T3/T4	6/10/1	10/4/0	
Clinical N status, *n*			1.000
cN0	24	22	
cN+ (N1/N2/N3)	7 (6/1/0)	6 (4/1/1)	
Clinical stage, *n*			
I/II/III/IV	18/11/2/0	21/5/1/1	0.299
Pathological T status, *n*			0.300
pT1	11	14	
pT2/T3/T4	8/5/7	4/9/1	
Pathological N status, *n*			0.438
pN0	14	16	
pN+ (N1/N2/N3)	17 (4/7/6)	12 (8/3/1)	
Pathological stage, *n*			0.370
I	14 (8/6)	17 (11/6)	
II (IIA/IIB)	7 (4/3)	5 (2/3)	
III (IIIA/IIIB/IIIC)	10 (4/2/4)	5 (4/1/0)	
IV	0	1	
Curability			
R0/R1	31/0	27/1	0.475
Adjuvant chemotherapy			
Yes/no	13/18	11/17	1.000

Values are presented as median (range). TNM staging was based on the Japanese Classification of Gastric Carcinoma, 3rd English edition

LEPG-TDF, laparoscopic lower esophagectomy and proximal gastrectomy with esophagogastrotomy using the tri double-flap hybrid method TDF; *LEPG-CDF*, laparoscopic lower esophagectomy and proximal gastrectomy with esophagogastrotomy using the conventional double-flap technique; *ASA*, American Society of Anesthesiologists; *BMI*, body mass index

mediastinum/intrathoracic conventional double-flap reconstruction.[34] Second, after comparing short- and long-term surgical outcomes of our novel TDF method and those of the CDF technique, our results showed that the TDF method provided shorter operative time and lower anastomotic morbidity rates compared to the CDF technique. Moreover, long-term results, particularly anti-reflux function, body weight, and nutritional condition, in the LEPG-TDF group were comparable to those in the LEPG-CDF group. Although the present study carries a small sample size from a single center, we found that TDF facilitates valvuloplastic esophagogastrostomy and is a safe and useful reconstruction method after laparoscopic transhiatal LEPG that could preserve anti-reflux function.

The original double-flap technique has been reported to necessitate that all procedures should be performed through totally hand-sewn suturing to achieve soft and flexible

Table 4 Comparison of surgical outcomes between the LEPG-TDF and LEPG-CDF groups

	LTEP-TDF ($n = 31$)	LTEP-CDF ($n = 28$)	p value
Operative time, min, median (range)	298 (184–505)	336 (227–613)	0.041
Estimated blood loss, ml	15 (0–170)	25 (0–180)	0.093
Transfusion, *n*	0	0	–
Conversion, *n*	0	0	–
No. of lymph nodes retrieved, *n*	42 (23–80)	36 (13–57)	0.016
Length of resected esophagus, mm	48.5 (5–70)	30 (5–60)	0.026
Morbidity[a], *n* (%)	0 (0)	4 (14.2)	0.045
Early complications			
Anastomotic leak	0	1 (3.6)	0.475
Intra-abdominal fluid collection	0	0	
Pancreatic fistula	0	0	
Late complications			
Anastomotic stricture[b]	0	3 (10.7)	0.101
Ileus	0	0	
Delayed gastric emptying	0	0	
Reflux symptoms			
Visick score I/II/III/IV	29/2/0/0	26/2/0/0	1.000
Postoperative hospital stay			
Median, days	8 (6–19)	8 (6–58)	0.208
Postoperative mortality	0	0	–

Values are presented in median (range)

[a] Morbidity is indicated by Clavien–Dindo classification grade ≥ 3

[b] Anastomotic stenosis is indicated by Clavien–Dindo classification grade ≥ 3, which necessitates endoscopic balloon dilation

anastomosis that is expected to function as a one-way check valve.[19] However, performing this reconstruction method in transhiatal laparoscopic is extremely complicated and time-consuming.[20–22] Accordingly, Hosoda et al. reported regarding intrathoracic double-flap reconstruction after LEPG, but an operative time was relatively long (662 min) in a case report.[33] Although the present study had a median operative time of 336 min in the CDF group, which is shorter than that in previous reports,[20–22, 35, 36] the procedures are still difficult in a transhiatal laparoscopic approach.

Table 5 Comparison of nutritional status between the LEPG-TDF and LEPG-CDF groups

	LTEP-TDF ($n = 31$)	LTEP-CDF ($n = 28$)	p value
Body weight ratio, %			
Before surgery	100	100	–
3M	90.4 (81.7–104.1)	91.6 (77.6–108.7)	0.484
6M	88.5 (77.4–104.1)	88.8 (72.4–111.3)	0.392
Alb, g/ml, median (range)			
Before surgery	4.2 (3.4–4.8)	4.1 (3.5–4.8)	0.181
3M	4.1 (3.3–4.9)	4.1 (3.4–4.6)	0.588
6M	4.1 (3.2–4.6)	4.1 (3.2–5.0)	0.901
PNI, median (range)			
Before surgery	50.2 (40–50.2)	48.2 (41.6–56.4)	0.400
3M	48.8 (41.5–57.3)	48.3 (39.6–60.5)	0.903
6M	48.8 (41.2–57.9)	49.2 (40.5–59.5)	0.169

Alb, serum albumin; *PNI*, prognostic nutritional index; *3M*, 3 months after surgery; *6M*, 6 months after surgery

Furthermore, previous reports have shown a 10–29% incidence rate of anastomotic stricture, which required some endoscopic dilations.[20–22] Our results showed incidence rates of 10.7% for anastomotic stricture in LEPG-CDF, which is similar to those in previous reports.[20–22, 33] Although their results suggested that some modifications, such as careful hand-sewn suturing combined with endoscopic guidance, should be required to prevent anastomotic stricture, the best procedure is still unknown.[20–22, 36]

To overcome the aforementioned problems, we had devised a hybrid technique for valvuloplastic esophagogastrostomy that comprised linear-stapled esophagogastrostomy using hand-sutured flap closure. We applied INTACT to linear-stapled esophagogastrostomy, which was originally developed for laparoscopic Billroth-I gastrectomy, to create a virtual end-to-end anastomosis with no twists and ischemic areas.[30, 31] The rate of anastomotic leaks after stapled esophagogastromy was reported to be 1.2–9.8% in previous reports.[37–39] In the present study, the incidence of

anastomotic leak was comparable or lower in the LEPG-TDF group than in the LEPG-CDF group (0 vs. 3.5%) or in the previous reports. In the present study, the length of the resected distal esophagus was longer in the LEPG-TDF group than in the LEPG-CDF group because of the larger tumor size and greater number of diffuse-type tumors in the former. Despite the severe conditions, the TDF hybrid method resulted in a shorter operative time compared to the CDF technique, which might be associated with a steep learning curve of the TDF procedures. Furthermore, the TDF method had excellent surgical outcomes such that no anastomotic leakage and stenosis occurred and there were significantly lower anastomotic complication rates than CDF esophagogastrostomy. This novel technique facilitates valvuloplastic esophagogastrostomy while achieving excellent surgical outcomes, even when performed after transhiatal LEPG.

Reports have shown that double-flap esophagogastrostomy reduces reflux symptoms.[20–22] Accordingly, Hosoda et al., who analyzed the reflux status using 24 h impedance–pH monitoring after proximal gastrectomy with double-flap esophagogastrostomy for early gastric cancer, showed that this method had a satisfactory anti-reflux function.[22] The TDF method had an acceptable anti-reflux function in terms of reflux symptoms, endoscopic findings, and nutritional status, which was comparable to the CDF method. Considering that end-to-side esophagogastrostomy was performed using INTACT, the vertical dissection around the proximal esophagus and flap length had been minimal compared to the overlap technique, in which end-to-side anastomosis is performed. The I-shaped flap, which was vertically longer than that in the CDF technique, was suitable for wrapping the linear-stapled esophagogastrostomy created using INTACT and the distal esophagus.

The present study has several limitations. First, the analysis was based on data collected from a single institution. Given the retrospective nature of this study, selection bias between the LEPG-TDF and LEPG-CDF groups was present because the historical background of the two groups differed. The first TDF method was performed in our institute in August 2016. Since then, the indications for TDF included all of Siewert type II junction cancer. The frequency of TDF increased during the study period, whereas the frequency of CDF decreased. Therefore, during the analyzed period, LEPG-CDF was performed mainly in the early period (2014–2017 June) and LEPG-TDF performed mainly in the late period (2017 July–2018). Second, the present study used only the Visick score for grading postoperative esophageal reflux and did not include assessments of patients' symptoms or quality of life using validated questionnaires after surgery. Third, the present study selected a small sample size and required further evaluation of long-term outcomes. Ideally, a large-scale randomized controlled study is required to confirm the feasibility of LEPG with double-flap valvuloplastic esophagogastrostomy and the superiority of the TDF reconstruction method in LEPG.

In summary, this study showed that double-flap valvuloplastic esophagogastrostomy is a feasible and safe reconstruction procedure after laparoscopic transhiatal LEPG for Siewert type II junction carcinoma. Our novel TDF method for valvuloplastic esophagogastrostomy is simple and useful given its shorter operative time and lower anastomotic complication rates compared to the CDF method. Nevertheless, prospective randomized trials are still required to establish the advantages of this novel reconstruction procedure over the CDF method.

Acknowledgments The authors would like to thank Enago (www.Enago.jp) for the English language review.

Authors' Contributions TO designed the study and wrote the initial draft of the manuscript. TO and KY contributed to data interpretation and critical revision of the manuscript for important intellectual content. All the other authors (KY, YY, NS, KS, HT, MY, HW, HM, MO, MY, and MS) contributed to data collection and interpretation and critical review of the manuscript. All authors have read and approved the final version of the manuscript and have agreed to be accountable for all aspects of the study, ensuring that any queries related to the accuracy or integrity of any part of the work are answerable.

Compliance with Ethical Standards

This study was approved by the Institutional Review Board of the Osaka International Cancer Institute. All procedures followed were in accordance with the ethical standards of the responsible committee on human experimentation (institutional and national) and with the Helsinki Declaration of 1964 and later versions. Informed consent to be included in the study, or the equivalent, was obtained from all patients.

Conflict of Interest The authors declare that they have no conflict of interest.

References

1. Wu H, Rusiecki JA, Zhu K, Potter J, Devesa SS. Stomach carcinoma incidence patterns in the United States by histologic type and anatomic site. Cancer Epidemiol Biomark Prev. 2009;18:1945–1952.
2. Steevens J, Botterweck AA, Dirx MJ, van den Brandt PA, Schouten LJ. Trends in incidence of oesophageal and stomach cancer subtypes in Europe. Eur J Gastroenterol Hepatol. 2010;22:669–678.
3. Kusano C, Gotoda T, Khor CJ, Katai H, Kato H, Taniguchi H, et al. Changing trends in the proportion of adenocarcinoma of the esophagogastric junction in a large tertiary referral center in Japan. J Gastroenterol Hepatol. 2008;23:1662–1665.
4. Blaser MJ, Saito D. Trends in reported adenocarcinomas of the oesophagus and gastric cardia in Japan. Eur J Gastroenterol Hepatol. 2002;14:107–113.
5. Ahn HS, Lee HJ, Yoo MW, Jeong SH, Park DJ, Kim HH, et al. Changes in clinicopathological features and survival after gastrectomy for gastric cancer over a 20-year period. Br J Surg. 2011;98:255–260.

6. Hosoda K, Yamashita K, Moriya H, Mieno H, Watanabe M. Optimal treatment for Siewert type II and III adenocarcinoma of the esophagogastric junction: a retrospective cohort study with long-term follow-up. World J Gastroenterol. 2017;23:2723–2730.
7. Sugita S, Kinoshita T, Kaito A, Watanabe M, Sunagawa H. Short-term outcomes after laparoscopic versus open transhiatal resection of Siewert type II adenocarcinoma of the esophagogastric junction. Surg Endosc. 2018;32:383–390.
8. Shi Y, Li L, Xiao H, Guo S, Wang G, Tao K, et al. Feasibility of laparoscopic gastrectomy for patients with Siewert-type II/III adenocarcinoma of the esophagogastric junction: a propensity score matching analysis. PLoS One. 2018;13:e0203125.
9. Nozaki I, Hato S, Kobatake T, Ohta K, Kubo Y, Kurita A. Long-term outcome after proximal gastrectomy with jejunal interposition for gastric cancer compared with total gastrectomy. World J Surg. 2013;37:558–664. doi: https://doi.org/10.1007/s00268-012-1894-4.
10. Adachi Y, Katsuta T, Aramaki M, Morimoto A, Shiraishi N, Kitano S. Proximal gastrectomy and gastric tube reconstruction for early cancer of the gastric cardia. Dig Surg. 1999;16:468–470.
11. Nakamura M, Yamaue H. Reconstruction after proximal gastrectomy for gastric cancer in the upper third of the stomach: a review of the literature published from 2000 to 2014. Surg Today. 2016;46: 517–527. doi: https://doi.org/10.1007/s00595-015-1185-4.
12. Ahn SH, Lee JH, Park DJ, Kim HH. Comparative study of clinical outcomes between laparoscopy-assisted proximal gastrectomy (LAPG) and laparoscopy-assisted total gastrectomy (LATG) for proximal gastric cancer. Gastric Cancer. 2013;16:282–289.
13. Aihara R, Mochiki E, Ohno T, Yanai M, Toyomasu Y, Ogata K, et al. Laparoscopy-assisted proximal gastrectomy with gastric tube reconstruction for early gastric cancer. Surg Endosc. 2010;24: 2343–2348.
14. Sakuramoto S, Yamashita K, Kikuchi S, Futawatari N, Katada N, Moriya H, et al. Clinical experience of laparoscopy-assisted proximal gastrectomy with Toupet-like partial fundoplication in early gastric cancer for preventing reflux esophagitis. J Am Coll Surg 2009;209:344–351.
15. Ichikawa D, Komatsu S, Okamoto K, Shiozaki A, Fujiwara H, Otsuji E. Evaluation of symptoms related to reflux esophagitis in patients with esophagogastrostomy after proximal gastrectomy. Langenbecks Arch Surg. 2013;398:697–701.
16. Nakamura M, Nakamori M, Ojima T, Katsuda M, Iida T, Hayata K, et al. Reconstruction after proximal gastrectomy for early gastric cancer in the upper third of the stomach: an analysis of our 13-year experience. Surgery. 2014;156:57–63.
17. Hosogi H, Yoshimura F, Yamaura T, Satoh S, Uyama I, Kanaya S. Esophagogastric tube reconstruction with stapled pseudo-fornix in laparoscopic proximal gastrectomy: a novel technique proposed for Siewert type II tumors. Langenbecks Arch Surg. 2014;399:517–523.
18. Chen XF, Zhang B, Chen ZX, Hu JK, Dai B, Wang F, et al. Gastric tube reconstruction reduces postoperative gastroesophageal reflux in adenocarcinoma of esophagogastric junction. Dig Dis Sci. 2012: 57:738–745.
19. Kamikawa Y. A new antireflux procedure in esophagogastrostomy after proximal gastrectomy. Gastroenterol Surg. 2001;24:1053–1060.
20. Kuroda S, Nishizaki M, Kikuchi S, Noma K, Tanabe S, Kagawa S, et al. Double-flap technique as an antireflux procedure in esophagogastrostomy after proximal gastrectomy. J Am Coll Surg. 2016;223:e7–13. doi:https://doi.org/10.1016/j.jamcollsurg.2016.04.041.
21. Muraoka A, Kobayashi M, Kokudo Y. Laparoscopy-assisted proximal gastrectomy with the hinged double flap method. World J Surg. 2016;40:2419–2424. doi: https://doi.org/10.1007/s00268-016-3510-5.
22. Hosoda K, Yamashita K, Moriya H, Mieno H, Ema A, Washio M, et al. Laparoscopically assisted proximal gastrectomy with esophagogastrostomy using a novel "open-door" technique: LAPG with novel reconstruction. J Gastrointest Surg. 2017:21: 1174–1180.
23. Dindo D, Demartines N, Clavien PA. Classification of surgical complications: a new proposal with evaluation in a cohort of 6336 patients and results of a survey. Ann Surg. 2004;240:205–213.
24. Japanese Gastric Cancer Association. Japanese classification of gastric carcinoma 3rd English edition. Gastric Cancer. 2011;14: 101–102.
25. Omori T, Moon JH, Yanagimoto Y, Sugimura K, Miyata H, Yano M. Pure single-port laparoscopic proximal gastrectomy using a novel double-flap technique. Ann Laparosc Endosc Surg. 2017:2: 123.
26. Omori T, Oyama T, Akamatsu H, Tori M, Ueshima S, Nishida T. Transumbilical single-incision laparoscopic distal gastrectomy for early gastric cancer. Surg Endosc. 2011; 25:2400–2404.
27. Hamabe A, Omori T, Tanaka K, Nishida T. Comparison of long-term results between laparoscopy-assisted gastrectomy and open gastrectomy with D2 lymph node dissection for advanced gastric cancer. Surg Endosc. 2012;26:1702–1709.
28. Omori T, Fujiwara Y, Moon J, Sugimura K, Miyata H, Masuzawa T, et al. Comparison of single-incision and conventional multiport laparoscopic distal gastrectomy with D2 lymph node dissection for gastric cancer: a propensity score–matched analysis. Ann Surg Oncol. 2016;23:817–824.
29. Omori T, Fujiwara Y, Yamamoto K, Yanagimoto V, Sugimura K, Masuzawa T, et al. The safety and feasibility of single-port laparoscopic gastrectomy for advanced gastric cancer. J Gastrointest Surg. 2019;23:1329–1339.
30. Omori T, Masuzawa T, Akamatsu H, Nishida T. A simple and safe method for Billroth I reconstruction in single-incision laparoscopic gastrectomy using a novel intracorporeal triangular anastomotic technique. J Gastrointest Surg. 2014;18:613–616.
31. Omori T, Nishida T. Distal Gastrectomy. In: Mori T, Dapri G, eds. Reduced Port Laparoscopic Surgery. Tokyo: Springer; 2014. pp. 183–95.
32. Watson DI, Jamieson GG, Lally C, Archer S, Bessell JR, Booth M, et al. Multicenter, prospective, double-blind, randomized trial of laparoscopic nissen vs anterior 90 degrees partial fundoplication. Arch Surg. 2004:139:1160–1167.
33. Armstrong D, Bennett JR, Blum AL, Dent J, De Dombal FT, Galmiche JP, et al. The endoscopic assessment of esophagitis: a progress report on observer agreement. Gastroenterology. 1996;111:85–92.
34. Kuroda S, Choda Y, Otsuka S, Ueyama S, Tanaka N, Muraoka A, Hato S, Kimura T, Tanakaya K, Kikuchi S, Tanabe S, Noma K, Nishizaki M, Kagawa S, Shirakawa Y, Kamikawa Y, Fujiwara T. Multicenter retrospective study to evaluate the efficacy and safety of the double- flap technique as antireflux esophagogastrostomy after proximal gastrectomy (rD- FLAP Study). Ann Gastroenterol Surg. 2018;3:96–103.
35. Hosoda K, Yamashita K, Moriya H, Washio M, Mieno H, Ema A, et al. Esophagogastric junction cancer successfully treated by laparoscopic proximal gastrectomy and lower esophagectomy with intrathoracic double-flap technique: a case report. Asian J Endosc Surg. 2018;11:160–164.
36. Hayami M, Hiki N, Nunobe S, Mine S, Ohashi M, Kumagai K, et al. Clinical outcomes and evaluation of laparoscopic proximal gastrectomy with double-flap technique for early gastric cancer in the upper third of the stomach. Ann Surg Oncol. 2017;24:1635–1642.
37. Irino T, Tsai JA, Ericson J, Nilsson M, Lundell L, Rouvelas I. Thoracoscopic side-to-side esophagogastrostomy by use of linear

stapler-a simplified technique facilitating a minimally invasive Ivor-Lewis operation. Langenbecks Arch Surg. 2016;401:315–22.
38. Xu QR, Wang KN, Wang WP, Zhang K, Chen LQ. Linear stapled esophagogastrostomy is more effective than hand-sewn or circular stapler in prevention of anastomotic stricture: a comparative clinical study. J Gastrointest Surg. 2011;15:915–21.
39. Maas KW, Biere SS, Scheepers JJ, Gisbertz SS, Turrado Rodriguez VT, van der Peet DL, Cuesta MA. Minimally invasive intrathoracic anastomosis after Ivor Lewis esophagectomy for cancer: a review of transoral or transthoracic use of staplers. Surg Endosc. 2012;26: 1795–802.

Publisher's Note Springer Nature remains neutral with regard to jurisdictional claims in published maps and institutional affiliations.