

MyHip: supporting planning and surgical guidance for a better total hip arthroplasty

A pilot study

Jérôme Schmid¹ · Christophe Chênes¹ · Sylvain Chagué² · Pierre Hoffmeyer³ · Panayiotis Christofilopoulos³ · Massimiliano Bernardoni⁴ · Caecilia Charbonnier²

Received: 15 November 2014 / Accepted: 13 March 2015 / Published online: 1 April 2015
© CARS 2015

Abstract

Purpose Total hip arthroplasty (THA) aims to restore patient mobility by providing a pain-free and stable artificial joint. A successful THA depends on the planning and its execution during surgery. Both tasks rely on the experience of the surgeon to understand the complex biomechanical behavior of the hip. We investigate the hypothesis that a computer-assisted solution for THA effectively supports the preparation and execution of the planning.

Methods We devised *MyHip* as a computer-assisted framework for THA. The framework provides pre-operative planning based on medical imaging and optical motion capture to optimally select and position the implant. The planning considers the morphology and range of motion of the patient's hip to reduce the risk of impingements and joint instability. The framework also provides intra-operative support based on patient-specific surgical guides. We performed a post-operative analysis on three patients who underwent THA. Based on post-operative radiological images, we reconstructed a patient-specific model of the prosthetic hip to compare planned and effective positioning of the implants.

Results When the guides were used, we measured non-significant variations of planned executions such as bone cutting. Moreover, patients' hip motions were acquired and

used in a dynamic simulation of the prosthetic hip. Conflicts prone to implant failure, such as impingements or subluxations, were not detected.

Conclusions The results show that *MyHip* provides a promising computer assistance for THA. The results of the dynamic simulation highlighted the quality of the surgery and especially of its planning. The planning was properly executed since non-significant variations were detected during the radiological analysis.

Keywords Total hip arthroplasty · Pre-operative planning · Guiding blocks · Medical imaging · Joint kinematics · Impingements and joint instability

Introduction

Total hip arthroplasty (THA) aims to restore patient mobility by providing a pain-free and stable joint. A successful THA is mainly characterized by the efficiency of the prosthetic hip in terms of biomechanics and fulfillment of patient expectations [31]. Another success criterion is the cost-effectiveness of the surgery—which includes economic aspects such as the surgical time and reduction in implant revisions (up to 150 % of the cost of a primary hip arthroplasty [50]).

THA is constantly evolving to reduce possible complications such as implant fracture or dislocation—despite it presents a very good survivorship (e.g., 80 % at 25 years of post-operative follow-up [31]). Complications are particularly related to the selection and positioning of the implants. These factors are also critical to ensure patients' comfort and satisfactory hip range of motion (ROM).

Conventional planning mostly relies on antero-posterior radiographs to image the patient's anatomy. Such procedure is subjective and lacks accuracy in assessing the correct posi-

✉ Jérôme Schmid
jerome.schmid@hesge.ch

¹ Geneva School of Health (HEdS), University of Applied Sciences of Western Switzerland (HES-SO), Av. de Champel 47, 1206 Geneva, Switzerland

² Medical Research Department, Artanim Foundation, Geneva, Switzerland

³ Orthopedics and Trauma Service, University Hospitals of Geneva, Geneva, Switzerland

⁴ Medacta International SA, Lugano, Switzerland

tioning of implants from 2D projected images [3]. To improve the planning accuracy, some authors devised computer-assisted solutions to select and fit the implants [25, 28, 43, 52].

Despite these improvements, the planning adopts a “static” approach that ignores dynamic aspects such as joint kinematics and postural variations (i.e., pelvic tilt [29]). Kinematics play an important role since some movements may yield excessive wear [5, 37] and create impingements resulting in reduced ROM [54], dislocations [40, 45] and implant loosening [34]. The influence of kinematics has been studied in relation with kinetics (load, stress) in computer simulations [1, 21, 45, 53]—but these works did not focus on planning strategies to provide computer-assisted support to THA.

While the THA success is undoubtedly dependent on the planning quality [16, 18], the surgeon’s ability to exactly reproduce the planning is also critical [38]. Without intra-operative assistance, surgeons usually refine their choice of resected areas and of the type and positioning of implants during surgery, which is time-consuming and may result in a loss of accuracy [47]. For instance, Callanan et al. [9] reported a 50% of malpositioned cups in non-assisted THA and hip resurfacing surgeries.

Computer-assisted surgical systems have often been reported with an increase in accuracy in implant positioning [2, 57]—but with some possible lengthening of surgical time [36]. An adequate intra-operative assistance should help to reproduce the planning while being cost-effective and respectful to patients (e.g., reasonable blood loss and short recovery time).

In this paper, our research hypothesis is that the consideration of patient morphology and dynamics during the pre- and intra-operative phases are expected to improve the quality and success of THA, as suggested by Wixson et al. [56]. To test it, we developed and present here our computer-assisted framework “MyHip” for THA that considers the anatomy and kinematics of the prosthetic hip during planning. The planning relies on morphology and ROM of the patient’s hip to optimally position the implant, and reduce the risk of impingements and joint instability. The framework also facilitates the automatic creation of patient-specific surgical guides for intra-operative assistance—a technology successfully used in total knee arthroplasties (TKA) [14, 15].

Materials and methods

Pre-operative planning

The goal of pre-operative planning is to assess the surgical parameters regarding acetabular and femoral positioning of implants—including size of implant components, cup orientation and stem anteversion, femoral neck cut height

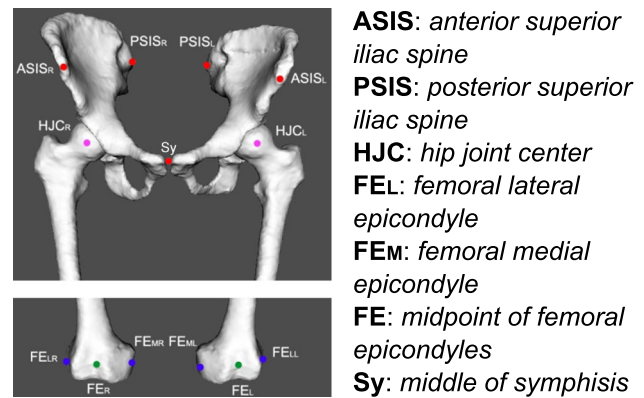


Fig. 1 Anatomical and functional landmarks for surgical and kinematic parameters

and angle, and differences in leg length and lateralization. Cup orientation is controlled by inclination and anteversion angles [39]. The positioning and the size of implants are known to be correlated with implant failures such as dislocations [26, 46], impingements [26], reduced ROM [7], excessive wear [8] and leg length discrepancy [27].

Anatomical reconstruction

Based on computed tomography (CT) images, we reconstruct subject-specific models of hips by segmentation. The CT protocol is designed to maximize image quality while reducing at best the dose—by using varying slice thickness (e.g., pelvis: [0.5–1] mm, femur: [2–3] mm) and acquiring only proximal and distal parts of the femurs.

Automatic thresholding coupled with bone filling segments most of the bones but we perform some manual segmentation to refine results in pathological areas with abnormal morphology and intensities. The manual refinement requires in average 5 min of time. The segmentation is carried out with Mimics software v16.0 (Materialise NV, Leuven, Belgium).

Various anatomical and functional landmarks (Fig. 1) are extracted from the reconstructed models to define key parameters of the surgical planning and the kinematics. For instance, landmarks on the pelvis are used to express pelvic tilt (“Pelvic tilt”) and implant orientation while femoral neck anteversion is derived from landmarks on femoral epicondyles. Similarly, the location of the hip joint center (HJC)—estimated by a functional method [19]—is required to compute the joint coordinate system and to estimate hip joint rotations.

Pelvic tilt

Pelvic tilt is defined as the angle α between the anterior pelvic plane (APP) and the coronal plane [4] (Fig. 2a). It is an impor-

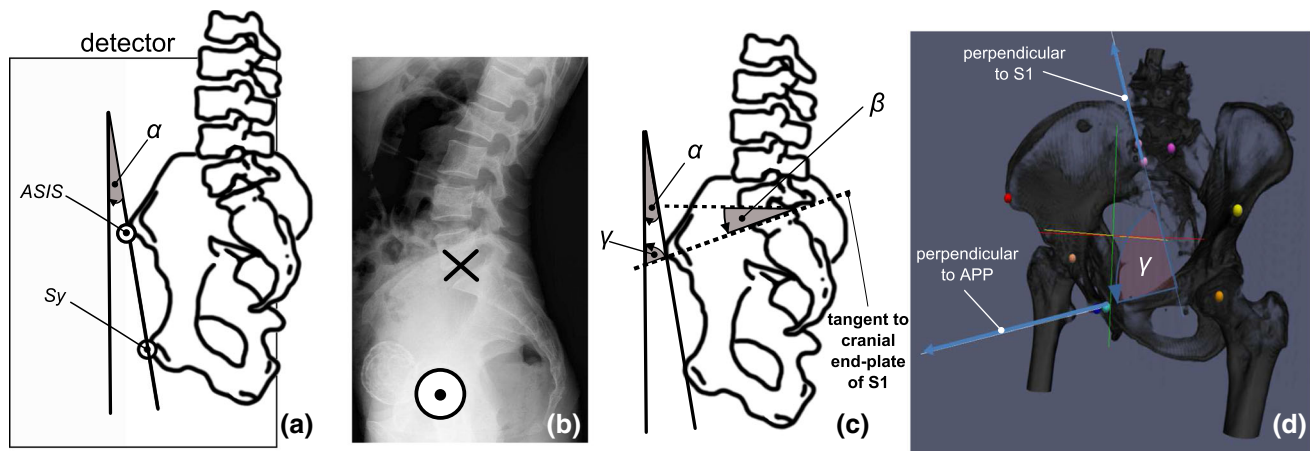


Fig. 2 Pelvic tilt computation. **a** The pelvic tilt is defined as the angle α between the coronal plane and the anterior pelvic plane (APP) passing through the ASIS and Sy anatomical landmarks. Here, the α angle is positive since the pelvis is anteverted. **b** Our alternative radiograph protocol: the centering point (X) is located below the iliac crest on the

lumbar spine and the success criterion is the alignment of the femoral heads (O). **c** The pelvic tilt is linked to the sacral slope β (angle between horizontal direction and cranial end-plate tangent of S1) and the γ angle by $\alpha = \gamma + \beta - \pi/2$. **d** The γ angle is independent of patient position and can be directly computed from the pelvic bone morphology

tant indicator of pelvis version that should be used to correct the chosen value of cup anteversion [32,44,48]. We used the ASIS and Sy anatomical landmarks (Fig. 1) to compute the APP [33].

Lateral radiographs are commonly used to measure pelvic tilt since patients can be acquired in weight-bearing position. To accurately measure the angle by avoiding beam divergence [58], left and right ASIS should be superimposed and centered with respect to the detector [4] (Fig. 2a). This results in a significantly large portion of the detector being directly exposed which yields too short exposure time and a bad image quality when using automatic exposure control.

To avoid the use of an invasive fluoroscopy guidance to tackle beam divergence, we devised an alternative protocol based on the acquisition of lateral lumbar spine radiographs (Fig. 2b). In this protocol, we do not need to acquire the ASIS as produced radiographs are used to compute the sacral slope. It is defined as the angle β between the horizontal direction and the cranial end-plate tangent of S1 (Fig. 2c).

As reported by Lazennec et al. [29], the β angle is accurately computed in lateral radiographs—with the same accuracy than would be obtained with the modality EOS (EOS imaging SA, Paris, France). Similar to radiographs, the EOS scans patients in standing position but does not produce images with projective distortion—which theoretically makes it a better candidate to compute pelvic descriptors. However, Lazennec et al. [29] could not find any statistical difference when measuring the sacral slope with EOS and standard radiographs.

The value of pelvic tilt α is linked to the sacral slope β with the following formula (Fig. 2c):

$$\alpha = \gamma + \beta - \pi/2 \quad (1)$$

The presence of divergence or the possible absence of the ASIS in the radiographs prevents the direct computation of the γ angle. However, the γ angle is not dependent on the patient position and can be expressed as the angle between the normals of the S1 cranial plate and the APP (Fig. 2d). Hence, we can easily compute this angle from the reconstructed models of the hip (“Anatomical reconstruction”).

Kinematics

To perform realistic motion simulations of prosthetic models, a motion database of daily activities was created. Four young active healthy subjects (1 female, 3 males; mean age, weight and height: 28.0 years, 74.2 kg and 181.5 cm) underwent magnetic resonance imaging (MRI) and motion capture.

Kinematic data were recorded using a Vicon MXT40S motion capture system (Oxford Metrics, UK) consisting of 24 cameras sampling at 120Hz. The volunteers were equipped with retroreflective markers ($\varnothing 14$ mm) placed directly onto the skin. Six markers were placed on pelvic anatomical landmarks (e.g., ASIS, Fig. 1) and two clusters of six markers were stuck on the lateral and frontal parts of both thighs. Additional markers were distributed over the body to provide a global visualization of the motion.

The following activities were recorded (3 trials each): walk, stand-to-sit, lie down on the floor, lace the shoes while seated and pick an object on the floor while seated or standing. These activities were chosen to reflect a variety of routine movements. Some are also known to be prone to hip implants failure (e.g., dislocation, impingements) [40,45]. If more specific patient’s activities (e.g., sport movements) would be required, the patient could perform a dedicated motion capture session to enrich the motion database.

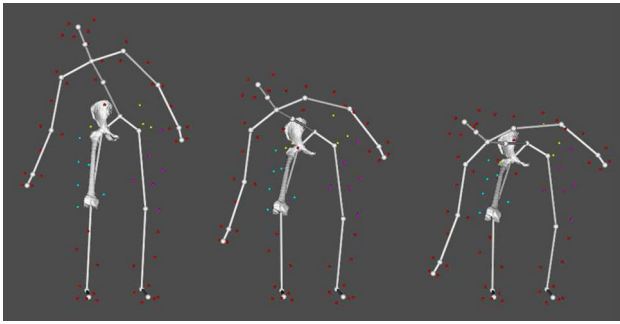


Fig. 3 Kinematic animation of the right hip joint during activity of “picking an object on the floor,” showing the markers set-up (small colored spheres) and a virtual skeleton used to better visualize and analyze the motion as a whole

The hip joint kinematics was computed from the recorded marker data (Vicon markers reconstruction error < 0.5 mm). To solve the issue of soft tissue artifacts (STA) that could hinder accurate kinematic estimation [30], we used a validated optimized fitting algorithm (accuracy: translational error \approx 0.5 mm, rotational error < 3°) which accounted for STA and patient-specific anatomical constraints [10,11]. Indeed, computed motion was applied to the volunteer’s hip joint 3D models reconstructed from their MRI data [51]—which allowed accounting for the subject’s anatomy and kinematic parameters (e.g., hip joint center). Figure 3 shows examples of computed postures.

The hip ROM was quantified for each volunteer and for all recorded daily activities, thanks to two bone coordinate systems (one for the pelvis, one for the femur) defined on the reconstructed models and derived from the anatomical landmarks (“Anatomical reconstruction”), according to standards of the International Society of Biomechanics [59]. Given the computed bone poses from motion capture data, hip angles (flex/ext, abd/add and IR/ER) were determined at each point of the movement [11]. Eventually, the ROM of the four volunteers’ trials were averaged for each activity, and the final values were stored in a database to be later used in the simulation software.

We decided to use a motion database for two main reasons: (1) to acquire target ROMs that THA should restore in terms of mobility, since patient undergoing this surgery have limited ROMs or simply cannot perform a motion capture due to their musculoskeletal disorder and (2) to avoid any additional financial burden to patients since acquiring patient motion might not be reimbursed by the health insurance.

Dynamic planning

Based on reconstructed models and surgical parameters computed from landmarks (“Anatomical reconstruction”), surgeons perform a virtual planning of THA. Implant size and positioning are selected and a virtual bone resection is

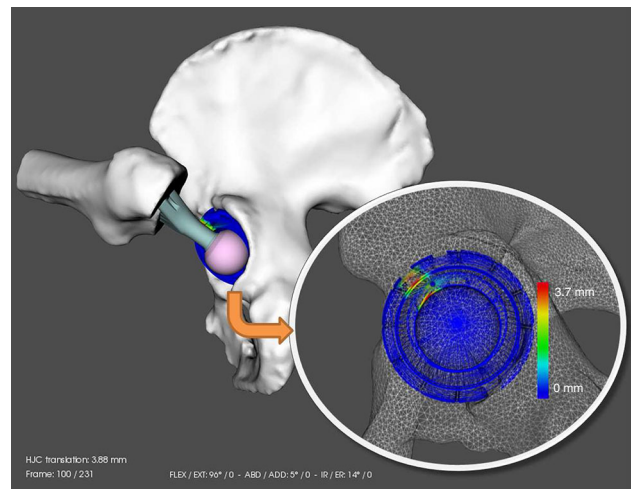


Fig. 4 Detection of the impingement region during simulation of a prosthetic hip. The colors represent the area of increased contact (blue no contact, red highest contact). Here, the simulation shows a prosthetic impingement between the stem and the cup/liner during lacing the shoes

immediately applied to the models, as exemplified in Fig. 4. This virtual planning is performed online and provides an efficient feedback to prepare a first planning based on morphological aspects.

The initial planning is subsequently refined by performing a dynamic simulation of the prosthetic 3D models driven by the motion database. The goal of this simulation is to detect potential risk of impingement and joint instability during everyday activities. The pre-computed hip angles stored in the database are first applied at each time step to the virtual prosthetic hip in its anatomical coordinate systems [12].

A collision detection algorithm [10,11] is then used to virtually locate abnormal contacts between both prosthetic and bony components (Fig. 4). Moreover, femoral head translations (subluxation) are computed to evaluate the joint congruence [12]. Based on the simulation’s results, the surgeon adapts and refines the initial implant configuration and selects the optimal planning for the surgery.

Intra-operative guidance

Guides are components that are placed intra-operatively on bones to support the bone resection process. Their surface must accurately match the patient anatomy to ensure a good anchoring, and their shape and positioning are derived from the surgical planning. Guides are thus personalized for the patient and the surgery, and are produced by rapid prototyping based on 3D meshes.

We devised a computer-assisted process for the creation of these meshes, exemplified in Fig. 5. Based on information of the surgical planning (e.g., cutting plane P for the femoral neck) and on constraints provided by the operator (e.g., anchoring points a_1 and a_2 specified on bone), generic

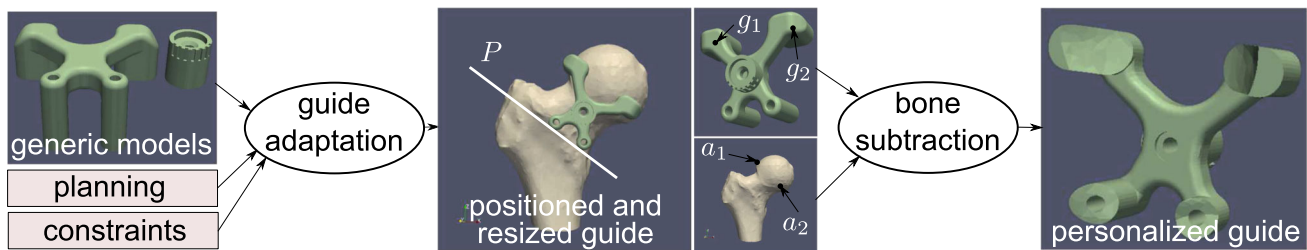


Fig. 5 Guide adaptation process with an example of prototype for a femoral guide. From left to right: a generic model of the guide is resized and positioned on the bone surface based on information of the planning (e.g., femoral cutting plane P) and constraints provided by an operator (e.g., points g_1 and g_2 of the superior “pads” of the model to be located at

anchoring points a_1 and a_2). The generic model is composed of sub-parts to easily resize the guide—while avoiding geometrical complications such as overlapping triangles. The bone surface is subsequently subtracted from the guide model to yield the final personalized guide

models of guides are automatically resized and positioned with respect to the reconstructed bones. The geometry of a guide is divided into different sub-parts that are independently deformed with thin-plate spline transforms (TPS) [17]—this subdivision mainly preventing geometrical complications such as overlapping triangles that could result from TPS.

Finally, the bone surface is removed from the adapted guide models based on Boolean mesh subtraction to obtain individualized meshes closely fitting patient anatomy. We used the CARVE library (<http://carve-csg.com>) to perform Boolean mesh operations.

Post-operative assessment

For validation purposes, we acquired and processed post-operative CT images of operated patients to accurately assess the quality of the surgery with respect to the planning—by reconstructing 3D models of the bones and implants. Patients underwent a post-operative dual energy CT scan designed to reduce artifacts of metallic implants. Instead of directly segmenting the collected images, we rigidly registered the pre-operative bone models (“Anatomical reconstruction”) and CAD models of the implants to the CT images.

The optimization of the model transformations was indirectly performed by controlling the motion of the corresponding models as they were rigid bodies evolving in a system built upon Newtonian laws of motion [51]. We defined external forces based on image gradient to attract models toward boundaries of interest [51]. To regulate the simultaneous evolution of several models, we implemented collision response to avoid inter-penetrating models and constrained the head of the stem to remain inside the socket of the cup’s liner.

Bone segmentation was corrected to account for resected areas. First the implant models were subtracted from the bone models, then the bony parts effectively removed by the surgery were manually identified in the image and subtracted from the models.

Experiments

First, we ran a pre-operative experiment to investigate the impact of pelvic tilt on THA planning, by performing a dynamic analysis on one patient (“Pre-operative experiment on pelvic tilt”). Then, we ran two post-operative experiments with three patients based on post-operative CT images and motion capture data (“Post-operative experiments”).

Pre-operative experiment on pelvic tilt

The purpose of this experiment was to quantitatively assess the impact of significant pelvic tilts in the dynamic planning. We considered a pelvic tilt as being significant when $|\alpha| > 5^\circ$ (Eq. 1). Such value of 5° would produce an approximate error of 3.5° in effective cup anteversion [32] (for planned radiographic anteversion (RA) of 15° and inclination (RI) of 45°)—yielding a cup configuration close to the limits of the recommended “safe zone” [45].

We measured on one patient a retroverted pelvic tilt of -17.8° based on our radiographic protocol (“Pelvic tilt”). Two sets of prosthetic 3D models were produced whether or not the pelvic tilt was accounted for in the planning. Dynamic simulations (“Dynamic planning”) were then performed with the two sets of models in order to compare the incidence of impingements during motion. To investigate more variations of ROM, all individual motion trials of the healthy volunteers were simulated for each daily activity instead of the averaged trials stored in the database.

Post-operative experiments

A pilot study was conducted with three male patients undergoing THA (mean age, weight and height: 65.0 years, 91.3 kg and 178.0 cm)—after approval from local ethics committees and written informed consent given by the patients. All patients benefited from the *MyHip* pre-operative planning. During their surgery performed with the anterior approach, only femoral guides were used since support for acetabular guidance was still under development.

Two post-operative experiments were conducted. The first experiment (“evaluation of intra-operative guidance”) studied the efficiency of the intra-operative guidance with respect to surgical outcomes, while the second one (“Dynamic simulation”) applied a dynamic analysis on reconstructed post-operative hips based on kinematics acquired from post-operative motion capture sessions or extracted from our motion database.

Evaluation of intra-operative guidance

Based on our registration-based approach (“Post-operative assessment”), pre-operative bone and implant models were simultaneously and rigidly registered to the corresponding CT image. We first assessed the accuracy of the bone segmentation by comparing the bone registration results with manual segmentations performed by a trained radiographer, based on the average symmetric distance (SD) [23]. Then, we measured (i) the differences in position and orientation of the virtual and effective cutting planes of femurs and (ii) the positioning of the stem with respect to the femur between the planning and the post-operative reconstruction. Based on these measures, the quality of the planning execution was studied along with associated surgical outcomes such as leg length discrepancy.

Dynamic simulation

After a minimum of four months after surgery, the three patients participated to a motion capture session. Marker data were collected during the activities of daily living with the same motion capture system and markers protocol as those used in the pre-operative stage. The captured data were post-processed and the patients’ hip ROM were calculated based on the method described in Section “Kinematics.”

Using the patient’s motion as input and the models of their prosthetic hips reconstructed from the post-operative CT images (“evaluation of intra-operative guidance”), a dynamic simulation was performed to assess the prevalence of impingement during their practice. Again, the collision detection algorithm [10, 11] was used to detect any abnormal contact (“Dynamic planning”). All patients’ trials were simulated. To evaluate the patients’ mobility compared to healthy subjects, additional simulations were performed with motion data from the database.

Results

Impact of pelvic tilt on planning

In the pre-operative experiment on pelvic tilt impact (“Pre-operative experiment on pelvic tilt”), the dynamic simulation was performed for the planning with and without tilting con-

sideration. For both plannings, impingements were observed during lacing the shoes in the antero-superior position of the acetabulum. Contacts occurred either between the stem and acetabular rim (20%), the femur and anterior superior iliac spine (20%) or a combination of both (60%). Subluxation was slightly higher when the pelvic tilt was ignored (mean \pm standard deviation: 1.0 ± 1.5 mm without tilt vs. 0.7 ± 1.0 mm with tilt).

Moreover, impingements between the prosthetic components were more intense. In particular, the stem and cup/liner also encountered collisions, which could result in extra joint damage.

Evaluation of intra-operative guidance

In the first post-operative experiment (“Evaluation of intra-operative guidance”), the simultaneous registration of bone and implant models required in average 3 min to converge (Intel Xeon Quad-Core at 2.1 Ghz, 8 Gb of RAM), while the subsequent manual correction for resected bone was quickly performed within 5–10 min.

The rigid registration of models combined with inter-model constraints (collisions, liner-head constraint) allowed us to tackle image regions with significant metallic artifacts that would have been very difficult to segment manually (Fig. 6a, b). Indeed, since some regions around bone and implants presented little image artifacts, the approach was more effective in these regions and could constraint the registration in areas with more artifacts—yielding a robust process.

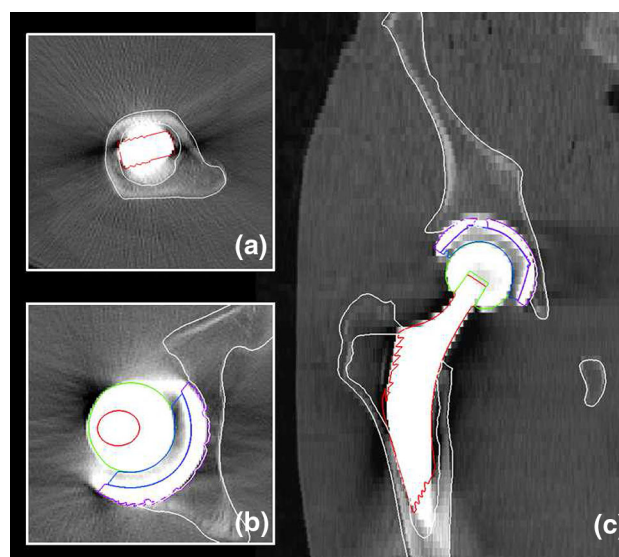


Fig. 6 Example of segmentation of a post-operative CT image by rigid registration of pre-operative models, whose contours are overlaid on **a–b** axial and **c** coronal slices. Our constrained registration is particularly useful in regions with strong metallic artifacts, exemplified in the axial slices

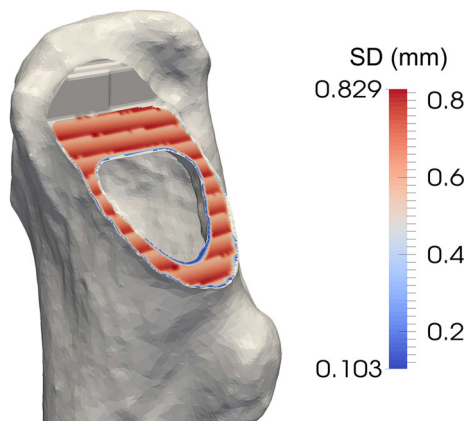


Fig. 7 Example of segmented femur for which the cutting plane area is color mapped with the surface distance between planned and effective resection. Highest errors take place along lines related to the staircase effect of manual segmentation

Despite we used pre-operative bone models and the images presented resected areas and image artifacts, we observed an accurate bone segmentation (Fig. 6). Compared to the manual reference segmentation, we measured an average SD of 0.36 ± 0.20 mm.

We measured small differences in the position and orientation of the virtual and effective cutting planes of femurs. We computed for the cutting plane area an average surface error of 0.68 ± 0.08 mm. As shown in Fig. 7, this small error was partially related to the “staircase” effect of the reconstruction of the manually segmented area. Since the accuracy of the bone segmentation was very satisfactory (≈ 0.36 mm), it did not significantly bias the computation of the cutting plane error.

Finally, we compared the positioning of the stem with respect to the femur between the planning and the post-operative reconstruction, by measuring an average distance of 4.4 mm between the centers of the planned and post-operative head of the stem.

Post-operative dynamic simulation

In the second post-operative experiment (“Dynamic simulation”), no impingement could be noted for any patient using their own motion. When the motion database was used, bony impingements were observed during lacing the shoes and prosthetic impingements occurred during picking an object while standing for all patients. The average subluxation was 2.63 ± 2.25 mm and 1.01 ± 1.31 mm, respectively. The contacts were all located in the antero-superior position of the acetabulum.

Interestingly, patients did not have the same ROM compared to the one from the motion database of healthy subjects. Patients performed the different daily activities with lower hip flexion ($-13 \pm 11.2^\circ$) and higher abduction ($+14 \pm 4.4^\circ$).

In addition, one patient could not perform the full ROM of one motion (lace the shoes) because of hip and back pain.

Discussion

Dose exposure in radiological acquisitions

Volunteers of our pilot study underwent various radiological acquisitions: the pre-operative CT for anatomical reconstruction (“anatomical reconstruction”), the lateral radiograph for pelvic tilt computation (“pelvic tilt”) and finally the post-operative CT for post-operative assessment (“evaluation of intra-operative guidance”). In clinical routine, the *MyHip* approach does not include post-operative CT acquisitions as surgeons commonly assess the implant position by using post-operative radiographs—to reduce dose exposure. In this study, the Computed Tomography Dose Index (CTDI) and the Entrance Surface Dose (ESD, for radiographs) were within the recommended National Diagnostic Reference Levels provided by the Swiss Federal Office of Public Health.

In our pre-operative CT protocol, we sought for the best trade-off between image quality and delivered dose, and we preferred not to use MR images as an alternative modality despite it is not invasive. In fact, despite equivalent bone segmentation accuracy with MR or CT images has been reported with cadavers [6, 49], MR scanning time is longer—possibly yielding image motion artifacts with patients [49]. Furthermore, MR segmentation generally requires more complex segmentation approaches as trabecular and cortical bone intensities vary and are dependent on the MR protocol [51]. Finally, surgical outcomes are generally worse when MR images are used for arthroplasty planning instead of the CT modality (e.g., superiority of CT-based plannings [20] in post-operative neutral alignment of total knee arthroplasty compared to an MR-based approach [42]).

Pelvic tilt computation and consideration

Our experiment on the impact of pelvic tilt (“Impact of pelvic tilt on planning”) showed that if the tilt was ignored during planning, there was an increased risk of observing significant subluxation and impingement in the prosthetic hip. These results are consistent with other studies that showed the necessity to consider pelvic tilt in THA [32, 44, 48].

Our imaging protocol to measure pelvic tilt (“Pelvic tilt”) is currently performed in various clinics and hospitals, and the feedback from radiographers and physicians is so far very positive. The main advantage of the protocol that we were reported was its close similarity with standard protocols for lumbar spine acquisition. These protocols being mastered by radiographers, the integration of the new protocol in clinical

practice is greatly facilitated without any significant loss in productivity.

Besides this positive qualitative assessment, our imaging protocol also brings some robustness against possible positioning errors performed by radiographers such as lateral flexion and pelvis rotation. Imai et al. [24] showed that errors up to 6° in lateral flexion or rotation did not impact significantly the accuracy of the sacral slope measurement from lateral radiographs. In [55], results showed that even with large rotations up to 30° , the measurement was still reliable. Experienced radiographers confirmed to us that they could achieve an alignment of the femoral heads with errors below 6° .

Study [24] also reported an accuracy of 3° to compute the sacral slope from lateral radiographs. We showed in Eq. (1) that pelvic tilt and sacral slope were related to the γ angle. Since this angle can be computed accurately from the reconstructed models or the CT images, the computation of the pelvic tilt is expected to be as accurate as the measurement of the sacral slope.

Use of intra-operative guidance

Currently, the femoral guide provides assistance for the bone resection but not for the placement of the femoral component. Even if such assistance was available, many surgeons still prefer to be able to perform some modifications based on information only available intra-operatively (e.g., penetration and adherence of the stem in the femur). Still, the analysis of differences between planned and executed femoral arthroplasty provides insightful information.

The absence of significant differences between planned and performed femoral cut (≈ 0.68 mm of surface error, Section “evaluation of intra-operative guidance”) highlighted the surgeons’ capability to correctly replicate the planned bone cutting by using the femoral guide. As a result, guides offer a cost-effective alternative to more complex computer-assisted surgical systems, since they offer accuracy and reproducibility for an operative time equivalent to a traditional surgery. Indeed, despite these advanced systems provide improved reliability and accuracy, they are more expensive and usually yield longer operative times [36].

Despite the planned bone resection was well executed, surgeons did not fully respect the suggested placement of the femoral component as we measured an average error of 4.4 mm between planned and executed positions of the stem head (“evaluation of intra-operative guidance”). This error may impact any planned correction of leg length discrepancy (LLD)—a magnitude of LLD over 20 mm being often associated with post-operative signs of discomfort or functional disabilities [22]. The value of problematic LLD being patient-specific, other studies [41] proposed a more conservative threshold of 10 mm. Knowing that THAs usually yield

an average LLD of 5–6 mm [27, 35], the measured difference of 4.4 mm is likely to lead to an LLD below this conservative threshold.

We also assessed the impact of the automated creation of the femoral guides (“intra-operative guidance”) from a productivity perspective. We surveyed the operators responsible for creating the models of the guides based on the planning—who commonly performed a manual positioning and resizing of the models. They reported that the time required to design the models decreased from 25 min to 3 min (in average).

Despite we reconstructed the acetabular components from the post-operative images (“Evaluation of intra-operative guidance”), we did not perform a similar post-operative analysis since the involved patients did not benefit from an acetabular guide. Furthermore, some surgeons use to align the cup with respect to the transverse ligament, ignoring the traditional rule of thumb of 45° – 15° for inclination and anteversion. A further study would be necessary to understand the impact of this anatomical alignment, especially with respect to dynamic aspects as conducted in our experiments.

Consideration of hip kinematics

As in our previous studies [12, 13], we studied the effects of implant positioning, pelvic tilt and motion on impingements, joint congruence and ROM—using computer simulations and motion capture data. A strong correlation between the frequency of impingements and implant characteristics was reported. This confirmed the importance of performing a dynamic planning to select the best implants configuration based on the patient’s morphology, posture and activity lifestyle.

In the post-operative experiment (“post-operative dynamic simulation”), we investigated the surgical outcomes in terms of kinematics and impingements. Patient’s motion was free of collisions, but not when testing with ROM of healthy subjects. Simulations revealed interesting motion adaptations in order to execute the different activities. In particular, patients adopted less hip flexion with more abduction, which seems to be a good strategy to avoid impingement. However, it is unknown if those adaptations resulted from the hip replacement, since we could not compare the patient’s post-operative ROM to motion data acquired before the surgery. This aspect could be addressed in future work—such a study providing useful information about patient’s mobility, stability and kinematic changes after THA.

Finally, we were unable to post-operatively evaluate whether the use of intra-operative acetabular guidance to accurately reproduce the planning minimizes the frequency of impingement during motion, since the guide was still under development. The results of our post-operative study showed that the patients’ hips were in good function. However, a more comprehensive study including more patients

undergoing THA under the *MyHip* framework is necessary to evaluate the support of acetabular guidance. This kind of study is already planned by our research team.

Conclusion

We presented the computer-assisted *MyHip* framework to plan and execute THA. Based on patient-specific data including anatomical and dynamic information (posture, kinematics), we refined traditional planning by simulating the prosthetic hip and detecting some possible causes of implant failures. We showed how surgical guides can be designed with computer assistance and how they effectively assist surgeons in performing more accurate surgical gestures—yielding a more cost-effective surgery.

So far, more than 230 *MyHip* surgeries have been successfully performed with the femoral guide. Results are very encouraging, but future work is needed to fully validate the overall approach. In particular, the acetabular guide is now available and we are extending our experiments to account for a larger number of subjects and testing conditions.

Acknowledgments Authors would like to thank all members of the *MyHip* consortium, as well as the patients and volunteers who agreed to participate to this study. This research work was supported by the *MyHip: Patient-Specific Pre-operative Planning and Intra-operative Surgical Guidance for Total Hip Arthroplasty* project funded by the Swiss Commission for Technology and Innovation (CTI No. 13573.1 PFFLE-LS).

Compliance with ethical standard All procedures performed in studies involving human participants were in accordance with the ethical standards of the institutional and/or national research committee and with the 1964 Helsinki Declaration and its later amendments or comparable ethical standards.

Conflicts of interest All authors declare that they have no conflict of interest.

Informed consent Informed consent was obtained from all individual participants included in the study.

References

1. Asgari S, Hamouda A, Mansor S, Singh H, Mahdi E, Wirza R, Prakash B (2004) Finite element modeling of a generic stemless hip implant design in comparison with conventional hip implants. *Finite Elem Anal Des* 40(15):2027–2047
2. Beaumont E, Beaumont P, Odermat D, Fontaine I, Jansen H, Prince F (2010) Clinical validation of computer-assisted navigation in total hip arthroplasty. *Adv Orthoped* 2011
3. Beckmann J, Lüiring C, Tingart M, Anders S, Grifka J, Köck F (2009) Cup positioning in THA: current status and pitfalls. a systematic evaluation of the literature. *Arch Orthop Trauma Surg* 129(7):863–872
4. Blondel B, Parratte S, Tropiano P, Pauly V, Aubaniac JM, Argenson JN (2009) Pelvic tilt measurement before and after total hip arthroplasty. *J Orthop Traumatol Surg Res* 95(8):568–572
5. Bowsher J, Hussain A, Williams P, Shelton J (2006) Metal-on-metal hip simulator study of increased wear particle surface area due to ‘severe’ patient activity. *Proc IME H J Eng Med* 220(2):279–287
6. Van den Broeck J, Vereecke E, Speetjens R, Vander Sloten J (2014) Segmentation accuracy of long bones. *Med Eng Phys* 36(7):949–953
7. Burroughs B, Hallstrom B, Golladay G, Hoeffel D, Harris W (2005) Range of motion and stability in total hip arthroplasty with 28-, 32-, 38-, and 44-mm femoral head sizes: an in vitro study. *J Arthroplasty* 20(1):11–19
8. Callaghan J, Pedersen D, Johnston R, Brown T (2003) Clinical biomechanics of wear in total hip arthroplasty. *Iowa Orthop J* 23:1–12
9. Callanan M, Jarrett B, Bragdon C, Zurakowski D, Rubash H, Freiberg A, Malchau H (2011) The John Charnley award: risk factors for cup malpositioning: quality improvement through a joint registry at a tertiary hospital. *Clin Orthop Relat Res* 469(2):319–329
10. Charbonnier C, Assassi L, Volino P, Magnenat-Thalmann N (2009) Motion study of the hip joint in extreme postures. *Vis Comput* 25(9):873–882
11. Charbonnier C, Kolo F, Duthon V, Magnenat-Thalmann N, Becker C, Hoffmeyer P, Menetrey J (2011) Assessment of congruence and impingement of the hip joint in professional ballet dancers. *Am J Sports Med* 39(3):557–566
12. Charbonnier C, Chagué S, Bernardoni M, Panzoni M, Hoffmeyer P, Christofilopoulos P (2014) Sexual activity after total hip arthroplasty: a motion capture study. *J Arthroplasty* 29(3):640–647
13. Charbonnier C, Chagué S, Schmid J, Kolo F, Bernardoni M, Christofilopoulos P (2014) Analysis of hip range of motion in everyday life: a pilot study. *Hip Int* 25(1):82–90
14. Chemello C, Costacurta G (2014) Patient Specific Instruments is really useful? Prospective study of 50 pre-navigated total knee replacement. In: *Proceedings of CAOS*
15. Dao-Lena S, P M (2014) Patient specific guides for total knee arthroplasty. A cadaveric study. In: *Abstracts of CAOS*
16. De Thomasson E, Mazel C, Guingand O, Terracher R (2002) Value of preoperative planning in total hip arthroplasty. *Revue de chirurgie orthopedique et reparatrice de l’appareil moteur* 88(3):229–235
17. Duchon J (1977) Splines minimizing rotation-invariant semi-norms in sobolev spaces. In: *Constructive theory of functions of several variables*. Springer, pp 85–100
18. Egli S, Pisan M, Müller M (1998) The value of preoperative planning for total hip arthroplasty. *J Bone Joint Surg Br* 80(3):382–390
19. Gilles B, Kolo F, Magnenat-Thalmann N, Becker C, Duc S, Menetrey J, Hoffmeyer P (2009) MRI-based assessment of hip joint translations. *J Biomech* 42(9):1201–1205
20. Goldberg T, Curry WT, Bush JW (2013) CT-based patient-specific instrumentation is accurate for TKA: a single-surgeon, prospective trial. *Bone Joint J Orthop Proc Supp* 95(34):325–325
21. Gross S, Abel E (2001) A finite element analysis of hollow stemmed hip prostheses as a means of reducing stress shielding of the femur. *J Biomech* 34(8):995–1003
22. Gurney B (2002) Leg length discrepancy. *Gait Posture* 15(2):195–206
23. Heimann T, Van Ginneken B, Styner MA, Arzhaeva Y, Aurich V, Bauer C, Beck A, Becker C, Beichel R, Bekes G et al (2009) Comparison and evaluation of methods for liver segmentation from CT datasets. *IEEE Trans Med Imaging* 28(8):1251–1265
24. Imai N, Miyasaka D, Horigome Y, Suzuki H, Takubo R, Endo N (2014) Are measurements of sacral slopes reliable? *Am J Clin Med Res* 2(3):57–60

25. Jun Y, Choi K (2010) Design of patient-specific hip implants based on the 3D geometry of the human femur. *Adv Eng Softw* 41(4):537–547
26. Kluess D, Martin H, Mittelmeier W, Schmitz KP, Bader R (2007) Influence of femoral head size on impingement, dislocation and stress distribution in total hip replacement. *Med Eng Phys* 29(4):465–471
27. Konyves A, Bannister G (2005) The importance of leg length discrepancy after total hip arthroplasty. *J Bone Joint Surg Br* 87(2):155–157
28. Lattanzi R, Viceconti M, Zannoni C, Quadrani P, Toni A (2002) Hip-Op: an innovative software to plan total hip replacement surgery. *Inform Health Soc Care* 27(2):71–83
29. Lazennec J, Rousseau M, Rangel A, Gorin M, Belicourt C, Brusson A, Catonné Y (2011) Pelvis and total hip arthroplasty acetabular component orientations in sitting and standing positions: measurements reproducibility with eos imaging system versus conventional radiographies. *Orthop Traumatol: Surg Res* 97(4):373–380
30. Leardini A, Chiari L, Croce UD, Cappozzo A (2005) Human movement analysis using stereophotogrammetry-part 3: soft tissue artifact assessment and compensation. *Gait Posture* 21:212–225
31. Learmonth I, Young C, Rorabeck C (2007) The operation of the century: total hip replacement. *Lancet* 370(9597):1508–1519
32. Lembeck B, Mueller O, Reize P, Wuelker N (2005) Pelvic tilt makes acetabular cup navigation inaccurate. *Acta Orthop* 76(4):517–523
33. Lewinnek G, Lewis J, Tarr R, Compere C, Zimmerman J (1978) Dislocations after total hip-replacement arthroplasties. *J Bone Joint Surg* 60(2):217–220
34. Malik A, Maheshwari A, Dorr LD (2007) Impingement with total hip replacement. *J Bone Joint Surg* 89(8):1832–1842
35. Maloney WJ, Keeney JA (2004) Leg length discrepancy after total hip arthroplasty. *J Arthroplasty* 19(4):108–110
36. Manzotti A, Cerveri P, De Momi E, Pullen C, Confalonieri N (2011) Does computer-assisted surgery benefit leg length restoration in total hip replacement? Navigation versus conventional freehand. *Int Orthop* 35(1):19–24
37. Mattei L, Di Puccio F, Piccigallo B, Ciulli E (2011) Lubrication and wear modelling of artificial hip joints: a review. *Tribol Int* 44(5):532–549
38. Minoda Y, Kadowaki T, Kim M (2006) Acetabular component orientation in 834 total hip arthroplasties using a manual technique. *Clin Orthop Relat Res* 445:186–191
39. Murray D (1993) The definition and measurement of acetabular orientation. *J Bone Joint Surg* 75(2):228–232
40. Nadzadi M, Pedersen D, Yack H, Callaghan J, Brown T (2003) Kinematics, kinetics, and finite element analysis of commonplace maneuvers at risk for total hip dislocation. *J Biomech* 36(4):577–591
41. Nam D, Sculco PK, Abdel MP, Alexiades MM, Figgie MP, Mayman DJ (2013) Leg-length inequalities following THA based on surgical technique. *Orthopedics* 36(4):e395–400
42. Nunley RM, Ellison BS, Zhu J, Ruh EL, Howell SM, Barrack RL (2012) Do patient-specific guides improve coronal alignment in total knee arthroplasty? *Clin Orthop Relat Res* 470(3):895–902
43. Otomaru I, Kobayashi K, Okada T, Nakamoto M, Kagiya Y, Takao M, Sugano N, Tada Y, Sato Y (2009) Expertise modelling for automated planning of acetabular cup in total hip arthroplasty using combined bone and implant statistical atlases. In: *Proceedings of MICCAI*, vol LNCS 5761. Springer, pp 532–539
44. Parratte S, Pagnano M, Coleman-Wood K, Kaufman K, Berry D (2009) The 2008 Frank Stinchfield award: variation in postoperative pelvic tilt may confound the accuracy of hip navigation systems. *Clin Orthop Relat Res* 467(1):43–49
45. Pedersen D, Callaghan J, Brown T (2005) Activity-dependence of the “safe zone” for impingement versus dislocation avoidance. *Med Eng Phys* 27(4):323–328
46. Peter R, Lübbeke A, Stern R, Hoffmeyer P (2011) Cup size and risk of dislocation after primary total hip arthroplasty. *J Arthroplasty* 26(8):1305–1309
47. Petrella A, Stowe J, DLima D, Rullkoetter P, Laz P (2009) Computer-assisted versus manual alignment in THA: a probabilistic approach to range of motion. *Clin Orthop Relat Res* 467(1):50–55
48. Philippot R, Wegrzyn J, Farizon F, Fessy MH (2009) Pelvic balance in sagittal and lewinnek reference planes in the standing, supine and sitting positions. *J Orthop Traumatol Surg Res* 95(1):70–76
49. Rathnayaka K, Sahama T, Schuetz MA, Schmutz B (2011) Effects of CT image segmentation methods on the accuracy of long bone 3D reconstructions. *Med Eng Phys* 33(2):226–233
50. Sanchez-Sotelo J, Haidukewych G, Boberg C (2006) Hospital cost of dislocation after primary total hip arthroplasty. *J Bone Joint Surg* 88(2):290–294
51. Schmid J, Kim J, Magnenat-Thalmann N (2011) Robust statistical shape models for MRI bone segmentation in presence of small field of view. *Med Image Anal* 15:155–168
52. Shaarani S, McHugh G, Collins D (2013) Accuracy of digital preoperative templating in 100 consecutive uncemented total hip arthroplasties: a single surgeon series. *J Arthroplasty* 28(2):331–337
53. Stewart K, Pedersen D, Callaghan J, Brown T (2004) Implementing capsule representation in a total hip dislocation finite element model. *Iowa Orthop J* 24:1
54. Turley G, Williams M, Wellings R, Griffin D (2013) Evaluation of range of motion restriction within the hip joint. *Med Biol Eng Comput* 51(4):467–477
55. Tyrakowski M, Wojtera-Tyrakowska D, Siemionow K (2014) Influence of pelvic rotation on pelvic incidence, pelvic tilt, and sacral slope. *Spine* 39(21):E1276–E1283
56. Wixson R (2007) Computer-assisted total hip navigation. *Instr Course Lect* 57:707–720
57. Wixson R, MacDonald M (2005) Total hip arthroplasty through a minimal posterior approach using imageless computer-assisted hip navigation. *J Arthroplasty* 20(3):51–56
58. Wolf A, DiGioia AI, Mor A, Jaramaz B (2005) Cup alignment error model for total hip arthroplasty. *Clin Orthop Relat Res* 437:132–137
59. Wu G, Siegler S, Allard P, Kirtley C, Leardini A, Rosenbaum D, Whittle M, D’Lima D, Cristofolini L, Witte H, Schmid O, Strokes I (2002) ISB recommendation on definitions of joint coordinate system of various joints for the reporting of human joint motion - part I: Ankle, hip and spine. *J Biomech* 35(4):543–548