

Shoulder Instability After Total Shoulder Arthroplasty: a Case of Arthroscopic Repair

Albert O. Gee, MD · Michael E. Angeline, MD · Joshua S. Dines, MD · David M. Dines, MD

Received: 28 August 2013/Accepted: 25 October 2013 /Published online: 12 December 2013
© Hospital for Special Surgery 2013

Keywords total shoulder arthroplasty · posterior instability · shoulder arthroscopy · arthroscopic stabilization · shoulder pain · shoulder instability

Case Report

Introduction

Arthroscopy has become a mainstay of minimally invasive orthopedic surgery. A host of intra-articular and periarticular lesions can now be safely and effectively addressed using arthroscopic techniques in both native and prosthetic joints. Although not common, arthroscopy after total shoulder arthroplasty (TSA) can be a valuable tool in addressing postoperative issues including instability, infection, component loosening, and pain. We describe a case of atraumatic posterior instability after a TSA, which was addressed arthroscopically, and then review indications for arthroscopic management of the painful total shoulder.

A 74-year-old male underwent an uncomplicated anatomic total shoulder arthroplasty for primary osteoarthritis of his right dominant shoulder. At index surgery, there was minimal posterior glenoid wear, which required less than 3 mm of eccentric reaming. After 3 years of uneventful follow-up and excellent function and pain relief, the patient developed recurrent posterior instability without a traumatic etiology. The patient could not recall a specific mechanism to correlate with the onset of his instability and presented to the office within 1 week after the first instability event. He had several subsequent dislocations, which required closed reduction under sedation. Physical examination of his right shoulder revealed full range of motion with forward flexion to 170°, adducted external rotation to 50°, and internal rotation to L2. On manual muscle testing, the patient had 5/5 strength with resisted supraspinatus and external rotation testing. The patient additionally had a negative belly press test and a negative lift-off test. In the supine position, the patient had a positive apprehension test with flexion–adduction and showed significant laxity with posterior load and shift testing. The patient had no evidence of elbow hyperextension and had a negative thumb to forearm test bilaterally. The patient had a 1+ sulcus sign, which was equal and symmetric to the contralateral left side. On the left shoulder, the patient had full range of motion with forward flexion to 170°, adducted external rotation to 60°, and internal rotation to L2. On manual muscle testing, the patient had 5/5 strength with resisted supraspinatus and external rotation testing. The patient had a negative belly press test and a negative lift-off test. The patient had a negative anterior and posterior instability examination on the left shoulder.

Radiographic evaluation with a computed tomography (CT) scan revealed neutral glenoid component version and the humeral component retroversion was noted to be 20°. There was no evidence of component loosening. Serum inflammatory markers were all within normal limits and

Electronic supplementary material The online version of this article (doi:10.1007/s11420-013-9373-5) contains supplementary material, which is available to authorized users.

A. O. Gee, MD
Department of Orthopedics and Sports Medicine,
University of Washington,
Hec Edmundson Pavilion, 3950 Montlake Blvd NE, Room 148,
Seattle, WA 98195, USA

M. E. Angeline, MD (✉)
Mercy Health System,
3524 E Milwaukee St,
Janesville, WI 53546, USA
e-mail: angelimi@gmail.com

J. S. Dines, MD · D. M. Dines, MD
Hospital for Special Surgery,
535 East 70th Street,
New York, NY 10021, USA

two shoulder joint aspirations were negative for any sign of an infectious etiology.

Initial treatment consisted of physical therapy and rehabilitation with emphasis on anterior deltoid, trapezial, rhomboid, serratus anterior, levator scapulae, and rotator cuff strengthening. Despite 3 months of physical therapy, the patient continued to have pain and symptoms of instability. As there was no roentgenographic or imaging evidence of component malalignment or loosening causing the patient's instability, arthroscopic surgery was recommended for the purposes of exploration and posterior capsulorrhaphy with the possibility that an open stabilization may be required, depending on the quality of the posterior capsular tissue and other abnormal findings noted at the time of arthroscopy.

Arthroscopic posterior capsulorrhaphy was recommended to the patient to address the recurrent dislocations after 3 months from the initial presentation. Surgery was performed with the patient in the beach chair position. General anesthesia supplemented with a supraclavicular regional nerve block was utilized. The examination under anesthesia revealed full range of motion with forward flexion to 170°, adducted external rotation to 60°, abducted external rotation to 60°, and abducted internal rotation to 40°. The patient had a +1 sulcus sign and noted grade 3 posterior shoulder laxity, the humeral head translated over the rim and locked out posteriorly. The patient had grade 1 laxity in the anteroinferior direction.

Diagnostic arthroscopy revealed a patulous posterior capsule with a preserved but degenerative posterior labrum. Cultures and synovial biopsy specimens were taken and sent for microbiology and pathology to rule out infection. The remainder of the diagnostic arthroscopy revealed no other abnormality. The rotator cuff was intact, and there was no evidence of glenoid component loosening, synovitis, or loose bodies present.

A posterior capsular imbrication was then performed using two suture anchors. The anchors were placed at the 7 o'clock and 9 o'clock positions just off the posterior margin of the glenoid component percutaneously. A cannula was placed through the original posterior portal incision, and the sutures were passed through the capsule using a curved arthroscopic suture passing device and then tied in simple interrupted configuration.

The patient was kept in an abduction brace in external rotation at the side for 6 weeks to allow healing. During that time frame, the patient was allowed free distal elbow, wrist, and forearm motion. He was otherwise instructed to remain in the sling. Gradual range of motion therapy and rotator cuff strengthening exercises were initiated and advanced over the next 6 weeks. The patient was allowed to return to normal activities at 3 months. At 24-month follow-up, the patient had 140° of forward flexion, 45° of external rotation, and IR behind the back to L3 level with no further symptoms of instability or pain. On manual muscle testing, the patient had 5/5 strength with resisted supraspinatus and external rotation testing compared to the contralateral uninjured side. The patient additionally had a negative belly press test and a negative lift-off test. Follow-up radiographs demonstrated no further evidence of posterior instability or component

malpositioning. The patient additionally had a Simple Shoulder Test (SST) score of 10 and a modified American Shoulder and Elbow Surgeons (ASES) score of 83 at 24-month follow-up.

Discussion

Total shoulder arthroplasty is effective in relieving pain and restoring function to patients with degenerative shoulder conditions. Like all arthroplasties, however, TSA is not without complications. Studies have shown complication rates after total shoulder arthroplasty ranging from 0% to 62% in some series [8, 19]. As outlined by this case report, instability is a potential factor that can account for pain and disability after a TSA. The instability can either be anterior or posterior. The causes of anterior instability are often multifactorial and relate to humeral implant malrotation, abnormal capsular tensioning, deltoid dysfunction, or subscapularis failure. Recognition of the underlying cause is critical for successful treatment [14, 18]. Posterior instability is thought to be caused by excessive retroversion of either component, posterior glenoid wear or posterior capsulotomy. The clinician should utilize the patient's history and physical examination findings along with a full radiographic evaluation as previously described in order to determine the true etiology of instability. In the setting of anterior instability or component malpositioning, open revision or conversion to a reverse TSA is typically necessary. When the patient presents with posterior instability, implant positioning errors must be ruled out first. With an isolated posterior soft tissue imbalance as noted in this case, arthroscopy can be utilized as a tool to selectively tighten the posterior capsule as described. In addition, arthroscopy can be utilized when patients present with potential stiffness, capsular fibrosis, or synovitis after an arthroplasty [8, 17].

Besides instability, the patient presenting with pain after a total shoulder arthroplasty may have an infection, a component-related failure, soft tissue or bone-related pathology, or stiffness/synovitis. Our approach to evaluation of a painful TSA is based on these four previously noted categories, and when the standard investigative methods fail to identify a source of pain in these patients, shoulder arthroscopy may be considered. Arthroscopy allows the surgeon to directly visualize and evaluate the intra-articular and extra-articular portions of the shoulder and address a number of pathologic conditions after shoulder arthroplasty [3, 6, 8, 11–13, 16, 17]. Our proposed algorithm for the approach to delineation of the potential causes of pain after a total shoulder arthroplasty and the role for utilizing arthroscopy in this setting are outlined in Fig. 1.

Infection should always be a consideration in the painful total shoulder. Patients with a septic shoulder arthroplasty may present with stiffness or instability. Evaluation should begin with serum inflammatory markers such as C-reactive protein, erythrocyte sedimentation rate and white blood cell count, and possibly an aspiration of the glenohumeral joint with fluid analysis sent for cell count, gram stain, and culture including aerobic, anaerobic, and fungal. A recent

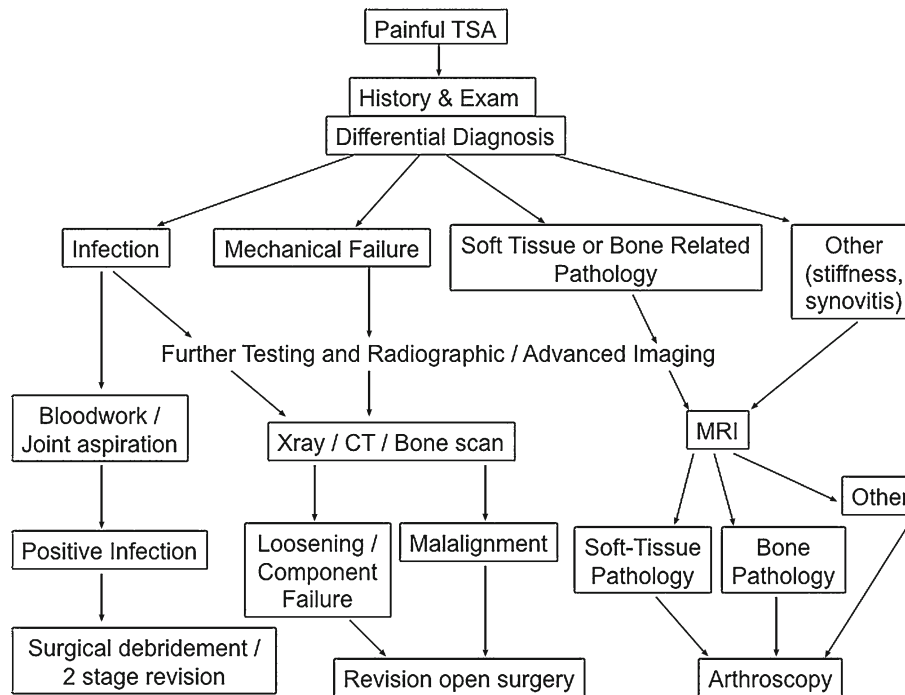


Fig. 1. Our algorithm to help define the potential causes of pain after a total shoulder arthroplasty and the role for utilizing arthroscopy in this setting.

retrospective review by Singh et al. [15] noted that the infection-free survival rate in TSA patients at 20-year follow-up was 97%. *Propionibacterium acnes* (*P. acnes*) was recognized as the most common causative organism. Male gender, younger age, and longer operating room (OR) times were associated with an increased risk for deep infections after TSA. A *P. acnes* infection often will not necessarily present with elevated inflammatory markers and may have negative aspirate cultures [5]. It is additionally important to note that culture specimens for suspected shoulder infections should be held for at least 14 days due to the slow-growing nature of *P. acnes*. Recent work has also noted that patients presenting with “aseptic loosening” without any noted signs of infection had a high percentage of cultures positive for *P. acnes* [5, 9]. Arthroscopy can be used if an infection is suspected but not definitively proven in order to obtain soft tissue samples for microbial culture and histological examination to improve the diagnostic accuracy.

Mechanical failure specifically relating to loosening or malalignment of the components can also cause pain after a TSA. Radiographic evaluation including plain radiographs or a CT scan can help define if there is any evidence of component loosening or malalignment. In the setting of loosening or malalignment of the humeral component, open revision arthroplasty is typically necessary. When a loose glenoid component is noted, however, arthroscopy can be utilized to obtain tissue samples to evaluate for an infection and help assist with the removal of the glenoid component itself [3, 10–13]. Several authors have described an arthroscopically assisted approach for the conversion of a total shoulder arthroplasty to a hemiarthroplasty in the setting of a loose glenoid component. O’Driscoll et al. [12]

published their experience using an arthroscopic-assisted technique to excise a loose keeled glenoid component using a series of glenoid cuts in an ordered fashion using an osteotome in order to remove the polyethylene in a piecemeal fashion. Namdari and Glaser [11] described their technique to perform an arthroscopic-assisted glenoid resection and also were able to bone graft the glenoid through the same approach. Raphael et al. [13] used arthroscopic techniques to remove a subset of loose glenoids in patients who had painful TSA and showed that these patients had similar outcomes to those who had open surgery. Bone-related and soft tissue pathologies are also potential sources of pain after a TSA. This can include painful subacromial impingement, biceps tendon lesions, capsular contractures, rotator cuff tears, and humeral head instability. Subacromial impingement was found to be a source of pain after total shoulder arthroplasty or hemiarthroplasty in 3% of patients (6 of 203) in a series reported by Freedman et al. [6]. Arthroscopic subacromial decompression and acromioplasty resulted in improvements in pain scores, function, and patient satisfaction in five of six patients. At an average of 5.3 years after a TSA, the prevalence of rotator cuff tears was noted to be 1.3% [2]. Looking at moderate-to-long-term follow-up, a recent multicenter retrospective study by Young et al. [20] noted that the average rate of secondary rotator cuff dysfunction was 16.8% at 103.6 months after a TSA. These findings highlight the long-term soft tissue-related changes that occur following arthroplasty and the potential effects on patient outcomes [4]. Given the potential development of a rotator cuff tear after shoulder arthroplasty, arthroscopy can be utilized as a means for treatment and potential repair. The clinician should proceed with caution, however, as the risk

of failure is high in this setting due to the chronic attritional nature of the tears and the poor healing response in the setting of an arthroplasty [1, 7].

Arthroscopy after total shoulder arthroplasty is an important tool in the armamentarium of the shoulder surgeon. It has a unique ability to address soft tissue problems around a TSA using minimally invasive techniques and carries a low complication rate. Rotator cuff tears, arthrofibrosis, subacromial impingement, AC joint degeneration, and recurrent posterior instability can be significant sources of pain and poor outcomes after TSA which can be addressed with arthroscopic techniques. It may also be useful in the diagnosis and treatment of the painful TSA in infection and other cases without a clear reason for pain despite thorough evaluation.

This case demonstrates a clear indication for the usefulness of diagnostic and therapeutic arthroscopy in this particular situation of soft tissue instability complicating a previously successful total shoulder arthroplasty with excellent result.

Disclosures

Conflict of Interest: Albert O. Gee, MD and Michael E. Angelina, MD have declared that they have no conflict of interest. David Dines, MD receives royalties from Biomet; is a board member of American Shoulder and Elbow Surgeons; other from *Journal of Shoulder and Elbow Surgery* and Saunders/Mosby-Elsevier; outside the submitted work. Joshua Dines, MD reports royalties from Biomet; grants from Biomimetic; paid consultant for Biomimetic, CONMED Linvatec and Tornier; board member of *American Journal of Orthopedics* and *Journal of Shoulder and Elbow Surgery*; other from *Journal of Shoulder and Elbow Surgery*; outside the submitted work.

Human/Animal Rights: All procedures followed were in accordance with the ethical standards of the responsible committee on human experimentation (institutional and national) and with the Helsinki Declaration of 1975, as revised in 2008 (5).

Informed Consent: Informed consent was waived from all patients for being included in the study.

Required Author Forms Disclosure forms provided by the authors are available with the online version of this article.

References

- Blalock R, Galatz LM. Rotator cuff tears after arthroplasty. *Semin Arthroplas.* 2012; 23(2): 114-117. doi:10.1053/j.sart.2012.03.011.
- Bohsali KI, Wirth MA, Rockwood CA Jr. Complications of total shoulder arthroplasty. *J Bone Joint Surg Am.* 2006; 88(10): 2279-2292. doi:10.2106/JBJS.F.00125.
- Bonutti PM, Hawkins RJ, Saddemi S. Arthroscopic assessment of glenoid component loosening after total shoulder arthroplasty. *Arthroscopy.* 1993; 9(3): 272-276.
- Dines D. Late-onset rotator cuff dysfunction after total shoulder arthroplasty—the “forgotten” complication. Commentary on an article by Allan A. Young, MD, et al.: “Secondary rotator cuff dysfunction following total shoulder arthroplasty for primary glenohumeral osteoarthritis: results of a multicenter study with more than five years of follow-up”. *J Bone Joint Surg Am.* 2012; 94(8): e53.
- Dodson CC, Craig EV, Cordasco FA, et al. *Propionibacterium acnes* infection after shoulder arthroplasty: a diagnostic challenge. *J Shoulder Elbow Surg.* 2010; 19(2): 303-307. doi:10.1016/j.jse.2009.07.065.
- Freedman KB, Williams GR, Iannotti JP. Impingement syndrome following total shoulder arthroplasty and humeral hemiarthroplasty: treatment with arthroscopic acromioplasty. *Arthroscopy.* 1998; 14(7): 665-670.
- Hattrup SJ, Cofield RH, Cha SS. Rotator cuff repair after shoulder replacement. *J Shoulder Elbow Surg.* 2006; 15(1): 78-83. doi:10.1016/j.jse.2005.06.002.
- Hersch JC, Dines DM. Arthroscopy for failed shoulder arthroplasty. *Arthroscopy.* 2000; 16(6): 606-612.
- Levy O, Iyer S, Atoun E, et al. *Propionibacterium acnes*: an underestimated etiology in the pathogenesis of osteoarthritis? *J Shoulder Elbow Surg.* 2012. doi:10.1016/j.jse.2012.07.007.
- Moen TC, Bigliani LU. Arthroscopic removal of a displaced glenoid component after total shoulder arthroplasty: case report, surgical technique, and pearls. *Tech Orthop.* 2012; 27(3): 229-234. doi:10.1097/BTO.0b013e318255e386.
- Namdari S, Glaser D. Arthroscopically assisted conversion of total shoulder arthroplasty to hemiarthroplasty with glenoid bone grafting. *Orthopedics.* 2011; 34(11): 862-865. doi:10.3928/01477447-20110922-19.
- O'Driscoll SW, Petrie RS, Torchia ME. Arthroscopic removal of the glenoid component for failed total shoulder arthroplasty. A report of five cases. *J Bone Joint Surg Am.* 2005; 87(4): 858-863. doi:10.2106/JBJS.C.01732.
- Raphael BS, Dines JS, Warren RF, et al. Symptomatic glenoid loosening complicating total shoulder arthroplasty. *HSS J.* 2010; 6(1): 52-56. doi:10.1007/s11420-009-9148-1.
- Sanchez-Sotelo J, Sperling JW, Rowland CM, et al. Instability after shoulder arthroplasty: results of surgical treatment. *J Bone Joint Surg Am.* 2003; 85-A(4): 622-631.
- Singh JA, Sperling JW, Schleck C, et al. Periprosthetic infections after total shoulder arthroplasty: a 33-year perspective. *J Shoulder Elbow Surg.* 2012; 21(11): 1534-1541. doi:10.1016/j.jse.2012.01.006.
- Tuckman DV, Dines DM. Long head of the biceps pathology as a cause of anterior shoulder pain after shoulder arthroplasty. *J Shoulder Elbow Surg.* 2006; 15(4): 415-418. doi:10.1016/j.jse.2005.09.004.
- Tytherleigh-Strong GM, Levy O, Sforza G, et al. The role of arthroscopy for the problem shoulder arthroplasty. *J Shoulder Elbow Surg.* 2002; 11(3): 230-234. doi:10.1067/mse.2002.122257.
- Warren RF, Coleman SH, Dines JS. Instability after arthroplasty: the shoulder. *J Arthroplasty.* 2002; 17(4 Suppl 1): 28-31. doi:10.1054/arth.2002.32543.
- Wirth MA, Rockwood CA Jr. Complications of total shoulder-replacement arthroplasty. *J Bone Joint Surg Am.* 1996; 78(4): 603-616.
- Young AA, Walch G, Pape G, et al. Secondary rotator cuff dysfunction following total shoulder arthroplasty for primary glenohumeral osteoarthritis: results of a multicenter study with more than five years of follow-up. *J Bone Joint Surg Am.* 2012; 94(8): 685-693. doi:10.2106/JBJS.J.00727.