

# Structural and Histochemical Changes in Neurons in the Frontal Cortex of the Brain in Rats with Cholestasis

S. V. Emel'yanchik<sup>1</sup> and S. M. Zimatkin<sup>2</sup>

UDC 611.813.1.018:616.36-008.811.6:599.323.4

*Translated from Morfologiya, Vol. 153, No. 1, pp. 7–12, January–February, 2018. Original article submitted June 10, 2017. Revised version received September 16, 2017.*

**Objectives.** To study structural and histochemical changes in neurons in the frontal cortex of the brain in rats after ligation of the common bile duct. **Materials and methods.** The cortex of the frontal lobe was studied in 72 mongrel adult white male rats weighing  $200 \pm 25$  g. Ligation of the common bile duct and development of cholestasis (experimental group) and sham surgery (control group) was followed by histological and histochemical studies of microstructural changes in pyramidal neurons in all layers of the frontal cortex on days 2, 5, 10, 20, 45, and 90. **Results.** Ligation of the common bile duct in rats producing cholestasis led to profound histological and histochemical changes in neurons in the frontal cortex of the brain: changes in size and shape, and appearance of hyperchromic shrunken neurons and ghost cells. Impairments to energy and plastic metabolism in neurons led to the death of the experimental animals. The consequences of cholestasis in the brains of rats were apparent on days 2–5 and reached a maximum on days 10–20. In the later post-operative period (45–90 days), groups of survivors showed gradual reductions in these changes, though the consequences of cholestasis consisted of foci of neuron loss in all layers of the frontal cortex. **Conclusions.** It is suggested that survival of rats after ligation of the common bile duct is due to formation of bypass bile ducts, with elimination of cholestasis and the high adaptive potential of neurons.

**Keywords:** cerebral cortex, frontal cortex, pyramidal neurons, microstructural changes, cholestasis.

Gallstone disease is common in modern society [12]. This pathology is often linked with impairments to bile outflow, leading to stasis in the biliary system (cholestasis), preventing it from reaching the duodenum and accumulation of bile components in the blood [1]; impairments to digestion and food absorption (especially fats) develop, and body weight decreases, as does the uptake of fat-soluble vitamins A, D, E, and K, and also calcium. Lipid peroxidation processes in the organs are impaired and membrane viscosity and  $\text{Na}^+/\text{K}^+$ -ATPase activity change [7]. Functional and structural changes are seen in many body organs and systems in cholestasis, these including the central nervous system. There is weakening of analytical/synthetic activity of

the cortex; process of cortical arousal and inhibition are deranged, and neurasthenia, encephalopathy, and encephalomyelopathy develop; symptoms of diffuse brain injury are seen [6, 13]. These processes are linked with increases in blood bilirubin and bile acids levels, leading to damage to the blood-brain barrier and penetration of these compounds into brain tissue [8].

The literature contains only a few histological studies of the brain in cholestasis. Thus, the CNS in humans dying from mechanical jaundice shows diffuse toxic-hypoxic changes to neurons and neuroglial cells, and also to brain vessels. Neurons in the brain show swelling, local and total chromatolysis, these occurring in combination with hyperchromia and perinuclear hydropic dystrophy [4]. Experiments in rats showed that starting from day 5 after ligation of the common bile duct (CBD), animals showed cerebral edema in the perivascular and pericellular areas, with increases in the number of microglial cells in essentially all parts of the brain [11]. Other authors noted that on day 15 af-

<sup>1</sup> Department of Zoology and Human and Animal Physiology, Grodno State University, Grodno, Republic of Belarus; e-mail: semel@grsu.by.

<sup>2</sup> Department of Histology, Cytology, and Embryology, Grodno State Medical University, Grodno, Republic of Belarus; e-mail: smzimatkin@mail.ru.

ter ligation of the CBD, mice showed severe cerebral edema associated with impaired permeability of blood vessel walls [10]. In experimental cholestasis, the bodies of neurons in the brain in dogs showed simple atrophy of nerve cells, with nuclear pyknosis and formation of a reticular structure to the cytoplasm [9]. Our previous studies showed that rats examined 20 days after ligation of the CBD displayed increases in structural and cytochemical impairments in cerebellar Purkinje cells, leading to severe and irreversible changes to neurons, reaching the level of death. Hyperchromic, shrunken neurons were seen; nerve cells showed signs of organelle destruction, especially affecting mitochondria, and the numbers and sizes of mitochondria were increased. At the later post-operative time points (45–90 days), cerebellar Purkinje cells in surviving animals showed gradual normalization of structure and metabolism [2]. We have previously seen similar changes in histaminergic neurons in the rat hypothalamus in cholestasis [3].

The aim of the present work was to study structural and histochemical changes in neurons in the frontal cortex of the rat brain during the course of subhepatic cholestasis.

**Materials and Methods.** Studies used materials from 72 mongrel white male rats weighing  $200 \pm 25$  g. Animals were kept in standard animal-house conditions. The study was approved by the Ethics Committee of Grodno State Medical University (protocol No. 3 of November 8, 2016). Ligation of the CBD 3–5 mm below the junction of the lobar ducts was performed using two ligatures followed by transection between them. Animals of the control group underwent sham operations. On days 2, 5, 10, 20, 45, and 90 after surgery, in the morning (for time synchronization), animals were anesthetized with ether vapor and then euthanased in compliance with the “Regulations for studies using experimental animals” and the Helsinki Declaration (1975) and its 2000 update. Brains were rapidly extracted and fragments of frontal lobe (4.20–1.80 mm from the bregma, stereotaxic atlas of the rat brain [14]) of the right hemisphere of size 5–7 mm were fixed in Carnoy's fluid (for histological studies). Fragments of left hemisphere frontal lobe of the same size were frozen and stored in liquid nitrogen (for subsequent histoenzymatic investigations).

Frontal paraffin sections of the cortex of thickness  $7 \mu\text{m}$  were prepared on a LeicaRM 2125 RTS microtome (Leica, Germany). Brain tissue microstructural components were detected using hematoxylin and eosin, as well as Nissl thionine. Dead neurons were identified by the Victorov method [16]; histochemical analysis of RNA content was by the Einarsson method [5]. Frontal cryostat sections of the cortex of thickness  $10 \mu\text{m}$  were made on a Leica CM 1840 cryostat (Leica, Germany). Sections were treated using standard histochemical methods to detect enzyme activities: enzymes linked with the Krebs cycle – succinate dehydrogenase (SDH, E.C. 1.3.99.1); enzymes linked with the pentose phosphate system – glucose-6-phosphate dehydrogenase (G6PDH; E.C. 1.1.1.49); enzymes linked with electron

transport – reduced NAD dehydrogenase (NADH-DH; E.C. 1.6.99.3); and enzymes linked with glycolysis – lactate dehydrogenase (LDH; E.C. 1.1.1.27). Acid phosphatase (AP, E.C. 3.1.3.2), a marker enzyme for lysosomes, was detected on sections fixed with 10% neutral formalin and processed as described by Gomori [5].

Visual assessment, microphotography, and morphometry of histological and histochemical sections were performed using an Axioscop 2 Plus light microscope with an Axio Cam MR c5 digital video camera (Karl Zeiss, Germany), and image analysis was with Image Warp (Bit Flow, USA). Preparations stained by the Nissl method were assessed by randomly selecting 10 fields of view in areas of  $1 \text{ mm}^2$  and counting the total number of neurons, including normochromic, hypochromic, hyperchromic non-shrunken, hyperchromic shrunken, and ghost cells, as well as the number of glial cells. Assessment of neuron body size and shape on Nissl-stained preparations was performed by measuring their smallest and largest diameters, perimeters, areas, form factors, and elongation factors. Totals of 120–200 neurons were examined in each experimental group. Quantitative assessment of the activity of the enzymes of interest was performed by cytophotometry at the absorption peak of the colored reaction product. A total of 150–200 neurons were evaluated in each experimental group (20–30 neurons in each animal).

The causes of recovery of the structural-metabolic state of the cerebral cortex in rats in the later periods after transection of the CBD at 10, 20, and 90 days after surgery were addressed by injecting India ink with gelatin into the stump (above the ligation site) and examining the development of newly formed bypass bile ducts.

Numerical data were processed by nonparametric statistics in Statistica 10 for Windows. Differences between the control and experimental groups were regarded as significant at  $p < 0.05$  (Mann–Whitney test).

**Results.** Transection of the CBD was followed by a gradual increase in structural and histochemical changes in neurons in the frontal cortex of the rat brain. These appeared on days 2–5 of cholestasis and reached a maximum on days 10–20. Nuclei were deformed in many neurons and their nucleoli were located eccentrically. The cytoplasm showed partial lysis of chromatophilic substance, though some neurons showed hyperchromatosis. Shrunken neurons were found in all layers of the cortex. These appeared elongated, dark, and hyperchromic. The apical dendrites of pyramidal neurons sometimes acquired a corkscrew shape (Fig. 1, *a, b*). Some neurons showed cytoplasmic vacuolization. Furthermore, ghost cells with hypochromic cytoplasm and light, vesicle-like nuclei were identified, and satellitosis was seen (see Fig. 1, *c*). Specific staining using the Victorov method revealed fuchsinophilic dying neurons in all layers in the frontal cortex.

At 10 days of cholestasis, the number of normochromic neurons in layer III of the frontal cortex decreased by

TABLE 1. Numbers of Different Types of Neurons and Gliocytes in Layer III of the Frontal Cortex of the Rat Brain at 10 Days of Cholestasis per 1 mm<sup>2</sup> (Me ± IQR)

Parameter	Control (n = 6)	Experiment (n = 6)	p
Normochromic neurons	416.0 ± 99.2	293.3 ± 177.8*	0.042
Hypochromic neurons	9.6 ± 3.2	32.0 ± 39.2**	0.007
Hyperchromic non-shrunken neurons	6.4 ± 3.2	26.7 ± 25.0**	0.007
Hyperchromic shrunken neurons	3.2 ± 3.2	24.8 ± 3.8**	0.004
Ghost cells	3.2 ± 0	39.0 ± 19.7**	0.004
Total neurons	438.4 ± 89.6	415.8 ± 65.9	0.167
Glial cells	400.0 ± 54.4	455.0 ± 89.0**	0.004
Dead neurons	3.2 ± 1.6	21.3 ± 28.5**	0.002

Me – median; IQR – interquartile range. Here and in Table 2: \**p* < 0.05; \*\**p* < 0.01 compared with controls.

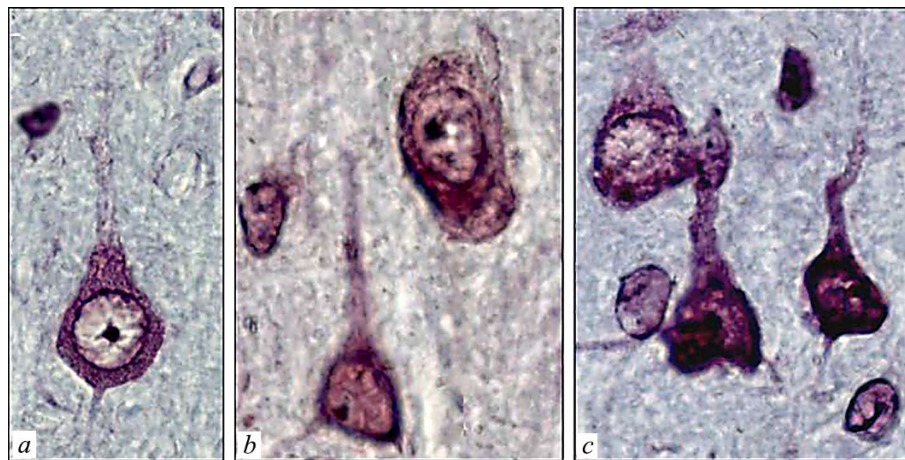

Fig. 1. Neurons in layer III of the frontal cortex of the rat brain. *a*) Control, 10 days after sham operation; *b, c*) day 10 of cholestasis (partial lysis of chromatophilic substance and hyperchromatosis). *b*) Hyperchromic shrunken neurons with corkscrewed apical dendrites; *c*) satellitosis. *a, b*) Nissl staining; *c*) stained with hematoxylin and eosin. Digital microphotography. Magnification ×800.

32.3%. This was accompanied by a 2.9-fold increase in the number of hypochromic neurons, a 2.1-fold increase in the number of hyperchromic non-shrunken neurons, a 6.1-fold increase in the number of hyperchromic shrunken neurons, and a 10.6-fold increase in the number of ghost cells as compared with the control group. The number of dead neurons assessed by the Victorov method increased 5.4-fold (Table 1). Analogous changes were seen in cortical layers II and V. By day 90, the number of damaged neurons returned to the control level, with the exception of a decrease in the total number of normochromic neurons and an increase in the number of glial cells.

The evolution of subhepatic cholestasis was linked with a change in neuron body size and shape: these decreased in all cortical layers, becoming more extended. The greatest changes were identified on days 10–20 (Table 2). On days 45 and 90, neuron body shape and size gradually normalized.

Ligation of the CBD led to a gradual decrease in enzyme activity in the neuron cytoplasm, affecting SDH, NADH-DH (Fig. 2), and G6PDH, as well as RNA content, with simultaneous increases in LDH and AP activities. These changes were maximal on days 10–20. All layers of the frontal cortex subsequently underwent partial normalization of these histochemical parameters of neurons (day 45), while by the end of the experiment (day 90) values were no different from controls (Fig. 3).

After administration of India ink with gelatin into the CBD stump on day 10 after surgery, surviving animals showed individual fine newly formed bile ducts running around the scar at the CBD transection site. These drained into the duodenum, which was filled with India ink. On day 20, these ducts became larger, and the size of the newly formed ducts by day 90 in all surviving animals approached

TABLE 2. Neuron Body Size and Shape in Layer III of the Frontal Cortex of Rat Brain at 10 Days of Cholestasis (Me  $\pm$  IQR)

Parameter		Control ( $n = 6$ )	Experiment ( $n = 6$ )	$p$
Neuron body	Area, $\mu\text{m}^2$	149.49 $\pm$ 15.59	131.92 $\pm$ 13.59**	0.003
	Elongation factor	1.18 $\pm$ 0.11	2.34 $\pm$ 1.14*	0.048
Neuron nucleus	Area, $\mu\text{m}^2$	82.19 $\pm$ 3.15	49.89 $\pm$ 8.94**	0.004
	Elongation factor	1.18 $\pm$ 0.05	1.94 $\pm$ 0.87*	0.025

the size of the normal CBD. These bypass bile ducts did not develop in animals dying from cholestasis.

**Discussion.** The data obtained here provide evidence that cholestasis is accompanied by impaired energy metabolism in neurons in the frontal cortex of the brain. The electron transport system was suppressed (NADH-DH), as were the pentose phosphate pathway (G6PDH), mitochondrial functioning (SDH), and protein biosynthesis (RNA). Compensatory activation of glycolysis (LDH) may at least partially compensate for the consequences of the impaired energy supply to neurons in cholestasis. The increased activity of the lysosome marker enzyme AP seen here provides evidence for activation of the neuronal lysosome apparatus, which is required for increased autophagy for timely removal of damaged membranes and organelles from cells. These metabolic impairments in neurons reached a peak at 10–20 days, gradually normalizing by days 45 and 90. Histological abnormalities in the neurons of interest also increased and then gradually disappeared at these same times. The dynamics of histological and histochemical changes in frontal cortex neurons in the rat brain after ligation of the CBD probably result from cholestasis, accompanied by an increase in the blood contents of toxic components of bile such as bilirubin and certain bile acids. The blood levels of these compounds reach peaks at 10–20 days after surgery, which leads to the death of more than 50% of the rats [1]. Normalization of these morphofunctional impairments at 45 and 90 days after surgery in surviving animals may be due to the timely formation of bypass bile ducts supporting outflow of bile into the duodenum. The signs of cholestasis, including jaundice and increased blood bilirubin, cholesterol, and bile acids levels, disappear, and these animals do not die in the late period after surgery [1]. It can be suggested that 20 days after CBD ligation, the only surviving animals are those succeeding in growing bypass bile ducts. The others die as a result of multiple organ failure induced by increasing cholestasis. It should be noted that in cholestasis in humans, the formation of bypass bile ducts is insufficient, and without timely surgery all die [1].

The question of the direct causes of damage to brain neurons in cholestasis remains open. It would appear that the main toxic agent in this situation is bilirubin, which crosses the blood-brain barrier [8]. The hyperbilirubinemia seen in cholestasis has been shown to induce degradation of the cytoskeleton, which may underlie the changes in neuron

body shape seen here. Shrinkage of neurons may also be due to impairment to the osmolarity of their cytoplasm and water-salt balance [15]. Cholestasis involves depolymerization of microfilaments, which leads to glutamate release, hyperarousal, and death of neurons [8, 15]. We found such areas with pathologically altered and dead neurons in the frontal cortex of the brain in animals with cholestasis.

Thus, ligation of the CBD in rats was followed by the development of profound structural and histochemical impairments, which appeared on days 2–5 of the experiment and reached maximum levels on days 10–20. These led to severe irreversible impairments to some neurons (hyperchromic shrunken neurons, ghost cells), death, and reductions in their numbers. The cytoplasm showed abnormalities in energy and plastic metabolism, with suppression of succinate, reduced NADH, NADPH, and glucose-6-phosphate dehydrogenases, and a decrease in RNA content, but activation of LDH and AP. It is possible that the morphofunctional impairments to frontal cortex neurons seen here are one of the causes of the neurological and mental symptoms occurring in patients with cholestasis. In surviving animals, forming bypass bile ducts by 20 days after CBD ligation and disappearance of cholestasis, all the parameters studied gradually normalized in surviving neurons.

### Conclusions

1. Transection of the common bile duct in rats, accompanied by cholestasis, led to severe morphofunctional changes in neurons in all layers of the frontal cortex of the brain, which was apparent on post-operative days 2–5 and reached a peak on days 10–20. This led to derangement of the size and shape, as well as energy and plastic metabolism, of neurons, which led to the death of some of them.

2. In the late period after ligation of the common bile duct (days 45–90), neuronal abnormalities in surviving animals gradually normalized, though the sequelae of cholestasis consisted of foci of lost neurons in all layers of the frontal cortex and an increased number of glial cells.

3. The cause of normalization of impairments in neurons in the cerebral cortex after this surgery in rats may be elimination of cholestasis due to the growth of bypass bile ducts and the high adaptive capacity of neurons.

*Authors' contributions.* Study concept and design, S.V.E., S.M.Z.; collection and processing of specimens: S.V.E.; statistical data processing: S.V.E.; writing: S.V.E., S.M.Z.

The authors have no conflicts of interests.




Fig 2. NADH-DH activity in neurons in layer V of the frontal cortex of the rat brain in controls. *a*) Day 10 after sham operation; *b*) day 10 of cholestasis. Stained by Nakhlas, Walker, Zeligman method. Digital microphotography. Magnification  $\times 400$ .

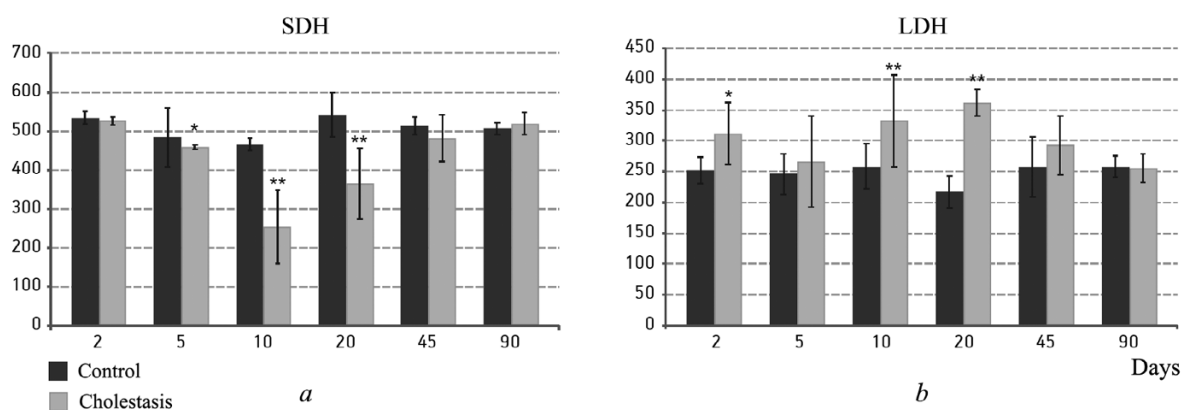


Fig. 3. Changes in succinate dehydrogenase (SDH) and lactate dehydrogenase (LDH) activities in neurons in layer V of the frontal cortex of the rat brain. The abscissas show times (in days) after ligation of the common bile duct; the ordinates show optical density units  $\times 1000$ . Columns show medians and vertical bars show interquartile ranges. \* $p < 0.05$ ; \*\* $p < 0.01$  (significant differences compared with controls).

## REFERENCES

1. S. V. Emel'yanchik and S. M. Zimatkin, *The Brain in Cholestasis*, Grodno State University, Grodno (2011).
2. S. V. Emel'yanchik and S. M. Zimatkin, "Structural and histochemical changes in cerebellar Purkinje cells in cholestasis," *Morfologiya*, **143**, No. 2, 19–23 (2013).
3. S. M. Zimatkin, O. V. Baraban, and S. V. Emel'yanchik, "Metabolic changes in rat brain histaminergic neurons during subhepatic cholestasis," *Morfologiya*, **132**, No. 4, 27–30 (2007).
4. Yu. S. Martynov, E. V. Malkova, and V. V. Proskurin, "Cholestatic toxic-vascular encephalopathy and encephalomyelopathy," *Zh. Nevrol. Psikhiat.*, **87**, No. 11, 1640–1646 (1987).
5. E. Pearse, *Histochemistry, Theoretical and Applied* [Russian translation], Foreign Literature Press, Moscow (1962).
6. S. V. Chepur, *Morphofunctional Characteristics of the Structure of the Nervous System in Health and Patterns of Changes in Hepatic Encephalopathy: Author's Abstract of Doctoral Thesis in Medical Sciences*, St. Petersburg State Pediatric Medical Academy, St. Petersburg (2003).
7. S. Sherlock and J. Dooley, *Diseases of the Liver and Biliary System*, GEOTAR Meditsina, MV (1999).
8. M. A. Brito, I. Palmela, F. L. Cardoso, et al, "Blood-brain barrier and bilirubin: clinical aspects and experimental data," *Arch. Med. Res.*, **45**, No. 8, 660–676 (2014).
9. Y. Furukawa, "Histological changes in the brain due to experimental obstructive jaundice," *Nihon Geka Gakkai Zasshi*, **92**, No. 1, 37–45 (1991).
10. O. H. Juarez, "Hepatic anatomopathologic injuries by extrahepatic biliary tract obstruction in mice," *Rev. Gastroenterol. Mex.*, **73**, No. 1, 17–20 (2008).
11. L. A. Kikalishvili, "Morphological changes in brain and heart after the temporary liver exclusion from the bloodstream during the cholestasis," *Georgian Med. News*, No. 167, 77–81 (2009).
12. F. M. Konikoff, "Gallstones – approach to medical management," *Med. Gen. Med.*, **5**, No. 4, 8 (2003).
13. R. Leke, D. L. Oliveira, and L. F. Forgiarini, et al., "Impairment of short term memory in rats with hepatic encephalopathy due to bile duct ligation," *Metab. Brain Dis.*, **28**, No. 2, 187–192 (2013).
14. G. Paxinos and C. Watson, *The Rat Brain in Stereotaxic Coordinates*, Academic Press, London, (2007), 6th ed.
15. P. A. Schwarzkroin, S. C. Baraban, and D. W. Hochman, "Osmolarity, ionic flux, and changes in brain excitability," *Epilepsy Res.*, **32**, No. 1–2, 275–285 (1998).
16. I. V. Victorov, K. Prass, and U. Dirnagl, "Improved selective, simple, and contrast staining of acidophilic neurons with vanadium acid fuchsin," *Brain Res. Protoc.*, **5**, No. 2, 135–139 (2000).