

Corneal Collagen Cross-Linking for the Management of Mycotic Keratitis

Elif Erdem · Ibrahim Inan Harbiyeli  · Hazal Boral · Macit Ilkit · Meltem Yagmur · Reha Ersoz

Received: 16 December 2017 / Accepted: 2 February 2018 / Published online: 16 February 2018
© Springer Science+Business Media B.V., part of Springer Nature 2018

Abstract

Purpose To evaluate the efficiency of corneal collagen cross-linking (CXL) in addition to topical voriconazole in cases with mycotic keratitis.

Design Retrospective case series in a tertiary university hospital.

Participants CXL was performed on 13 patients with mycotic keratitis who presented poor or no response to topical voriconazole treatment.

Methods The clinical features, symptoms, treatment results and complications were recorded retrospectively. The corneal infection was graded according to the depth of infection into the stroma (from grade 1 to

grade 3). The visual analogue scale was used to calculate the pain score before and 2 days after surgery.

Main Outcome Measures Grade of the corneal infection.

Results Mean age of 13 patients (6 female and 7 male) was 42.4 ± 17.7 years (20–74 years). Fungus was demonstrated in culture (eight patients) or cytological examination (five patients). Seven of the 13 patients (54%) were healed with topical voriconazole and CXL adjuvant treatment in 26 ± 10 days (15–40 days). The remaining six patients did not respond to CXL treatment; they initially presented with higher grade ulcers. Pre- and post-operative pain score values were 8 ± 0.8 and 3.5 ± 1 , respectively ($p < 0.05$).

Conclusions The current study suggests that adjunctive CXL treatment is effective in patients with small and superficial mycotic ulcers. These observations require further research by large randomized clinical trials.

Keywords Corneal collagen cross-linking · Corneal infection · Mycotic keratitis · Topical voriconazole

E. Erdem · I. I. Harbiyeli (✉) · M. Yagmur · R. Ersoz
Department of Ophthalmology, School of Medicine,
Cukurova University, 01330 Adana, Turkey
e-mail: inanharbiyeli@hotmail.com

E. Erdem
e-mail: elif.erdem.1979@gmail.com

M. Yagmur
e-mail: meltemyagmur@gmail.com

R. Ersoz
e-mail: reha@erso.org

H. Boral · M. Ilkit
Division of Mycology, Department of Microbiology,
School of Medicine, Cukurova University, Adana, Turkey
e-mail: hazalkandemr@gmail.com

M. Ilkit
e-mail: macitilkit@gmail.com

Abbreviations

CXL Corneal collagen cross-linking

SGA Sabouraud glucose agar

PDA Potato dextrose agar

Introduction

Mycotic keratitis is one of the challenges of the current ophthalmology practice. The management of the disease is difficult because of the aggressive course of infection, limitations of medical treatment options, and fungal resistance to the drugs used [1, 2]. Novel treatment options are urgently needed for this visually debilitating disease.

UV-activated riboflavin has been effectively used for many years for the inactivation of pathogens in blood products before transfusion [3, 4]. In recent years, the antimicrobial effect of corneal collagen cross-linking (CXL) has been investigated in various forms of keratitis, and the results are promising [5–10]. These studies also demonstrated the biomechanically stabilizing effect of CXL in cases with structurally weakened corneas [8–17]. The therapeutic effect of CXL on mycotic ulcers is controversial, however, as some studies report that CXL improves the healing process, while others demonstrate no change or deterioration in the course of disease. In the current study, we assessed the efficiency of topical voriconazole and adjuvant CXL treatment in mycotic keratitis.

Methods

This was a retrospective analysis. The approval of the institutional ethics committee at the Çukurova University Faculty of Medicine (Adana, Turkey) was obtained, and the study protocol followed the guidelines of the Declaration of Helsinki.

The study participants were enrolled at Cukurova University (Faculty of Medicine, Ophthalmology Department) from January 2014 to July 2015. The study comprised 13 patients with mycotic keratitis affecting one eye, who showed poor response to conventional medical treatment (Table 1). A complete history of the disease course and medications were evaluated. The patients used various topical antibiotic drugs, such as moxifloxacin, fortified cefazolin, and fortified gentamicin, prior to their visit at the clinic. Demographics, risk factors, slit-lamp findings, microbiological examination results, and complications were obtained from the medical records. Uncorrected visual acuity was determined using the Snellen chart. The size of the lesions was determined along two

perpendicular axes of the infiltrate. The corneal infection was graded according to the depth of infection in the corneal layers, as follows: grade 1, anterior 1/3; grade 2, anterior 2/3, and grade 3, full thickness corneal involvement. Because UV-A-mediated CXL effect is most pronounced in the anterior 300 nm of the cornea, the ulcers that spread to this depth were excluded to avoid possible endothelial damage. The ocular pain score was evaluated before and 2 days after the surgery using a visual analogue scale (0–10), with 0 representing no pain and 10 representing very severe pain.

Corneal Sampling and Analysis

Corneal smear samples were obtained by lesion scraping under aseptic conditions. All samples were inoculated onto Sabouraud glucose agar (SGA; Merck, Darmstadt, Germany), potato dextrose agar (PDA; Merck), blood agar (Biomark, Pune, India), brain-heart infusion agar (Merck), and endo agar (HiMedia, Mumbai, India) in the form of a 'C' streak. The SGA and PDA plates were incubated at 30 °C for 7 days, and the other plates were incubated at 37 °C for 3 days. In addition, the samples were submitted to cytological examination by light microscopy.

CXL Procedure

At presentation, clinical diagnosis was mixed infection (bacterial infection with fungal infection) in all cases. Following cessation of previous drugs, wide-spectrum topical antibacterial (fortified vancomycin 50 mg/ml and fortified amikacin 20 mg/ml) and topical antifungal (voriconazole 10 mg/ml) drops were initiated hourly. Treatment regimens were modified based on laboratory results. The decision to proceed with CXL was made when only poor response to the topical treatment or a progression of infection was observed. Written informed consent was obtained from all patients before the surgery. CXL was performed according to the Dresden protocol [18]. Epithelial debridement was performed over the area of infiltration under topical anesthesia, and the corneal epithelium was removed, exceeding the infiltrate margins by 2 mm. Riboflavin solution (10 mg riboflavin phosphate in 10 ml of 20% aqueous dextran solution; Medio-cross GmbH, Neudorf, Germany) was then applied every 5 min over a 30-min period,

Table 1 Clinical and microbiological characteristics

Case	Age/sex	Duration of symptoms weeks	Time to CXL ^a (days)	Ulcer diameter ^b (mm)	Ulcer grade	Pain score ^c before/after	Visual acuity ^d initial/final	Culture	Cytological examination	Co-infections	Time to complete epithelization days	Complications
1	33/M	2	7	5 × 5	3	8/4	HM ^e /HM	-	+	-	-	Progressive melting
2	66/F	1	18	3 × 4	2	8/2	0.05/0.1	-	+	-	20	-
3	20/M	4	4	2 × 3	1	7/3	0.1/0.4	-	+	<i>Acanthamoeba</i>	15	-
4	23/F	2	10	3 × 3	1	8/4	0.05/0.1	<i>Aspergillus</i>	+	<i>Acanthamoeba</i>	35	-
5	45/M	3	5	4 × 5	3	9/5	HM/HM	-	+	-	-	Progressive melting
6	41/F	2	7	2 × 3	1	6/2	0.2/0.4	<i>Fusarium</i>	-	-	33	-
7	74/M	2	8	5 × 5	3	7/3	HM/HM	-	+	<i>S. pneumoniae</i>	-	Progressive melting
8	60/F	3	10	3 × 4	2	9/4	HM/0.05	<i>Fusarium</i>	-	<i>S. epidermidis</i>	40	-
9	45/M	4	6	4 × 5	2	8/3	0.05/0.1	<i>Aspergillus</i>	-	-	15	-
10	39/F	5	4	4 × 4	3	8/5	0.2/0.05	<i>Fusarium</i>	+	-	-	Progressive melting
11	35/M	3	6	2 × 3	1	8/3	0.2/0.4	<i>Fusarium</i>	-	-	25	-
12	16/M	2	7	3 × 4	3	9/4	0.05/HM	<i>Fusarium</i>	-	-	-	Progressive melting
13	55/F	3	7	4 × 4	2	8/4	HM/HM	<i>Aspergillus</i>	+	-	-	Progressive melting

^aDuration between presentation and CXL^bLongest diameters in two perpendicular axis^cVisual analogue score before and 2 days after CXL^dDecimal value^eHand motion

followed by UV-A radiation (365 nm) with an irradiation of 3 mW/cm² for 30 min. Riboflavin instillation was continued every 5 min during UV-A radiation. Previous topical medications were continued after the CXL. Patient condition was daily evaluated using a slit-lamp daily during the first couple of weeks, and then during frequent visits at following days until complete epithelialization.

Statistical Analysis

Statistical analysis was performed using paired t tests to compare pre- and postoperative pain score values. A *p* value less than 0.05 was considered statistically significant.

Results

Patients' Characteristics

The clinical and microbiological characteristics of the 13 patients assessed in the present study are shown in Table 1.

At presentation, all patients suffered from reduced visual acuity, photophobia, ocular pain, and redness. The mean duration of symptoms was 2.7 ± 1 weeks (1–5 weeks). The risk factors were trauma with vegetative matter (tree branch, or leaf and soil; cases 1, 2, 5–8, and 11–13), contact lens wearing (cases 3, 4, and 10), and previous ocular surgery (keratoplasty; case 9).

Culture results were positive for *Aspergillus* spp. (in three cases) and *Fusarium* spp. (in five cases). In the remaining five patients, fungal infection was diagnosed by detection of fungus hyphae upon cytological examination. Besides fungal infection, various microorganisms were detected in four patients (*Acanthamoeba* spp. in two cases, *Streptococcus pneumoniae* in one case and *Staphylococcus epidermidis* in one case), and the treatment was appropriately modified to target these additional microorganisms.

CXL Treatment and Outcomes

Patient follow-up was conducted for an average of 5.3 ± 3 months (1–12 months). CXL was performed at 7.6 ± 3.6 days (4–18 days) after presentation. No intraoperative complications were observed in any of

the cases. The patients reported a pronounced pain relief at early postoperative period. Pre- and postoperative pain score values were 8 ± 0.8 and 3.5 ± 1, respectively (*p* < 0.05). At presentation, hypopyon was present in three patients (cases 1, 2 and 7). It disappeared in all patients 2 days after CXL; however, it recurred during follow-up.

Seven of the 13 patients (54%) were cured with topical voriconazole and CXL adjuvant treatment in 26 ± 10 days (15–40 days). The remaining six patients (46%) required other medical/surgical interventions to manage the infection and progressive corneal melting, i.e., intrastromal voriconazole injection (cases 1, 10, and 12), amniotic membrane transplantation (cases 1, 5, 7 and 12), and penetrating keratoplasty (cases 1, 10, 12 and 13). All these complicated cases had initially large (> 4 mm) and grade 3 (five cases) or grade 2 (one case) ulcers. Penetrating keratoplasty was immediately performed to repair the severe corneal melting and prevent the progressive invasion of infection. Perforation was not observed in any of these cases.

At presentation, all patients had low visual acuity (ranging from hand motion to 0.2). Seven cases who were treated with topical voriconazole and CXL adjuvant treatment also demonstrated improvement in visual acuity, and final visual acuity for these cases was 0.2 (0.05–0.4).

Of note, one specific causative agent, *Fusarium*, demonstrated different clinical presentations and responses to same treatment in this series (cases 6 and 10). The clinical result was positive in case 6 (superficial infiltration) and did not require any additional treatments. In case 10, the infection was deep seated; CXL did not alter the aggressive course of the disease and penetrating keratoplasty was required to control the infection (Figs. 1, 2).

Discussion

The management of mycotic keratitis is challenging because the available treatment options are limited. Topical use of antifungal drugs is not satisfactory because of its poor corneal penetration. Natamycin is the drug of choice for treating filamentous keratitis [2]. Another drug, voriconazole, is a wide-spectrum triazole with good corneal penetration [19]. The safety and efficacy of voriconazole and natamycin were

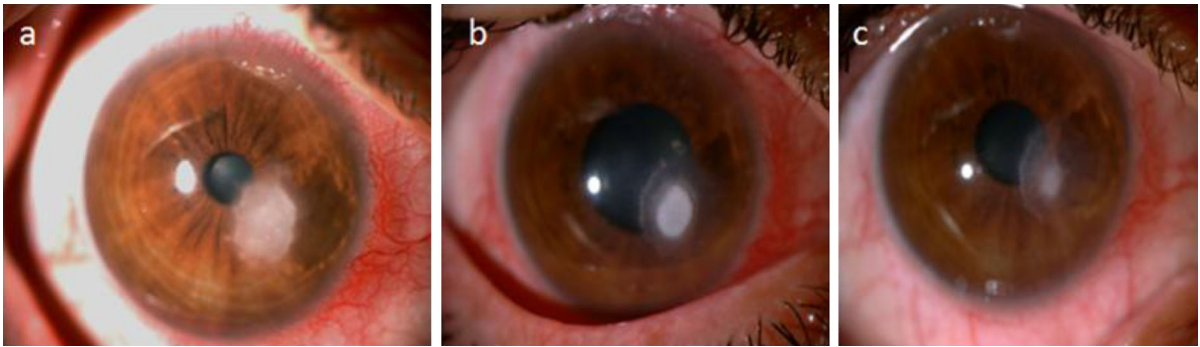


Fig. 1 Clinical images of case 6. **a** Presentation: superficial infiltration with feathery margins. **b** Seven days after CXL: reduction in the lesion diameter. **c** 1 month after CXL: complete resolution of the infection

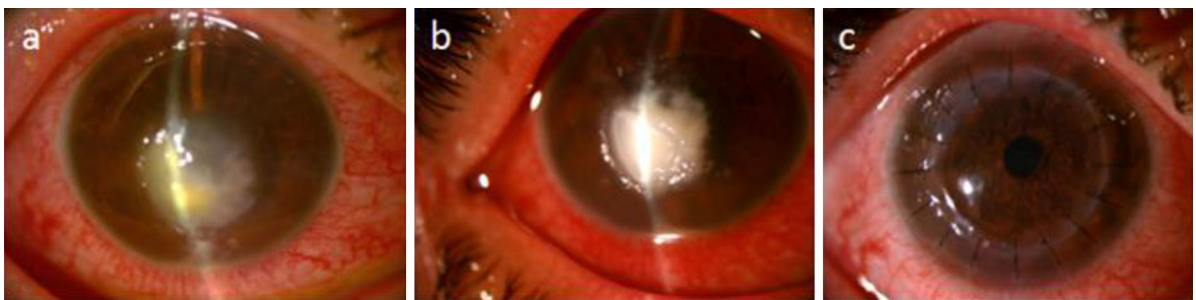


Fig. 2 Clinical images of case 10. **a** The initial examination: deep-seated infection with large infiltration. **b** Seven days after CXL: the thinning of the cornea and deep invasion infection. **c** Penetrating keratoplasty 20 days after CXL: clear corneal graft

recently compared in a double-blinded randomized trial; no difference between the two was apparent [20]. Intrastromal, intracameral, or systemic administrations of antifungals constitute additional adjuvant treatment options despite insufficient evidence for their efficacy [21, 22]. In the current study, we performed CXL in patients that showed poor or no response to topical voriconazole treatment. We anticipated that CXL would promote healing and strengthen the cornea.

The results of recent studies on the treatment of microbial keratitis with CXL are encouraging. Although the mechanism is not yet fully understood, several hypotheses (antimicrobial and biomechanical) have been proposed for the observed CXL-stimulated healing of ulcers. The antimicrobial effect of CXL is attributed to oxidative damage to the nucleic acid via UV-A-activated riboflavin [3, 23–25]. Further, CXL can enhance the resistance of the cornea, which may help prevent enzymatic damage and deep invasion of infection [10, 26]. Fungi can produce collagenases that may cause corneal melting [27] and in vitro

experiments demonstrated that CXL increases the resistance of the cornea to enzymatic damage [28]. Another effect of CXL is the reduction in the inflammatory response via the induction of the apoptosis of inflammatory cells [29]. In agreement with these observations, clinical studies support the notion that CXL halts the melting process in microbial keratitis (bacteria as well as fungi or *Acanthamoeba* spp.) [5–17].

The role of CXL in the management of mycotic keratitis remains to be established. In fact, the majority of clinical studies reported in the literature are observational case series. A single case report demonstrated that CXL may be effective as a sole treatment in superficial mycotic keratitis [30]. In another case series, CXL was performed on eight patients with mycotic keratitis, who were resistant to antifungal treatment; the authors reported healing in all cases and no corneal transplantation was required [5]. Vajpayee et al. [31] compared the adjuvant CXL treatment with the conventional antifungal treatment (5% natamycin eye drops) in cases with moderate mycotic keratitis;

the authors concluded that additional CXL treatment did not affect the resolution time or visual outcomes. In another study, Price et al. [9] reported that CXL is not effective without adjunctive antifungal medications as a mycotic keratitis therapy.

Uddaraju et al. [32] reported recently that CXL does not improve the outcome in cases with recalcitrant deep stromal fungal ulcers and that perforation risk was higher in these cases. In the case series presented in the current study, corneal perforation was not observed but surgical procedures, such as amniotic membrane transplantation or keratoplasty, were performed as emergency treatments in cases with progressive melting.

On the other hand, positive effect of CXL on clinical outcomes and symptoms has also been reported. Shetty et al. [33] reported the pain relief effect of CXL; this was attributed to the possible damage of subepithelial nerve plexuses following the procedure. Similarly, we observed that all pain scores were remarkably reduced 2 days after the procedure. Another observation was the disappearance of hypopyon following CXL, which may be associated with an anti-inflammatory effect of the procedure [17]. However, the hypopyon resolving effect of CXL was transient, and hypopyon recurred during follow-up.

Different susceptibility to antifungals of *Fusarium* and *Aspergillus* species was reported [1]. No convincing evidence of the antifungal efficacy of CXL exists. Uddaraju et al. [32] reported that CXL was more successful in *Fusarium* than *Aspergillus* keratitis. Because of the small sample sizes assessed in the current study, it is difficult to address this issue herein. Of note, early 40s women (41 and 39 years old; 2 women) with *Fusarium* infection might not benefit from the treatment. It appears that clinical presentation, particularly the depth of infection, may help predict the treatment response.

In the current study, we investigated the adjunctive CXL treatment outcomes in cases with mycotic keratitis. Complete recovery was observed in 54% of the cases. The procedure was well tolerated by the patients, and no side effects or complications were observed at the perioperative period. Based on our observations, CXL appears ineffective, particularly in cases with deep invasion of fungal infection. CXL did not prevent the progressive stromal melting in such cases.

The present study has several limitations, such as the small number of participants and the retrospective design. Further, because of the ongoing antifungal treatment, the clinical improvement could not be entirely attributed to CXL.

In conclusion, poor corneal penetration and increasing drug resistance are the main issues associated with the use of the available topical antifungal drugs. CXL is a safe procedure and may comprise a novel, alternative treatment option for specific mycotic keratitis cases, e.g., as an adjuvant treatment option for early stage mycotic keratitis. In addition, it may be a preferred procedure in cases with poor response to intensive medical treatment as it may postpone an emergency keratoplasty. Considering evidence-based medicine and in light of the current literature, it is difficult to justify incorporation of CXL into the conventional antifungal treatment protocols. Large-scale randomized controlled studies are required to establish the efficiency and safety profile of this procedure.

Compliance with Ethical Standards

Conflict of interest The authors declare that they have no conflict of interest.

References

1. Prajna NV, Srinivasan M, Lalitha P, et al. Differences in clinical outcomes in keratitis due to fungus and bacteria. *JAMA Ophthalmol.* 2013;131:1088–9.
2. Prajna NV, Mascarenhas J, Krishnan T, et al. Comparison of natamycin and voriconazole for the treatment of fungal keratitis. *Arch Ophthalmol.* 2010;128:672–8.
3. Ruane PH, Edrich R, Gampp D, Keil SD, Leonard RL, Goodrich RP. Photochemical inactivation of selected viruses and bacteria in platelet concentrates using riboflavin and light. *Transfusion.* 2004;44:877–85.
4. Reddy HL, Dayan AD, Cavagnaro J, Gad S, Li J, Goodrich RP. Toxicity testing of a novel riboflavin-based technology for pathogen reduction and white blood cell inactivation. *Transfus Med Rev.* 2008;22:133–53.
5. Li Z, Jhanji V, Tao X, Yu H, Chen W, Mu G. Riboflavin/ultraviolet light-mediated crosslinking for fungal keratitis. *Br J Ophthalmol.* 2013;97:669–71.
6. Morén H, Malmström M, Mortensen J, Ohrström A. Riboflavin and ultraviolet a collagen crosslinking of the cornea for the treatment of keratitis. *Cornea.* 2010;29:102–4.
7. Anwar HM, El-Danasoury AM, Hashem AN. Corneal collagen crosslinking in the treatment of infectious keratitis. *Clin Ophthalmol.* 2011;5:1277–80.

8. Iseli HP, Thiel MA, Hafezi F, Kampmeier J, Seiler T. Ultraviolet A/riboflavin corneal cross-linking for infectious keratitis associated with corneal melts. *Cornea*. 2008;27:590–4.
9. Price MO, Tenkman LR, Schrier A, Fairchild KM, Trokel SL, Price FW. Photoactivated riboflavin treatment of infectious keratitis using collagen cross-linking technology. *J Refract Surg*. 2012;28:706–13.
10. Said DG, Elalfy MS, Gatzoufas Z, et al. Collagen crosslinking with photoactivated riboflavin (PACK-CXL) for the treatment of advanced infectious keratitis with corneal melting. *Ophthalmology*. 2014;121:1377–82.
11. Makdoui K, Mortensen J, Crafoord S. Infectious keratitis treated with corneal crosslinking. *Cornea*. 2010;29:1353–8.
12. Galperin G, Berra M, Tau J, Boscaro G, Zarate J, Berra A. Treatment of fungal keratitis from *Fusarium* infection by corneal cross-linking. *Cornea*. 2012;31:176–80.
13. Alio JL, Abbouda A, Valle DD, Del Castillo JM, Fernandez JA. Corneal cross linking and infectious keratitis: a systematic review with a meta-analysis of reported cases. *J Ophthalmic Inflamm Infect*. 2013;3:47.
14. Zhang ZY. Corneal cross-linking for the treatment of fungal keratitis. *Cornea*. 2013;32:217–8.
15. Vinciguerra R, Rosetta P, Romano MR, Azzolini C, Vinciguerra P. Treatment of refractory infectious keratitis with corneal collagen cross-linking window absorption. *Cornea*. 2013;32:139–40.
16. Vazirani J, Vaddavalli PK. Cross-linking for microbial keratitis. *Indian J Ophthalmol*. 2013;61:441–4.
17. Sorkhabi R, Sedgipoor M, Mahdavi A. Collagen cross-linking for resistant corneal ulcer. *Int Ophthalmol*. 2013;33:61–6.
18. Wollensak G, Spoerl E, Seiler T. Riboflavin/ultraviolet-a-induced collagen crosslinking for the treatment of keratoconus. *Am J Ophthalmol*. 2003;135:620–7.
19. Johnson LB, Kauffman CA. Voriconazole: a new triazole antifungal agent. *Clin Infect Dis*. 2003;36:630–7.
20. Sharma S, Das S, Viridi A, et al. Re-appraisal of topical 1% voriconazole and 5% natamycin in the treatment of fungal keratitis in a randomised trial. *Br J Ophthalmol*. 2015;99:1190–5.
21. Sharma N, Agarwal P, Sinha R, Titiyal JS, Velpandian T, Vajpayee RB. Evaluation of intrastromal voriconazole injection in recalcitrant deep fungal keratitis: case series. *Br J Ophthalmol*. 2011;95:1735–7.
22. Kuriakose T, Kothari M, Paul P, Jacob P, Thomas R. Intracameral amphotericin B injection in the management of deep keratomycosis. *Cornea*. 2002;21:653–6.
23. Kumar V, Lockerbie O, Keil SD, et al. Riboflavin and UV-light based pathogen reduction: extent and consequence of DNA damage at the molecular level. *Photochem Photobiol*. 2004;80:15–21.
24. Panda A, Krishna SN, Kumar S. Photoactivated riboflavin therapy of refractory corneal ulcers. *Cornea*. 2012;31:1210–3.
25. Bettis DI, Hsu M, Moshirfar M. Corneal collagen cross-linking for nonectatic disorders: a systematic review. *J Refract Surg*. 2012;28:798–807.
26. Spoerl E, Huhle M, Seiler T. Induction of cross-links in corneal tissue. *Exp Eye Res*. 1998;66:97–103.
27. Dong X, Shi W, Zeng Q, et al. Roles of adherence and matrix metalloproteinases in growth patterns of fungal pathogens in cornea. *Curr Eye Res*. 2005;30:613–20.
28. Spoerl E, Mrochen M, Sliney D, et al. Safety of UVA-riboflavin crosslinking of the cornea. *Cornea*. 2007;26:385–9.
29. Wollensak G, Spoerl E, Wilsch M, et al. Keratocyte apoptosis after corneal collagen cross-linking using riboflavin/UVA treatment. *Cornea*. 2004;23:43–9.
30. Tabibian D, Richo O, Riat A, et al. Accelerated photoactivated chromophore for keratitis—corneal collagen cross-linking as a first-line and sole treatment in early fungal keratitis. *J Refract Surg*. 2014;30:855–7.
31. Vajpayee RB, Shafi SN, Maharana PK, Sharma N, Jhanji V. Evaluation of corneal collagen cross-linking as an additional therapy in mycotic keratitis. *Clin Exp Ophthalmol*. 2015;43:103–7.
32. Uddaraju M, Mascarenhas J, Ranjan MD, Radhakrishnan N, Keenan JD, Prajna L. Corneal cross-linking as an adjuvant therapy in the management of recalcitrant deep stromal fungal keratitis: a randomized trial. *Am J Ophthalmol*. 2015;160:131–4.
33. Shetty R, Nagaraja H, Jayadev C, et al. Collagen crosslinking in the management of advanced non-resolving microbial keratitis. *Br J Ophthalmol*. 2014;98:1033–5.