



Battling the emerging epidemic of rhino-orbital-cerebral mucormycosis (ROCM) in COVID-19 pandemic: an interventional study

Aastha Gandhi · Anurag Narula · Shreya Chandra · Dhwanee Agarwal · Anuj Mehta · Shaktiprada Nayak · Sheetal Arora · Malini R. Capoor

Received: 4 October 2021 / Accepted: 6 October 2022 / Published online: 23 October 2022
© The Author(s), under exclusive licence to Springer Nature B.V. 2022

Abstract

Purpose The most recent challenge being faced by the healthcare system during the worldwide COVID-19 pandemic is increase in the incidence rate of coinfection or superinfection; one of the most fatal being mucormycosis. This study aimed to estimate the risk factors, symptoms and signs, treatment outcome and prognosis of COVID-19-associated mucormycosis (CAM) patients.

Methods This is an interventional study of 35 patients diagnosed and managed as CAM at a tertiary care centre in New Delhi, India.

Results The mean age of patients was 40.45 ± 6 years with a male preponderance. CAM did

not affect healthy individuals; the major risk factors included diabetes in 65.7% and injudicious steroid use in 51.4% patients. Orbital/facial edema was the most common presenting symptom (25.7%) as well as sign (28.57%). 68.5% patients were stage 3 (involvement of orbit) at presentation; 33.3% showed medial wall involvement. Treatment included intravenous Amphotericin and oral Posaconazole in all patients, paranasal sinus (PNS) debridement in 94.2%, orbital exenteration was done in 8 patients. Adjuvant retrobulbar Amphotericin B injection was administered in 12 patients with radiological resolution seen in 50% after 1 cycle. In patients with Stage 4 disease who underwent exenteration along with PNS debridement, survival rate was 100% at 30 days, and disease reduction occurred in 87.5% patients ($P < 0.01$). Overall, 68.5% responded to therapy, 8.5% showed progression and mortality rate was 22.85%, at a mean follow up period of 59.5 days.

Conclusion A multidisciplinary and aggressive approach is essential in the management of CAM patients.

Keywords COVID-19 · ROCM · CAM

A. Gandhi (✉) · A. Narula · S. Chandra · D. Agarwal · A. Mehta
Department of Ophthalmology, Vardhman Mahavir Medical College and Safdarjung Hospital, New Delhi 110029, India
e-mail: aastha1009@yahoo.co.in

S. Nayak
Department of Radiodiagnosis, Vardhman Mahavir Medical College and Safdarjung Hospital, New Delhi, India

S. Arora
Department of Pathology, Vardhman Mahavir Medical College and Safdarjung Hospital, New Delhi, India

M. R. Capoor
Department of Microbiology, Vardhman Mahavir Medical College and Safdarjung Hospital, New Delhi, India

Introduction

Mucormycosis is a rare, opportunistic, life threatening angio-invasive disorder caused by Mucorales fungus species like *Rhizopus*, *Mucor*, *Rhizomucor*,

Cunninghamella and Absidia [1]. It affects nose, sinus, orbit, central nervous system, gastrointestinal tract, skin, jaw bones, lung, heart and kidneys. Amongst these, ROCM is the most common presentation [2].

India, being the diabetic capital of the world, has reported a prevalence rate of 0.14 mucormycosis patients per 1000, which is more than 80 times as compared to developed countries [3, 4]. In addition, in the latest systematic review published by Pal et al., wherein they identified 30 case reports/case series by pooling data retrieved from 99 patients with CAM, most cases were reported from India (72%) [5]. The sudden upsurge of mucormycosis cases in India shows a close link between mucormycosis and COVID-19. The non – judicious use of corticosteroids and oxygen in patients with COVID-19, worsening of blood sugar control and viral-induced lymphopenia have been implicated as probable causal factors [5, 6]. Furthermore, with the cytokine storm in COVID, the resultant endothelial damage and lymphopenia makes the patient more prone to infection with Mucor [7]. The fungal hyphae invades blood vessels causing infarction and necrosis of host tissue. In addition, due to the rapid onset and progression, delay in diagnosis doubles the mortality rate from 35 to 66%; prompting the need for early diagnosis and treatment [4]. Due to the sudden upheaval of the fungal infection challenging the already overburdened healthcare system, it is the need of hour to assess and devise a better management algorithm for prevention, early detection and management of the disease for better morbidity and mortality rates.

We present a series of 35 patients who presented to us and were subsequently diagnosed, investigated, and managed as COVID-19 associated ROCM cases. To the best of our knowledge, no study has been undertaken yet that intends to estimate risk factors, population at risk, clinical presentation, treatment outcome and prognosis of a large cohort of patients as ours.

Materials and methods

A single centred study was performed on 35 patients who presented to a tertiary care hospital, New Delhi during January–July 2021 and followed up for a mean period of 59.5 days. The patients enrolled were

proven to be cases of CAM on the basis of clinical features along with supporting radiological and/or microbiological evidence. The COVID infection, concurrent or in the past (< 12 weeks), was tested by a real-time reverse transcriptase-polymerase chain reaction (RT-PCR) report of nasopharyngeal/ oropharyngeal swab of the patient. Non COVID associated ROCM patients and patients who were lost to follow up were excluded from the study.

The clinical diagnosis of CAM in a patient having a history of recently treated/concurrent COVID infection was made on the basis of presenting symptoms like nasal block, nasal discharge, orbital or facial pain/swelling/numbness/dyscolouration, drooping of eyelid, bulging out of eyeball, loss of vision, with one or more of the following clinical signs like nasal ulcer, nasal/palatal eschar, periocular edema/dyscolouration/hypoesthesia, ptosis, diplopia, proptosis, loss of vision or cranial nerve involvement (FIGURE 1). A history of uncontrolled or poorly controlled diabetes mellitus, immunosuppressive state due to prolonged steroid/Remdesivir intake, intensive care unit (ICU) stay, leukemia/other malignancies or other comorbidities was also asked for.

After complete ophthalmological examination, referral to an ear-nose-throat (ENT) specialist was done and the patient was then subjected to direct nasal endoscopy (DNE)/ functional endoscopic sinus surgery (FESS) and a conclusion was drawn after direct microscopy, histopathology and/or Potassium Hydroxide (KOH)/Calcoflour white culture. (FIGURE 2) All patients underwent Gadolinium enhanced magnetic resonance imaging (Gd-MRI) and fat saturation post contrast sequences were examined to assess the extent of the disease. All patients in our study turned out to be “proven” cases of mucormycosis (TABLE 1) and subsequently rhino-orbito-cerebral mucormycosis (ROCM) Staging was done according to the Code Mucor guidelines [2].

Based on the final diagnosis and depending on the availability, all the patients were initiated on intravenous Liposomal Amphotericin B (5–10 mg/kg/day) or Deoxycholate Amphotericin B (1–1.5 mg/kg/day) with renal monitoring along with tablet Posaconazole 300 mg BD on the first day followed by 300 mg OD for 13 days. The combined approach was opted because of the irregular supply of Amphotericin in the market and non-inferior action of Posaconazole [8]. In ROCM stage 3a-b, in addition, a trial of

Fig. 1 **a** Periorbital edema with conjunctival chemosis and crusting **b** Left eye complete ptosis with mild periorbital edema **c** Limitation in eye movement in elevation

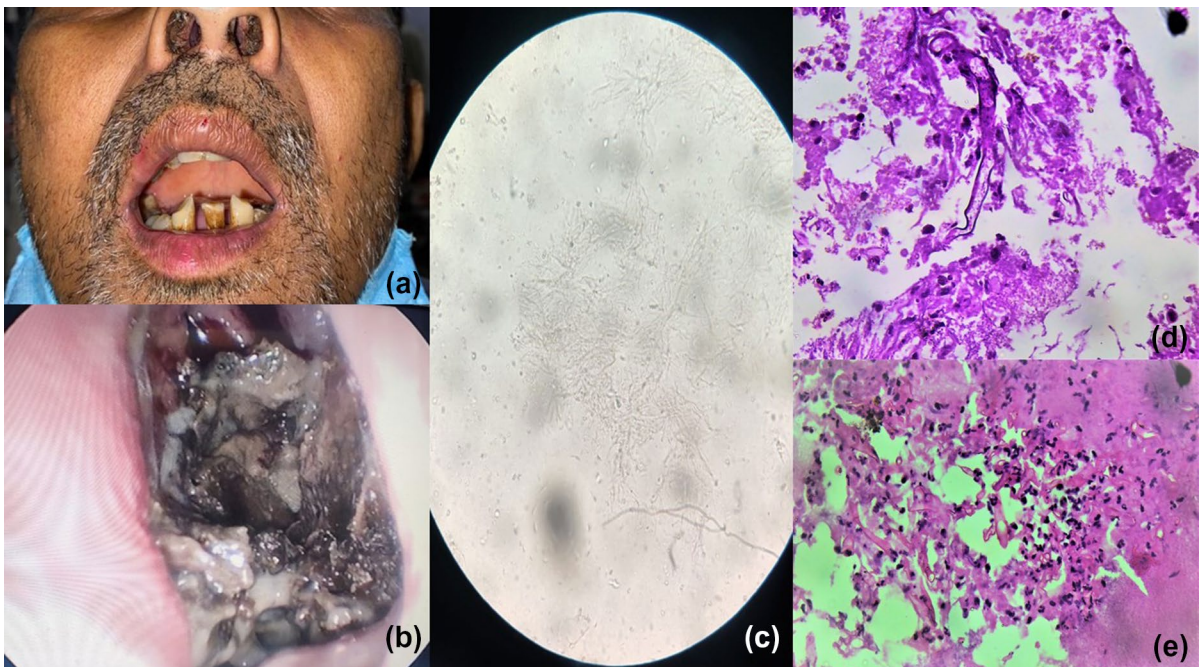
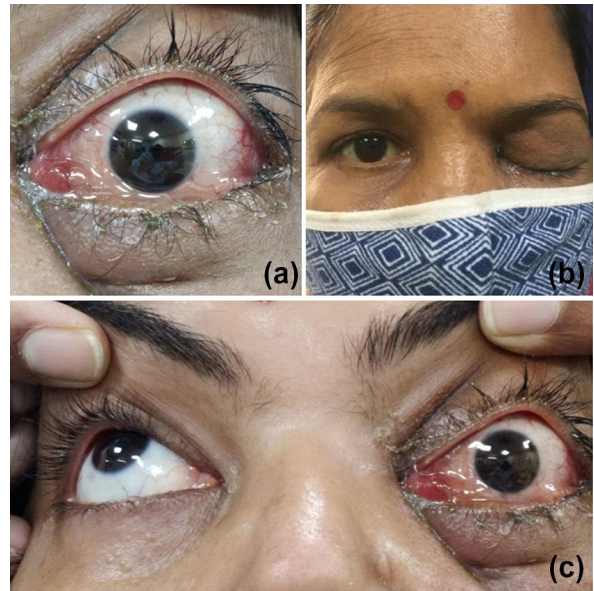

Fig. 2 Examination of a 42 year old male patient presenting with nasal discharge **(a)** Clinical photograph showing presence of nasal eschar **(b)** DNE showing areas of necrosis. KOH mount **(c)** and Periodic Acid Schiff **(d)** stained section shows

broad septate fungal hyphae **(e)** Histopathology (H&E stain) shows multiple broad aseptate fungal hyphae with areas of necrosis, morphologically consistent with mucor species

retrobulbar Amphotericin B 3.5 mg/ml injection was given on alternate days for 3 days followed by 1 day off, followed by repeat contrast MRI to assess the

control of disease; following which another cycle of 3 alternate days was repeated in case of insufficient resolution/disease progression. In cases of suboptimal

Table 1 Classification of ROCM (Reproduced with permission from Honavar SG. Code Mucor: Guidelines for the Diagnosis, Staging and Management of Rhino-Orbito-Cerebral Mucormycosis in the Setting of COVID-19. Indian Journal of Ophthalmology. 2021;69:1361–5)(2)

Possible ROCM	Typical symptoms and signs of ROCM Clinical setting of concurrent or recently treated COVID-19
Probable ROCM	Clinical features suggestive of ROCM Supportive diagnostic nasal endoscopy findings and/or Supportive radiological signs on contrast-enhanced magnetic resonance imaging or computed tomography scan
Proven ROCM	Clinico-radiological features suggestive of ROCM Microbiological confirmation on direct microscopy and/or Culture and/ or Histopathology with special stains and/or Molecular diagnostics

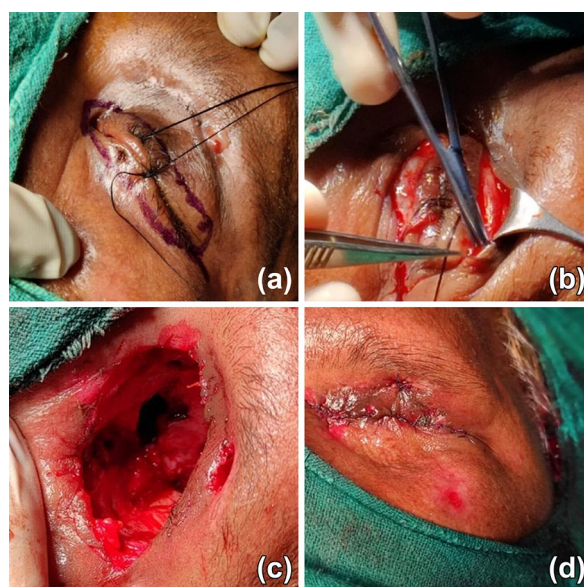
response to the medical treatment with the possibility of active intracranial spread, lid sparing orbital exenteration with transverse blepharorrhaphy along with endoscopic sinus surgery and sinus irrigation was carried out.(FIGURE 3) The patients were post operatively kept on intravenous antifungal therapy for 14 days and subsequently, down staged to oral antifungal therapy. The entire team consisted of Internal Medicine specialists, ENT specialists, Ophthalmologist, Neurologists, Microbiologists, Radiologists, and Anaesthetists. The data was entered in MS EXCEL and analysed using SPSS version 20 and Microsoft excel version 16.49. The Chi-square/Fisher's

exact tests were used to compare outcomes. For all tests, p values ≤ 0.05 were considered as statistically significant.

Results

Out of the 35 patients that presented to us, 20 were males and 15 were females of mean age 40.45 ± 6 years (range 20.1 to 74.8 years). 20% patients had active COVID-19 infection, 70% the patients had a history of recently treated COVID-19

Fig. 3 Steps of eyelid sparing orbital exenteration: **a** Incision marking is placed 2 mm behind the lash line, and joined at the medial and lateral commissures. **b** A periosteal elevator is used to separate periorbita from the bony socket **c** The globe and all orbital contents are cut at the orbital apex and removed. **d** The eyelid flaps are reapproximated in two layers



infection (<6 weeks) and 10% had recovered from COVID-19 infection >6 weeks ago.

Further analysis showed 65.7% (23) were diabetics, 31.4% (11) were hypertensives, 5.7% (2) had malignancy and 2.8% (1) had rheumatoid arthritis. Out of all the diabetic patients, 65.2% of patients were on insulin with uncontrolled blood sugar profile (Mean HbA1c=10.5 g %), 13.04% were on insulin with controlled blood sugar profile (Mean Hb1ac=6.2 g %), and 8.72% patients were on oral hypoglycaemic drugs with controlled blood sugar profile (Mean Hb1ac=6.4 g %). Besides, 51.4% (18) patients of our study group had a history of prolonged steroid intake (mean duration 17.5 ± 4 days), out of which 83.3% had been on intravenous steroids. In addition 11.4% (4) patients received Remdesivir and 31.4% (11) patients received oxygen supplementation (72.7% via facemask, 18.1% on NIVM and 9.2% on ventilator) for COVID-19 infection.

The median time duration of onset of first symptom suggestive of mucormycosis was 21.5 days from the day of negative RT-PCR report. Orbital/facial edema was noticed to be the most common presenting symptom (25.7%), followed by orbital/facial pain (17.14%) and discolouration (14.28%). Other presenting symptoms included: dental pain, nasal discharge, nasal block, ptosis, proptosis, loss of vision and diplopia. The most common sign was facial/periorbital edema in 28.57% patients, followed by ptosis in 22.85% and loss of vision in 14.28%. Other evident signs were: nasal discharge, periorbital/facial discolouration, nasal ulcer/eschar, periorbital hypoesthesia, diplopia, proptosis, cranial nerve involvement. (TABLE 2) 14.2% patients presented with complete loss of vision (No perception of light), 22.8% with hand movement close to face, 14.2% with visual acuity <6/60 and 48.5% with 6/60 and better.

At the time of presentation, majority of the patients had diffuse involvement of all paranasal sinus (85.7%) and 68.5% patients had orbital involvement. Amongst the patients with orbital involvement, 33.3% showed involvement of medial wall, 23.3% of orbital apex, 20% inferior wall, 3% roof and 16% showed diffuse orbital involvement. CNS involvement was seen in 22.85% cases which was mostly through cavernous sinus (75%) followed by cribriform plate (25%). Bilaterality of CNS involvement was found in 5.7% cases. Fungal culture was positive in 82.8% patients and showed Rhizomucor strain in all.

Table 2 Clinical profile, management and treatment outcome of patients

Parameter	Number	Percentage (%)
<i>Presenting Symptom</i>		
Nasal block	2	5.7
Nasal discharge	3	8.5
Dental pain	4	11.4
Orbital/facial pain	6	17.1
Orbital/facial edema	9	25.7
Orbital/facial discolouration	5	14.2
Ptosis	2	5.7
Diplopia	1	2.8
Proptosis	2	5.7
Loss of vision	2	5.7
Others	0	0
<i>Presenting Sign</i>		
Nasal discharge	3	8.5
Nasal ulcer/eschar	2	5.7
Periorbital/facial edema	10	28.5
Periocular/facial discolouration	3	8.5
Periocular hypoesthesia	2	5.7
Ptosis	7	22.8
Diplopia	1	2.8
Proptosis	1	2.8
Loss of vision	5	14.2
Cranial nerve involvement	1	2.8
Others	0	0
<i>ROCM Staging at presentation</i>		
STAGE 1	2	5.7
STAGE 2	1	2.8
STAGE 3A	2	5.7
3B	10	28.5
3C	6	17.1
3D	6	17.1
STAGE 4A	4	11.4
4B	2	5.7
4C	2	5.7
4D	0	0
<i>Final Outcome</i>		
Alive with regression	14	40
Alive and stable	10	28.5
Alive with progression	3	8.5
Dead	8	22.8
<i>Management</i>		
IV Amphotericin B	35	100
Posaconazole	35	100
Retrobulbar Amphotericin	12	34.2
Debridement	33	94.2

Table 2 (continued)

Parameter	Number	Percentage (%)
Exenteration	8	22.8

All the patients were started on intravenous Amphotericin and oral Posaconazole. 12 out of the 35 patients, based on the ROCM staging, were given adjuvant retrobulbar Amphotericin injection. As a primary surgical intervention, 94.2% of the patients underwent endoscopic sinus surgery followed by sinus debridement and irrigation and 8 patients underwent exenteration either as a primary procedure or after non response/progression despite medical treatment.

About 68.5% patients showed response to the therapy, with 40% showing regression. 8.5% of patients are still showing further progression and would need more aggressive and prolonged treatment. Out of 8 exenterated patients, follow up of 6 patients was uneventful. 1 patient had wound gaping on 3rd post-op day, which was resutured and 1 showed progression to severe disease. Overall, we found that the prognosis was poor after the disease advanced to stage 3c or worse with mortality and disease progression seen in 75% (15 of 20) of the patients in comparison to 20% (3 of 15) in those with stage 3b or better ($P=0.03$). Presence of CNS involvement (Stage 4), bilaterality, HbA1c value of ≥ 10 were also found to be predictors of poor prognosis ($P=0.01$). In our study, overall mortality rate of CAM was 22.85%.

Discussion

The nation had already been struggling with the notorious second wave of COVID-19 infection when the epidemic of mucormycosis presented as another hurdle to tackle with. The average annual incidence of non COVID associated mucormycosis in the past 5 years presenting to our department was 8.9 cases per year. Our study comes with sudden surge of mucormycosis, with 35 COVID associated mucormycosis cases till date. Mucormycosis is commonly known to be an angio-invasive opportunistic fungal infection that infects people predisposed with uncontrolled diabetes mellitus, prolonged steroid usage or immunosuppressive therapy, malignancies, primary

or secondary immunodeficient state like in HIV infection, tuberculosis, lung diseases, chronic malnutrition, renal failure, etc. [7]. The hypoxic state produced in COVID infection along with high glucose and ferritin levels and low phagocytic action of leucocytes and the management of the infection with steroid and other immunosuppressive drug therapies like remdesivir make the environment conducive for mucor infection [6].

In our study, majority of ROCM affected patients were middle aged men with mean age group of 40.45 ± 6 years, a decade younger than in the latest largest retrospective study (COSMIC report) conducted by Sen M et al. [9], where the mean age was 51.9 (range 12–88) years with a male preponderance of 71%, where they quote greater severity of COVID-19 in male gender and greater outdoor exposure and, thus, to fungal spores as the possible reasons for this majority. The major highlight that came forward in our study was that CAM did not affect healthy individuals and all the people affected were predisposed to the disease, with the most common risk factors being steroid usage and uncontrolled diabetes. Out of the 35 patients enrolled, 51.4% had history of steroid intake and 65.7% had diabetes mellitus. These findings are consistent with a systematic review conducted by John et al. in 41 confirmed cases of CAM where 93% were diabetics and 88% had a history of corticosteroid intake [10], and by Singh et al. [6] which revealed 80% patients were diabetics and 76.3% had history of corticosteroid use. Moorthy et al. [11] recently reported the association of COVID-19 infection with uncontrolled DM and usage of corticosteroids. Furthermore, the incidence of mucormycosis, in our study, was more in people with mild to moderate COVID who were managed under home isolation with unregulated or self-prescribed use of steroid, with average duration of treatment lasting > 2 weeks. This led to upstaging of the disease to severe COVID and resultant hospitalization in 65.8% of cases where oxygen supplementation and steroid therapy became the key management. In the pre COVID era, diabetes mellitus has been identified as an independent risk factor for mucormycosis [1, 4] as has been prolonged (> 3 weeks) of high-dose systemic corticosteroid [9]; however, there is paucity of literature to state a causal effect relationship with reference to oxygen supplementation, steroid and immunosuppressive drug therapy in COVID-19 patients.

The mode of infection of mucor is usually by inhalation of fungal sporangiospores in the paranasal sinus which upon germination, actively spread into the adjacent spaces—inferiorly to palate, posteriorly to sphenoid sinus, laterally to the cavernous sinus and orbit, and cranially to the brain through orbital apex or cribriform fossa [12, 13]. Most of the patients that presented to us were ROCM stage 3 or beyond at the time of first presentation. It might be due to relatively late presentation for the primary ophthalmic symptoms of the disease entity when fungus has further spread beyond the paranasal sinus and orbit. The onset of first symptom suggestive of mucormycosis was, 70% of the times, within 6 weeks of recovery from COVID infection, the median time duration being 21.5 days from the day of negative RT-PCR report. Our study determined orbital/facial swelling as the most common presenting feature followed by orbital/facial pain, orbital/facial discoloration, dental pain, and ptosis. The most common presenting signs were periocular/facial edema followed by ptosis, periocular/facial discoloration, and hypoesthesia. These primary signs and symptoms of COVID-19 associated ROCM were largely consistent with that of pre COVID era ROCM [14].

The gold standard for definite diagnosis of ROCM still remains histopathological analysis of mucosal biopsy [8]. In our study, samples from nasal mucosa, paranasal sinus mucosa or orbital tissue was subjected to routine fixed sections for histopathological analysis with Hematoxylin–eosin, periodic acid-schiff, and/or Grocott-Gomori's methenamine silver special stain. Identification of broad non-septate or sparsely septate fungal hyphae with associated tissue damage/ angioinvasion/ necrosis was characteristic of the disease. Contrast enhanced MRI has been proved to be a superior imaging technique over Contrast enhanced CT [9]. MRI was the preferred modality to monitor the extent of the disease. The latest retrospective series on CAM from a geographically different location published by T.V. Dave et al. [15] analysed 58 cases and noted that Intracranial extension was seen in 33%, comparable to 22.85% in current study. ($p=0.2$). In the COSMIC report, diffuse orbital involvement predominated in 40% followed by involvement of the medial orbit in 27%, compared to medial orbital wall involvement as the most common form of orbital involvement (33%) in our study. In the CNS, cavernous sinus was most commonly involved

in both the studies (53% and 75% respectively). Besides diagnosis, MRI was also the preferred modality to monitor the progression of disease and effect of treatment in our study. (FIGURE 4).

The global guidelines for the diagnoses and management of mucormycosis by the European Society for Clinical Microbiology and Infectious Diseases and European Confederation of Medical Mycology [13] was followed with certain modifications (FIGURE 5). Medical antifungal therapy with or without surgical debridement along with glycemic control or control of any other risk factor is the mainstay of management [13]. In addition, 1 ml of retrobulbar Amphotericin B-deoxycholate in the dose of 3.5 mg/dl was injected for stages 3A-3B, on alternate days for 3 days followed by 1 day off before the next cycle. Quadrant was decided based on route of spread as determined on Gd-MRI. The most common side effects noted included chemosis (85%), pain (60%), and proptosis (15%). In the recent reports published on CAM, retrobulbar Amphotericin was given in one patient in the recent study by Dave et al., [15] and they reported radiological resolution with uneventful follow up at 6 months of follow up. Although there is paucity of literature on the safety and efficacy profile of the treatment method, we found that retrobulbar Amphotericin injection, when indicated, caused radiological resolution in atleast 50% patients after 1 cycle of therapy and in 65% patients after 2 cycles. However, larger studies with a non COVID control group is needed to prove the efficacy of the same. Overall, the treatment success rates of their study and the current study were 60% and 68.5%, respectively ($p=0.2$).

Orbital exenteration is done in cases with no visual potential, with diffuse orbital involvement, but with the disease limited to the orbit without or minimal extension beyond cavernous sinus [9]. Few studies have even highlighted orbital exenteration in cases with CNS involvement to be detrimental to survival. In our study, orbital exenteration along with PNS debridement was done in 22.8% patients. (FIGURE 5). With the mean follow up being at least 30 days, 100% of the patients with stage 4 ROCM who had undergone orbital exenteration survived and 87.5% showed regression of disease burden ($P<0.01$). This was in comparison to 100% mortality seen in those who did not undergo exenteration. Thus, contrary to current belief, surgery in such patients may drastically improve survival, though larger studies are

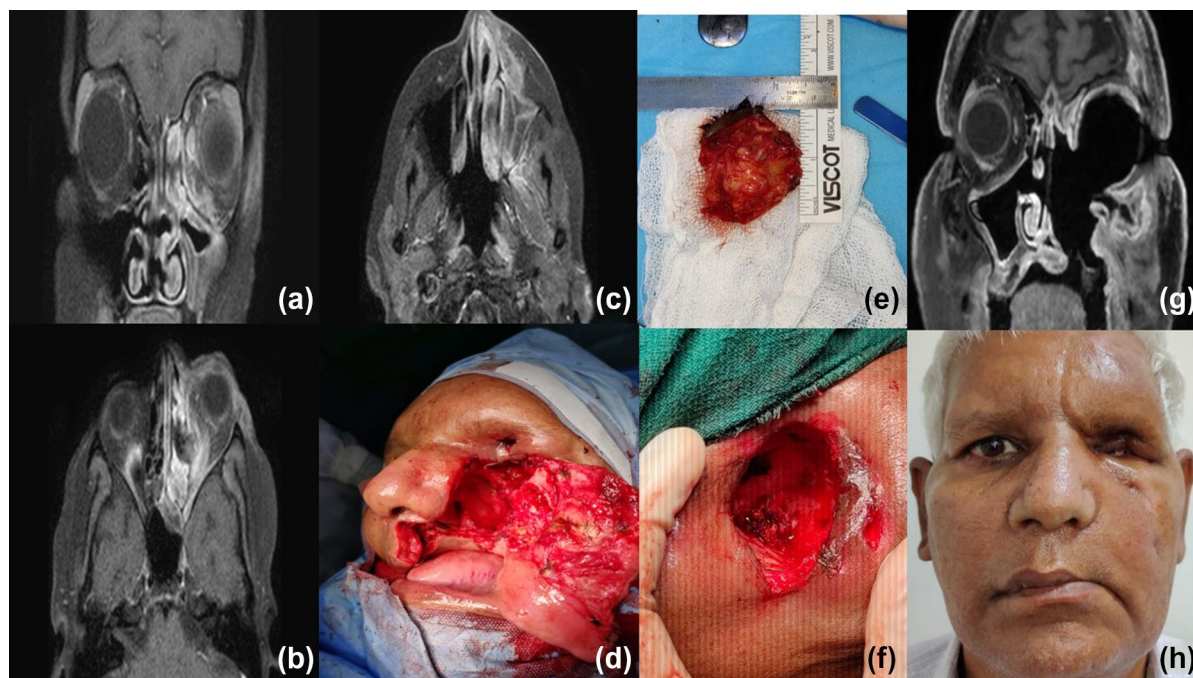


Fig. 4 T1 weighted post contrast fat saturated sequences (coronal and axial; **a,b,c**) of a 45 year old patient show enhancing soft tissue thickening involving left ethmoid sinus, left maxillary sinus with destruction of left medial orbital wall with contiguous extension of the disease into left orbit causing extensive orbital fat stranding with enhancing thickening and indentation of left medial rectus. There is associated enhancing thickening in preantral fat on left side with extension into

anterior nares. Patient underwent (**d**) Hemimaxillectomy with sinus debridement and (**e**) Exenteration (gross sample) (**f**) Socket post exenteration (**g**) Post-operative CE MR shows non visualization of left maxilla and orbit suggestive of resolution of disease. Residual enhancing thickening in preantral fat and ethmoid noticed. (**h**) Clinical photograph at 3 months of follow up after surgical reconstruction

needed to prove the same. In patients with Stage 4 disease, we found that orbital exenteration was helpful in increasing survival besides disease reduction. Till date, results from our study indicate that mortality with CAM was 22.85% and disease progression was seen in 10% of the cases; comparable to the overall mortality rate of 34% in the series by TV Dave et al. [15]. ($p=0.48$) These results are however likely to change over time while the patients are followed up for a longer duration.

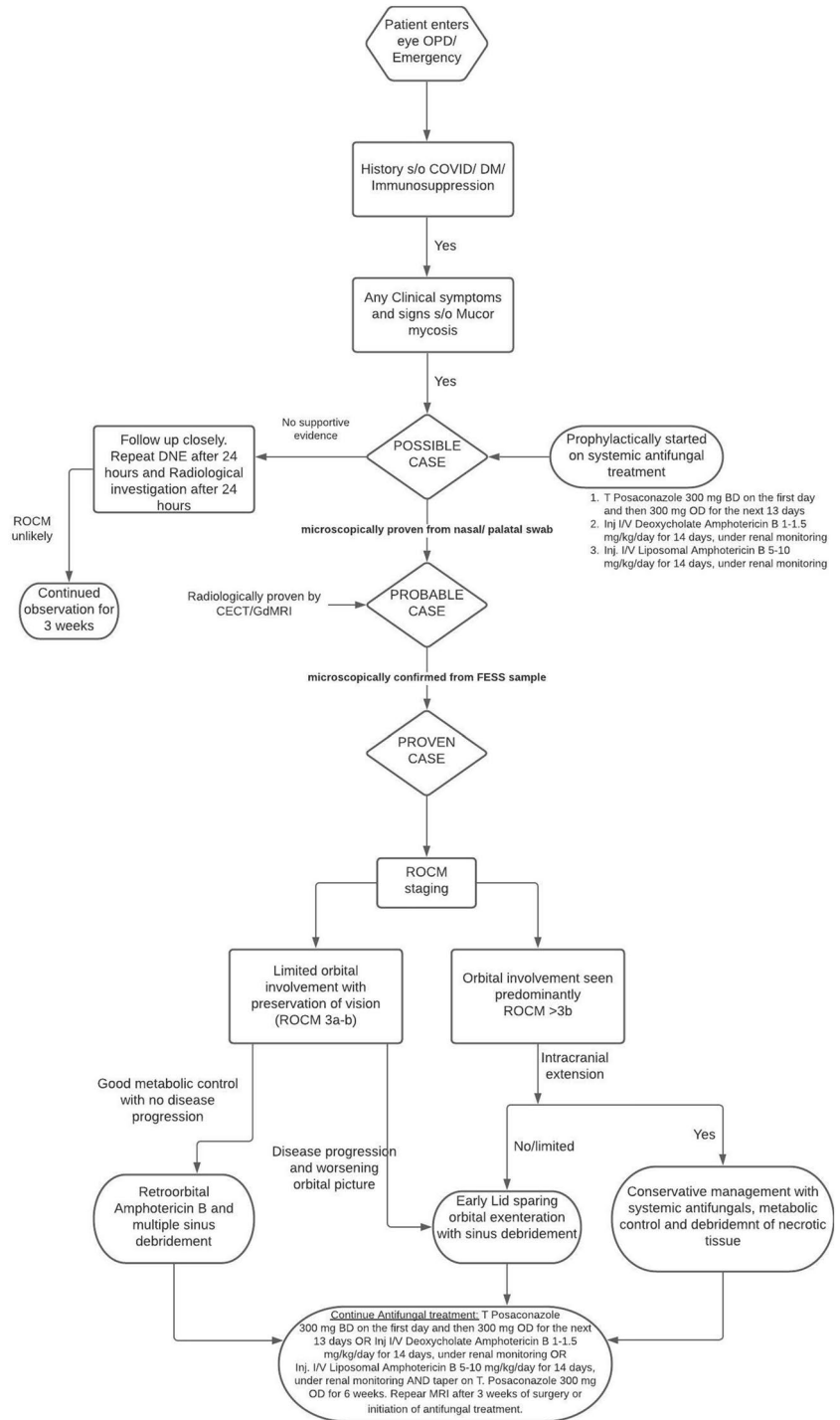
Non COVID associated mucormycosis (Pre COVID era) is an established entity. However, there is a huge deficit of literature on COVID associated mucormycosis due to the sudden upsurge and relative newness of the disease. Our study comes as the largest interventional institutional study studying the risk factors, population at risk, clinical presentation, approach to the diagnosis, management, treatment outcome and prognosis of COVID associated

mucormycosis patients. However, being a single centered study and lacking a non COVID ROCM control group, are some of the inherent limitations to this study.

Conclusion

Due to lack of previous literature and evidence-based medicine, the increase in incidence of mucormycosis in COVID patients proved to take a heavy toll on the healthcare system as well as on the personal front throughout the country. Therefore, it became most essential to study the demographics, presentation and course of disease so as to aid in early detection and better management methods of ROCM. Our study was conducted in a tertiary care center which was fully equipped to identify, diagnose, and manage CAM patients and analyze the outcomes in a unique

Fig. 5 Treatment protocol



way as to enrich the deficit in literature felt for the disease.

Author contributions Prof. Anuj Mehta and Dr. Anurag Narula planned and validated the study. Dr. Anurag Narula was the primary operating surgeon. Dr. Aastha Gandhi designed the study, wrote the primary draft and revised it. Dr. Shreya Chandra, Dr. Dhwanee Agarwal, Dr. Aastha Gandhi collected and analysed the data. Dr. Sheetal Arora, Dr. Malini Capoor, Dr. Shaktiprada Nayak performed histopathological, microbiological and radiological analysis for patients and provided the images. Dr. Aastha Gandhi, Dr. Shaktiprada Nayak and Prof. Anuj Mehta revised the manuscript and made necessary amendments.

Declarations

Conflict of interest Nothing to declare for all authors. There were no conflicts of interest.

Ethical approval All procedures performed in studies involving human participants were in accordance with the ethical standards of the institutional and/or national research committee and with the 1964 Helsinki declaration and its later amendments or comparable ethical standards. The ethical clearance was obtained from Institutional Ethics Committee, Institutional Review Board of V.M.M. C & Safdarjung Hospital, New Delhi vide proposal no. IEC/VMMC/SJH/2021/02–117.

References

1. Skiada A, Pavleas I, Drogari-Apiranthitou M (2020) Epidemiology and diagnosis of mucormycosis: an update. *J Fungi* 6:265
2. Honavar SG (2021) Code mucor guidelines for the diagnosis, staging and management of rhino-orbital-cerebral mucormycosis in the setting of COVID-19. *Indian J Ophthalmol* 69(6):1361–1365
3. Chander J, Kaur M, Singla N, Punia R, Singhal S, Attri A, Guarro J (2018) Mucormycosis: battle with the deadly enemy over a five-year period in India. *J Fungi* 4(2):46. <https://doi.org/10.3390/jof4020046>
4. Patel A, Kaur H, Xess I, Michael JS, Savio J, Rudramurthy S, Singh R, Shastri P, Umabala P, Sardana R, Kindo A (2020) A multicentre observational study on the epidemiology, risk factors, management and outcomes of mucormycosis in India. *Clin Microbiol Infect* 26(7):944–e9
5. Pal R, Singh B, Bhadada S, Banerjee M, Bhogal R, Hage N, Kumar A (2021) COVID-19-associated mucormycosis: an updated systematic review of literature. *Mycoses* 00:1–8
6. Singh AK, Singh R, Joshi SR, Misra A (2021) Mucormycosis in COVID-19: A systematic review of cases reported worldwide and in India. *Diabetes Metab Syndr*. <https://doi.org/10.1016/j.dsx.2021.05.019>
7. Sen M, Lahane S, Lahane TP, Parekh R, Honavar SG (2021) Mucor in a Viral Land: a tale of two pathogens. *Indian J Ophthalmol* 69:244–252
8. ManeshA JohnAO, Mathew B et al (2016) Posaconazole: an emerging therapeutic option for invasive rhino-orbital-cerebral mucormycosis. *Mycoses* 59:765–767
9. Sen M, Honavar SG, Bansal R et al (2021) Epidemiology, clinical profile, management, and outcome of COVID 19 associated rhino orbital cerebral mucormycosis in 2826 patients in India – collaborative OPAI IJO study on mucormycosis in COVID 19 (COSMIC), report 1. *Indian J Ophthalmol* 69:1670–1692
10. John TM, Jacob CN, Kontoyiannis DP (2021) When Uncontrolled diabetes mellitus and severe COVID-19 Converge: the perfect storm for mucormycosis. *J Fungi* 7(4):298. <https://doi.org/10.3390/jof7040298>
11. Moorthy A, Gaikwad R, Krishna S et al (2021) SARS-CoV-2, uncontrolled diabetes and corticosteroids-an unholy trinity in invasive fungal infections of the maxillofacial region? A retrospective, multi centric analysis. *J Maxillofac Oral Surg* 6:1–8
12. Hosseini SM, Borghei P (2005) Rhinocerebral mucormycosis: pathways of spread. *Eur Arch Otorhinolaryngol* 262:932–938
13. Cornely OA, Alastruey-Izquierdo A, Arenz D et al (2019) Mucormycosis ECMM MSG Global Guideline Writing Group. Global guideline for the diagnosis and management of mucormycosis: an initiative of the European Confederation of Medical Mycology in cooperation with the Mycoses Study Group Education and Research Consortium. *Lancet Infect Dis* 19(12):e405–e421. [https://doi.org/10.1016/S1473-3099\(19\)30312-3](https://doi.org/10.1016/S1473-3099(19)30312-3)
14. Lackner M, Caramalho R, Lass-Flörl C (2014) Laboratory diagnosis of mucormycosis: current status and future perspectives. *Future Microbiol* 9(5):683–695. <https://doi.org/10.2217/fmb.14.23>
15. Dave TV, Gopinathan Nair A, Hegde R et al (2021) Clinical presentations, management and outcomes of rhino-orbital-cerebral mucormycosis (ROCM) following COVID-19: a multi-centric study. *Ophthalmic Plast Reconstr Surg*. <https://doi.org/10.1097/iop.0000000000002030>

Publisher's Note Springer Nature remains neutral with regard to jurisdictional claims in published maps and institutional affiliations.

Springer Nature or its licensor (e.g. a society or other partner) holds exclusive rights to this article under a publishing agreement with the author(s) or other rightsholder(s); author self-archiving of the accepted manuscript version of this article is solely governed by the terms of such publishing agreement and applicable law.