

Reduced Prefrontal Hemodynamic Response in Pediatric Obsessive–Compulsive Disorder as Measured by Near-Infrared Spectroscopy

Toyosaku Ota · Junzo Iida · Masayuki Sawada · Yuko Suehiro · Kazuhiko Yamamuro · Hiroki Matsuura · Shohei Tanaka · Naoko Kishimoto · Hideki Negoro · Toshifumi Kishimoto

Published online: 26 July 2012
© Springer Science+Business Media, LLC 2012

Abstract Recent developments in near-infrared spectroscopy (NIRS) have enabled non-invasive clarification of brain functions in psychiatric disorders. Functional neuroimaging studies of patients with obsessive–compulsive disorder (OCD) have suggested that the frontal cortex and subcortical structures may play a role in the pathophysiology of the disorder. Twelve treatment-naïve children with OCD and 12 age- and sex-matched healthy control subjects participated in the present study after giving consent. The relative concentrations of oxyhemoglobin (oxy-Hb) were measured with prefrontal probes every 0.1 s during the Stroop color-word task, using 24-channel NIRS machines. During the Stroop color-word task, the oxy-Hb changes in the OCD group were significantly smaller than those in the control group in the prefrontal cortex, especially in the frontopolar cortex. The present study suggests that children with OCD have reduced prefrontal hemodynamic response as measured by NIRS.

Keywords Pediatric obsessive–compulsive disorder · Near-infrared spectroscopy · Functional neuroimaging study · Prefrontal hemodynamic response

Introduction

Recent functional neuroimaging studies of patients with obsessive–compulsive disorder (OCD) have suggested that the frontal cortex and subcortical structures may play a role in

T. Ota (✉) · Y. Suehiro · K. Yamamuro · H. Matsuura · S. Tanaka · N. Kishimoto · T. Kishimoto
Department of Psychiatry, Nara Medical University, 840 Shijyou-cho, Kashihara-shi 634-8522, Nara,
Japan
e-mail: toyosaku@naramed-u.ac.jp

J. Iida
Faculty of Nursing, Nara Medical University, Kashihara-shi, Japan

M. Sawada
Department of Psychiatry, Hannan Hospital, Sakai-shi, Japan

H. Negoro
Department of Education, Nara University of Education, Nara-shi, Japan

the pathophysiology of the disorder. Studies of OCD patients using single photon emission computed tomography (SPECT) have suggested dysfunction of the orbitofrontal cortex and the caudate nucleus [1, 2]. Each study reported increased and/or decreased activity in local regions such as the anterior cingulate cortex, the orbitofrontal cortex and the caudate nucleus. Several studies of OCD patients using positron emission tomography (PET) have identified abnormally high functional activity in local regions such as the orbitofrontal cortex, the anterior cingulate cortex, and the caudate nucleus [3, 4]. Menzies et al. [5] performed a meta-analysis of functional magnetic resonance imaging (fMRI) findings and reported consistent abnormalities in orbitofronto-striatal and other additional areas in OCD patients. It has been postulated that the cortico-striato-thalamo-cortical circuit mediates the symptomatic expression of OCD [6]. Thus, it is possible that OCD patients have differential prefrontal hemodynamic response.

However, functional brain imaging methodologies, such as PET, SPECT and fMRI, have the disadvantage of requiring large apparatuses, which prevents their use in a bedside setting for diagnostic and treatment purposes. Furthermore, these functional brain imaging methodologies do not offer high time resolution. By contrast, multi-channel near-infrared spectroscopy (NIRS) systems have recently been developed to allow non-invasive and bedside functional mapping of the cerebral cortex, with high time resolution [7–9]. Additionally, functional studies of pediatric OCD populations with SPECT and PET are rare owing to restrictions in the use of radioactive material in young subjects. Recently, results of several fMRI studies that do not entail the use of radioactive materials have become available [10–12].

NIRS is a method that enables functional imaging of brain activity [13]. It measures changes in the concentration of oxy-hemoglobin (oxy-Hb) and deoxy-hemoglobin (deoxy-Hb), as well as the changes in the redox state of cytochrome-c-oxidase by their different specific spectra in the near-infrared range between 700 and 1,000 nm. Due to neurovascular coupling [14, 15], brain activation leads to an increase in cerebral blood flow without a proportionate increase in oxygen consumption, and, consequently, to an increase in the concentration of oxy-Hb and a decrease in the concentration of deoxy-Hb [13]. NIRS is a neuroimaging modality that, for the following reasons is especially suitable for psychiatric patients [16]. First, because NIRS is relatively insensitive to motion artifact, it can be applied to experiments that might cause some motion of the subjects such as vocalization. Second, the subject can be examined in a natural sitting position, without any surrounding distraction. Third, the cost is much lower than other neuroimaging modalities and the set-up is very easy. Fourth, the high temporal resolution of NIRS is useful in characterizing the time course of prefrontal activity of psychiatric disorders [17, 18]. Accordingly, NIRS has been used to assess brain functions in many psychiatric disorders, including schizophrenia, bipolar disorder, depression, dementia, post traumatic stress disorder, and pervasive developmental disorders [16–23].

Recent developments in NIRS have enabled non-invasive clarification of brain functions in pediatric psychiatric disorders. For example, in pediatric attention-deficit/hyperactivity disorder (ADHD), reduced prefrontal hemodynamic response has been reported as measured by NIRS. Negoro et al. [24] examined reduced prefrontal hemodynamic response in ADHD children as measured by NIRS and determined cerebral hemodynamic changes in response to the Stroop color-word task in 20 children with ADHD and 20 healthy age- and sex-matched controls. They found that the oxy-Hb changes in the control group were significantly larger than those in the ADHD group in the inferior prefrontal cortex during the Stroop color-word task. Schroeter et al. [25] examined hemodynamic responses during incongruent, congruent, and neutral trials of the Stroop task using NIRS in 14 adult healthy

controls and reported that the hemodynamic response was stronger during incongruent trials compared with congruent and neutral trials of the Stroop task in the lateral prefrontal cortex bilaterally. Thus, the stronger hemodynamic response was interpreted as stronger brain activation during incongruent trials of the Stroop task because of interference.

To our knowledge, however, there are no reports on prefrontal hemodynamic response in pediatric OCD patients as measured by NIRS. Based on previous studies using other neuroimaging techniques that showed dysfunction of the prefrontal cortex, we hypothesized that children with OCD have reduced prefrontal hemodynamic response as measured by NIRS. Thus, in the present study, we used multi-channel NIRS machines to examine the characteristics of prefrontal cerebral blood volume changes during the Stroop color-word task in pediatric OCD patients and in age- and sex-matched control subjects.

Methods

Subjects

Twelve subjects (6 boys and 6 girls), aged 9–14 years and diagnosed with OCD according to DSM-IV-TR [26], were compared with 12 age-, sex-, and intelligence quotient (IQ)-matched healthy control subjects (6 boys and 6 girls), aged 10–14 years (Table 1).

The subjects with OCD, who had no history of previous psychiatric disorder treatment, consulted one of the experienced pediatric psychiatrists at the Department of Psychiatry of Nara Medical University. The subjects with OCD underwent a standard clinical assessment comprising a psychiatric evaluation, a semi-structured diagnostic interview (the Kiddie Schedule for Affective Disorders and Schizophrenia for School-Age Children-Present and Lifetime version (K-SADS-PL) [27], and a medical history by the experienced pediatric psychiatrist. Two experienced pediatric psychiatrists confirmed the diagnosis of OCD according to DSM-IV-TR [26]. Intellectual level was assessed with the Wechsler Intelligence Scale for Children—Third Edition by the psychologist, and patients whose full scale

Table 1 Characteristics of the subjects

	OCD mean (SD)	Control mean (SD)	<i>P</i> value
Number [sex ratio: JVTF]	12 [6:6]	12 [6:6]	1.00
Age (years)	11.58 (2.07)	11.42 (1.50)	0.82
Age of onset (years)	11.08 (2.15)		
Duration of illness (months)	7.33 (5.07)		
FIQ (WISC-III)	95.25 (6.97)	94.50 (7.14)	0.80
CY-BOCS	22.08 (4.87)		
SCWC-1	48.92 (8.02)	47.75 (6.33)	0.70
SCWC-2	46.17 (7.95)	44.58 (7.96)	0.63
SCWC-3	44.75 (8.01)	44.58 (8.30)	0.96

Group differences tested with *t* test

OCD obsessive–compulsive disorder, *M* male, *F* female, *FIQ (WISC-III)* full scale IQ score of the Wechsler Intelligence Scale for Children-Third Edition, *CY-BOCS* Children’s Yale-Brown obsessive–compulsive scale, *SCWC-1* Stroop color-word task number of correct answers first time, *SCWC-2* Stroop color-word task number of correct answers second time, *SCWC-3* Stroop color-word task number of correct answers third time

IQ (FIQ) scores were below 70 were excluded. Patients who presented a comorbid Axis I diagnosis, a neurological disorder, a head injury, a serious medical condition or a history of substance abuse/dependence were excluded; two patients with chronic tic disorder and two patients with attention-deficit/hyperactivity disorder were excluded. Finally, 12 subjects with OCD who had no previous medication were enrolled in the present study.

Healthy control subjects were recruited from local elementary schools and junior high schools. They also underwent a standard clinical assessment comprising a psychiatric evaluation, a semi-structured diagnostic interview (K-SADS-PL), and a medical history by the experienced pediatric psychiatrist. Intellectual level was assessed with the Wechsler Intelligence Scale for Children—Third Edition by the psychologist. Finally, 12 healthy control subjects, who did not have confirmed OCD and who had no current or past history of psychiatric or neurological disorder, were enrolled in the present study as well.

All subjects were right-handed and Japanese. Ethical approval for the present study was obtained through the Nara Medical University. Written informed consent was obtained from all subjects and/or their parents before the study.

Assessment of OCD Symptoms

The Children's Yale-Brown Obsessive–Compulsive Scale (CY-BOCS) [28] was used to evaluate OCD symptoms in OCD children. The CY-BOCS is a well-known 10-item semi-structured clinician-rated instrument and is designed to assess current OCD symptoms and severity. Obsessions and compulsions are each rated using a five-point scale (score ranging from 0 to 4) assessing multiple domains related to OCD symptom severity, including time, interference, distress, resistance, and control. Consequently, the CY-BOCS yields a total obsession score (0–20), a total compulsion score (0–20), and a combined total score (0–40), with higher scores indicating increasing symptom severity. The CY-BOCS has adequate convergent and divergent validity [29, 30].

OCD subjects underwent assessment for CY-BOCS (Table 1) at the same day that they were measured by NIRS. As shown in Table 1, the mean CY-BOCS score was 22.08 (SD, 4.87), ranging from 13 to 28. The factor analysis by Leckman et al. [31] is utilized; the individual symptom subtype were contamination and cleaning (50.0 %, $n = 6$), obsessions and checking (41.7 %, $n = 5$), symmetry and ordering (8.3 %, $n = 1$), with none exhibiting hoarding.

The Stroop Color-Word Task

The traditional Stroop task was combined with the word reading task, incongruent color naming task and the color naming task. However, we reproduced the Stroop task according to the method previously described [32]. The Stroop task consisted of two pages stapled together; each page had 100 items in five columns of 20 items. Items on the first page were the color words RED, GREEN and BLUE in black ink. Items on the second page were the words RED, GREEN and BLUE printed in red, green or blue ink, with the limitation that the word and ink could not match. On the two pages, the items were randomly distributed, except that no item within a column could follow itself.

Before the task, examiners instructed subjects as follows: “These are tests of how quickly you can read the words on the first page, and say the colors of the words on the second page. After we say ‘begin,’ you are to read down the columns, starting with the first one, saying the words/colors to yourself as quickly as you can. After you finish the first column, go on to the next and so on. After you have read the paper for 45 s, we will turn the page. Then you will read the turned paper again. And we will repeat this process with you”.

We combined these two pages and made the Stroop color-word task simple and easy because the subjects were school-age children. The Stroop color-word task consisted of the first page (p1) and the second page (p2). The entire Stroop color-word task sequence consisted of a 45-s p1 task, a 45-s p2 task (the color-word task first time), a 45-s p1 task, a 45-s p2 task (the color-word task second time), a 45-s p1 task, a 45-s p2 task (the color-word task third time), and a 45-s p1 task. We designated the 45-s p1 task as the baseline task. We also counted the number of correct answers each time. We named them as follows: Stroop color-word task number of correct answers first time (SCWC-1), second time (SCWC-2) and third time (SCWC-3). Examiners who were blind to diagnoses measured the Stroop color-word task. As shown in Table 1, there were no significant differences in the SCWC-1, SCWC-2 and SCWC-3 scores of the two groups.

The Stroop task designed for this study was not the traditional Stroop task. We made the Stroop color-word task simple and easy because the subjects were school-age children. Furthermore, the word reading task and incongruent color naming task were adopted with the exception of the color naming task because the NIRS study required two tasks (baseline task and activation task). Negoro et al. [24] suggested that suitable brain activation in healthy children was obtained by using the word reading task and incongruent color naming task.

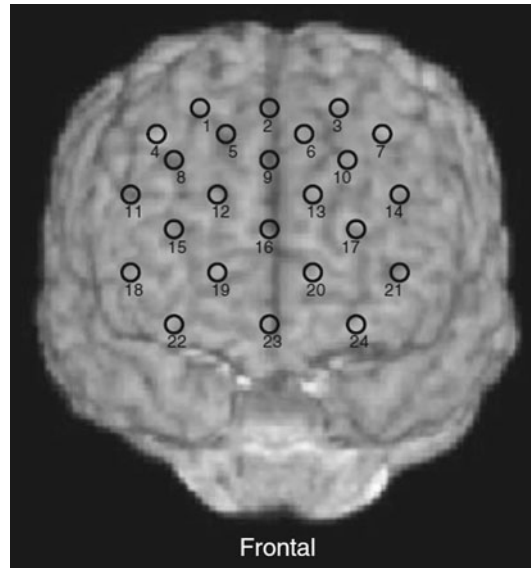
The Stroop color-word task was utilized by the following reasons. First, the inferior frontal gyrus has been described as one of the regions most strongly related to Stroop interference [33]. Second, in the NIRS study that the same task was used, Negoro et al. [24] concluded that suitable prefrontal brain activation in healthy children was recognized by using the Stroop color-word task.

NIRS Measurements

The oxy-Hb increase and deoxy-Hb decrease in NIRS have been shown to reflect cortical activation. In animal studies, oxy-Hb is the most sensitive indicator of regional cerebral blood flow because the direction of change in deoxy-Hb is determined by the degree of changes in venous blood oxygenation and volume [34]. Therefore, we decided to focus on changes in oxy-Hb. In this study, oxy-Hb was measured with a 24-channel NIRS machine (Hitachi ETG-100, Hitachi Medical Corporation, Tokyo, Japan) at two wavelengths of near-infrared light (760 and 840 nm), the absorption of which was measured. Oxy-Hb was calculated as previously described [35]. The inter-probe intervals of the machine were 3.0 cm, and it was determined that the machine measures points 2–3 cm beneath the scalp, i.e., the surface of the cerebral cortices [20, 36].

In a natural sitting position, the subjects were measured by NIRS. The NIRS probes were placed on the subject's prefrontal regions, and arranged to measure the relative concentrations of Hb changes at 24 measurement points in an 8×8 cm area, with the lowest probes positioned along the Fp1–Fp2 line according to the international 10/20 system used in electroencephalography. The correspondence of the probe positions and the measurement points on the cerebral cortex were confirmed by superimposition of the probe positions on an MRI of a three-dimensionally reconstructed cerebral cortex of a representative subject in the control group (Fig. 1). The absorption of near-infrared light was measured with a time resolution of 0.1 s. The data obtained were analyzed with the “integral mode”: the pre-task baseline was determined as the mean across 10 s just before the task period; the post-task baseline was determined as the mean across 25 s after the task period; and linear fitting was performed on the data between the two baselines. Moving average methods were used to exclude short-term motion artifact in the analyzed data (moving average window, 5 s).

Fig. 1 Cortical projection of near-infrared spectroscopy (NIRS) measurement points. The points were mapped onto anatomical frontal lobes using MRIcro software (MRIcro: developed by Dr. Chris Rorden, available at <http://www.mricro.com>). Numbers denote channel numbers for points of measurement



We tried to exclude motion artifacts by closely monitoring artifact-evoking body movements, such as neck movements, strong biting, and blinking (identified as most influential in the preliminary artifact-evoking study), and by instructing the subjects to avoid these movements during the NIRS measurements. Examiners who were blind to diagnoses measured NIRS.

Statistical Analyses

Oxy-Hb changes were compared between each of the two groups with Student's *t*-tests using the grand average waveforms every 0.1 s in each channel. This analysis enabled more detailed comparison of oxy-Hb changes along the time course of the task. Data analyses were conducted using MATLAB 6.5.2 (Mathworks, Natick, MA, USA) and Topo Signal Processing type-G version 2.05 (Hitachi Medical Corporation, Tokyo, Japan). OT-A4 version 1.63 K (Hitachi Medical Corporation, Tokyo, Japan) was used for the overlap display of the grand average waveforms in both groups in Fig. 2 and was also used to calculate mean oxy-Hb measurements in Table 3. Since we performed 24 paired *t* tests, the correction for multiple comparisons was made using the false discovery rate (FDR) (two-tailed; we set the value of *q* specifying the maximum FDR to 0.05, so that there are no more than 5 % false positives on average [37]). PASW Statistics 18.0 J for Windows (SPSS, Tokyo, Japan) was used for statistical analysis.

Results

Correlation Between the Stroop Task and Characteristics of the Subjects

Spearman's ρ correlations between the scores of SCWC and age, FIQ, and the scores of CY-BOCS can be seen in Table 2. In both groups, there are positive correlations between

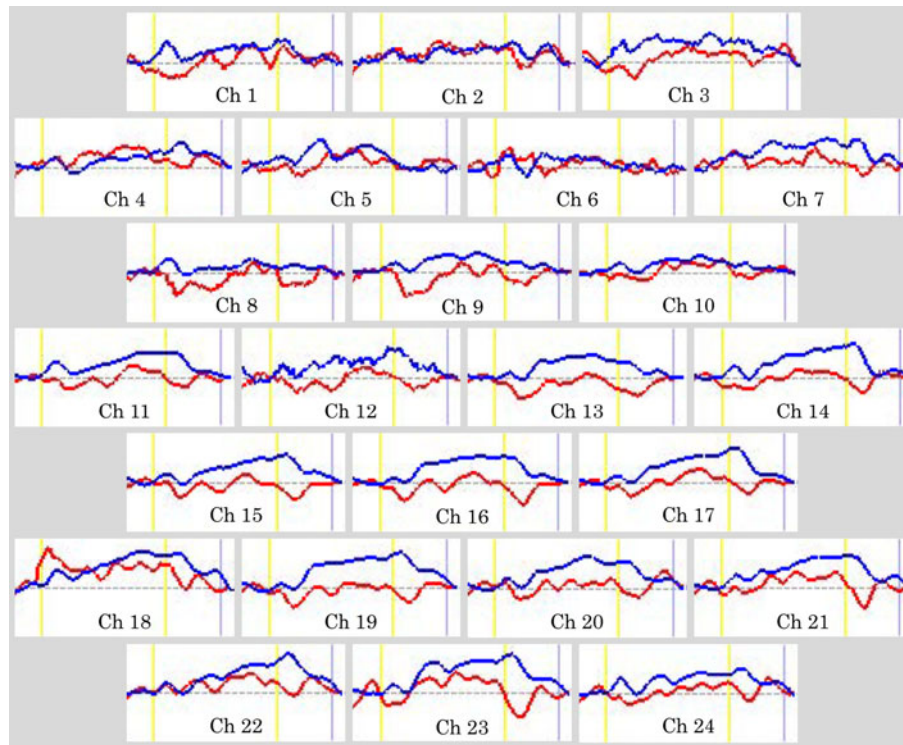


Fig. 2 Grand average waveforms of oxyhemoglobin (oxy-Hb) concentration changes during the Stroop color-word task in both groups. The grand average waveforms of oxy-Hb in the obsessive-compulsive disorder (OCD) group are the red lines, and the grand average waveforms of oxy-Hb in the control group are the blue lines. The task is being performed between the yellow lines

Table 2 Correlations between Stroop task and characteristics of the subjects

	OCD			Control		
	SCWC-1	SCWC-2	SCWC-3	SCWC-1	SCWC-2	SCWC-3
Age	0.694**	0.635*	0.804***	0.648*	0.637*	0.639*
FIQ (WISC-III)	-0.126	-0.091	0.105	-0.057	-0.159	-0.201
CY-BOCS	-0.456	-0.477	-0.464			

Correlations between the Stroop task and characteristics of the subjects tested with Spearman's correlation test

OCD obsessive-compulsive disorder, *FIQ (WISC-III)* full IQ score of the Wechsler Intelligence Scale for Children-Third Edition, *CY-BOCS* Children's Yale-Brown obsessive-compulsive scale, *SCWC-1* Stroop color-word task number of correct answers first time, *SCWC-2* Stroop color-word task number of correct answers second time, *SCWC-3* Stroop color-word task number of correct answers third time

* $P < 0.05$, ** $P < 0.02$, *** $P < 0.01$

the scores of SCWC and age and and no correlations between the scores of SCWC and FIQ. In the OCD group, there are no correlations between the scores of SCWC and the scores of CY-BOCS.

Table 3 Difference of mean oxyhemoglobin (oxy-Hb) measurements between task and post-task periods in 24 channels

	OCD (mMmm)		Control (niMmm)		Student's <i>t</i> test	FDR correction
	Mean	SD	Mean	SD		
Chi	0.0051	0.0654	0.0337	0.0421	NS	NS
Ch2	0.0305	0.0393	0.0315	0.0527	NS	NS
Ch3	0.0120	0.0621	0.0527	0.0420	†	NS
Ch4	0.0286	0.0692	0.0278	0.0472	NS	NS
Cho	0.0103	0.0455	0.0266	0.0433	NS	NS
Ch6	0.0090	0.0527	0.0114	0.0542	NS	NS
Ch7	0.0130	0.0486	0.0513	0.0519	NS	NS
Ch8	-0.0182	0.0428	0.0166	0.0404	†	NS
Ch9	-0.0148	0.0612	0.0282	0.0195	†	NS
Chl0	0.0048	0.0312	0.0243	0.0358	NS	NS
Chl1	-0.0048	0.0262	0.0412	0.0516	*	NS
Chl2	-0.0091	0.0417	0.0399	0.0563	*	NS
Chl3	-0.0228	0.0428	0.0338	0.0334	**	***
Chl4	-0.0056	0.0358	0.0485	0.0499	*	NS
Chl5	-0.0128	0.0350	0.0392	0.0352	**	***
Chl6	-0.0136	0.0333	0.0441	0.0496	**	***
Chl7	-0.0016	0.0244	0.0488	0.0409	**	***
Chl8	0.0490	0.1337	0.0653	0.0846	NS	NS
Chl9	-0.0111	0.0672	0.0572	0.0678	*	NS
Ch20	0.0057	0.0660	0.0506	0.1022	NS	NS
Ch21	0.0074	0.0840	0.0547	0.0422	NS	NS
Ch22	0.0227	0.0674	0.0526	0.0677	NS	NS
Ch23	0.0055	0.0513	0.0622	0.0689	*	NS
Ch24	0.0051	0.0340	0.0397	0.0348	*	NS

Group differences tested with t-test and false discovery rate (FDR) correction

† $P < 0.1$, * $P < 0.05$, ** $P < 0.01$, *** $P < \text{FDR-corrected } P$

NIRS Data of the Subjects During the Stroop Color-Word Task

The grand average waveforms of oxy-Hb concentration changes during the Stroop color-word task in both groups can be seen in Fig. 2. The grand average waveforms of oxy-Hb concentration change in the control group increased during the task period. On the other hand, those of the OCD group did not change much. The difference of mean oxy-Hb measurements between task and post-task periods in the 24 channels can be seen in Table 3. Between task and post-task periods, the mean oxy-Hb difference of the OCD group was significantly smaller than that of the control group in channels 13, 15, 16, and 17 (FDR-corrected P : 0.0021–0.0083). Topographic presentation of the t -value of oxy-Hb comparison between the control group and the OCD group during the Stroop color task can be seen in Fig. 3. The oxy-Hb changes in the control group were significantly greater than those in the OCD group during the task period in the prefrontal cortex.

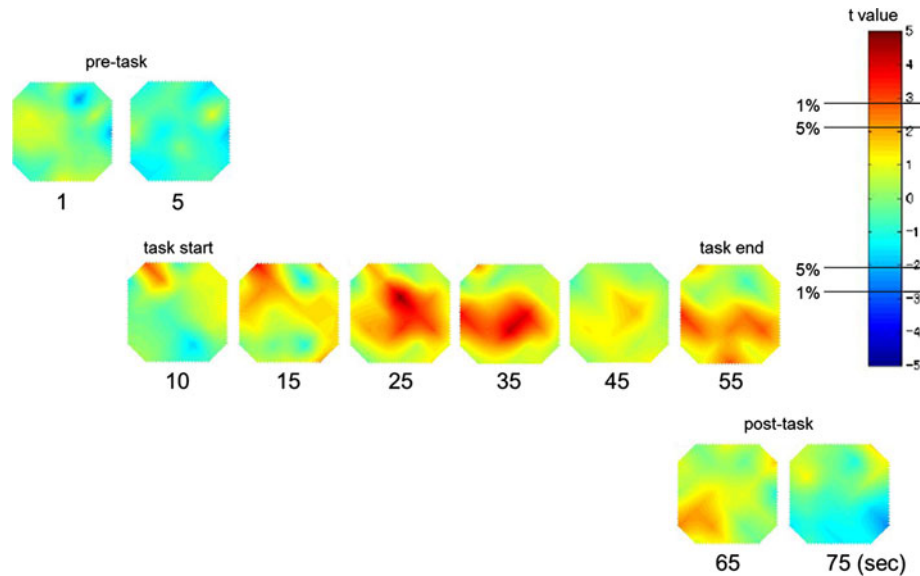


Fig. 3 Topographic presentation of the t value of the oxyhemoglobin (oxy-Hb) comparison between the control group and the obsessive-compulsive disorder (OCD) group during the Stroop color-word task. The t values of oxy-Hb for the control and OCD groups are presented as a topographic map along the time course of the task (from *top to bottom*). The *red*, *green*, and *blue* areas in the topographs indicate positive, zero, and negative t values, with ± 2.8 and ± 2.1 for 1 and 5 % statistical significance levels, respectively

Discussion

To our knowledge, this is the first NIRS study that examined prefrontal hemodynamic response in pediatric OCD. In the present study, it was shown that oxy-Hb changes in 12 treatment-naïve OCD children during the Stroop color-word task were significantly smaller than those in 12 healthy children in the prefrontal cortex. Therefore, the present study supported our hypothesis sufficiently; the present findings are consistent with the proposed prefrontal dysfunction in pediatric OCD identified by other imaging modalities, such as fMRI and SPECT. The first fMRI study in pediatric OCD [10] studied 10 boys with OCD after treatment and nine healthy controls. Event-related fMRI was used to compare brain activation patterns during three different tasks of inhibitory control, i.e., a stop task, a motor Stroop task, and a switch task. No significant behavioral differences were found between OCD patients and healthy controls in any of the tasks. The fMRI data revealed that in pediatric OCD subjects compared with healthy controls fronto-striatal regions were hypoactive during the stop task, whereas the Stroop and switch task data revealed not only frontal but also temporoparietal and cerebellar regions of hypoactivity. Furthermore, it is interesting to note that task-specific abnormalities in pediatric OCD are not limited to fronto-striatal structures but extend to frontotemporoparietal and frontocerebellar circuits. Lazaro et al. [11] reported that drug-naïve pediatric OCD patients had increased activity in bilateral middle frontal gyri compared with controls in the fMRI study. In another fMRI study, Britton et al. [12] reported that the pediatric OCD group exhibited less left inferior frontal gyrus/BA47 activation in the set-shifting contrast compared with the healthy comparison group. In a resting state SPECT study, increased regional cerebral blood flow

in bilateral dorsolateral prefrontal cortex, anterior cingulate cortex, and caudate nucleus was reported in pediatric OCD patients versus healthy controls [38].

At four channels (Ch 13, Ch 15, Ch 16, Ch 17), OCD children were associated with significantly smaller oxy-Hb changes than healthy children in the present study. Those channels were nearly localized in the frontopolar regions (also known as the anterior prefrontal cortex) (BA 10), which has been relatively less recognized in functional neuroimaging studies. Frontopolar regions might provide higher levels of control to coordinate ventrolateral and dorsolateral functions in order to maximize task performance or to achieve goals [39–41]. Burgess et al. [42] noted that rostral prefrontal cortex is identified as subserving a system that biases the relative influence of stimulus-oriented and stimulus-independent thought. This cognitive control function is used in a wide range of situations critical to competent human behavior in everyday life. Additionally, it was suggested that dysfunction of this cognitive control system might induce the symptoms linked to unwanted (intrusive) thoughts and be associated with psychiatric disorders [42]. Because OCD is a disorder marked by intrusive thoughts/images and/or compulsions, the frontopolar cortex might be associated with the pathophysiology of OCD.

In the present study, we used the Stroop color-word task because the inferior frontal gyrus has been described as one of the regions most strongly related to Stroop interference [33]. Negoro et al. [24] examined the brain activation in 20 healthy children during the Stroop color-word task as measured by NIRS. In that study, oxy-Hb changes indicated specific activation in the inferior prefrontal cortex, and there were positive correlations between the Stroop color-word task number of correct answers (SCWC) and age. They concluded that prefrontal brain activation in healthy children during the Stroop color-word task is similar to healthy adults as measured by NIRS [25]. Similar results were obtained in the present study. In both groups, there were positive correlations between the scores of SCWC and age, and there were no correlations between the scores of SCWC and FIQ. These data suggest that our Stroop color-word task may be a useful task for children.

In the present study, there were no significant differences in the SCWC-1, SCWC-2 and SCWC-3 of the two groups. It was shown that oxy-Hb changes in 12 treatment-naïve OCD children during the Stroop color-word task were significantly smaller than those in 12 healthy children in the prefrontal cortex. In the previous fMRI study, it was reported that OCD patients had different activation patterns in the dorsolateral prefrontal cortex, the anterior cingulate cortex, and the caudate nucleus during the Stroop task compared with the healthy controls despite similar task performance [43]. Woolley et al. [10] suggested that there was a discrepancy between the activation and task performance in pediatric OCD subjects compared with healthy controls.

Potential limitations of the present study should also be taken into consideration. First, NIRS has disadvantages compared with other methodologies [8], the main one being that it enables measurement of Hb concentration changes only as relative values, not as absolute values. We made a Stroop task that had the first page as the baseline task to overcome these potential problems. Furthermore, we measured Hb concentration changes from the activation task to the baseline task and performed the task three times to average potential accidental changes and prevent the subjects from becoming tired. The grand average waveforms of oxy-Hb concentration changes in the OCD group do not show a regional cerebral blood flow decrease during the activation task or a difference between the blood flows during the baseline and activation tasks. Second, spatial resolution for detecting hemodynamic responses from the scalp surface using NIRS is lower than those for fMRI, SPECT and PET. Although it has been suggested that children with OCD may have specific reduced hemodynamic response at the frontopolar cortex, the present findings

indicate that children with OCD have reduced hemodynamic response at the broader prefrontal cortex including dorsolateral prefrontal and orbitofrontal cortex as measured by NIRS. However, it is certainly significant that reduced prefrontal hemodynamic response in pediatric OCD can be shown by NIRS. Third, the sample size was small, although the 12 OCD children were treatment-naïve and none of them had comorbid psychiatric or neurological disorder. Future study is needed with a larger sample size.

In conclusion, to our knowledge this is the first NIRS study that examined reduced prefrontal hemodynamic response in pediatric OCD. The multi-channel NIRS systems may be a very useful measurement tool for assessing brain function, especially in children, because multi-channel NIRS systems can provide handy, non-invasive functional mapping of the cerebral cortex at the bedside with much shorter measurement times (about 5 min) than other functional brain imaging methodologies.

Summary

The purpose of the present study was to examine the prefrontal hemodynamic response in healthy children and in OCD children as measured by NIRS using the Stroop task. Twelve treatment-naïve children with OCD and 12 age- and sex-matched healthy control subjects participated in the study. The relative concentrations of oxy-Hb were measured with prefrontal probes every 0.1 s during the Stroop color-word task, using 24-channel NIRS machines. During the Stroop color-word task, the oxy-Hb changes in the OCD group were significantly smaller than those in the control group in the prefrontal cortex, especially in the frontopolar cortex, dysfunction of which might induce the symptoms linked to unwanted (intrusive) thoughts and be associated with psychiatric disorders. The Stroop color-word task during NIRS may be a useful method for assessing prefrontal brain differential hemodynamic response in OCD children. Finally, multi-channel NIRS systems are attractive for assessing brain function, especially for children, because they can provide handy, non-invasive functional mapping of the cerebral cortex at the bedside with much shorter measurement times (about 5 min) than other functional brain imaging methodologies.

Acknowledgments We wish to thank the participating patients and control subjects for their valuable help. The authors would also like to thank Hitachi Medical Corporation for the ETG-100 equipment and skilled technical and methodical support.

References

1. Machlin SR, Harris GJ, Pearlson GD, Hoehn-Saric R, Jeffery P, Camargo EE (1991) Elevated medial-frontal cerebral blood flow in obsessive-compulsive patients: a SPECT study. *Am J Psychiatry* 148:1240–1242
2. Busatto GF, Zamignani DR, Buchpiguel CA, Garrido GE, Glabus MF, Rocha ET et al (2000) A voxel-based investigation of regional cerebral blood flow abnormalities in obsessive-compulsive disorder using single photon emission computed tomography (SPECT). *Psychiatry Res* 99:15–27
3. Baxter LR Jr, Phelps ME, Mazziotta JC, Guze BH, Schwartz JM, Selin CE (1987) Local cerebral glucose metabolic rates in obsessive-compulsive disorder. A comparison with rates in unipolar depression and in normal controls. *Arch Gen Psychiatry* 44:211–218
4. Swedo SE, Schapiro MB, Grady CL, Cheslow DL, Leonard HL, Kumar A et al (1989) Cerebral glucose metabolism in childhood-onset obsessive-compulsive disorder. *Arch Gen Psychiatry* 46:518–523

5. Menzies L, Chamberlain SR, Laird AR, Thelen SM, Sahakian BJ, Bullmore ET (2008) Integrating evidence from neuroimaging and neuropsychological studies of obsessive-compulsive disorder: the orbitofronto-striatal model revisited. *Neurosci Biobehav Rev* 32:525–549
6. Saxena S (2003) Neuroimaging and the pathophysiology of obsessive compulsive disorder. In: Fu C, Senior C, Russell T, Weinberger D, Murray R (eds) *Neuroimaging in psychiatry*. Martin Dunitz, London, pp 191–224
7. Maki A, Yamashita Y, Ito Y, Watanabe E, Mayanagi Y, Koizumi H (1995) Spatial and temporal analysis of human motor activity using non-invasive NIR topography. *Med Phys* 22:1997–2005
8. Yamashita Y, Maki A, Koizumi H (1996) Near-infrared topographic measurement system: imaging of absorbers localized in a scattering medium. *Rev Sci Instrum* 67:730–732
9. Koizumi H, Yamashita Y, Maki A, Yamamoto T, Ito Y, Itagaki H et al (1999) Higher-order brain function analysis by trans-cranial dynamic near-infrared spectroscopy imaging. *J Biomed Opt* 4:403–413
10. Woolley J, Heyman I, Brammer M, Frampton I, McGuire PK, Rubia K (2008) Brain activation in paediatric obsessive-compulsive disorder during tasks of inhibitory control. *Br J Psychiatry* 192:25–31
11. Lázaro L, Caldú X, Junqué C, Bargalló N, Andrés S, Morer A et al (2008) Cerebral activation in children and adolescents with obsessive-compulsive disorder before and after treatment: a functional MRI study. *J Psychiatr Res* 42:1051–1059
12. Britton JC, Rauch SL, Rosso IM, Killgore WD, Price LM, Ragan J et al (2010) Cognitive inflexibility and frontal-cortical activation in pediatric obsessive-compulsive disorder. *J Am Acad Child Adolesc Psychiatry* 49:944–953
13. Villringer A, Chance B (1997) Non-invasive optical spectroscopy and imaging of human brain function. *Trends Neurosci* 20:435–442
14. Gratton G, Goodman-Wood MR, Fabiani M (2001) Comparison of neuronal and hemodynamic measures of the brain response to visual stimulation: an optical imaging study. *Hum Brain Mapp* 13:13–25
15. Villringer A, Dirnagl U (1995) Coupling of brain activity and cerebral blood flow: basis of functional neuroimaging. *Cerebrovasc Brain Metab Rev* 7:240–276
16. Matsuo K, Kato T, Taneichi K, Matsumoto A, Ohtani T, Hamamoto T et al (2003) Activation of the prefrontal cortex to trauma-related stimuli measured by near-infrared spectroscopy in posttraumatic stress disorder due to terrorism. *Psychophysiology* 40:492–500
17. Kameyama M, Fukuda M, Yamagishi Y, Sato T, Uehara T, Ito M et al (2006) Frontal lobe function in bipolar disorder: a multichannel near-infrared spectroscopy study. *Neuroimage* 29:172–184
18. Suto T, Fukuda M, Ito M, Uehara T, Mikuni M (2004) Multichannel near-infrared spectroscopy in depression and schizophrenia: cognitive brain activation study. *Biol Psychiatry* 55:501–511
19. Fallgatter AJ, Roesler M, Sitzmann L, Heidrich A, Mueller TJ, Strik WK (1997) Loss of functional hemispheric asymmetry in Alzheimer's dementia assessed with near-infrared spectroscopy. *Brain Res Cogn Brain Res* 6:67–72
20. Hock C, Villringer K, Müller-Spahn F, Wenzel R, Heekeren H, Schuh-Hofer S et al (1997) Decrease in parietal cerebral hemoglobin oxygenation during performance of a verbal fluency task in patients with Alzheimer's disease monitored by means of near-infrared spectroscopy (NIRS)—correlation with simultaneous rCBF-PET measurements. *Brain Res* 755:293–303
21. Kubota Y, Toichi M, Shimizu M, Mason RA, Coconcea CM, Findling RL et al (2005) Prefrontal activation during verbal fluency tests in schizophrenia—a near-infrared spectroscopy (NIRS) study. *Schizophr Res* 77:65–73
22. Kuwabara H, Kasai K, Takizawa R, Kawakubo Y, Yamasue H, Rogers MA et al (2006) Decreased prefrontal activation during letter fluency task in adults with pervasive developmental disorders: a near-infrared spectroscopy study. *Behav Brain Res* 172:272–277
23. Shinba T, Nagano M, Kariya N, Ogawa K, Shinozaki T, Shimosato S et al (2004) Near-infrared spectroscopy analysis of frontal lobe dysfunction in schizophrenia. *Biol Psychiatry* 55:154–164
24. Negoro H, Sawada M, Iida J, Ota T, Tanaka S, Kishimoto T (2010) Prefrontal dysfunction in attention-deficit/hyperactivity disorder as measured by near-infrared spectroscopy. *Child Psychiatry Hum Dev* 41:193–203
25. Schroeter ML, Zysset S, Kupka T, Kruggel F, Yves von Cramon D (2002) Near-infrared spectroscopy can detect brain activity during a color-word matching Stroop task in an event-related design. *Hum Brain Mapp* 17:61–71
26. American Psychiatric Association (2000) *Diagnostic and statistical manual of mental disorders, 4th edn, text revision (DSM-IV-TR)*. American Psychiatric Association, Washington, DC
27. Kaufman J, Birmaher B, Brent D, Rao U, Flynn C, Moreci P et al (1997) Schedule for Affective Disorders and Schizophrenia for School-Age Children—Present and Lifetime Version (K-SADS-PL): initial reliability and validity data. *J Am Acad Child Adolesc Psychiatry* 36:980–988

28. Scahill L, Riddle MA, McSwiggan-Hardin M, Ort SI, King RA, Goodman WK et al (1997) Children's Yale-Brown Obsessive-Compulsive Scale: reliability and validity. *J Am Acad Child Adolesc Psychiatry* 36:844–852
29. Storch EA, Murphy TK, Adkins JW, Lewin AB, Geffken GR, Johns NB et al (2006) The Children's Yale-Brown Obsessive-Compulsive scale: psychometric properties of child- and parent-report formats. *J Anxiety Disord* 20:1–16
30. Yucelen AG, Rodopman-Arman A, Topcuoglu V, Yazgan MY, Fisek G (2006) Interrater reliability and clinical efficacy of Children's Yale-Brown Obsessive-Compulsive Scale in an outpatient setting. *Compr Psychiatry* 47:48–53
31. Leckman JF, Grice DE, Boardman J, Zhang H, Vitale A, Bondi C et al (1997) Symptoms of obsessive-compulsive disorder. *Am J Psychiatry* 154:911–917
32. Goldman CJ (1975) A group version of the Stroop color and word test. *J Pers Assess* 39:386–388
33. Laird AR, McMillan KM, Lancaster JL, Kochunov P, Turkeltaub PE, Pardo JV et al (2005) A comparison of label-based review and ALE meta-analysis in the Stroop task. *Hum Brain Mapp* 25:6–21
34. Hoshi Y, Kobayashi N, Tamura M (2001) Interpretation of near-infrared spectroscopy signals: a study with a newly developed perfused rat brain model. *J Appl Physiol* 90:1657–1662
35. Schweitzer JB, Faber TL, Grafton ST, Tune LE, Hoffman JM, Kilts CD (2000) Alterations in the functional anatomy of working memory in adult attention-deficit/hyperactivity disorder. *Am J Psychiatry* 157:278–280
36. Toronov V, Webb A, Choi JH, Wolf M, Michalos A, Gratton E et al (2001) Investigation of human brain hemodynamics by simultaneous near-infrared spectroscopy and functional magnetic resonance imaging. *Med Phys* 28:521–527
37. Singh AK, Dan I (2006) Exploring the false discovery rate in multichannel NIRS. *Neuroimage* 33:542–549
38. Diler RS, Kibar M, Avci A (2004) Pharmacotherapy and regional cerebral blood flow in children with obsessive compulsive disorder. *Yonsei Med J* 29:90–99
39. Koechlin E, Basso G, Pietrini P, Panzer S, Grafman J (1999) The role of the anterior prefrontal cortex in human cognition. *Nature* 399:148–151
40. Fletcher PC, Henson RN (2001) Frontal lobes and human memory: insights from functional neuroimaging. *Brain* 124:849–881
41. Braver TS, Bongiolatti SR (2002) The role of frontopolar cortex in subgoal processing during working memory. *Neuroimage* 15:523–536
42. Burgess PW, Simons JS, Dumontheil I, Gilbert SJ (2005) The gateway hypothesis of rostral prefrontal cortex (area 10) function. In: Duncan J, Phillips L, McLeod P (eds) *Measuring the mind: speed, control, and age*. Oxford University Press, Oxford, pp 217–248
43. Nakao T, Nakagawa A, Yoshiura T, Nakatani E, Nabeyama M, Yoshizato C et al (2005) A functional MRI comparison of patients with obsessive-compulsive disorder and normal controls during a Chinese character Stroop task. *Psychiatry Res* 139:101–114