



Yield of flow cytometry in addition to cytology for lymph node sampling in patients with incidental axillary adenopathy without a concurrent diagnosis of primary breast malignancy

Roberto Lo Gullo¹ · Christophe Cloutier Lambert² · Oscar Lin³ · Maxine S. Jochelson¹ · Donna D'Alessio¹

Received: 2 September 2021 / Accepted: 2 December 2021 / Published online: 11 January 2022
© The Author(s), under exclusive licence to Springer Science+Business Media, LLC, part of Springer Nature 2021

Abstract

Purpose Non-specific lymphadenopathy is increasingly being reported especially given the COVID-19 vaccination campaign and is a diagnostic dilemma especially in oncology patients. The purpose of this study was to evaluate the diagnostic accuracy and discordance rate between fine-needle aspiration (FNA) cytology and flow cytometry (FC) immunophenotyping in axillary FNA in patients with morphologically abnormal axillary lymph nodes on imaging and no concurrent diagnosis of primary breast malignancy.

Methods This retrospective study included 222 patients who underwent screening or diagnostic axillary ultrasound that yielded suspicious lymphadenopathy without concurrent or recent prior diagnosis of breast cancer and who had subsequent image-guided axillary FNA and FC. Diagnostic accuracy, sensitivity, specificity, and positive and negative predictive value (PPV and NPV) were reported for FNA with cytology alone, and FC alone, and in combination. Discordance rate between FNA cytology and FC was assessed. Discordant cases were evaluated with histology or clinical and imaging follow-up.

Results Diagnostic sensitivity, specificity, PPV, NPV, and diagnostic accuracy were 88%, 92%, 77%, 96%, and 91%, for FNA alone, 98%, 98%, 92%, 99%, and 98% for FC alone, and 100%, 92%, 79%, 100%, and 94% when combined. The overall discordance rate between FNA and FC was 7% (16/222). 7/16 (44%) patients with discordant results were diagnosed with lymphoma, while 9/16 (56%) patients with discordant results had benign findings.

Conclusion With a diagnostic accuracy of 91%, FNA with cytology is sufficient to screen patients with indeterminate and incidental lymphadenopathy. Flow cytometry could be initially deferred in patients with low pretest probability of lymphoma.

Keywords Non-specific lymphadenopathy · Cytology · Fine-needle aspiration · Flow cytometry · Lymphoma

Introduction

The diagnostic dilemma of non-specific lymphadenopathy is a common issue in clinical practice. For axillary lymphadenopathy, differential diagnoses include benign etiologies (e.g., mastitis, breast abscess, infected skin lesions, cat-scratch fever) as well as malignant etiologies, with lymphoma or metastatic breast cancer being the most common malignant etiologies [1–3]. Nevertheless, most cases of axillary lymphadenopathy are due to benign etiologies [2–4]. Routine vaccination such as influenza, measles, smallpox, anthrax, and Bacille Calmette-Guerin vaccination can elicit unilateral axillary lymphadenopathy [5, 6]. Most recently, data from COVID-19 vaccination suggest a higher immunogenic power of this vaccine, having shown higher rates of unilateral axillary lymphadenopathy [7, 8].

Roberto Lo Gullo and Christophe Cloutier Lambert are Co-first authors, Maxine S. Jochelson and Donna D'Alessio are Co-senior authors.

✉ Roberto Lo Gullo
logullo@mskcc.org

¹ Department of Radiology, Breast Imaging Service, Memorial Sloan Kettering Cancer Center, 300 E 66th Street, New York, NY 10065, USA

² Hôpital Maisonneuve-Rosemont, Montréal, Québec, Canada

³ Department of Pathology, Memorial Sloan Kettering Cancer Center, New York, NY 10065, USA

The first reports of subclinical unilateral axillary lymphadenopathy after COVID-19 vaccination were made by breast imagers and identified in women undergoing breast cancer screening [10–12]. The Society of Breast Imaging responded rapidly with guidelines and educational materials for radiologists, referring providers, and patients (13), although management is still mostly institution-dependent, ranging from “benign” assessment with no clinical follow-up, immediate additional diagnostic imaging, to short-interval follow-up until resolution or biopsy [10–18].

Unilateral axillary lymphadenopathy may present as a diagnostic dilemma especially in patients with cancer where it raises the concern for malignancy. When axillary lymphadenopathy persists, or no cause is evident, biopsy is considered the standard of care to rule out malignancy. Although most guidelines consider histology the gold standard for morphological diagnosis of lymphoma [9–12], since 2008, the World Health Organization (WHO) classification of lymphomas has based their diagnosis on morphology, immunophenotype, and molecular characteristics of lymphoid cells in the appropriate clinical setting rather than cellular architecture [13]. This has paved the way for the use of more minimally invasive, cost-effective, and accurate diagnostic techniques such as fine-needle aspiration (FNA) alone, or FNA with other ancillary diagnostic techniques, such as immunocytochemistry, flow cytometry, cytogenetics, or molecular techniques, i.e., fluorescence in situ hybridization (FISH), chromogenic in situ hybridization (CISH), and polymerase chain reaction (PCR) [14, 15].

Morphological findings of some lymphomas such as low-grade lymphoma can be very similar to the ones seen in a reactive lymph node, as both lesions are composed by a population of small lymphocytes, and the differences between the two entities can be difficult to identify in fixed specimens. The distinction between the two is primarily based on the recognition of an abnormal phenotype in the B- or T-cell population using ancillary diagnostic techniques. Of the ancillary diagnostic techniques, flow cytometry allows an accurate, reliable, and complete basic phenotype of lymphoid populations from limited cytology specimens to be determined, making it an ideal technique for a combined application with FNA to diagnose lymphoma; flow cytometry studies have a sensitivity above 95% in cases of low-grade lymphomas and approximately 60% in cases of large cell lymphomas. [16]. However, flow cytometry requires extra sampling, which is time consuming, may cause additional patient discomfort, and adds costs. Cost burden may be an issue especially given the increasing number of patients that may present with non-specific axillary lymphadenopathy in the setting of increasing COVID-19 vaccinations.

We hypothesized that FNA alone without ancillary techniques is sufficient to assess non-specific axillary

lymphadenopathy and can rule out lymphoproliferative disease. In this study we evaluated the diagnostic accuracy and discordance rate between FNA cytology and flow cytometry immunophenotyping in axillary FNA in patients with morphologically abnormal axillary lymph nodes on imaging and no concurrent diagnosis of primary breast malignancy.

Methods

Patients

This is a retrospective institutional review board-approved and Health Insurance Portability and Accountability Act-compliant study conducted at a tertiary cancer center. The need for written informed consent was waived.

We searched the Department of Radiology database for patients who underwent screening or diagnostic imaging (breast or axillary ultrasound, and/or mammogram) and who had subsequent image-guided axillary FNA from January 1, 2013, to December 31, 2018, that yielded suspicious lymphadenopathy. From our initial search, we excluded patients with one or more of the following: a current diagnosis of breast cancer; incomplete data (i.e., FNA without flow cytometry); and FNA and/or flow cytometry performed on sites other than the axilla, e.g., intramammary lymph nodes or periprosthetic fluid. Patient medical records were reviewed to determine the clinical follow-up and to compare results in patients where a core needle or excisional biopsy was subsequently performed.

Fine-needle aspiration, cytology, and flow cytometry

Related risks and complications of FNA were discussed with each patient prior to the procedure. Ultrasound-guided sampling was performed by a radiologist for both palpable and non-palpable axillary lymph nodes. All procedures were performed in the outpatient setting. Prior to the FNA procedure, local anesthesia (2.5 ml Lidocaine 1%) was administered under imaging guidance using a 25-gauge needle. FNA was performed using a 22-gauge needle attached to a syringe under suction with an average of 3 passes per case. For each pass, the needle was moved quickly back and forth in different directions, thereby ensuring that different areas of the lymph node were sampled. Material obtained from the first two passes was fixed in ethanol and processed for cell block preparation. A third aspiration was rinsed in a culture medium and transported immediately to the flow cytometry laboratory. Specimens were centrifuged.

Flow cytometry staining for initial method evaluation was performed by standard protocols using simultaneous ammonium chloride lysis and fixation. Briefly, 100 μ L of

blood containing 0.5–1.5 million cells were stained with a cocktail of antibodies for 15 min at room temperature, followed by ammonium chloride lysis with 0.025% formaldehyde for 15 min. Cells were washed with phosphate-buffered saline with bovine serum albumin and sodium azide (PBA) and the cell pellets were resuspended 100 μ l PBA. Fluorescence minus one and single stains were performed using the same methodology. The legacy assay was acquired on standardized BD FACS Canto-10 flow cytometers, while the 14-color assay was acquired on BD Fortessa-X20 flow cytometers equipped with four lasers. Manual analysis was performed using Woodlist software (generous gift of Dr. Brent Wood, University of Washington) (27).

A specimen was considered benign based on the presence of a mixture of T and B cells without evidence of monoclonality or aberrant immunophenotype and no suspicious cells on the histology.

Statistical analysis

Sensitivity, specificity, positive predictive value, and negative predictive value were calculated for FNA alone, flow cytometry alone, and combined FNA and flow cytometry for the diagnosis of lymphoma. Cases were considered true negative when both FNA and flow cytometry yielded benign results, and true positive when both FNA and flow cytometry yielded malignant/suspicious results. Discordant cases (FNA positive for malignancy but flow cytometry negative, or vice versa) were evaluated with histology performed on core biopsy or surgical excision or clinical and imaging follow-up.

Results

Patients

From a sample of 381 patients who were identified from our initial database search, 159 patients were excluded from the study (Fig. 1): 56 patients due to a concurrent ipsilateral breast cancer diagnosis, 38 due to incomplete data, and 65 because the FNA/flow cytometry sampling was performed on a target other than the axilla (with peri-implant fluid being the most common extra-axillary location). This study included 222 eligible patients, of which 220 (99%) were women, with an average age of 58.3 ± 13.4 years (range 21–92). Across the entire sample, 47/222 (21%) patients presented with a palpable axillary lymphadenopathy whereas 175/222 (79%) did not have a clinical suspicious finding. In terms of personal history of cancer, 136/222 (61%) had history of cancer (see Table 1 for a further breakdown of cancer types).

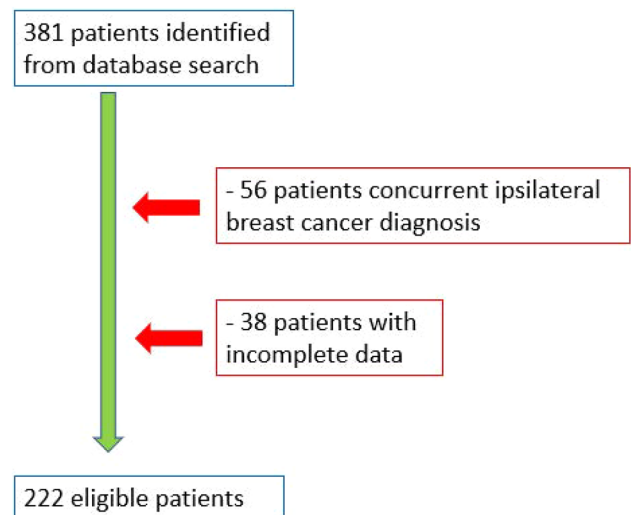


Fig. 1 Flowchart of patients included in this study

Table 1 Summary of personal history of cancer in the study sample ($n = 222$)

Personal history	Number of patients
Breast cancer	86
Breast cancer + additional malignancy excluding lymphoma	9
Breast cancer + lymphoma	1
Non-Hodgkin lymphoma	12 ^a
Hodgkin lymphoma	3
Non-Hodgkin lymphoma + additional malignancy excluding breast	2
Cervical cancer	2
Colorectal cancer	5
Endometrial cancer	4
Ewing sarcoma	1
Melanoma	2
Ovarian cancer	5
Pancreas cancer	1
Renal cancer	2
Thyroid cancer	1
No history of cancer	86

^a1 patient had cutaneous non-Hodgkin lymphoma

Diagnostic accuracy

The overall diagnostic sensitivity, specificity, positive predictive value, negative predictive value, and diagnostic accuracy of FNA alone were 88% (95% confidence interval (CI) 86.6%–89.4%), 92% (95% CI 91.6%–92.4%), 77% (95% CI 75.6%–78.4%), 96% (95% CI 95.2%–96.8%), and 91% (95%

CI 90.8%–91.2%), respectively. The overall diagnostic sensitivity, specificity, positive predictive value, negative predictive value, and diagnostic accuracy of flow cytometry alone were 98% (95% CI 97.4–98.6), 98% (95% CI 97.8–98.2), 92% (95% CI 91–93), 99% (95% CI 98.6–99.4), and 98% (95% CI 97.9–98.1), respectively. The overall diagnostic sensitivity, specificity, positive predictive value, negative predictive value, and diagnostic accuracy of combined FNA and flow cytometry were 100%, 92% (92.3–91.7), 79% (95% CI 77.8%–80.3%), 100%, and 94% (95% CI 93.8%–94.2%), respectively.

Concordance between FNA and flow cytometry

Across the study sample, 172/222 (71%) patients had benign axillary lymph nodes while 50/222 (29%) had malignant lymph nodes. Analysis of concordance between FNA and flow cytometry showed a 93% (206/222) concordance rate.

Of the patients with concordant suspicious results, 43/206 (21%) patients were diagnosed with a hematologic malignancy, i.e., B-cell lymphoma ($n = 39$), T-cell lymphoma ($n = 4$), and chronic lymphocytic leukemia ($n = 1$); this latter diagnosis was confirmed on peripheral blood smear.

Another 4/206 (2%) of the patients with concordant suspicious results were false positives, ultimately not demonstrating malignant lymphadenopathy: One patient had a minute focus of atypical CD20 positive B lymphocytes; the patient did not undergo repeat flow cytometry even though it was requested as the lymphadenopathy resolved, and the same patient had a negative follow-up for 6 years. Another patient had a minute focus of suspicious myeloblasts and underwent multiple repeat negative flow cytometry and bone marrow aspirations, with a negative follow-up for 4 years. Two patients had both suspicious FNA and flow cytometry but negative final histology demonstrating follicular hyperplasia. For both of these patients, flow cytometry yielded a very minute atypical cell population of 0.60% of the total number of white cells.

On the other hand, 159/206 (77%) had benign concordant findings including reactive lymph nodes ($n = 151$), reactive/follicular hyperplasia ($n = 5$), reactive dermatopathic changes ($n = 1$), non-necrotizing granulomatous inflammation ($n = 1$), and fibroadipose tissue with rare lymphocytes ($n = 1$). Follow-up ≥ 6 months was available for 146/159 patients with concordant benign findings (average follow-up 37.3 ± 18.5 months). All 146 patients were negative on follow-up.

In the 222 patients who underwent FNA cytology and flow cytometry, histological confirmation by means of core biopsy or surgical excision was available for 32/222 (14%) patients.

Histological confirmation was available for 9/159 (6%) patients with concordant benign results; for 13/43 (26%)

patients with concordant suspicious/malignant results, 11 of which were diagnosed with a hematologic malignancy (Table 2) and two diagnosed with follicular hyperplasia; and for 10/16 (63%) patients with discordant results.

The overall discordance rate between FNA and flow cytometry was 7% (16/222).

Of the 16 patients with discordant results, 7/16 (44%) patients were diagnosed with cancer (Table 3); all diagnoses of cancer were all confirmed on histology or peripheral blood smear (one patient). Of these seven patients, six patients had positive flow cytometry but negative FNA, whereas the remaining patient had positive FNA but negative flow cytometry. Cancer diagnosis included B-cell lymphoma ($n = 4$), Hodgkin lymphoma ($n = 1$), chronic lymphocytic leukemia ($n = 1$), and myeloid sarcoma ($n = 1$). The one patient who was misdiagnosed on flow cytometry had Epstein–Barr virus associated Hodgkin lymphoma.

Meanwhile, 9/16 (56%) patients with discordant results had benign findings (Table 4). All 9 patients had suspicious FNA and negative flow cytometry; benign etiology was confirmed with histology by means of core biopsy in 3/9 patients. Of the 6/9 patients that were not assessed with histology, 3/6 had negative follow-up of more than 3 years, 1/6 had a negative follow-up of more than 3 years and repeat FNA showed normal lymphoid population, and 2/6 were lost at follow-up (follow-up ≤ 6 months).

Discussion

Fine-needle aspiration biopsy is a well-established tool for the diagnosis of malignant neoplasms. For hematologic malignancies, the accuracy of FNA is improved by the use of flow cytometry [12, 17, 18] but the role of FNA as a standalone technique in the primary diagnosis and subclassification of lymphoma remains controversial [19–24]. The purpose of our study was to assess whether FNA alone (without ancillary techniques) is sufficient to assess non-specific axillary lymphadenopathy to rule out lymphoproliferative disease regardless of subclassification.

Standalone FNA in patients with non-specific palpable or incidentally identified axillary lymphadenopathy and no concurrent diagnosis of malignancy yielded a sensitivity of 88% for the diagnosis of lymphoproliferative malignancy; the sensitivity was increased to 100% with the addition of flow cytometry. FNA as a standalone diagnostic tool missed 6 lymphoproliferative diseases which were detected by flow cytometry. In our study, flow cytometry missed the only case of Hodgkin lymphoma in our study sample; this is concordant with the current literature which shows that flow cytometry is not an accurate tool for the diagnosis of classic Hodgkin lymphoma due to the difficulty in isolating Reed–Sternberg cells as they are admixed in a rich

Table 2 Histological confirmation for concordant FNA/flow cytometry reports

Patient	Concordance	FNA	Flow Cytometry	Tissue Biopsy	Histology
1	Negative-concordant	Negative	Negative	Benign	Reactive lymph node
2	Negative-concordant	Negative	Negative	Benign	Reactive lymph node
3	Negative-concordant	Negative	Negative	Benign	Reactive lymph node
4	Negative-concordant	Negative	Negative	Benign	Non-necrotizing granulomatous inflammation
5	Negative-concordant	Negative	Negative	Benign	Florid lymphoid hyperplasia
6	Negative-concordant	Negative	Negative	Benign	Reactive follicular hyperplasia
7	Negative-concordant	Negative	Negative	Benign	Reactive follicular hyperplasia
8	Negative-concordant	Negative	Negative	Benign	FibroadiPOSE tissue/rare lymphocytes
9	Negative-concordant	Negative	Negative	Benign	FibroadiPOSE tissue/rare lymphocytes
10	Positive-concordant	Positive	Positive	Malignant	Follicular lymphoma
11	Positive-concordant	Positive	Positive	Malignant	Nodal marginal zone lymphoma
12	Positive-concordant	Positive	Positive	Malignant	B-cell lymphoma (Burkitt) HIV-related
13	Positive-concordant	Positive	Positive	Malignant	Large B-cell lymphoma
14	Positive-concordant	Positive	Positive	Malignant	B-cell lymphoma130
15	Positive-concordant	Positive	Positive	Malignant	Low-grade B-cell lymphoma
16	Positive-concordant	Positive	Positive	Malignant	Marginal zone lymphoma
17	Positive-concordant	Positive	Positive	Malignant	Follicular lymphoma
18	Positive-concordant	Positive	Positive	Malignant	B-cell lymphoma
19	Positive-concordant	Positive	Positive	Malignant	Lymphocytic lymphoma
20	Positive-concordant	Positive	Positive	Malignant	Indolent B-cell lymphoma
21	Positive-concordant	Positive	Positive	Benign	Reactive lymph node and pigment consistent with tattoo procedure
22	Positive-concordant	Positive	Positive	Benign	Follicular hyperplasia

Table 3 Discordant FNA/flow cytometry cases yielding malignant results

Patient	FNA	Flow cytometry	Tissue Biopsy	Diagnosis
1	Negative	Positive	Performed	B-cell lymphoma
2	Positive	Negative	Performed	EBV + Hodgkin lymphoma
3	Negative	Positive	Performed	Myeloid sarcoma
4	Negative	Positive	Performed	Chronic lymphocytic leukemia (blood exam)
5	Negative	Positive	Performed	Follicular lymphoma
6	Negative	Positive	Performed	Follicular lymphoma
7	Negative	Positive	Performed	Low-grade B-cell lymphoma (probably mantle cell lymphoma)

EBV Epstein–Barr virus

inflammatory background. In fact, 15% of Hodgkin lymphomas may show normal flow cytometry results (36–38).

Although the combination of FNA with ancillary techniques such as flow cytometry increases the sensitivity, interestingly, in our study, the specificity of standalone FNA did not differ from the specificity of FNA combined with flow cytometry (92% for both). The overall diagnostic accuracy for FNA alone was 91% in our patient sample and 94% for FNA combined with flow cytometry.

We believe that the diagnostic accuracy of FNA alone may be sufficient to screen patients with indeterminate and incidental lymphadenopathy and that flow cytometry could

be initially deferred in patients with low pretest probability of lymphoma. Flow cytometry could be performed on follow-up for cases with suspicious findings on FNA. Using FNA to triage patients with unilateral axillary lymphadenopathy could help save time and costs and avoid additional sampling for specimen collections which can lead to additional patient discomfort.

Our results are in line with those of another study by Metzgeroth et al. [25] which yielded a sensitivity of 91% of FNA alone. Another study on cervical lymphadenopathy by Choy et al. [26] yielded a higher sensitivity of 94.1% of FNA alone but their patient sample was younger in age (range

Table 4 Discordant FNA/flow cytometry cases yielding benign results

Patient	FNA	Flow cytometry	Tissue Biopsy	Histological diagnosis
1	Positive	Negative	Performed	Reactive lymph node
2	Positive	Negative	Performed	Reactive follicular hyperplasia
3	Positive	Negative	Performed	Reactive hyperplasia (SLE-related)
4	Positive	Negative	Not performed	Reactive lymph node (neg. FU)
5	Positive	Negative	Not performed	Reactive lymph node (neg. FU)
6	Positive	Negative	Not performed	Reactive lymph node (neg. FU)
7	Positive	Negative	Not performed	Reactive lymph node (neg. FU and repeat FNA negative)
8	Positive	Negative	Not performed	Reactive lymph node (lost at FU)
9	Positive	Negative	Not performed	Reactive lymph node (lost at FU)

SLE systemic lupus erythematosus, *FU* follow-up

18–30 years) and there was a predominance of Hodgkin lymphoma as hematologic malignancy. Our patient sample had an average age of 58.3 years and only one patient had a diagnosis of Hodgkin lymphoma which was diagnosed on FNA but missed on flow cytometry. This may be a limitation of our study as it may falsely increase the sensitivity of flow cytometry for the diagnosis of lymphoma as compared to FNA alone.

Limitations of our study include the makeup of our patient sample which was primarily female (99%) who presented to our clinic for a diagnostic or screening breast exam. Therefore, the results cannot be generalized and applied to the entire population including young adults where Hodgkin lymphoma is more prevalent. However, our results are valid for patients in the breast cancer screening group with incidental lymphadenopathy found during screening exams or on palpation. Another limitation is the small number of patients included in the study, due to the retrospective nature of this study. Finally, this was a single-institution study, limiting the generalizability of the results.

Conclusion

With a diagnostic accuracy of 91%, FNA with cytology is a useful first-line standalone diagnostic procedure to screen patients with incidental non-specific axillary lymphadenopathy in the breast cancer screening population. Flow cytometry could be initially deferred in patients with low pretest probability of lymphoma. A positive/suspicious FNA result can be used to triage specimens for flow cytometry and/or tissue biopsy to characterize hematologic malignancy.

Acknowledgements Joanne Chin, MFA, ELS, provided editorial assistance for the manuscript.

Funding This study received funding from the National Institutes of Health/National Cancer Institute Cancer Center Support Grant (P30 CA008748).

Data Availability The datasets generated during and/or analyzed during the current study are available from the corresponding author on reasonable request.

Declarations

Conflict of interest All authors report no industry support of the project. Maxine S Jochelson has received an honorarium from GE for speaking, and an honorarium for speaking at the Lynn Sage Breast Cancer Symposium and at MD Anderson. The other authors of this manuscript declare no conflicts of interest.

Ethical approval All procedures performed in studies involving human participants were in accordance with the ethical standards of the institutional review board at Memorial Sloan Kettering Cancer Center and with the 1964 Helsinki declaration and its later amendments or comparable ethical standards.

Informed consent This was an IRB-approved and HIPAA-compliant retrospective study for which the need for written informed consent was waived.

Research involved in human and animal rights This article does not contain any studies with animals performed by any of the authors.

References

1. Chetlun A, Nicholson B, Patrie JT, Harvey JA (2012) Is screening detected bilateral axillary adenopathy on mammography clinically significant? *Breast J* 18(6):582–587. <https://doi.org/10.1111/tbj.12040>
2. Murray ME, Given-Wilson RM (1997) The clinical importance of axillary lymphadenopathy detected on screening mammography. *Clin Radiol* 52(6):458–461. [https://doi.org/10.1016/s0009-9260\(97\)80008-6](https://doi.org/10.1016/s0009-9260(97)80008-6)
3. Patel T, Given-Wilson RM, Thomas V (2005) The clinical importance of axillary lymphadenopathy detected on screening mammography: revisited. *Clin Radiol* 60(1):64–71. <https://doi.org/10.1016/j.crad.2004.05.007>
4. Birch JM, Alston RD, Kelsey AM, Quinn MJ, Babb P, McNally RJ (2002) Classification and incidence of cancers in adolescents and young adults in England 1979–1997. *Br J Cancer* 87(11):1267–1274. <https://doi.org/10.1038/sj.bjc.6600647>

5. Burger IA, Husmann L, Hany TF, Schmid DT, Schaefer NG (2011) Incidence and intensity of F-18 FDG uptake after vaccination with H1N1 vaccine. *Clin Nucl Med* 36(10):848–853. <https://doi.org/10.1097/RLU.0b013e3182177322>
6. Rubinstein E, Keynan Y (2017) Lymphadenopathy. In: Cohen J, Powderly WG, Opal SM (eds) *Infectious Diseases (Fourth Edition)*. Elsevier, pp 136–145.e131. doi:<https://doi.org/10.1016/B978-0-7020-6285-8.00015-0>
7. Polack FP, Thomas SJ, Kitchin N, Absalon J, Gurtman A, Lockhart S, Perez JL, Pérez Marc G, Moreira ED, Zerbini C, Bailey R, Swanson KA, Roychoudhury S, Koury K, Li P, Kalina WV, Cooper D, Frenck RW Jr, Hammitt LL, Türeci Ö, Nell H, Schaefer A, Ünal S, Tresnan DB, Mather S, Dormitzer PR, Şahin U, Jansen KU, Gruber WC (2020) Safety and Efficacy of the BNT162b2 mRNA Covid-19 Vaccine. *N Engl J Med* 383(27):2603–2615. <https://doi.org/10.1056/NEJMoa2034577>
8. ModernaTX (2020) Moderna COVID-19 Vaccine: Vaccines and Related Biological Products Advisory Committee Briefing Document. Vaccines and Related Biological Products Advisory Committee Meeting, December 17, 2020. <https://www.fda.gov/media/144434/download>. Accessed March 11, 2021
9. Zeppa P, Marino G, Troncone G, Fulciniti F, De Renzo A, Picardi M, Benincasa G, Rotoli B, Vetrani A, Palombini L (2004) Fine-needle cytology and flow cytometry immunophenotyping and subclassification of non-Hodgkin lymphoma: a critical review of 307 cases with technical suggestions. *Cancer* 102(1):55–65. <https://doi.org/10.1002/cncr.11903>
10. Cheson BD, Fisher RI, Barrington SF, Cavalli F, Schwartz LH, Zucca E, Lister TA (2014) Recommendations for initial evaluation, staging, and response assessment of Hodgkin and non-Hodgkin lymphoma: the Lugano classification. *J Clin Oncol* 32(27):3059–3068. <https://doi.org/10.1200/jco.2013.54.8800>
11. Tilly H, Gomes da Silva M, Vitolo U, Jack A, Meignan M, Lopez-Guillermo A, Walewski J, André M, Johnson PW, Pfreundschuh M, Ladetto M (2015) Diffuse large B-cell lymphoma (DLBCL): ESMO Clinical Practice Guidelines for diagnosis, treatment and follow-up. *Ann Oncol* 26(Suppl 5):v116–125. <https://doi.org/10.1093/annonc/mdv304>
12. Meda BA, Buss DH, Woodruff RD, Cappellari JO, Rainer RO, Powell BL, Geisinger KR (2000) Diagnosis and subclassification of primary and recurrent lymphoma. The usefulness and limitations of combined fine-needle aspiration cytomorphology and flow cytometry. *Am J Clin Pathol* 113(5):688–699. <https://doi.org/10.1309/0q7f-qtgm-6dgd-tlgy>
13. Swerdlow SH, Campo E, Harris NL, Jaffe ES, Pileri SA, Stein H, Thiele J, Vardiman JW (2008) *WHO Classification of Tumours of Haematopoietic and Lymphoid Tissues*, vol 2 4th edn International Agency for Research on Cancer Lyon France
14. Zeppa P, Sosa Fernandez LV, Cozzolino I, Ronga V, Genesio R, Salatiello M, Picardi M, Malapelle U, Troncone G, Vigliar E (2012) Immunoglobulin heavy-chain fluorescence in situ hybridization-chromogenic in situ hybridization DNA probe split signal in the clonality assessment of lymphoproliferative processes on cytological samples. *Cancer Cytopathol* 120(6):390–400. <https://doi.org/10.1002/cncy.21203>
15. Kocjan G (2005) Best Practice No 185. Cytological and molecular diagnosis of lymphoma. *J Clin Pathol* 58(6):561–567. <https://doi.org/10.1136/jcp.2004.019133>
16. Barroca H, Marques C (2016) A Basic approach to lymph node and flow cytometry fine-needle cytology. *Acta Cytol* 60(4):284–301. <https://doi.org/10.1159/000448679>
17. Nicol TL, Silberman M, Rosenthal DL, Borowitz MJ (2000) The accuracy of combined cytopathologic and flow cytometric analysis of fine-needle aspirates of lymph nodes. *Am J Clin Pathol* 114(1):18–28. <https://doi.org/10.1309/mn6j-4njj-c5cg-1plh>
18. Liu K, Stern RC, Rogers RT, Dodd LG, Mann KP (2001) Diagnosis of hematopoietic processes by fine-needle aspiration in conjunction with flow cytometry: A review of 127 cases. *Diagn Cytopathol* 24(1):1–10. [https://doi.org/10.1002/1097-0339\(200101\)24:1%3c1::aid-dc1000%3e3.0.co;2-j](https://doi.org/10.1002/1097-0339(200101)24:1%3c1::aid-dc1000%3e3.0.co;2-j)
19. Cafferty LL, Katz RL, Ordonez NG, Carrasco CH, Cabanillas FR (1990) Fine needle aspiration diagnosis of intraabdominal and retroperitoneal lymphomas by a morphologic and immunocytochemical approach. *Cancer* 65(1):72–77. [https://doi.org/10.1002/1097-0142\(19900101\)65:1%3c72::aid-cncr2820650116%3e3.0.co;2-q](https://doi.org/10.1002/1097-0142(19900101)65:1%3c72::aid-cncr2820650116%3e3.0.co;2-q)
20. Sneige N, Dekmezian R, el-Naggar A, Manning J (1991) Cytomorphologic, immunocytochemical, and nucleic acid flow cytometric study of 50 lymph nodes by fine-needle aspiration Comparison with results obtained by subsequent excisional biopsy. *Cancer* 67(4):1003–1007 doi: [https://doi.org/10.1002/1097-0142\(19910215\)67:4<1003::aid-cncr2820670424>3.0.co;2-w](https://doi.org/10.1002/1097-0142(19910215)67:4<1003::aid-cncr2820670424>3.0.co;2-w)
21. Sneige N, Dekmezian RH, Katz RL, Fanning TV, Lukeman JL, Ordoñez NF, Cabanillas FF (1990) Morphologic and immunocytochemical evaluation of 220 fine needle aspirates of malignant lymphoma and lymphoid hyperplasia. *Acta Cytol* 34(3):311–322
22. Dunphy CH, Ramos R (1997) Combining fine-needle aspiration and flow cytometric immunophenotyping in evaluation of nodal and extranodal sites for possible lymphoma: a retrospective review. *Diagn Cytopathol* 16(3):200–206. [https://doi.org/10.1002/\(sici\)1097-0339\(199703\)16:3%3c200::aid-dc2%3e3.0.co;2-j](https://doi.org/10.1002/(sici)1097-0339(199703)16:3%3c200::aid-dc2%3e3.0.co;2-j)
23. Young NA, Al-Saleem TI, Ehya H, Smith MR (1998) Utilization of fine-needle aspiration cytology and flow cytometry in the diagnosis and subclassification of primary and recurrent lymphoma. *Cancer* 84(4):252–261
24. Johnson A, Akerman M, Cavallin-Ståhl E (1987) Flow cytometric detection of B-clonal excess in fine needle aspirates for enhanced diagnostic accuracy in non-Hodgkin's lymphoma in adults. *Histopathology* 11(6):581–590. <https://doi.org/10.1111/j.1365-2559.1987.tb02668.x>
25. Metzgeroth G, Schneider S, Walz C, Reiter S, Hofmann WK, Marx A, Hastka J (2012) Fine needle aspiration and core needle biopsy in the diagnosis of lymphadenopathy of unknown aetiology. *Ann Hematol* 91(9):1477–1484. <https://doi.org/10.1007/s00277-012-1476-4>
26. Choy B, Venkataraman G, Biernacka A, Lastra RR, Mueller J, Setia N, Reeves W, Antic T (2019) Correlation of cytopathology with flow cytometry and histopathology for the diagnosis of hematologic malignancies in young adults presenting with cervical lymphadenopathy. *Diagn Cytopathol* 47(6):579–583. <https://doi.org/10.1002/dc.24157>

Publisher's Note Springer Nature remains neutral with regard to jurisdictional claims in published maps and institutional affiliations.