

Survival After Induction Chemotherapy and Surgical Resection for High-Grade Soft Tissue Sarcoma. Is Radiation Necessary?

Robert Mikael Henshaw, MD, Dennis A. Priebat, MD, David J. Perry, MD,
Barry M. Shmookler, MD, and Martin M. Malawer, MD

Background: Induction chemotherapy can produce dramatic necrosis in sarcomas—raising the question of whether or not radiation is necessary. This study reviews the clinical outcome of a subset of patients with high-grade extremity soft tissue sarcomas (STS) who were treated with induction chemotherapy and surgical resection but without radiation.

Methods: Nonmetastatic, large, high-grade STS of the pelvis and extremities were treated with intra-arterial cisplatin, adriamycin, and, after 1995, ifosfamide. After induction, oncologic resection and histologic evaluation were performed. Good responders with good surgical margins were not treated with radiation.

Results: Thirty-three patients, with a median follow-up of 5 years, were included. Limb salvage rate was 94%. Median tumor necrosis was 95%. Four patients developed metastatic disease with three subsequent deaths. Two local recurrences occurred; both patients were salvaged with resection and adjuvant external beam radiotherapy, although one died of metastatic disease 10 years later. Relapse-free and overall survival is 80% and 88% at 5 and 10 years by Kaplan-Meier analysis.

Conclusions: Intensive induction chemotherapy can be extremely effective for high-grade STS, permitting limb-sparing surgery in lieu of amputation. Radiation may not be necessary if a good response to induction chemotherapy and negative wide margins are achieved. All patients with large, deep, high-grade STS of the extremities should be considered candidates for induction chemotherapy.

Key Words: Induction chemotherapy—Soft tissue sarcoma—Survival rates—Surgical Resection—Treatment.

After prospective, randomized, controlled studies demonstrated a significant survival advantage for patients receiving adjuvant chemotherapy after resection of osteosarcoma,^{1,2} there was a rapid migration to initiating treatment prior to surgical resection. Induction (neoadjuvant or preoperative) chemotherapy has since gained widespread international acceptance in the treatment of osteosarcoma and other high-grade bone sarcomas. Effective induction therapy enables surgeons to reduce the

need for amputation in favor of the current techniques of wide resection and skeletal reconstruction (referred to as limb salvage). Today, limb salvage is the preferred treatment method for bone sarcomas,³ with no difference seen in overall survival between patients undergoing limb salvage or amputation.^{4,5} The efficacy of chemotherapy has been established in the treatment of osteosarcoma, and current protocols emphasize the use of multi-agent combination chemotherapy prior to surgical resection. Recently, several studies have identified the percentage of histologic tumor necrosis seen at the time of surgical resection as a significant independent prognostic factor for patient survival.^{6,7} Unlike chemotherapy, which has been shown to be effective, radiation has been rarely used for patients with osteosarcoma. It is typically reserved only for those patients with unresectable disease of the sacrum or spine or for salvage treatment in patients with recurrent disease.⁸

Received June 23, 2000; accepted January 3, 2001.

From the Division of Orthopedic Oncology (RMH, MMM) and the Department of Hematology/Oncology (DAP, DJP), George Washington University, Washington Cancer Institute; and the Department of Pathology (BMS), Washington Hospital Center, Washington, DC.

Address correspondence and reprint requests to: Robert Mikael Henshaw, MD, Assistant Professor, Orthopedic Surgery, The Washington Cancer Institute at Washington Hospital Center, 110 Irving Street, NW, Washington DC 20010; Fax: 202-877-8959; E-mail: rmh4@mhg.edu.

Development of treatment strategies for soft tissue sarcomas (STS) has generally lagged behind those for osteosarcoma. However, on the basis of growing experience and excellent results of limb-sparing surgery with bone sarcomas, several centers now utilize similar surgical techniques for soft tissue sarcomas.^{9,10} Local control of the primary tumor is highly dependent on the surgical margin achieved at the time of resection.¹¹ Adjuvant radiotherapy, delivered either by external beam (XRT) or indwelling catheters (brachytherapy), can improve local tumor control, presumably by extending the surgical margin.¹²⁻¹⁴ Radiation has also been used as an induction treatment to induce tumor shrinkage and facilitate surgical resection.¹⁵ However, there are significant problems associated with radiotherapy, including delayed wound healing, tissue fibrosis, loss of joint motion, neuritis, flap necrosis, and an increased risk of secondary sarcomas. In addition, radiation is limited to local control and cannot treat micrometastatic disease that may already be present. For these reasons, radiation may not have a major impact on patient survival. Recent trends in orthopedic oncology have included a reduced reliance on radiotherapy as a primary treatment for musculoskeletal tumors due to long-term morbidity (e.g., lymphedema, pathologic bone fracture, and secondary sarcoma formation) associated with radiation.

By nature of its systemic administration, chemotherapy can have both local and systemic effects. Doxorubicin has been the most active single agent in the treatment of metastatic soft tissue sarcomas.^{16,17} Less activity has also been shown for cisplatin (CDDP).¹⁸⁻²⁰ However, cisplatin has been shown to have a synergistic effect when given concomitantly with epirubicin (a doxorubicin derivative) in the treatment of advanced STS.²¹ More recently, ifosfamide has been found to be almost as active as doxorubicin against STS, with further improved response rates seen with regimens combining both drugs.²²⁻²⁹ However, few centers have reported on the use of chemotherapy for induction treatment for soft tissue sarcomas, despite its role in the treatment of osteosarcoma. Beginning in 1985, our institution embarked on a prospective trial of induction chemotherapy for extremity and pelvic STS. Our primary objective was to avoid performing amputations in patients presenting with extremely large tumors in difficult locations. Prospectively, we looked at clinical response rates, tumor necrosis, and patient outcomes in high-risk extremity STS patients.

Early candidates for treatment were limited to patients with high-grade STS of the extremities and pelvis judged to be unresectable because of anatomic location, size, and/or the presence of significant contamination from

prior unplanned intralesional procedures. Historically, such patients have been treated with major amputations and/or intensive radiation. On the basis of our prior experience with osteosarcomas, we hypothesized that neoadjuvant chemotherapy would permit limb salvage by inducing tumor shrinkage. Our strategy was to base the surgical treatment of each patient on restaging images and clinical examination after completion of induction treatment. Initial results showed excellent success in performing limb-sparing procedures in such patients after 2 cycles of continuous IV doxorubicin and intra-arterial cisplatin.³⁰ Based on our prior experience with bone sarcomas, patients demonstrating a good response to chemotherapy (as determined by semiquantitative analysis of tumor necrosis) and who had a good oncologic resection with negative margins were judged to not require radiation.

The purpose of this study was to evaluate the long-term disease-free and overall survival rates of patients presenting with large high-grade extremity and pelvic sarcomas who were treated with chemotherapy and surgical resection but who did not receive pre- or postoperative radiation.

METHODS

An interdisciplinary team composed of orthopedic, medical, and radiation oncologists evaluated all patients presenting with intermediate or high-grade STS. Patients underwent biopsy (core needle and/or incisional) and pathologic review to confirm their diagnosis. Axial imaging (computed tomography [CT] or magnetic resonance imaging [MRI]) was used to define the anatomic location, size, and extent of the tumor. In addition, patients were staged with chest CT scans to rule out metastatic disease. Originally, only those patients with non-metastatic, intermediate to high-grade STS of the extremities and pelvis and for whom an amputation was believed necessary were eligible for this protocol. After analysis of the first 24 patients revealed very favorable outcomes, the protocol was expanded to include all patients with large high-grade extremity sarcomas. Patients who opted for conventional treatment (i.e., attempted local wide resection followed by adjuvant radiotherapy) were excluded from this study.

Chemotherapy was administered by protocol as detailed below. After completion of induction treatment, restaging was performed with CT, MRI, and angiography. This was followed by surgical resection of the tumor. Major amputations were performed when necessary. Detailed histologic evaluation of the resected tumor was performed to determine the surgical margins and the

percentage of tumor necrosis. All patients were scheduled to receive adjuvant chemotherapy. In addition, patients felt to be at high risk for local recurrence (i.e., those with close or positive surgical margins) were offered standard adjuvant radiotherapy. All patients have been followed clinically with serial physical exams and radiographic staging studies to monitor patient outcomes. Standard Kaplan-Meier analysis was performed to determine disease-free and overall survival rates.

A total of 46 patients were treated with induction chemotherapy between 1985 and 1998. Twelve patients were treated with adjuvant external beam radiation after surgical resection and were therefore excluded from the analysis. One patient died of a myocardial infarction after receiving the first dose of induction chemotherapy and was therefore excluded from the survival analysis. The remaining 33 patients are included in this study. Median follow-up from the time of surgical resection is 5 years, with a minimum follow-up of 2 years.

Chemotherapy Protocol

Continuous IV infusion was chosen as the method of delivery for doxorubicin, based on data suggesting that continuous administration may result in less cardiac toxicity when compared with traditional bolus infusion.³¹ The second agent chosen for this protocol was cisplatin, which has been shown to have activity in the treatment of metastatic STS.¹⁸⁻²⁰ Regional intra-arterial administration was selected based on prior experience with this method in patients with bone sarcomas and the potential benefits of achieving a higher concentration of the drug at the tumor site.³²⁻³⁴

Experience with this initial two-drug protocol was very encouraging and it was used exclusively from 1985 through December 1995.^{30,35} Patients treated with this protocol constitute Group 1. These patients received 2 cycles of chemotherapy 4 weeks apart prior to surgical resection; this was followed by an additional 4 cycles given postoperatively.

In January 1996, the study protocol was revised. Indications for patient enrollment were expanded to include all patients with large high-grade extremity soft tissue sarcomas. The new protocol added an additional induction cycle consisting of adriamycin and ifosfamide. The dosage of adriamycin was increased to 75 mg/m², while the interval between cycles was reduced to 3 weeks. Additionally, ifosfamide was substituted for cisplatin in the adjuvant phase in order to reduce the incidence of significant peripheral neuropathy. Finally, dosage intensification was achieved by administration of granulocyte colony-stimulating factor (filgrastim, Neupogen) starting 24 hours after chemotherapy was admin-

istered. Patients treated with this updated protocol constitute Group 2.

Group 1 (n = 18)

Group 1 chemotherapy protocol for unresectable high-grade soft tissue sarcomas of the extremities and pelvis is shown in Fig. 1A.

Cycles 1 and 2

- Intra-arterial catheterization was performed under fluoroscopic guidance with placement of the catheter tip in the main arterial supply to the tumor.
- Cisplatin (cis platinum) was infused intra-arterially over 2 hours for a total dose of 120 mg/m² along with IV hydration and mannitol.
- Doxorubicin was given as a continuous IV infusion through an indwelling central venous catheter over 72 hours at a dose of 60 mg/m² after completion of the intra-arterial treatment.

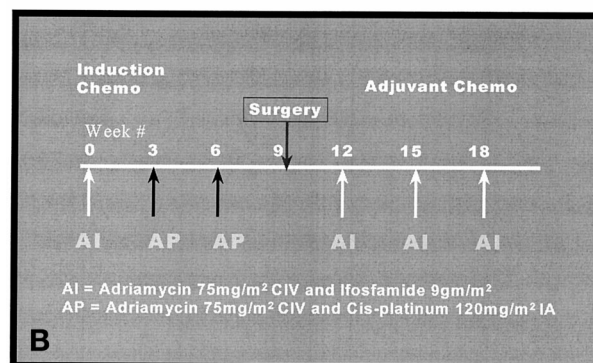
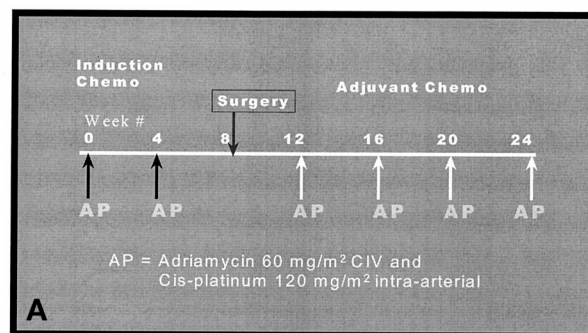


FIG. 1. (A) Group 1 chemotherapy protocol for unresectable high-grade soft tissue sarcomas of the extremities and pelvis. (B) Group 2 chemotherapy protocol for all large high-grade soft tissue sarcomas of the extremities and pelvis.

Group 2 (n = 15)

Group 2 chemotherapy protocol for all large high-grade soft tissue sarcomas of the extremities and pelvis is shown in Fig. 1B.

Cycle 1

- Ifosfamide (2.25 gm/m²) was infused over 2–3 hours per day for 4 days with MESNA (20% of ifosfamide dose) administered 15 minutes prior to, 4 hours after, and 8 hours after ifosfamide was started.
- Concomitant administration of doxorubicin (75 mg/m²) was given as a continuous IV infusion over 72 hours.
- Filgrastim (Neupogen) 5 µg/kg was given subcutaneously daily beginning 24 hours after chemotherapy was finished.

Cycles 2 and 3

- Doxorubicin was given as a continuous IV infusion over 72 hours to a dose of 75 mg/m², preferably as an outpatient.
- Intra-arterial catheterization was performed under fluoroscopic guidance with placement of the catheter tip in the main arterial supply to the tumor.
- Cisplatin (CDDP) was infused intra-arterially over 4 hours at a dose of 120 mg/m² along with IV hydration and mannitol. The dose was reduced to 100 mg/m² in patients over 70.
- Filgrastim (Neupogen) 5 µg/kg was given subcutaneously daily beginning 24 hours after chemotherapy was finished.

After completion of induction chemotherapy, repeat staging for metastatic disease was performed in both groups. In addition, angiography and axial imaging (CT or MRI) of the tumor was performed for preoperative surgical planning. The decision for amputation or limb-sparing resection was based on the results of this restaging. The decision to perform a limb-sparing resection was based on the clinical and radiographic response of the tumor to induction chemotherapy. Findings typically consistent with a good response included the loss of tumor vascularity as seen on angiography, thickening of the surrounding capsule and central tumor necrosis as seen on CT or MRI, and the definition of clear planes surrounding the neurovascular bundles as defined by all of the studies (Fig. 2 A,B). After surgical resection and wound healing, adjuvant chemotherapy was administered as follows:

Group 1: Patients received 4 cycles of adjuvant chemotherapy in 4-week intervals, including:

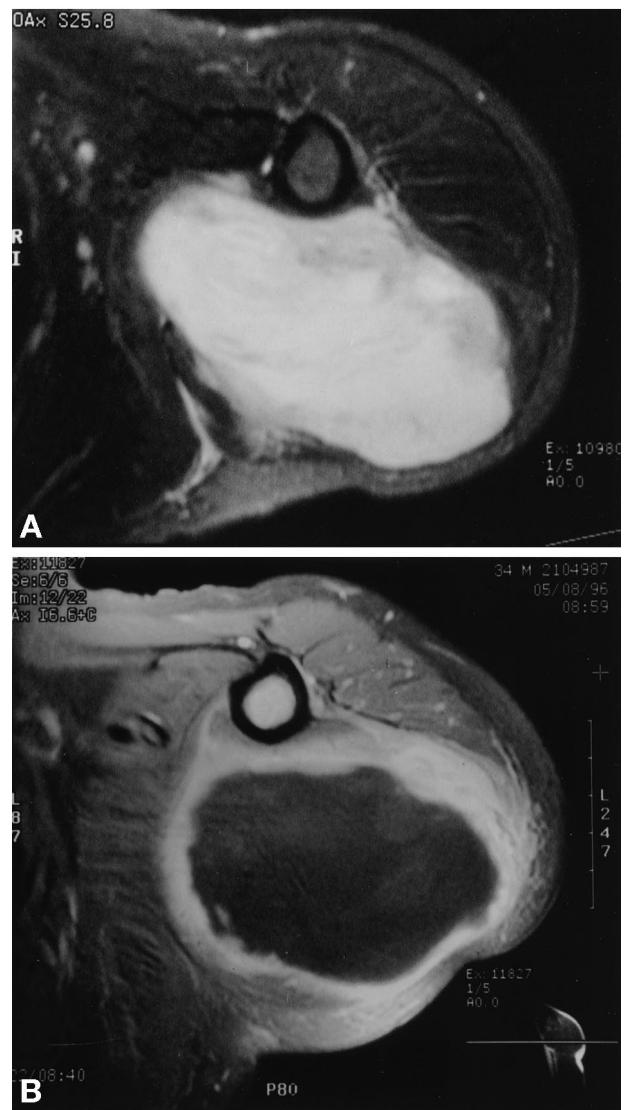


FIG. 2. (A) High-grade malignant peripheral nerve sheath tumor of the shoulder girdle. (B) After induction chemotherapy, marked central necrosis is visible, with thickening of the peripheral pseudocapsule, consistent with an excellent response to chemotherapy.

- 120 mg/m² of cisplatin IV over 2 hours
- 60 mg/m² of doxorubicin over 72 hours via continuous IV infusion

Group 2: Patients received 3 cycles of adjuvant chemotherapy at 3-week intervals as follows:

- Ifosfamide, 2.25 gm/m²/day given as a 2–3 hour IV bolus for 4 days
- Concomitant continuous IV infusion of doxorubicin at a dose of 75 mg/m² over 72 hours

Clinical Data and Tumor Classification

Group 1

The 18 patients in Group 1 (12 male, 6 female) had a median age of 54.5 years (range, 29–67.4) at time of enrollment. Preoperative pathologic diagnoses, based on core needle biopsy, showed: 11 patients had malignant fibrous histiocytoma (MFH), four patients had liposarcoma, one patient had synovial cell sarcoma, one patient had leiomyosarcoma, and one patient had an undifferentiated sarcoma (sarcoma, not otherwise specified) (Table 1).

Seventeen of the 18 patients presented with tumors ≥ 5 cm in diameter; tumors in nine patients were ≥ 10 cm in maximum diameter. Fourteen patients had high-grade (Russell or NCI grade 3) sarcomas, while those for the

remaining four patients were intermediate grade (Russell or NCI grade 2).

Seventeen patients were stage IIB, and one patient was stage IIA, according to the Musculoskeletal Tumor Society (MSTS) classification. Using the American Joint Cancer Commission (AJCC) staging system, one patient was stage IIB, one patient was stage IIIA, and 16 patients were stage IIIB. Anatomically, 12 patients presented with tumors of the groin or anterior thigh (involving the sartorial canal), two patients had tumors of the popliteal fossa, and there was one patient each with a tumor of the pelvis, calf, arm, and hand. Of the 18 patients, 12 were judged to definitely require an amputation, while six patients were classified as probable amputations. Five patients had undergone an intralesional procedure prior

TABLE 1. Patient data and oncologic outcomes for 33 patients with extremity soft tissue sarcomas treated with induction chemotherapy and surgical resection

	Tumor	Location	Size	Date of birth	Date of surgery	Amputation	Percentage tumor necrosis	Outcome
Group 1								
2	MFH	Thigh	5 × 4	8/02/39	2/07/95		96	
3	Liposarcoma	Calf	4 × 12	7/17/52	1/17/92	BKA	60	METS @ 0.7 yrs, dead @ 1.21 yrs
4	Liposarcoma	Prox thigh	10 × 9	4/07/38	11/30/94		95	
5	Synovial cell	Popliteal fossa	6 × 8	10/13/32	12/08/92		99	METS @ .31 yrs, dead @ 1.44 yrs
6	MFH	Thigh	5 × 2	11/14/34	7/12/94		100	
7	MFH	Popliteal fossa	6 × 16	3/10/39	7/27/93	AKA	50	
8	MFH	Upper arm	7 × 9	12/18/37	7/08/92		99	
9	MFH	Prox thigh	11 × 7	11/20/50	5/20/92		95	
10	MFH	Thigh	6 × 6	11/30/56	4/07/92		80	
11	Leiomyosarcoma	Thigh	8 × 6.5	2/18/28	12/04/92		100	METS @ 3.26 yrs, dead @ 4.69 yrs
12	Liposarcoma	Thigh	17 × 9	12/19/23	4/25/91		95	
13	MFH	Thigh	5 × 8	7/25/38	10/12/90		98	
14	Undiff spindle	Thigh	6 × 9	3/14/33	6/04/90		98	Pancreatic CA diagnosed in 1999
15	MFH	Hand	2 × 3	11/12/26	9/18/90		60	
16	MFH	Thigh	10 × 12	11/13/43	3/26/89		60	
17	MFH	Pelvis/thigh	10 × 7	10/25/56	10/17/85		100	
18	MFH	Thigh	16 × 5	1/21/34	6/08/88		95	LR @ 1.32 yrs, METS, dead @ 10.15 yrs
Group 2								
1	MFH	Thigh	8 × 4	6/08/34	10/03/95		99	
2	Liposarcoma	Popliteal/thigh	20 × 9	6/27/58	11/19/95		98	
3	MFH	Sartorius	4 × 3	4/25/49	11/28/95		50	
4	MFH	Calf	10 × 9	3/15/33	8/21/96		NTS	Solitary MET resected 8/20/98
5	MFH	Dist thigh	9 × 6	9/02/21	9/04/96		85	
6	MPNST	Sartorius	6 × 5	4/16/64	11/06/96		98	
7	Leiomyosarcoma	Calf	7.5 × 5 × 5	9/29/44	1/08/97		98	
8	Undiff spindle	Ant thigh	12 × 22	10/04/38	4/15/97		98	Renal cell CA diagnosed, resected in 1998
9	Undiff spindle	Quads	13 × 45	7/21/26	5/20/97		99	
10	Dediff liposarcoma	Post thigh	9 × 6 × 3.5	11/07/65	11/14/97		NTS	
11	Liposarcoma	Buttock	12 × 18	4/05/54	12/03/97		NTS	
12	MFH	Thigh	20 × 15 × 10	9/17/31	9/16/97		90	
13	Round cell liposarcoma	Thigh	4 × 2.5 × 2	6/04/58	1/28/98		NTS	
14	MFH	Adductors	10 × 5 × 6	3/19/45	3/24/98		92	
15	Liposarcoma	Dist thigh	14.2 × 6 × 5.4	10/17/53	8/14/98		98	

MFH, malignant fibrous histiocytoma; MPNST, malignant peripheral nerve sheath tumor; undiff spindle, undifferentiated spindle cell sarcoma; NTS, no tumor seen; LR, local recurrence; METS, pulmonary metastasis; BKA, below knee amputation; AKA, above knee amputation.

to referral to our center. These patients were treated as if the intralesional procedure was simply an extended open biopsy.

Group 2

Fifteen patients (8 male, 7 female) have completed treatment with a minimum 2-year follow-up. Median age was 49.4 years (range, 32–70.8). Preoperative diagnosis was as follows: six MFH, five liposarcomas, two undifferentiated sarcoma, one leiomyosarcoma, and one malignant peripheral nerve sheath tumor (MPNST/neurosarcoma). (Table 1).

Thirteen patients had tumors ≥ 5 cm in maximum diameter, eight of these exceeded 10 cm in diameter. Fourteen patients had high-grade (Russell or NCI grade 3) tumors while one patient had an intermediate grade (Russell or NCI grade 2) tumor. All 15 were classified as MSTS stage IIB or as AJCC stage IIIB. Anatomic location was as follows: 10 patients had involvement of the groin or anterior thigh, two of the calf, and one each involving the popliteal fossa, buttock, and knee. Four patients had undergone an intralesional procedure prior to referral to our center.

Surgical Technique

After induction treatment, all 33 patients were re-evaluated to determine whether a wide local resection or an amputation would be necessary. Detailed preoperative planning was performed based on sequential axial imaging with CT or MRI. Preoperative angiography was performed to define the vascular anatomy in the region of the tumor in addition to defining any residual tumor vascularity as a possible indication of the efficacy of induction treatment. Resection was performed through normal tissue planes outside the tumor pseudocapsule along with en-bloc resection of the biopsy site. The closest margins were frequently located along the main neurovascular bundle of the involved compartments. When possible, an attempt was made to save major nerves and vessels by dissecting the enveloping sheath free of the structure en bloc with the tumor specimen. Intraoperative frozen section histologic evaluation was performed on all margins to ensure complete removal of all the tumor. All resections were judged to be extralesional on the basis of these frozen sections. Reconstruction of surgical defects was performed by means of local muscle transfers to cover the neurovascular bundles and to restore the functional anatomy.

Histologic Evaluation

One musculoskeletal pathologist (BMS) performed the detailed histologic evaluation of all resection speci-

mens. In selected cases, the histologic diagnosis was confirmed with immunohistochemical stains. All surfaces and tagged surgical margins were painted with colored ink prior to sectioning. Multiple transverse slabs of the entire specimen were sectioned in a gridlike fashion, analogous to the evaluation of bone tumors. The resulting tissue sections were labeled sequentially and mapped to a diagram corresponding to each slab. All areas of necrosis consistent with the effects of chemotherapy were noted. For each section of the grid, the percentage of viable tumor, as well as the amount of fibrosis, hemosiderin deposition, inflammatory infiltration, and nonviable tumor, was recorded. Based on this data, the percentage of histologic necrosis attributable to chemotherapy was reached by semiquantitative estimation (referred to as the percentage chemotherapy tumor-killing effect). This technique is analogous to that used in the evaluation of tumor necrosis after induction treatment for osteosarcoma.

RESULTS

Induction Chemotherapy

All 33 enrolled patients were able to complete the full regimen of induction chemotherapy without major complications or toxicity. One patient, excluded from the analysis as previously stated, died of a myocardial infarction after initial administration of a single dose of adriamycin. Minor complications associated with the use of intra-arterial cisplatin included four patients who developed myocutaneous necrosis. One other patient developed an arterial thrombosis requiring an embolectomy. All complications resolved and had no impact on either surgical procedures performed, wound healing, or ultimate outcome. Minor complications included manageable neutropenia, thrombocytopenia, anemia, nausea, mucositis, alopecia, weight loss, and minor peripheral neuropathy. The majority of patients were found to have a clinically appreciable response to chemotherapy, typically characterized by marked softening and shrinkage of the palpable components. No patient was found to have progression of local disease or development of metastatic disease during induction treatment.

Surgical Resection

Two Group 1 patients and no Group 2 patients required a primary amputation after induction chemotherapy. Both patients amputated had tumors exceeding 10 cm in diameter, involving the popliteal fossa or calf. Of the remaining 31 patients in both groups, all underwent a successful limb-sparing procedure with wide margins

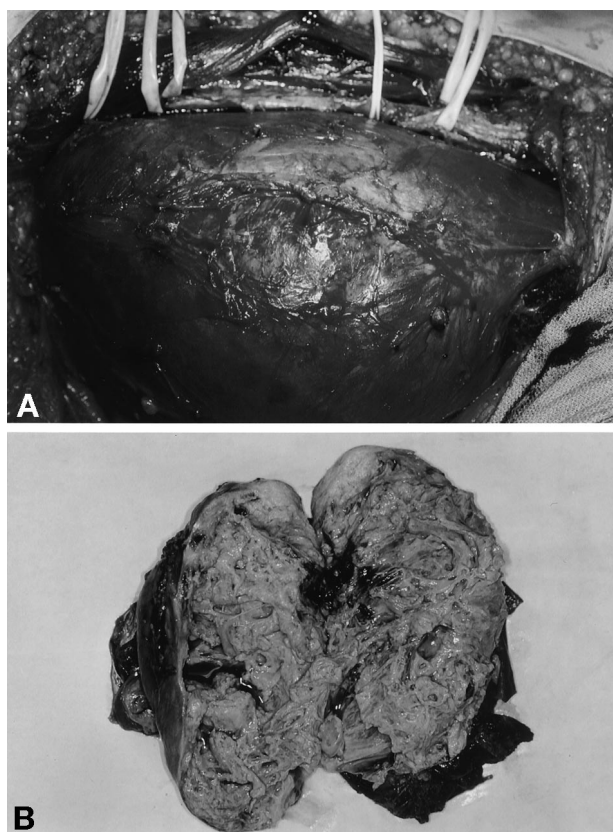


FIG. 3. Limb-sparing resection of a large adductor compartment mass after induction treatment. (A) Dissection of superficial femoral vessels (looped with Penrose drains) showing proximity of the tumor pseudocapsule to the vascular bundle. The surgical margin, consisting of the vascular sheath, was negative. (B) Photograph of gross specimen after sectioning which demonstrates marked involution and necrosis highly suggestive of an excellent response to induction treatment.

(Fig. 3). There were no positive surgical margins after final evaluation of the resected tumor specimen. The overall limb salvage rate was 94%. There were no perioperative deaths and no cardiac or pulmonary complications. There were no deep postoperative wound infections. Superficial skin necrosis was managed with early debridement and secondary wound closure.

Adjuvant Chemotherapy

In Group 1, 15 patients completed the full course of postoperative chemotherapy. Two patients required early cessation because of significant peripheral neuropathy. One patient had a reduction in dosage because of thrombocytopenia. Several patients experienced episodic mucositis or neutropenic sepsis that did not necessitate modification of their chemotherapy.

In Group 2, 13 patients completed the full course of postoperative chemotherapy. One patient received

only 1 adjuvant cycle secondary to severe *Klebsiella* pneumonia and a subsequent diagnosis of renal cell carcinoma. One patient had a reduction of dosage with the final cycle of treatment because of reduced renal function. Significant peripheral neuropathy was not a clinical problem because cisplatin was not given postoperatively in this group.

Histologic Evaluation

All resection specimens underwent detailed histologic evaluation as previously detailed. No patient was found to have a positive surgical margin. Four patients who had undergone subtotal intralesional resection prior to referral had no tumor cells seen in the resection specimen. Of the remaining 29 patients, the percentage of tumor necrosis attributable to the effects of chemotherapy ranged from 50% to 100%, with a median value of 95%. Overall, 22 of 29 patients (76%) had an estimated percent tumor necrosis (or chemotherapy tumor-killing effect) $\geq 90\%$. Patients in Group 1 had a median necrosis of 95%, while patients in Group 2 had a median necrosis of 98%. Both patients who underwent primary amputation had a poor tumor response (necrosis of 60% and 50%, respectively). Percentage tumor necrosis, histologic subtype, tumor size and location are shown in Table 1. Typical histologic effects of chemotherapy on soft tissue sarcomas are shown in Fig. 4.

Analysis of Disease-Free and Overall Survival Rates

All patients were followed longitudinally by the interdisciplinary team. Complete staging studies were repeated every 3 months for the first 2 years, every 6 months for the next 3 years, and yearly thereafter. Staging studies included routine chest CT scans and axial imagery (CT or MRI) of the involved extremity or pelvis. A detailed physical examination of the operative site was performed at the same time by the operative team.

To date, four patients have developed metastatic disease to the lungs, and three have died. Of this subgroup, the surviving patient is doing well with no evidence of disease 17 months after pulmonary metastasectomy. None of these four patients developed locally recurrent disease. Tumors (and the percentage necrosis seen in the resection specimen) resulting in metastatic disease included one MFH (no tumor seen), one synovial cell sarcoma (99% necrosis), and one liposarcoma (60% necrosis), each involving the calf or popliteal fossa; and one leiomyosarcoma (100% necrosis) of the thigh. The patient with the calf liposarcoma was treated with a below-knee amputation; the other patients had a limb-sparing resection. Three patients developed metastases

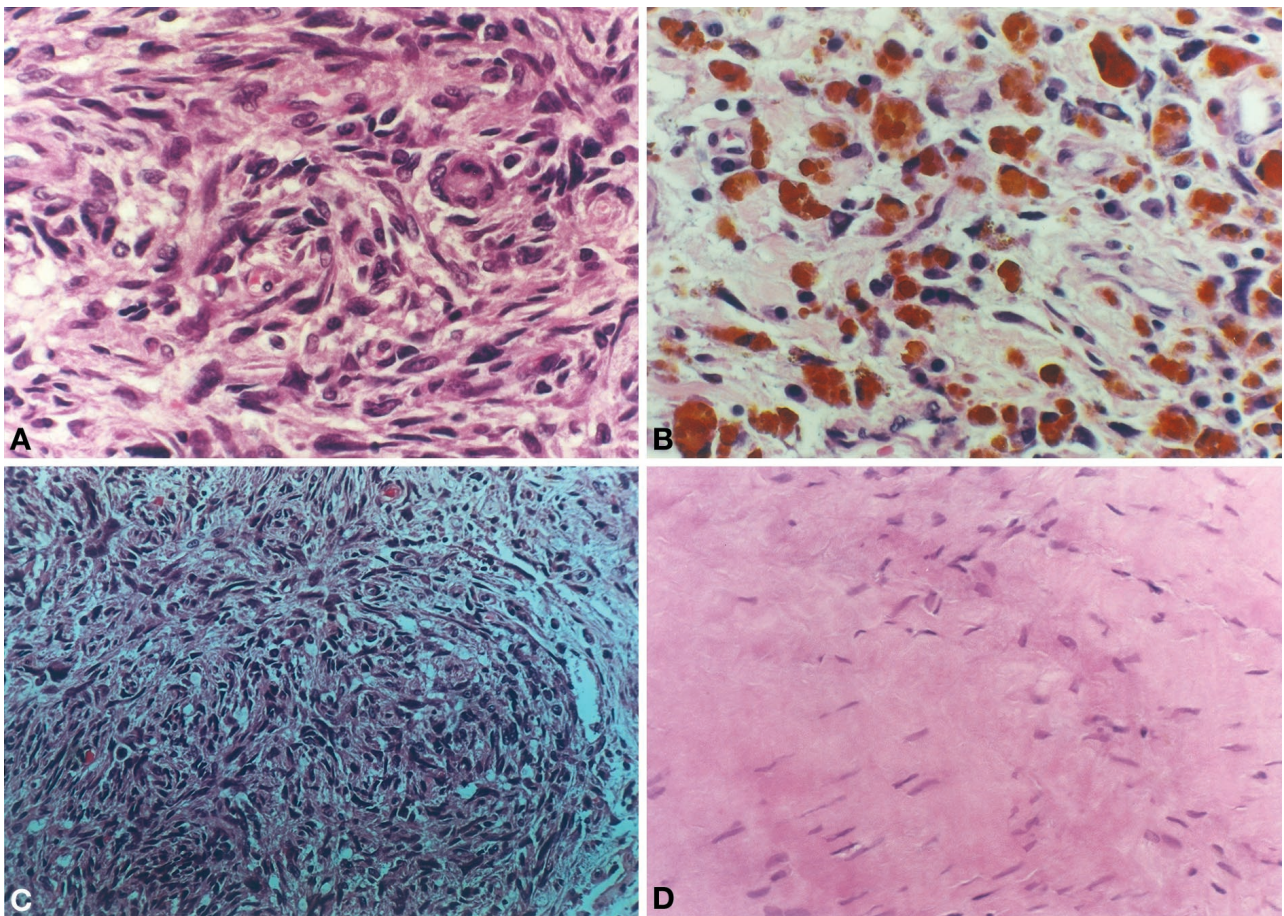


FIG. 4. Histologic effects of induction chemotherapy on high-grade extremity soft tissue sarcomas. (A) Malignant fibrous histiocytoma. (B) MFH after induction treatment demonstrating marked cellular pyknosis and hemosiderin deposition consistent with chemotherapy-induced necrosis. (C) Leiomyosarcoma. (D) Leiomyosarcoma after induction chemotherapy which demonstrates significant tumor regression and fibrin deposition.

within 2 years of surgical resection and the fourth patient developed metastatic disease 39 months postoperatively.

To date, two patients have developed biopsy-proven locally recurrent disease. The first patient had a liposarcoma of the thigh, measuring 21×11.5 cm in size, 90% tumor necrosis, and negative margins in the resection specimen. The local recurrence was identified 17 months postoperatively and was treated with a wide re-resection, followed by external beam radiation. This patient remains alive, free of local or systemic disease, 40 months after his second operation (57 months after his first operation). The second patient with locally recurrent disease had a MFH of the thigh measuring 16×5 cm in size, 95% tumor necrosis, and negative margins in the resection specimen. The local recurrence was diagnosed 16 months after surgical resection. This patient was also treated with wide re-resection of the recurrence, followed by external beam radiation. He subsequently died with

metastatic disease after surviving 106 months after salvage treatment (123 months after his first operation).

No other deaths have occurred in this series. The one patient who was excluded from study (because of death prior to surgical resection) was a 63-year-old female who developed cardiac complications after a single cycle of chemotherapy. One patient has been recently diagnosed with pancreatic cancer, but remains alive at time of study without evidence of recurrent or metastatic sarcoma. One patient underwent radical nephrectomy for a renal cell carcinoma and remains alive without evidence of sarcoma.

Survivorship analysis was performed using the Kaplan-Meier technique with the Greenwood estimate of standard error for both overall and disease-free survival (Figs. 5 and 6). Overall survival was 88% (95% CI, 0.75–1.00) at 5 years and at 10 years. Disease free-survival was 80% (95% CI, 0.68–0.93) at 5 and 10 years.

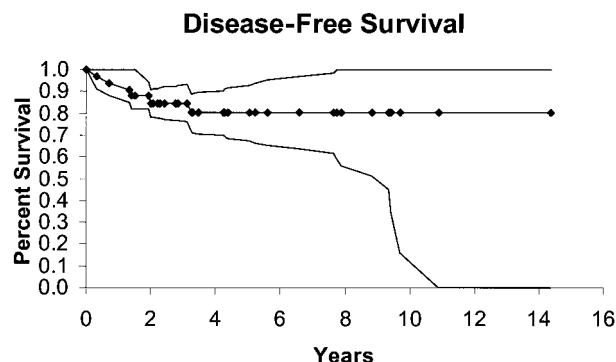


FIG. 5. Kaplan-Meier analysis of disease-free survival with standard measurement of error (Greenwood) for 33 patients with extremity soft tissue sarcomas treated with induction chemotherapy and without radiation.

DISCUSSION

Treatment for soft tissue sarcomas has traditionally consisted of attempted surgical resection of the tumor and extension of the surgical margins through the use of adjuvant external beam radiation. Although accepted in the treatment of bone sarcomas, the use of induction and adjuvant chemotherapy for soft tissue sarcomas remains controversial. Increased survival rates seen in patients with bone sarcomas are typically attributed to the systemic effect of chemotherapy on micrometastatic disease and on circulating viable tumor cells. It is hypothesized that similar gains in survival could be obtained in patients with STS. As a result, a number of adjuvant protocols, using different combinations of drugs, dosages, and routes of administration, have been published.³⁶⁻³⁹ The majority of these studies have used doxorubicin, either alone or in combination with other

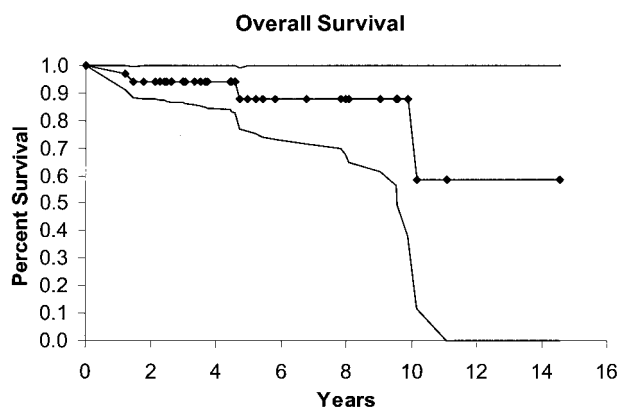


FIG. 6. Kaplan-Meier analysis of overall survival with standard measurement of error (Greenwood) for 33 patients with extremity soft tissue sarcomas treated with induction chemotherapy and without radiation.

agents. A recent meta-analysis of all prospective randomized adjuvant trials reported in the literature showed a moderate but significant improvement in both disease-free (68% vs. 53%, $P < .00001$) and overall survival rates (81% vs. 71%, $P = .0005$) when these patients were compared with those undergoing conventional treatment.⁴⁰ A second meta-analysis of the same data was less conclusive.⁴¹ Most recently, a combined studies meta-analysis of individual patient data, consisting of 1568 patients treated in 14 randomized trials (97% of patients listed in known randomized trials), was reported.⁴² Although showing evidence of improved local, distant, and disease-free survival for patients with STS treated with adjuvant chemotherapy, subset analysis showed that patients with extremity sarcomas ($n = 886$) had a significant absolute benefit in overall survival at 10 years (7%, $P = .029$). Furthermore, a recent randomized adjuvant trial of high-dose epirubicin (a doxorubicin derivative) and ifosfamide, used for 104 patients with high-risk (deep, high-grade, and size >5 cm) extremity STS, showed such a striking significant difference in both disease-free ($P < .001$) and overall survival ($P < .005$) for the adjuvant treatment arm at 24 months that further patient accrual was stopped.⁴³ Additional follow-up of this patient group has continued to show significant differences in survival after 36 months.⁴⁴

Only a handful of reports have been published concerning the use of neoadjuvant chemotherapy for the treatment of soft tissue sarcomas.⁴⁵⁻⁵⁰ The largest experience, as reported by Eilber,⁵⁰ included data on extremity sarcomas treated with five different preoperative protocols (all using adriamycin administered either intra-arterially or intravenously, combined with preoperative radiation). Although their initial experience showed an increase in the local recurrence rate with reduced doses of radiation, their subsequent data showed further reductions in the local recurrence rate when cis platinum was added. An even greater benefit was seen after high-dose ifosfamide was added to their final protocol. Our results, while based on a much smaller sample size, also suggest that dose intensification (with intra-arterial cis platinum, and later with dose-intensive ifosfamide and adriamycin) may be a significant factor in achieving improved patient response. It is our opinion that this accounts for the improved clinical outcomes seen in this subgroup treated without radiation. Although the design of our study does not permit us to judge which factors (drug combination, dosage, timing, or route of administration) are clinically significant, we feel that the use of intra-arterial cis platinum warrants further investigation.

Experience with bone sarcomas has shown that induction treatment can result in tumor shrinkage. Although

induction chemotherapy has not shown any survival advantage compared with adjuvant chemotherapy,⁵¹ this effect may improve the limb salvage rate and extremity function without compromising overall survival. Even small amounts of tumor shrinkage can greatly facilitate limb-sparing tumor resection by making the neurologic and vascular dissection safer. Additional tumor shrinkage can reduce the amount of tissue removed, resulting in improved wound healing and improved functional outcome. Moreover, percentage tumor necrosis, as measured after induction treatment of osteosarcoma, has been found to have significant prognostic implications.^{6,7} The major goal of our original protocol was to assess the effectiveness of neoadjuvant treatment in patients presenting with high-grade tumors that conventionally would require an amputation to achieve an acceptable surgical margin.^{30,35} In particular, we wanted to determine the impact of neoadjuvant chemotherapy on the choice of surgical procedure (i.e., limb-sparing resection or amputation). Only patients for whom a reasonable limb-sparing surgical option did not exist were accepted into the original protocol. This was subsequently modified in the second protocol to include all patients with nonmetastatic, large, high-grade extremity STS.

We recognize that the number of patients in this study is small, limiting the statistical power of our results. In addition, selection bias was present in this study in that some eligible patients did receive radiation (12 of the 46 patients treated with induction chemotherapy during the time frame of this study). Our criteria for recommending adjuvant radiation was based on our judgment that certain patients were at high risk of local recurrence as a result of close surgical margins, previous surgery contaminating multiple compartments, or poor response to induction chemotherapy. A review of the entire series of patients treated with induction chemotherapy, including those who received radiation, revealed very few differences in the two groups. There were no significant differences in tumor size, histologic subtype, or tumor location. All patients in both groups underwent successful surgical resection or amputation with negative margins. The median histologic necrosis of all patients treated with induction chemotherapy was 95%,⁵² similar to that seen in the group of patients presented here. Patients who did receive radiation tended to have close surgical margins (tumor approaching within 1–2 mm of the margin) as well as a tendency for overall lower histologic necrosis. This was expected because the percentage histologic necrosis was a determining factor in recommending patients to receive radiation. There were three local recurrences in the group of 12 who received adjuvant XRT. Two other patients died of metastatic disease without

evidence of local recurrence. Although this fails to reach statistical significance due to small sample size, local recurrence was more common in the subset of patients treated with adjuvant radiation as opposed to those treated without radiation ($P < .074$, χ^2 analysis).

Our experience with induction chemotherapy for soft tissue sarcomas has shown that intensive treatment can have a very positive effect on the limb salvage rate. Conversion of amputation to limb salvage can be attributed to shrinkage of the tumor and better definition of the surrounding pseudocapsule, particularly near critical neurovascular structures. However, attempts to quantify this effect by means other than clinical observation have been unsatisfactory. We feel that this is due, in large part, to the tendency of MRI to overread the size of a sarcoma after induction treatment, as a result of surrounding edema and inflammatory reaction that accompany a regressing tumor mass.

Despite this being a very high-risk patient population, we have only seen two local recurrences after completion of treatment. All patients have been followed for a minimum of two years, a period in which most recurrences would be predicted to occur. Since the major rationale for the use of adjuvant radiation is to reduce the local recurrence rate, this fact itself questions the need for radiation, provided that effective chemotherapy can be given. There was no correlation between patients who developed local recurrence and those who developed metastatic disease. Successful long-term salvage of patients with local recurrence was accomplished by repeat limb-sparing surgical resection and adjuvant radiation. These results clearly suggest that the intrinsic biology of each tumor is a major determinant of patient mortality and that treatment strategies must concentrate on systemic, rather than just local, control of the disease.

Kaplan-Meier survivorship analysis of this patient population demonstrates that intensive chemotherapy, combined with complete surgical resection, can enhance the overall prognosis of patients with large or unresectable high-grade extremity sarcomas. Our overall survival of 88% and relapse-free survival of 80% at 5 and 10 years compares favorably with those reported in any adjuvant chemotherapy study for soft tissue sarcoma. Our results are also consistent with the survival benefits seen in the large meta-analyses. Small numbers and the lack of a randomized control arm limit the impact of these results. However, when compared with historical controls, our results are encouraging. Given the persistent trend away from using radiation for bone sarcomas (including osteosarcoma in the 1940s and 1950s, and Ewing sarcoma in the present era), we anticipate a similar trend for soft tissue sarcomas in the future.

CONCLUSIONS

- The use of intensive induction chemotherapy can profoundly affect surgical options available for achieving local control in patients with high-grade soft tissue sarcomas. Limb-sparing resections can be performed safely in many patients who might otherwise require an amputation. Disease-free and overall survival rates are comparable or better than those reported for other protocols for extremity soft tissue sarcomas.
- Histologic response rates of patients with soft tissue sarcomas who undergo intensive induction chemotherapy are comparable to those seen in patients who undergo induction treatment for osteosarcoma. In addition to demonstrating the effectiveness of chemotherapy, this observation raises the question of whether chemotherapy-induced tumor necrosis may be a prognostic factor in determining overall patient survival as has been shown for osteosarcoma patients.
- Excellent local control and long-term survival are possible without the use of external beam radiation for select patients with large high-grade extremity sarcomas. Elimination of radiation may significantly reduce the associated morbidities that can interfere with patient outcome while preserving the option of using full-dose radiotherapy in the small percentage of patients who develop locally recurrent disease. This concept bears further study for patients with extremity soft tissue sarcomas.
- Although statistically limited by patient enrollment and lack of a control arm, this protocol achieved an overall survival rate comparable or better than those reported by other studies investigating the role of adjuvant chemotherapy for soft tissue sarcomas. As with induction chemotherapy for osteosarcoma, while there may be no difference in overall survival compared with adjuvant chemotherapy, the effect of induction chemotherapy may significantly improve the ability to perform a functional limb-sparing resection.
- Excellent local control of disease can be achieved in patients without the use of radiation provided that the tumor demonstrates a good response to induction chemotherapy and that a good surgical margin is achieved at the time of resection.
- Further investigation and continued clinical trials incorporating induction chemotherapy for the treatment of soft tissue sarcomas are needed and, if possible, should be pursued on a multi-institutional basis.

REFERENCES

1. Eilber F, Giuliano A, Eckardt J, Patterson K, Moseley S, Goodnight J. Adjuvant chemotherapy for osteosarcoma: A randomized prospective trial. *J Clin Oncol* 1987;5:21–26.
2. Link MP, Goorin AM, Horowitz M, et al. Adjuvant chemotherapy of high-grade osteosarcoma of the extremity: Updated results of the multi-institutional osteosarcoma study. *Clin Orthop* 1991;270:8–14.
3. Limb-sparing treatment of adult soft-tissue sarcomas and osteosarcomas. *NIH Consensus Statement*, Bethesda, MD, Dec 3–5, 1984. 5:1–7.
4. Gherlizoni F, Picci P, Bacci G, Campanacci D. Limb sparing versus amputation in osteosarcoma. Correlation between local control, surgical margins and tumor necrosis: Istituto Rizzoli experience. *Ann Oncol* 1992;3:S23–27.
5. Rougraff BT, Simon MA, Kneisl JS, Greenberg DB, Mankin HJ. Limb salvage compared with amputation for osteosarcoma of the distal end of the femur: A long term oncological, functional, and quality of life study. *J Bone Joint Surg* 1994;76A:649–56.
6. Picci P, Sangiorgi L, Rougraff BT, Neff JR, Casadei R, Campanacci M. Relationship of chemotherapy-induced necrosis and surgical margins to local recurrence in osteosarcoma. *J Clin Oncol* 1994;12:2699–2705.
7. Davis AM, Bell PJ. Prognostic factors in osteosarcoma: A critical review. *J Clin Oncol* 1994;12:423–31.
8. Malawer MM, Link MP, Donaldson SS. Sarcomas of Bone: Radiation therapy in the treatment of osteosarcoma. In: Devita VT, Hellman S, Rosenberg SA, eds. *Cancer Principles and Practice of Oncology*. 5th ed., New York: Lippincott-Raven, 1997:1833–4.
9. Williard WC, Hajdu SI, Casper ES, Brennan MF. Comparison of amputation with limb sparing operations for adult soft tissue sarcoma of the extremity. *Ann Surg* 1992;215:269–275.
10. Beech DJ, Pollock RE. Surgical management of primary soft tissue sarcomas. *Hematol Oncol Clin North Am* 1995;9:707–718.
11. Singer S, Corson JM, Gonin R, Labow B, Eberlein TJ. Prognostic factors predictive of survival and local recurrence for extremity soft tissue sarcoma. *Ann Surg* 1994;219:165–173.
12. Talbert ML, Zagars GK, Sherman NE, Rhomdsahl MM. Conservative surgery and radiation therapy for soft tissue sarcoma of the wrist, hand, ankle and foot. *Cancer* 1990;66:2482–2491.
13. Suit HD, Spiro I. Radiation as a therapeutic modality in sarcomas of the soft tissue. *Hematol Oncol Clin North Am* 1995;9:733–746.
14. Harrison LB, Janjan N. Brachytherapy in sarcomas. *Hematol Oncol Clin North Am* 1995;9:747–763.
15. Sadoski C, Suit HD, Rosenberg A, Mankin H, Efid J. Preoperative radiation, surgical margins and local control of extremity sarcomas of soft tissue. *J Surg Oncol* 1993;5:223–230.
16. Benjamin RS, Wiernik PH, Bachur NR. Adriamycin. A new effective agent in the therapy of disseminated sarcomas. *Med Pediatr Oncol* 1975;1:63–76.
17. Creagan ET, Hahn RG, Ahmann DL, Bisel HF. A clinical trial of adriamycin (NSC 123127) in advanced sarcomas. *Oncology* 1977;34:90–1.
18. Samson MK, Baker LH, Benjamin RS, Lane M, Plager C. Cis-dichlorodiamine-platinum (II) in Advanced Soft Tissue and Bony Sarcomas. A Southwest Oncology Group Study. *Cancer Treat Rep* 1979;63:2027–9.
19. Karakousis CP, Holtermann OA, Holyoke ED. Cis-dichlorodiamine-platinum (II) in Metastatic Soft Tissue Sarcomas. *Cancer Treat Rep* 1979;63:2071–5.
20. Brenner J, Magill GB, Sordillo PP, Cheng EW, Yagoda A. Phase II Trial of Cisplatin (CPDD) in Previously Treated Patients with Advanced Soft Tissue Sarcomas. *Cancer* 1982;50:2031–3.
21. Jelic S, Koucin V, Milanovic N, et al. Randomized study of high-dose epirubicin versus high-dose epirubicin-cisplatin chemotherapy for advanced soft tissue sarcoma. *Eur J Cancer* 1997;33:220–225.
22. Elias A, Ryan L, Sulkes A, Collins J, Aisner J, Antman KH. Response to mesna, doxorubicin, ifosfamide, and dacarbazine in 108 Patients with metastatic or unresectable sarcoma and no prior chemotherapy. *J Clin Oncol* 1989;7:1208–1216.
23. Bramwell V, Quirt I, Warr D, et al. Combination chemotherapy

- with doxorubicin, dacarbazine, and ifosfamide in advanced adult soft tissue sarcoma. *J Natl Cancer Inst* 1989;81:1496-1499.
24. Santoro A, Rouesse J, Steward W, et al. A randomized EORTC study in advanced soft tissue sarcoma (STS): ADM vs ADM + IFX vs CYVADIC. *Proc Annu Meet Am Soc Clin Oncol* 1990;9:A1196.
 25. Edmonson JH, Ryan LM, Blum RH, et al. Randomized comparison of doxorubicin alone versus ifosfamide plus doxorubicin or mitomycin, doxorubicin, and cisplatin against advanced soft tissue sarcomas. *J Clin Oncol* 1993;11:1269-75.
 26. Azzarelli A, Quagliuolo V, Casali F, Fissi S, Montalto F, Santoro A. Preoperative doxorubicin plus ifosfamide in primary soft tissue sarcomas of the extremities. *Cancer Chemother Pharmacol* 1993;31:S210-2.
 27. Demetri GD, Elias AD. Results of single-agent and combination chemotherapy for advanced soft tissue sarcomas. *Hematol Oncol Clin North Am* 1995;9:3:765-785.
 28. Patel SR, Vадjan-Raj S, Burgess MA, et al. Results of two consecutive trials of dose intensive chemotherapy with doxorubicin and ifosfamide in patients with sarcomas. *Am J Clin Oncol* 1998;21:317-321.
 29. Patel SR, Benjamin RS. New chemotherapeutic strategies for soft tissue sarcomas. *Semin Surg Oncol* 1999;17:47-51.
 30. Henshaw RM, Valente A, Shmookler BM, Prieбат D, Malawer MM. (Paper 180) Limb salvage, histologic necrosis and disease free survival for unresectable soft tissue sarcomas treated with neoadjuvant intra-arterial chemotherapy and attempted surgical resection. Paper presented at: 64th Annual Meeting of the American Academy of Orthopaedic Surgeons; February 1997; San Francisco, CA.
 31. Casper ES, Gaynor JJ, Hajdu SI, et al. A prospective randomized trial of adjuvant chemotherapy with bolus versus continuous infusion of doxorubicin in patients with high-grade extremity soft tissue sarcoma and an analysis of prognostic factors. *Cancer* 1991;68:1221-1229.
 32. Chan HG, Gross JF. Intra-arterial infusion of anti-cancer drugs: theoretic aspects of drug delivery and review of responses. *Cancer Treat Rep* 1980;64:31.
 33. Mavligit GM, Benjamin R, Patt YZ, et al. Intraarterial cis-platinum for patients with inoperable skeletal tumors. *Cancer* 1981;48:1-4.
 34. Jaffe N, Knapp J, Chuang VP. Osteosarcoma. Intra-arterial treatment of the primary tumor with cis-diammine-dichloroplatinum II (CDP). Angiographic, pathologic, and pharmacologic studies. *Cancer* 1983;51:402-407.
 35. Prieбат D, Malawer MM, Markan Y, et al. Clinical outcome of neoadjuvant intraarterial cisplatin and continuous intravenous infusion adriamycin for large high-grade unresectable/borderline soft tissue sarcomas of the extremities. *Proc Annu Meet Am Soc Clin Oncol* 1994;13:A1648.
 36. Chang AE, Kinsella T, Glatstein E, et al. Adjuvant chemotherapy for patients with high-grade soft tissue sarcomas of the extremity. *J Clin Oncol* 1988;6:1491-1500.
 37. Gherlinzoni F, Picca P, Bacci G, et al. Late results of a randomized trial for the treatment of soft tissue sarcomas (STS) of the extremities in adult patients. *Proc Annu Meet Am Soc Clin Oncol* 1993;12:A1633.
 38. Bramwell V, Rouesse J, Steward W, et al. Adjuvant CYVADIC chemotherapy for adult soft tissue sarcoma—reduced local recurrence but no improvement in survival: a study of the European Organization for Research and Treatment of Cancer Soft Tissue and Bone Sarcoma Group. *J Clin Oncol* 1994;12:1137-49.
 39. Mertens WC, Bramwell VH. Adjuvant chemotherapy in the treatment of soft tissue sarcoma. *Clin Orthop* 1993;289:81-93.
 40. Zalupski MM, Baker LH. Systemic adjuvant chemotherapy for soft tissue sarcomas. *Hematol Oncol Clin North Am* 1995;9:787-800.
 41. Tierney JF, Mosseri V, Stewart LA, Souhami RL, Parmar MK. Adjuvant chemotherapy for soft-tissue sarcoma: review and meta-analysis of the published results of randomised clinical trials. *Br J Cancer* 1995;72:469-75.
 42. Tierney JF. Adjuvant chemotherapy for localized unresectable soft tissue sarcoma of adults. Meta-analysis of individualized data. *Lancet* 1997;350:1647-1654.
 43. Frustaci S, Gherlinzoni F, De Pauli A, et al. Preliminary results of an adjuvant randomized trial on high risk extremity soft tissue sarcomas (STS). The interim analysis. *Proc Annu Meet Am Soc Clin Oncol* 1997;16:A1785.
 44. Frustaci S, Gherlinzoni F, De Pauli A, et al. Maintenance of efficacy of adjuvant chemotherapy in soft tissue sarcoma of the extremities. Update of a randomized trial. *Proc Annu Meet Am Soc Clin Oncol* 1999;18:A2108.
 45. Rouesse JG, Friedman S, Sevin DM, et al. Preoperative induction chemotherapy in the treatment of locally advanced soft tissue sarcomas. *Cancer* 1987;60:296-300.
 46. Pezzi CM, Pollock RE, Evans HL, et al. Preoperative chemotherapy for soft tissue sarcomas of the extremities. *Ann Surg* 1990;211:476-481.
 47. Rahoty P, Konya A. Results of preoperative neoadjuvant chemotherapy and surgery in the management of patients with soft tissue sarcoma. *Eur J Surg Oncol* 1993;19:641-5.
 48. Eilber F, Eckardt J, Rosen G, Forscher C, Selch M, Fu YS. Improved complete response rate with neoadjuvant chemotherapy and radiation for high grade extremity soft tissue sarcoma. *Proc Annu Meet Am Soc Clin Oncol* 1994;13:A1645.
 49. Casper ES, Gaynor JJ, Harrison LB, Panicek DM, Hajdu SI, Brennan MF. Preoperative and postoperative adjuvant combination chemotherapy for adults with high grade soft tissue sarcoma. *Cancer* 1994;73:1644-51.
 50. Eilber F, Eckardt J, Rosen G, Forscher C, Selch M, Fu YS. Preoperative therapy for soft tissue sarcomas. *Hematol Oncol Clin North Am* 1995;9:817-23.
 51. Goorin A, Schwartzentruber D, Gieser P, et al. No evidence for improved event free survival with presurgical chemotherapy for non-metastatic extremity osteogenic sarcoma: preliminary results of a randomized pediatric oncology group trial 8651, an update. *Med Pediatr Oncol* 1996;27:263.
 52. Henshaw RM, Shmookler BM, Malawer MM. Histologic response of high-grade soft tissue sarcomas to induction chemotherapy. Paper presented at: Connective Tissue Oncology Society Annual Meeting; October 1999; Arlington, VA.