

Incarceration of sessile uterine fibroids in an incisional hernia in a postmenopausal woman: a case report

Akintunde O. Fehintola¹ · Olusayo I. Amole² · Ayotunde O. Ogunlaja¹ ·
Olufemi T. Awotunde¹ · Olurotimi I. Aaron³ · B. Bakare⁴ · Adewumi O. Durodola² ·
Gbemi H. Ano-Edward⁵

Received: 14 July 2015 / Accepted: 10 November 2015 / Published online: 4 December 2015
© Springer-Verlag Berlin Heidelberg 2015

Abstract Incarceration of sessile fibroids in an incisional hernia is uncommon and can cause pain and discomfort. Very few cases have been reported in the literature but none in our region in women in the postmenopausal period. We present an uncommon case of a 57-year-old primipara with a previous history of caesarean section and a laparotomy on account of adhesive intestinal obstruction. She presented with lower abdominal swelling and abdominal pain since 7 years. She had surgical removal of the mass and total abdominal hysterectomy with mesh repair of the incisional hernia. Histology of the resected hernia content revealed leiomyoma. Abdominal wall fibroid is a good differential diagnosis to be considered in any woman with an anterior abdominal mass and previous uterine surgery, including caesarean section.

Keywords Leiomyoma · Incisional hernia · Postmenopausal woman

✉ Akintunde O. Fehintola
akintunds@yahoo.com

¹ Department of Obstetrics and Gynaecology, Bowen University Teaching Hospital, Ogbomosho, Oyo State, Nigeria

² Department of Surgery, Bowen University Teaching Hospital, Ogbomosho, Oyo State, Nigeria

³ Department of Anaesthesia, Bowen University Teaching Hospital, Ogbomosho, Oyo State, Nigeria

⁴ Department of Obstetrics & Gynaecology, State Hospital, Ondo, Ondo State, Nigeria

⁵ Department of Anatomic Pathology, Bowen University Teaching Hospital, Ogbomosho, Oyo State, Nigeria

Introduction

Fibroids also called leiomyoma are said to be the most common benign tumour of the reproductive tract and are clinically apparent in 20 % of women of reproductive age. They may be present in as many as 70 % of uteri removed at hysterectomy [1]. The most common site is the uterus but they are also found in the broad ligament, ovaries and vagina. Incarceration of uterine fibroids in incisional hernia in the anterior abdominal wall is a rare presentation [2–5]. Uterine fibroids are associated with infertility, menorrhagia, pain and compression symptoms when they are extended.

An incisional hernia is one that develops in the scar of a surgical incision. There is a risk of strangulation with a narrow neck and large sac. Thin-walled hernias may ulcerate and develop intestinal fistula. The long-term incidence in best centres is 10 %. Predisposing factors are obesity, age, wound infection and incisions of more than 18 cm. Common contents are the omentum, transverse colon, loops of small bowel and stomach [6].

Although gravid uterus in an incisional hernia has been reported earlier [7], the occurrence of incisional hernia 24 years after laparotomy with a sessile uterine fibroid as its content in the postmenopausal woman is extremely rare (Figs. 1, 2, 3, 4, and 5).

Case report

We present a case of a 57-year-old para 1 + 2, 6 years postmenopausal woman with a previous history of caesarean section and a previous laparotomy. She was seen at the gynaecological clinic with a 7-year history of progressive lower abdominal swelling which later became associated with pain. Her last delivery was in 1989 by caesarean section.

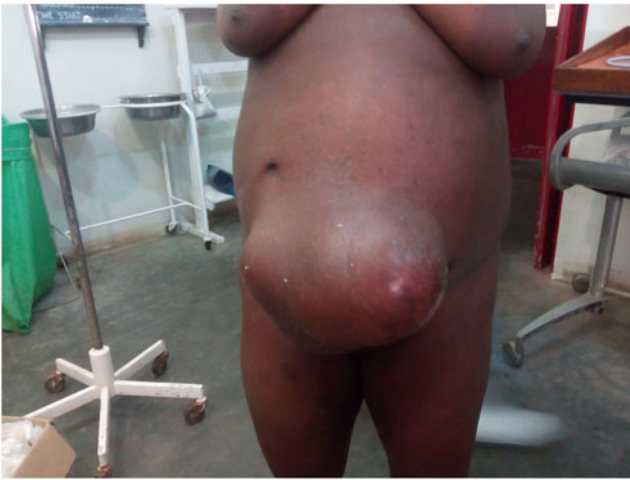

Fig. 1 Patient's picture in erect position

Two years later, she had a laparotomy on account of adhesive intestinal obstruction. She was asymptomatic until 7 years prior to presentation when she noticed a swelling around her umbilicus that was progressively increasing in size with associated pain.

On clinical examination, we saw a woman in good general condition with normal vitals, clear lungs and a soft abdomen. A mass in the lower right abdomen was palpated with a size of 28×22 cm and not reducible. The mass was firm and mildly tender with irregular surface; transillumination was negative and cough impulse was present. A 3×2 -cm gap was felt in the linea alba in the infra-umbilical region when the patient was asked to raise her leg or neck while on supine position without the support of arms. She was diagnosed as a case of irreducible incisional hernia with an abdominal mass as its content.

This was corroborated by the abdominopelvic ultrasound scanning that was done.

Under spinal anaesthesia converted to general anaesthesia through a mid-line supra-umbilical incision, the sac was

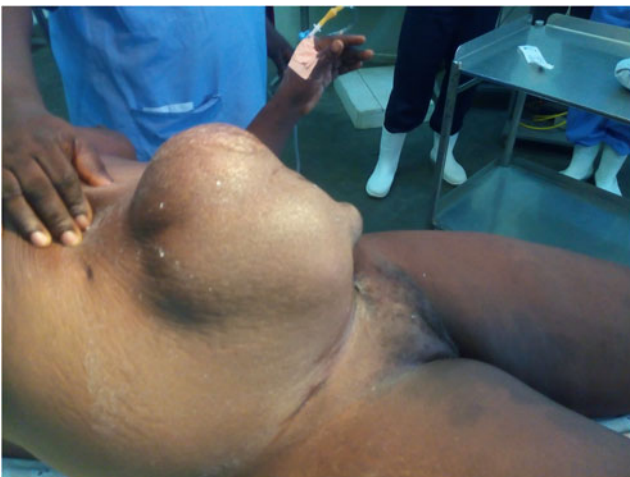

Fig. 2 Irreducible hernia content with patient in supine position

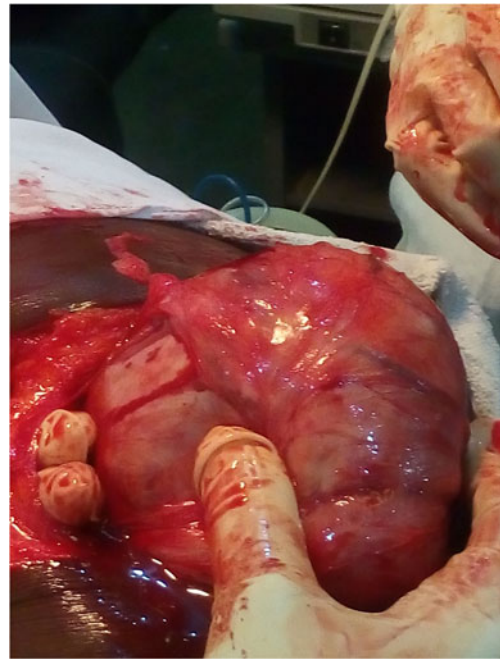

Fig. 3 Fingers of the surgeon forced in between the neck of the hernia sac and the content

defined and opened and a huge sessile fibroid located on the fundus of a bulky uterus was found lying outside the sac. Adhesions with parietal peritoneum were released. The bladder was catheterized and dissected free from the uterus; planes were defined and a subtotal hysterectomy with bilateral salpingo-oophorectomy was performed. Extra margins of sac with extra-peritoneal fat were excised. The large abdominal

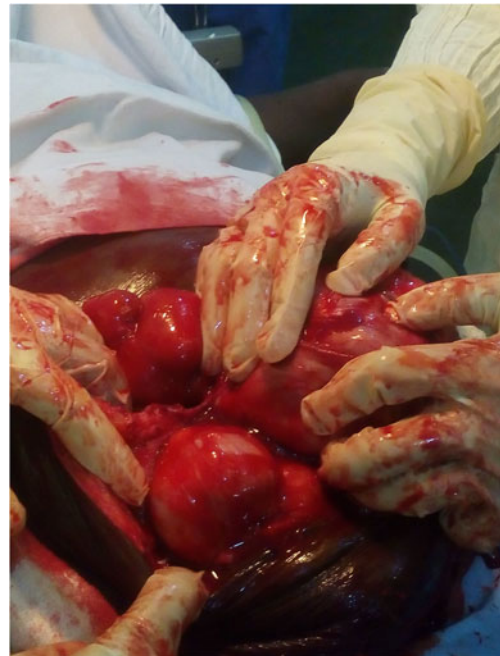

Fig. 4 Point of attachment of the content of the hernia to the fundus of the uterus

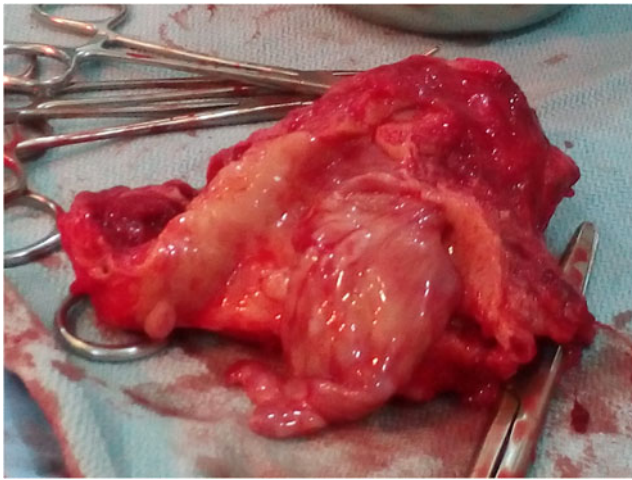


Fig. 5 Cut section of the uterus showing endometrial polyp after hysterectomy

defect was repaired with the use of a Premilene® mesh (Aesculap & Co, Germany). Estimated blood loss was 1.2 l. She was transfused with 2 pints of fresh whole blood during the surgery and another 2 pints in the immediate postoperative period. Antimicrobial prophylaxis with intravenous cefatoxime was given to obviate infection due to prolonged tissue handling. Postoperatively, the patient made an uneventful recovery. She was discharged on the 13th postoperative day.

Histopathological examination of the specimen showed a leiomyoma (fibroid). Cut section of the mass showed white fleshy tissue, and microscopic examination of the specimen showed spindle-shaped cells arranged in whorls consistent with fibroid with no evidence of malignancy.

Discussion

Uterine fibroids are a major cause of morbidity in women of a reproductive age (and sometimes even after menopause). The most likely presentation of fibroids is by their influence on the woman's menstrual cycle or pelvic pressure symptoms. Incarceration of sessile fibroid in abdominal hernia leading to pain is a rare presentation of uterine fibroids. Fibroid is an oestrogen-dependent tumour and commonly regresses after menopause. Leiomyosarcoma is a very rare entity that should be suspected in postmenopausal women with fibroid growth (and without concurrent hormone replacement therapy). In our patient, the fibroid failed to shrink despite her menopausal status but histology showed no malignant changes.

Incisional hernia is one that develops in the scar of a surgical incision. Most incisional hernias (66 %) develop within 5 years. The remaining hernias (33 %) develop in the next 5–10 years [3]. The occurrence of a incisional hernia 24 years after a laparotomy is rare. Although gravid uterus in an

incisional hernia has been reported earlier [2], the presence of a huge incarcerated sessile leiomyoma in an incisional hernia is seldom seen especially in postmenopausal period. Recently, a case involving the urinary bladder has been reported [4]. The causal factors in this case were age and increased intraabdominal pressure from the growing pelvic tumour. Ageing and weakening of tissues and the raised intraabdominal pressure associated with chronic cough and constipation are cited as factors. Several case reports have been written on incarceration of pedunculated and sessile subserosal fibroids in incisional hernia in pregnancy [5, 6]. The risk of incarceration is much lower in sessile fibroid compared to pedunculated type due to limited mobility. The progression of pregnancy makes sessile fibroid displace cranially onto the anterior wall of the uterus. During this process, compression of the uterus in the posterior to anterior direction in the abdominal cavity may cause the fibroid to be easily entrapped in the umbilical opening of the hernial sac.

The mechanism of incarceration of sessile fibroids in a non-pregnant uterus is difficult to explain. The only plausible explanation in our patient is the fact that the uterus was bulk, about 12 weeks in size containing multiple fibroids therefore has become an abdominal organ leading to an increase intraabdominal pressure.

The neck of the umbilical hernia, as in our patient, is usually quite narrow compared with the size of the hernial mass, and strangulation is therefore common [7]. Operative method used in this case was fascial repair using synthetic non-absorbable prolene mesh closure as it was difficult to appose the fascia without tension. Other methods include shoelace repair [5], fascial repair resuture technique and laparoscopic mesh repair [8]. There is no consensus on the best technique for the repair of umbilical hernia in adults [8]. The Mayo technique is known worldwide and is still one of the most frequently performed surgical techniques for the repair of the umbilical hernia. Very few randomized clinical studies have been published on this subject. However, it has been reported that the recurrence rate is 20 % and higher with this technique and its alternatives [6]. During a randomized clinical study involving 200 patients, Arroyo et al. [9] compared primary suture with mesh repair in the repair of adult primary umbilical hernia. A polypropylene plug was placed in small umbilical defects (<3 cm), whereas large defects (>3 cm in diameter) were repaired with polypropylene mesh. In the 64-month follow-up period, the recurrence rate was 11 % in the primary group and 1 % in the mesh group [9].

The authors suggested that mesh repair should be the standard treatment for primary umbilical hernia in adults. Kurzer et al. [8] did not observe any recurrences in a 43-month follow-up study of patients in whom a mesh plug was used in defects smaller than 3 cm and prolene mesh was used in defects larger than 3 cm in a method similar to that described by Arroyo et al. Based on a review of recurrence rates in

umbilical hernia, Schumacher et al. [10] suggested that the recurrence rate was correlated with the body weight and width of the hernia orifice.

They recommended that mesh be used to repair hernia in patients whose body mass index is higher than 30 and a hernia orifice larger than 3 cm; however, when the orifice is in the range of 2–3 cm, the decision to use mesh should be made on the basis of individual variations.

Conclusion

In conclusion, fibroids should be kept in mind as a rare underlying factor for incarcerated hernias in women irrespective of their age. If the contents of the hernia sac cannot be pushed into the abdominal cavity easily, a surgical intervention with the possibility to use mesh should be planned to prevent further complications.

Acknowledgments I am using this opportunity to acknowledge the useful contributions from Professor Adesegun Fatusi, Dr. Funmito Fehintola and Dr. Olorunfemi Ogundele of the Community Health Department, Obafemi Awolowo University Teaching Hospitals Complex, Ile Ife, Osun State, Nigeria, for their inputs in writing of this article.

Compliance with ethical standards

Informed consent Written informed consent was obtained from the patient for publication of this case presentation and accompanying image. A copy of the written consent is available for review by the editor-in-chief of this journal.

Conflict of interest The authors declare that they have no competing interests.

Disclosure statement None for all authors.

Additional file Exploratory laparotomy. Pictures showing the exploratory laparotomy and total abdominal hysterectomy with mesh repair of the hernia.

References

1. Abrahamson J. Hernias in Micheal J. Zinner, Seymour I. Schwartz, Harold Ellis (editors). In Maingot's, abdominal operations vol I, 10th ed. Appleton and Lounge, 1997,548–72.
2. Banerjee N, Deka D, Sinha A (2001) Gravid uterus in an incisional hernia. *Gynaecol Res* 27(2):77–79
3. Stoppa R. Hernia of the abdominal wall. In: Chevrel JP (ed). *Surgery of the abdominal wall*. Berlin: Springer-Verlag 1987:55–60.
4. Boughey JC, Nottingham JM (2002) Massive incisional hernia of the bowel and urinary bladder: a case report. *Am Surg* 68(10):892–894
5. Abrahamson J, Elder S (1988) 'Shoelace' repair of large post operative ventral abdominal hernias: a simple extra peritoneal technique. *Contemp Surg* 33:24–30
6. Muschaweck U (2003) Umbilical and epigastric hernia repair. *Surg Clin North Am* 83:1207–1221
7. Abrahamson J, Gorman J (2000) Pregnancy and ventral hernia repair. *Hernia* 4:187–191
8. Kurzer M, Belsham PA, Kark AE (2004) Tension-free mesh repair of umbilical hernia as a day case using local anaesthesia. *Hernia* 8: 104–107
9. Arroyo A, Garcia P, Perez F, Andreu J, Candela F, Calpena R (2001) Randomized clinical trial comparing suture and mesh repair of umbilical hernia in adults. *Br J Surg* 88:1321–1323
10. Schumacher OP, Peiper C, Lorken M, Schumpelick V (2003) Long-term results after Spitzzy's umbilical hernia repair. *Chirurgia* 74:50–54