

Long-term survival after hand-assisted laparoscopic approach of primary retroperitoneal mucinous cystadenocarcinoma in male: case report and review of literature

J.-P. Shiau, C.-T. Wu, C.-C. Chin, C.-K. Chuang

Received: 6 June 2011 / Accepted: 12 November 2012 / Published online: 4 December 2012
© The Author(s) 2012. This article is published with open access at Springerlink.com

Summary

Background Primary retroperitoneal mucinous cystadenocarcinoma (PRMC) is a rare disease and mostly occurs in females, and there are only three male cases described in the literatures without long-term follow-up.

Case report A 59-year-old male presented with a left retroperitoneal cystic mass (7.5×7×3 cm) that upwardly displaced the left kidney and caused abdominal discomfort. The tumor was totally excised by the hand-assisted laparoscopic method without complications or recurrence in a follow-up period of 79 months. The etiology from coelomic metaplasia of peritoneal epithelium was proved by a spectrum of diverse cells (benign, borderline malignant, and malignant cells) during pathological examination.

Results This is the fourth male case of PRMC in the world with a favorable outcome after hand-assisted lap-

aroscopic excision, and this is also distinct by the longest follow-up period in this disease entity.

Conclusions Because of its low-malignant potential and recurrence rate, surgical excision is still the best choice of treatment, but the least invasion method should be adopted in front.

Keywords: Primary mucinous cystadenocarcinoma, Retroperitoneal, Male, Laparoscopy

Introduction

Primary retroperitoneal mucinous cystadenocarcinoma (PRMC) is an extremely rare tumor. The first case was presented in 1977 [1], and total 36 cases were reported in the English literature, three of whom were male patients. Because of its rarity, the pathogenesis and biological behavior of this neoplasm is still ambiguous, so is its staging system. It is widely accepted that total resection without rupture and careful investigation of possible origins during surgery is the best strategy. We reported the fourth male case of PRMC in the world with the longest survival till date, who was also the first one treated by the hand-assisted laparoscopic approach without complications.

Case report

A 59-year-old male experienced the sudden onset of left flank pain without radiation, which was dullness and persistent, but not alleviated by posture change. Physical examination did not disclose palpable intraabdominal mass and definite tender point. Results of the routine laboratory tests, chest X-ray, and tumor markers (CA-125 and carcinoembryonic antigen) were normal. Intravenous urography showed an 8 cm space-occupying lesion just

C.-T. Wu, MD (✉)

Division of Urology, Chang Gung Memorial Hospital and Chang Gung University, No. 222, Maijin Rd., Anle Dist., 204 Keelung City, Taiwan (R.O.C.)

e-mail: chuntewu@cgmh.org.tw

J.-P. Shiau, MD

Department of Surgery, Chang Gung Memorial Hospital and Chang Gung University, No. 5, Fuxing St., Guishan Township, 333 Taoyuan County, Taiwan (R.O.C.)

e-mail: gp5066@gmail.com

C.-C. Chin, MD

Department of Pathology, Chang Gung Memorial Hospital and Chang Gung University, No. 5, Fuxing St., Guishan Township, 333 Taoyuan County, Taiwan (R.O.C.)

e-mail: chinchihching@gmail.com

C.-K. Chuang, MD

Division of Urology, Chang Gung Memorial Hospital and Chang Gung University, No. 5, Fuxing St., Guishan Township, 333 Taoyuan County, Taiwan (R.O.C.)

e-mail: chuang89@cgmh.org.tw

Fig. 1 Computed tomography showed a well-capsulated calcified tumor with heterogenous content in the left retroperitoneal space (a), which upwardly displaced the left kidney (b)

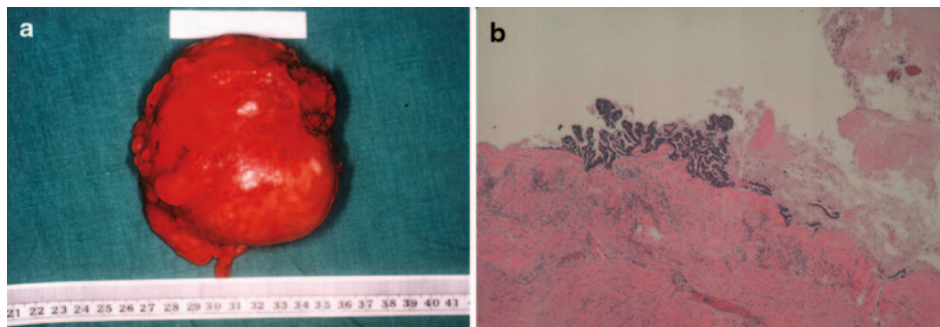
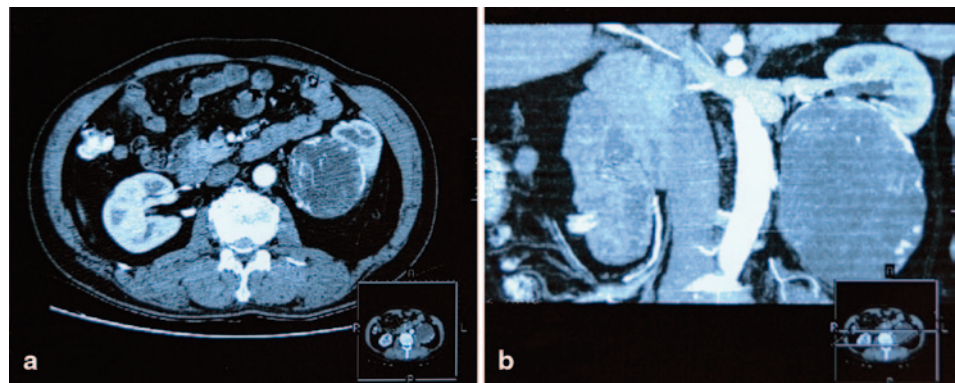


Fig. 2 a Grossly, the specimen measured 7.5×7×3 cm with smooth and glistening outer surface. It consisted of dark-brown viscid fluid within a thin-walled unilocular capsule, with some focal papillary tufting over the inner surface. **b** Micro-

scopically, the capsule wall was covered by single or multiple layers of mucinous epithelium, with histological sequential distribution of benign, borderline malignant, and malignant cells

below the left kidney, which displaced the left renal axis. Computed tomography (CT) revealed a well-capsulated tumor with heterogenous content and calcification in the left retroperitoneal space, which upwardly displaced the left kidney (Fig. 1). Hand-assisted laparoscopic surgery was performed and the tumor was completely resected without rupture. The stomach, gallbladder, small intestines, appendix, colon, and omentum were explored and no suspicious lesions were disclosed. Grossly, the specimen was measured 7.5×7×3 cm and consisted of dark-brown viscid fluid within a thin-walled unilocular capsule. The outer surface was smooth and glistening, with some focal papillary tufting over the inner surface (Fig. 2a).

Microscopically, the capsule wall was covered by single or multiple layers of mucinous epithelium, with histological sequential distribution of benign, borderline malignant, and malignant cells. Obvious cytological atypia, foci of stromal invasion and lymphoid aggregates, and extensive calcification were also noted (Fig. 2b). PRMC with well differentiation was the final pathological diagnosis. The postoperative course was uneventful, and no evidence of recurrence was observed within a 79-months follow-up period.

Discussion

A mucinous cystadenocarcinoma usually presents as a large cystic structure in the genital tract, and it has the

tendency to occur simultaneously at different sites such as the respiratory tract, gastrointestinal tract, and other extraabdominal areas. However, it rarely occurs in the retroperitoneal space: only 36 cases were reported, three of whom were male.

In 1994, Motoyama et al. [2] first reported a 42-year-old male case without sufficient clinical data. Thamboo et al. [3] reported the second case undergoing the laparotomy approach with 18-months follow-up. The third male patient with 6-months follow-up after laparotomy was described by Green et al. [4] in 2007. The demographic data was listed in Table 1, and the treatment strategies were all completely surgical resection without lymphadenopathy or chemotherapy. All the four male patients (including the present one) presented abdominal discomfort and slow-growing abdominal mass without any specific signs or symptoms, which was compatible with the previous survey in females [4, 5]. Statistically, the male patients are older in age than females (67.25 vs. 43 years old, respectively) [5].

The mucinous cystadenocarcinoma may occur at two different organs concurrently, and therefore the preoperative survey of the exact origins is very important [6]. Usually, they could metastasize from the uterus, ovaries, fallopian tubes, cervix, bladder, appendix, urachus, gall bladder, ureter, pancreas, bowel, or breast. CA-125 and carcinoembryonic antigen (CEA) level may disclose hint in investigating the possible etiology, but provide no benefits in differentiating the exact origin [4, 7]. Some

Table 1. Comparison of four male PRMC cases

	Age	Size (cm)	Symptoms	Diagnostic tool	Pathology	Location	Operation	Follow up (months)
Motoyama et al. [2]	63	6×4×3	NA	Explore laparotomy	Borderline	Right retroperitoneum	Laparotomy	NA
Thamboo et al. [3]	64	24×20×16	Abdominal pain, left flank palpable mass	CT	Mixed	Left retroperitoneum	Laparotomy	NR (18)
Green et al. [4]	83	26×20×16	Severe cachexia, abdominal pain, and palpable mass	CT	Malignant	Right retroperitoneum	Laparotomy	NR (6)
Present case	59	7.5×7×3	Left abdominal pain	CT	Mixed	Left retroperitoneum	Hand-assisted laparoscopy	NR (79)

PRMC primary retroperitoneal mucinous cystadenocarcinoma, *NA* not available, *NR* no recurrence, *CT* computed tomography

authors postulated that the exact origin should only be determined during surgery with careful exclusion of the other possible origins, rather than preoperative image survey [6]. However, the primary origin site was detected by exploring laparotomy in the first case, while the other cases were investigated the origins through CT. Only one case was mistakenly deem kidney as the primary origin in the initial review of the radiologist [4].

Because of its rarity, the etiology and biological behavior of PRMC are still ambiguous. In an attempt to explain its origin, there are four hypotheses being postulated: (1) heterotopic ovarian tissue or supernumerary ovary [6], (2) monodermal teratomas [8], (3) embryonal urogenital remnants [9], and (4) coelomic metaplasia [4, 5]. Nevertheless, most of the hypotheses were based upon female patients; the possible origins of male PRMC still require further investigation. We simply excluded the origin of heterotopic ovarian tissue because of the gender-specific characteristics. Monodermal proliferation of columnar epithelium and the cyst architecture composed all the structure without any teratoma-like components, so the possibility of teratoma origin can be excluded [5, 10]. Embryonal urogenital remnants are least likely because glomeruli, renal tubules, chorion, or other genital tissue were not discovered in the specimen [9].

Therefore, the hypothesis of coelomic metaplasia is the most appropriate etiology of the disease in males, which is also advocated by many reports [1-3, 5, 7]. During embryogenesis, the coelomic epithelial cells from the urogenital ridge are deposited along the retroperitoneal area during embryonic descent [10]. The peritoneal epithelium may act as epithelial ovarian tissue and conduct the process of mullerian differentiation. Thereafter, these epithelial cells cluster and form the inclusion cyst [4, 5]. Subsequently, the coelomic epitheliums of these cysts undergo metaplasia and develop a spectrum of histological cells in different stages [9]. As this case, cells of PRMC displayed a histology continuum since primary retroperitoneal mucinous cystadenomas, borderline tumors, and benign cells are found in the same specimen [2, 5]. As cell transformation needs a course of metaplasia, the male patients usually develop the disease in the middle age.

Currently, complete resection without rupture is the standard strategy and the most important prognostic

factor, and whether lymphadenectomy or adjuvant chemotherapy provides benefit is still controversial [5, 7]. Among the previous 36 cases, only three had died of their disease, and only one had recurrent mucinous cystadenocarcinoma after surgical resection [5]. However, the long-term survival (more than 5 years) of this disease entity was only disclosed in three cases (all were females) [7, 11], herein we proposed the longest survival after surgical treatment. Dealing with such a low-malignant disease entity, less-invasive surgical procedure can provide benefits of less pain, shorter hospitalization period, and earlier return to daily life. Herein, we suggest hand-assisted laparoscopic approach, because it provides the following advantages: (1) smaller incision wound comparing to laparotomy, but still allowing the tumor to pass without rupture; (2) adequate manipulating tumor and adjacent organs to explore other possible origin sites by hand; and (3) lesser operation time in comparison with the simply laparoscopic method.

Conflict of interest

There is no conflict of interest.

Open Access This article is distributed under the terms of the Creative Commons Attribution Noncommercial License which permits any noncommercial use, distribution, and reproduction in any medium, provided the original author(s) and the source are credited.

References

1. Roth LM, Ehrlich CE. Mucinous cystadenocarcinoma of the retroperitoneum. *Obstet Gynecol.* 1977;49:486-8.
2. Motoyama T, Chida T, Fujiwara T, et al. Mucinous cystic tumor of the retroperitoneum. A report of two cases. *Acta Cytol.* 1994;38:261-6.
3. Thamboo TP, Sim R, Tan SY, et al. Primary retroperitoneal mucinous cystadenocarcinoma in a male patient. *J Clin Pathol.* 2006;59:655-7.
4. Green JM, Bruner BC, Tang WW, et al. Retroperitoneal mucinous cystadenocarcinoma in a man: case report and review of the literature. *Urol Oncol.* 2007;25(1):53-5.
5. Tjalma WAA, Vaneerdeweg W. Primary retroperitoneal mucinous cystadenocarcinomas are distinct entity. *Int J Gynecol Cancer.* 2008;18:184-8.

6. Tangjitgamol S, Manusirivithaya S, Sheanakul C, et al. Retroperitoneal mucinous cystadenocarcinoma: a case report and review of literature. *Int J Gynecol Cancer*. 2002;12:403–8.
7. Law KS, Chang TM, Tung JN. Fertility-sparing treatment of a primary retroperitoneal mucinous cystadenocarcinoma. *BJOG*. 2006;113:612–4.
8. Erdemoglu E, Aydogdu T, Tokyol C. Primary retro peritoneal mucinous cystadenoma. *Acta Obstet Gynecol Scand*. 2003;82:486–7.
9. Heidi N, Brent B, Roger A. Primary retroperitoneal mucinous cystadenocarcinoma. *Cancer*. 1988;61:2117–21.
10. Dore R, La Fianza A, Storti L, et al. Primitive mucinous cystadenocarcinoma of the retroperitoneum. Case report and diagnostic considerations. *Clin Imaging*. 1996;20:129–32.
11. Uematsu T, Kitamura H, Iwase M, et al. Ruptured retroperitoneal mucinous cystadenocarcinoma with synchronous gastric carcinoma and a long postoperative survival: case report. *J Surg Oncol*. 2000;73:26–30.