

## The effectiveness of distal soft tissue procedures in hallux valgus

Cemil Kayali · Hasan Ozturk · Haluk Agus ·  
Taskin Altay · Ozgur Hancerli

Received: 9 January 2008 / Accepted: 19 May 2008 / Published online: 22 July 2008  
© Springer-Verlag 2008

### Abstract

**Background** Hallux valgus is a common disorder affecting mostly women population. Distal soft tissue procedure in the treatment of hallux valgus is one of the main operative techniques described. The aim of this study is to evaluate the outcomes of McBride's distal soft tissue procedure in hallux valgus cases.

**Materials and methods** This study includes 30 patients (27 women) having 31 hallux valgus, who were treated between 1999 and 2004. Modified McBride's distal soft tissue procedure was carried out in all cases. Pain status of the cases was recorded by using VAS, clinical assessment described by Bonney and Macnab, and American Orthopaedic Foot and Ankle Society's (AOFAS) score at the last follow up.

**Results** The mean hallux valgus and intermetatarsal angles decreased from 31.4° and 13.8° to 13.5° and 10.5°, respectively, with an average follow-up period of 54.4 months. AOFAS's score displayed significant improvement from 57 to 87. The mean VAS showed a significant decrease from 8.75 preoperatively to 2.1 at the last follow-up. According to Bonney and Macnab criteria, only one case was accepted as poor result due to 5° hallux varus.

**Conclusions** McBride's distal soft tissue procedure yields high rate of satisfaction for mild to moderate hallux valgus with no bony complications related to osteotomy.

**Keywords** Hallux valgus · Treatment · Soft tissue procedure · Osteotomy

### Introduction

Hallux valgus, complex deformity of the first ray and representing pain, is a common problem especially in women who wear esthetically well shoes but not comfortable [1]. It has some features including lateral deviation of great toe and medial deviation of first metatarsal [2]. There were many operative procedures described for the treatment of hallux valgus including distal soft tissue procedures (DSTPs), osteotomies through basis or head of first metatarsal and proximal phalanx, arthrodesis of the tarsocuneiform joint or metatarsophalangeal (MP) joint, excisional arthroplasty, and combined surgeries of osteotomy and DSTPs [3–8]. The main purposes of these procedures are to decrease the pain while maintaining the range of first MP joint and to correct the deformity.

The selection of surgery depends on some features of radiological findings of hallux valgus. The angles of hallux valgus or MP joint and intermetatarsal space, congruency of first MP joint and the degree of arthritis are the main factors used while deciding the operative procedure [9]. DSTPs, one of these alternatives, had been recommended by many authors for mild-to-moderate hallux valgus, as hallux valgus angle (HVA) was less than 30° and intermetatarsal angle (IMA) was less than 15° [9]. The aim of our study was to evaluate the clinical and radiological results of patients treated by DSTPs retrospectively.

---

C. Kayali · H. Agus · O. Hancerli  
2nd Clinic of Orthopaedics and Traumatology,  
Tepecik Education and Research Hospital, Izmir, Turkey

H. Ozturk · T. Altay  
1st Clinic of Orthopaedics and Traumatology,  
Tepecik Education and Research Hospital, Izmir, Turkey

C. Kayali (✉)  
6445 sokak No: 10 D: 4, 35550 Karşıyaka, Izmir, Turkey  
e-mail: cemilkayali@yahoo.com

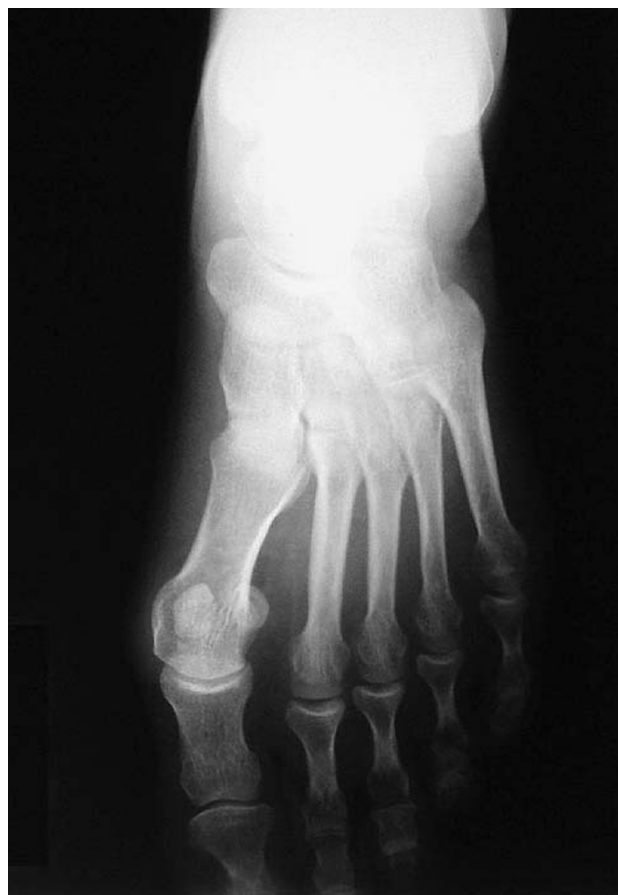## Materials and methods

This retrospective study included 31 feet of the 30 patients (27 women, 3 men) treated between 1999 and 2004 with an average age of 44.7 (17–63) years. Nineteen cases were on the right side, ten were on the left side and 1 case was bilateral. All the patients had been treated by conservative means before the decision of surgery. The mean preoperative sustaining period of complaints was 7.5 years. All the cases had pain during standing and walking especially over the first MP joint. The informed consent was obtained from all the patients in the form of a consent form and this form was taken from all patients after description of the procedure.

**Technique:** All the operations were carried out in supine position under spinal or general anesthesia using pneumatic tourniquet. A longitudinal incision was focused on the medial eminence of the first MP joint. The joint capsule was dissected while preserving dorsal and plantar digital nerves. A Y-shaped capsulotomy was performed to expose the medial eminence. The medial eminence was resected using osteotomes parallel to medial diaphyseal cortex. Then 3 cm longitudinal incision was performed over the dorsal aspect of the first intermetatarsal space to expose the conjoined adductor tendon. The tendon was dissected from the lateral sesamoid and base of the proximal phalanx. The lateral sesamoid was freed from all soft tissue attachments and the transverse intermetatarsal ligament was released. Partial capsulotomy was carried out to lateral aspect of the first MP joint. The distal stump of the adductor tendon is sutured into the lateral aspect of the MP capsule. Several sutures were placed to medial capsular leaves to get overriding for gaining realignment of first ray. The skin closure was performed after bleeding control.

Gauze between first and second fingers with compressive dressing and elastic bandage were applied in the operating room. Patients were allowed for weight-bearing as tolerated on to lateral side of the foot and heel for 3 weeks. The toe spacer was advocated for at least 3 weeks. Three to four weeks later, subjects were recommended for full weight-bearing as tolerated.

Patients were asked to score their pain while standing using visual analog score (VAS) representing 10 maximum pain and 0 no pain. Clinical assessment was performed based on the criteria described by Bonney and Macnab [8]. The American Orthopaedic Foot and Ankle Society's (AOFAS's) hallux metatarsophalangeal–interphalangeal scores were noted [10]. In addition, the ranges of motion (ROM) of the first MP joint and radiological parameters including HVA and IMA on weight-bearing radiographs were measured preoperatively and at the last follow-up (Figs. 1, 2, 3). Statistical analysis was performed by using Student's *t* test and  $P < 0.05$  was accepted as significant.

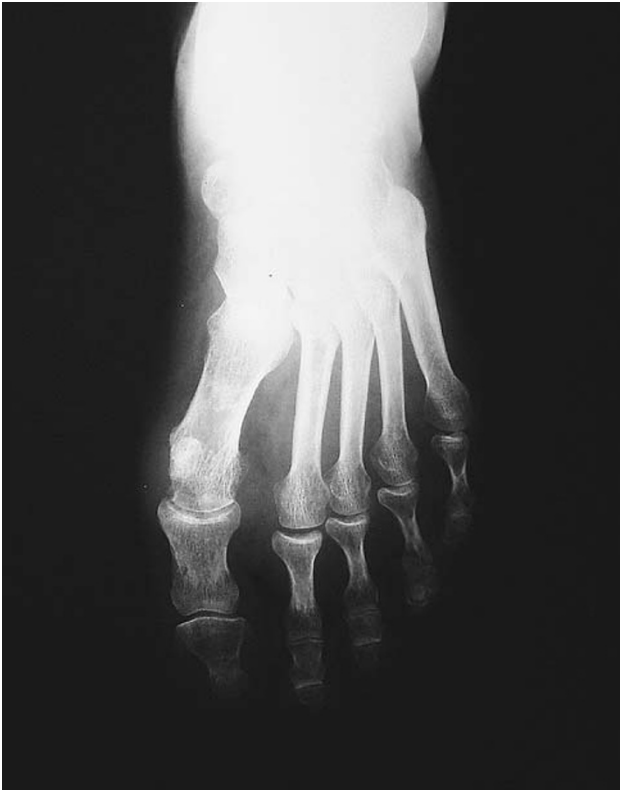

**Fig. 1** Preoperative AP (anteroposterior) X-ray of the left feet; E S., female, 49 years

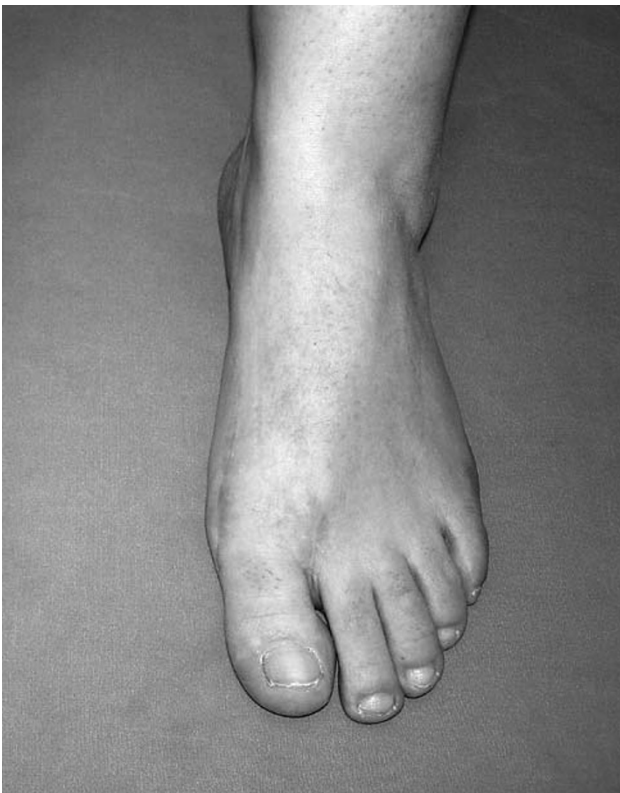
The study was performed in accordance to the Declaration of Helsinki.

## Results

The mean follow-up period was 54.4 months (range 36–82). The mean preoperative HVA was  $31.4^\circ \pm 6.7^\circ$  (range  $20^\circ$ – $40^\circ$ ). Significant correction for HVA was obtained ( $P = 0.0002$ ) that the HVA was decreased to mean  $13.5^\circ \pm 9.2^\circ$  (range  $-5^\circ$ – $32^\circ$ ) at the last follow up period. The mean preoperative IMA was  $13.8^\circ \pm 2.1^\circ$  (range  $10^\circ$ – $17^\circ$ ). Postoperatively it decreased to mean  $10.5^\circ \pm 2.7^\circ$  (range  $6^\circ$ – $16^\circ$ ) and it was observed that this correction was significantly different ( $P = 0.008$ ). There was significant decrease in the mean VAS as follows:  $8.75 \pm 1.3$  (range 6–10) preoperatively and  $2.1 \pm 1.7$  (range 0–6) postoperatively ( $P = 0.0001$ ). The mean required days to return to recreational activities was 48 days (range 40–65). The average range of motion (ROM) of first MP joints was  $82^\circ$  preoperatively and  $78^\circ$  postoperatively. The AOFAS's hallux metatarsophalangeal–interphalangeal score showed significant improvement from 57 to 89 ( $P = 0.0001$ ).



**Fig. 2** AP X-ray 36 months later postoperatively; good result



**Fig. 3** The appearance of the foot 36 months later postoperatively. She is satisfied with the clinical and cosmetic result

Based on the criteria described by Bonney and Macnab there were 24 excellent (77%), 3 good (10%), 3 fair (10%) and 1 poor (3%) results. The poor result was due to hallux varus development as HVA of  $(-5^\circ)$  postoperatively. Because of the patient's no major complaint, there was no need to perform salvage surgery. Three fair results were due to recurrence of deformity who had HVAs greater than  $30^\circ$  preoperatively. There were 2 (6%) superficial infections detected at the early postoperative period treated by meticulous wound care and oral antibiotics. Twentysix cases (84%) reported no obvious pain and the others (16%) were occasionally while standing.

## Discussion

The patho-anatomy of the hallux valgus comprised lateral joint capsule contracture, attenuation of the medial joint capsule, lateral subluxation of the proximal phalanx, and medial deviation of the metatarsal head [11, 12]. The indication for surgery is the pain that could not be controlled by conservative means. More than 200 procedures were described but none was universally suitable for all kinds of deformities. Therefore, a traditional classification depending on the degrees of HVA and IMA was proposed to make an algorithm for surgery as follows: mild (HVA up to  $19^\circ$ , IMA up to  $13^\circ$ ); moderate (HVA  $20^\circ$ – $40^\circ$ , IMA  $14^\circ$ – $20^\circ$ ); severe (HVA greater than  $40^\circ$ , IMA greater than  $20^\circ$ ) [2].

The DSTPs for correction of hallux valgus had been recommended by many authors for mild-to-moderate deformity. Silver first popularized DSTPs as medial capsulorrhaphy, medial exostectomy and release of lateral capsule and conjoined adductor tendon [13]. McBride modified this technique advocating removal of lateral sesamoid and transfer of the adductor tendon to the lateral wall of the first metatarsal head [3].

Mann and Coughlin reported the results of a hundred patients who treated via DSTPs representing  $14.8^\circ$  decrease in HVA and  $5.2^\circ$  in IMA [14]. They advocated that if more than  $20^\circ$  hallux valgus correction is needed, DSTPs should be combined with the corrective osteotomy of the first metatarsal. Johnson et al. and Meyer et al. reported a high degree of clinical success in the treatment of mild-to-moderate hallux valgus with DSTPs [15, 16].

Mittal et al. reported the pedobarographic results of 27 feet of the 19 patients treated by modified McBride procedure in a prospective study [17]. Their results showed significant improvement as in HVA of  $17^\circ$  and in IMA of  $5^\circ$ . They found statistically significant increase in the contact area of the hallux. In another study with a median of 9 years follow-up evaluation of McBride's operation, significant corrections of HVA from  $32^\circ$  to  $26^\circ$  and of IMA from  $13^\circ$  to  $10^\circ$  were reported [18].

In our study, the amount of hallux valgus and IMA correction was 17.9° and 3.3°, respectively. In the statistical analysis, these corrections were found as significantly different. In addition to radiological findings, most of the cases reported improvement in pain VAS clinically. Twenty-six (84%) cases had no or occasional pain while standing and shoe wearing at the last follow-up. The AOFAS's hallux metatarsophalangeal–interphalangeal score showed significant improvement from 57 to 89 with average 4.5 years of follow-up.

Some authors compared the clinical and radiological results of cases treated via DSTPs or metatarsal osteotomy. Johnson et al. showed that a Chevron osteotomy resulted in a significantly greater radiological correction than isolated DSTPs in these patients [15]. In another study, Udin and Dutoid compared the clinical and radiological findings of McBride operation and subcapital osteotomy in an average 19 years follow-up period [19]. However, they found that although the deformity was radiologically better improved via osteotomy, the subjects treated via McBride's operation were more satisfied.

Mann and Pfeffinger found that 91% of their cases were satisfied with the clinical outcome DSTPs and there was no recurrence of deformity [20]. In Mittal's study, the overall satisfaction rate was 96% [17]. However; in a comparative study between DSTPs and metatarsal osteotomy, the satisfaction rates were 71 and 81%, respectively [21]. Archibald and Hamilton evaluated the 29 feet using Bonney and MacNab's scoring system as 93% still satisfied with the treatment up to 12 years follow-up period [22]. Dick and Henche reported 85% satisfaction rate in 53 patients who had severe deformity [23].

Based on the criteria described by Bonney and MacNab, eighty-seven percent excellent and good clinical results were obtained. In the study group, 27 of the 31 cases were satisfied with the treatment especially with respect to cosmetic appearance. There was no apparent painful callosity in the plantar aspect of the feet. Recurrence of the deformity was determined in three patients (10%). All three cases had HVA greater than 35° preoperatively. These findings supported that HVA greater than 35° may require additional corrective attempts as reported by some authors' previously [14].

Distal osteotomies of the first metatarsal such as Chevron, Wilson, and Mitchell techniques were performed for mild-to-moderate hallux valgus deformities [24]. There were many complications related to osteotomy reported in many studies. Especially, in Chevron osteotomy, the most serious complication is avascular necrosis of the first metatarsal with a reported incidence of between 0 and 20% [25, 26]. Meier and Kenzora reported that avascular necrosis developed in 20% of sixty feet after Chevron osteotomy [27]. Lewis and Feffer reported the most

frequent complication of Chevron osteotomy as recurrence or under correction due to slippage at the site of osteotomy [28]. In another study in which Schemitsch and Horne reported the outcomes of Wilson's osteotomy, lateral metatarsalgia and callus were frequent complications resulting from excessive shortening of the first metatarsal [29]. In the Mitchell procedure malunion, delayed union and nonunion had been reported because of the nature of osteotomy [9].

However, since it is only a soft tissue procedure, there are no complications related to bone in DSTPs. In the literature, hallux varus is the most common complication of the DSTPs [9, 14, 20]. Mann and Coughlin reported the incidence of hallux varus as 11%, though it was severe in four cases [14]. In another report, Mann and Pfeffinger noted that hallux varus was due to the attempt of correction of severe deformities [20]. In our study, there was one case (3%) who sustained from hallux varus postoperatively. In the course of treatment, the radiological measurements of that case were found as follows: HVA from 34° to -5° and IMA from 17° to 6°. This mild degree of varus angulation did not bother the patient with minimal pain and discomfort. Therefore, no further surgery was required.

We concluded that McBride's DSTP is a good option to yield satisfactory clinical and radiological results without bony complications in comparison to osteotomies.

**Conflict of interest statement** All authors warrant that they do not have financial relationship with the organization that sponsored the research. None of the authors of this manuscript has received or will receive any type of support, funding, or benefits for personal or professional use from a commercial party related directly or indirectly to the subject of this article. They also state that they have full control of all primary data and that they agree to allow the journal to review their data if requested.

## References

1. Kato S, Watanabe S (1981) The etiology of hallux valgus in Japan. *Clin Orthop* 157:78–81
2. Robinson AHN, Limbers JP (2005) Aspects of current management: modern concepts in the treatment of hallux valgus. *J Bone Joint Surg (Br)* 87:1038–1045
3. McBride ED (1967) The McBride bunion hallux valgus operation. Refinements in the successive surgical steps of the operation. *J Bone Joint Surg (Am)* 49:1675–1683
4. Erturer E, Aksoy B, Beki S, Tokar S, Ozturk I (2004) Radiographic and functional results of the Lindgren–Turan operation in the treatment of hallux valgus. *Acta Orthop Traumatol Turc* 38:125–129
5. Yamamoto K, Imakiire A, Katori Y, Masaoka T, Koizumi R (2005) Clinical results of modified Mitchell's osteotomy for hallux valgus augmented with oblique lesser metatarsal osteotomy. *J Orthop Surg* 13:245–252
6. Faber FWM, Mulder PGH, Verhaar J (2004) Role of first ray hypermobility in the outcome of the Hohmann and the Lapidus

- procedure. A prospective, randomized trial involving one hundred and one feet. *J Bone Joint Surg (Am)* 86:486–495
7. Schneider W, Aigner N, Pinggera O, Knahr K (2004) Chevron osteotomy in hallux valgus. Ten-year results of 112 cases. *J Bone Joint Surg (Br)* 86:1016–1020
  8. Bonney G, Macnab I (1952) Hallux valgus and hallux rigidus. A critical survey of operative results. *J Bone Joint Surg (Br)* 34:366–385
  9. Coughlin MJ (1996) Hallux valgus. *J Bone Joint Surg (Am)* 78(6):932–966
  10. Kitaoka HB, Alexander IJ, Adelaar RS, Nunley JA, Myerson MS, Sanders M (1994) Clinical rating systems for the ankle-hindfoot, midfoot, hallux and lesser toes. *Foot Ankle Int* 15:349–353
  11. Mann RA, Rudicel S, Graves SC (1992) Repair of hallux valgus with a distal soft-tissue procedure and proximal metatarsal osteotomy. *J Bone Joint Surg (Am)* 74:124–129
  12. Stephens MM (1994) Pathogenesis of hallux valgus. *Eur J Foot Ankle Surg* 1:7–10
  13. Silver D (1923) The operative treatment of hallux valgus. *J Bone Joint Surg* 5:225–232
  14. Mann RA, Coughlin MJ (1981) Hallux valgus—etiology, anatomy, treatment and surgical considerations. *Clin Orthop* 157:31–41
  15. Johnson JE, Clanton TO, Baxter DE, Gottlieb MS (1991) Comparison of chevron osteotomy and modified McBride bunionectomy for correction of mild to moderate hallux valgus deformity. *Foot Ankle* 12:61–68
  16. Meyer JM, Hoffmeyer P, Borst F (1987) The treatment of hallux valgus in runners using a modified McBride procedure. *Int Orthop* 11:197–200
  17. Mittal D, Raja S, Geary NP (2006) The modified McBride procedure: clinical, radiological, and pedobarographic evaluations. *J Foot Ankle Surg* 45:235–239
  18. Gebuhr P, Soelberg M, Larsen TK, Niclasen BV, Laursen NO (1992) McBride's operation for hallux valgus. A 2–11-year follow-up of 46 cases. *Acta Orthop Scand* 63:189–191
  19. Udin B, Dutoit M (1992) Hallux valgus: the McBride procedure or subcapital osteotomy? *Rev Chir Orthop Reparatrice Appar Mot* 78:169–175
  20. Mann RA, Pfeffinger L (1991) Hallux valgus repair. DuVries modified McBride procedure. *Clin Orthop* 272:213–218
  21. Schwitalle M, Karbowski A, Eckardt A (1998) Hallux valgus in young patients: comparison of soft-tissue realignment and metatarsal osteotomy. *Eur J Pediatr Surg* 8:42–46
  22. Archibald DA, Hamilton JA (1990) Modified McBride's procedure: long-term results. *J R Coll Surg Edinb* 35:317–319
  23. Dick W, Henche HR (1976) The McBride operation of hallux valgus in adolescents. *Z Orthop Ihre Grenzgeb* 114:388–393
  24. Jones S, Al Hussainy HA, Ali F, Betts RP, Flowers MJ (2004) Scarf osteotomy for hallux valgus. A prospective clinical and pedobarographic study. *J Bone Joint Surg (Br)* 86:830–836
  25. Donnelly RE, Saltzman CL, Kile TA, Johnson KA (1994) Modified chevron osteotomy for hallux valgus. *Foot Ankle Int* 18:652–655
  26. Green MA, Dorris MF, Baessler TP, Mandel LM, Nachlas MJ (1993) Avascular necrosis following distal Chevron osteotomy of the first metatarsal. *J Foot Ankle Surg* 32:617–622
  27. Meier PJ, Kenzora JE (1985) The risks and benefits of distal first metatarsal osteotomies. *Foot Ankle* 6:7–17
  28. Lewis RJ, Feffer HL (1981) Modified chevron osteotomy of the first metatarsal. *Clin Orthop* 157:105–109
  29. Schemitsch E, Horne G (1989) Wilson's osteotomy for the treatment of hallux valgus. *Clin Orthop* 240:221–225