

Hooshang Saberi · Ali Tayebi Meybodi ·
Abdolreza Sheikh Rezai

Levine-Sekhar grading system for prediction of the extent of resection of cranial base meningiomas revisited: study of 124 cases

Received: 27 April 2005 / Accepted: 14 September 2005 / Published online: 11 January 2006
© Springer-Verlag 2006

Abstract Skull base meningiomas comprise an intricate kingdom in neurological surgery. Due to their proximity to critical neurovascular structures, these tumours impose a cumbersome burden on the surgeon regarding surgical intervention and the clinical outcome. Preoperative prediction of the meningioma resectability will help the surgeon seek a rational result from surgery. This study tries to re-examine and promote the Levine-Sekhar (LS) grading system proposed to predict the resectability of basal meningiomas. A retrospective study was performed on 124 eligible patients (90 female and 34 male) suffering from cranial base meningioma that had been operated on between April 1996 and February 2003. The patients were classified according to LS and our modified grading systems. The modified grading system deploys six groups of variables: optic apparatus involvement, cavernous sinus neural involvement, facial-auditory involvement, caudal cranial nerve dysfunction, data derived from imaging studies (multiple fossa involvement and/or vessel encasement), and history of previous radiosurgery. Each criterion scores 1 if present and the total score is the sum of scores obtained from the aforementioned criteria. Amongst 124 patients, 66 (52%) underwent gross total removal of the tumour. Regression and correlation analysis were performed for both LS ($r^2=0.9683$) and our modified grading systems ($r^2=0.990$) to evaluate the relationship of tumour grade versus the proportion of total resection. The correlations were significantly different ($P<0.01$). Although the LS grading system is reported to be a good predictor of the extent of tumour resection, we believe

that application of the six aforementioned variables will enhance the accuracy of this system, while preserving simplicity and communicability.

Keywords Cranial base · Extent of resection · Meningioma · Outcome

Introduction

Traditionally, the clinical course of intracranial meningiomas has been a matter of debate and histological morphology and biological behavior of the tumour have been determinants of utmost importance [3, 8]. Nevertheless, considering basal meningiomas, anatomical relationships gain much more concern regarding the cranial nerves and brain vasculature [15, 25]. The presence of multiple vital neurovascular structures and their anatomical variations make tumour removal much more difficult, and this has always been a dilemma in neurological surgery, with variable levels of surgical risk [1, 16, 18, 27]. Considering these factors as a whole, one will recognize that surgery of these tumours requires the highest degree of state-of-the-art. Whatever the philosophy, expertise and experience of the surgeon, prognostication remains an unanswered question regarding surgical indication, selection of treatment modalities including radiosurgery, total or partial resection, and the surgical corridor of choice [13, 17, 20, 29]. Various factors have been proposed by several authors to predict surgical resectability, such as peri-tumoural edema, presence of nourishing pial vessels, age of the patient, location of the tumour, duration of symptoms, preoperative neurological status, vessel encasement, tumour size, presence and severity of the associated hydrocephalus, extent of resection, and co-morbid conditions, such as hypertension and diabetes mellitus [10, 12, 19, 26].

Accordingly, Levine et al. [19] have proposed a grading system to predict the extent of resection and outcome for these complex tumours. This system has yielded a high degree of correlation between the extent of resection and the tumour grade. However, optic nerve, facial-auditory

H. Saberi (✉) · A. T. Meybodi · A. S. Rezai
Department of Neurosurgery,
Imam Khomeini Hospital,
Tehran University of Medical Sciences,
Tehran, 14197, Iran
e-mail: hgsaberi@yahoo.com
Tel.: +98-21-69350619
Fax: +98-21-6929977

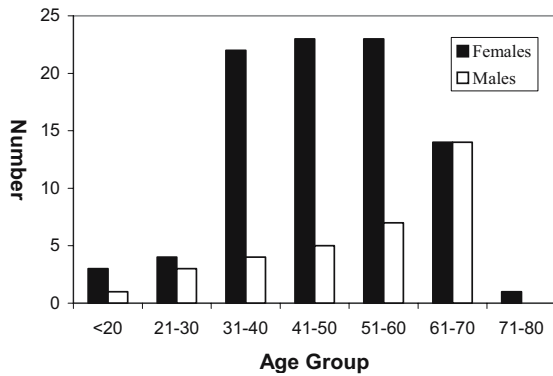


Fig. 1 Number of cases in different decades of life according to sex. Note the female preponderance between the 4th and 6th decades of life, in which the female sex hormonal burst is at its zenith. This supports the former viewpoint of etiological role of female sex hormones in meningiomas

and caudal cranial nerve involvement have not been addressed. In this study, for the sake of simplicity and communicability, we have postulated a modified grading system based on a series of 124 patients, trying to possibly achieve a more significant prognostic correlation.

Patients and methods

Between April 1996 and February 2003, 141 patients suffering from skull base meningiomas, who were candidates for elective surgery, have been referred to this hospital. Patients with a pathologically proven diagnosis were included, while those with an equivocal histology, comorbid conditions necessitating non-surgical management and/or inadequate data were excluded from the study. Subjects of the investigation included 90 females (73%) and 34 males (27%), with a mean age of 48.2 years (female/male ratio = 2.6:1, Fig. 1). The topographic locations of the tumours, as well as their relative frequency, are shown in Fig. 2. Patients were graded according to both the Levine-

Sekhar (LS) and our modified grading systems. The LS grading system uses six variables for determination of the grade in which every positive criterion equals one score and the sum of these options makes the patient’s total score, (Table 1) while our modified system employs six criteria, consisting of five based on regional surgical anatomy and pre-operative data as well as a former option employed in LS grading system, namely, history of radiosurgery (Fig. 3). The corresponding scores and grades of both systems have been tabulated in Table 2. Illustrative cases have been shown in Fig. 4a–c.

Statistical analysis included student’s *t*-test to compare independent samples and chi-square exam to assess statistical significance of non-parametric data. We also used linear regression, calculated the Pearson correlation coefficient for evaluation of the grading systems, and computed the *z*-score for comparison of the correlation coefficients of the original and modified grading systems.

Results

Mean hospital stay of the 124 eligible cases was 16 days. This was 12 days for the total resection group and 22.2 days for the partial resection group; and the difference was statistically significant ($P<0.001$). The mean duration of pre-operative symptoms was 27 ± 4 months, and this time did not show any correlation with tumour resectability ($P=0.68$, $\beta=80\%$). We did not have a single case of cranial base meningioma recurring after previous radiosurgery; therefore this factor was not applicable to our patients. The variables utilized in the modified system for grading of cranial base meningiomas were (1) presence of optic apparatus involvement, i.e. visual loss, optic atrophy and/or papilledema, (2) signs of cavernous sinus neural involvement, i.e. involvement of cranial nerves III, V and/or VI, (3) 7th and/or 8th nerve complex involvement, (4) dysfunction of at least one of the caudal cranial nerves, (5) vessel encasement and/or multiple fossa involvement by the tumour and (6) recurrence after radiosurgical treatment.

Fig. 2 Topographic prevalence of tumours, with the most common presenting symptom *in parentheses*

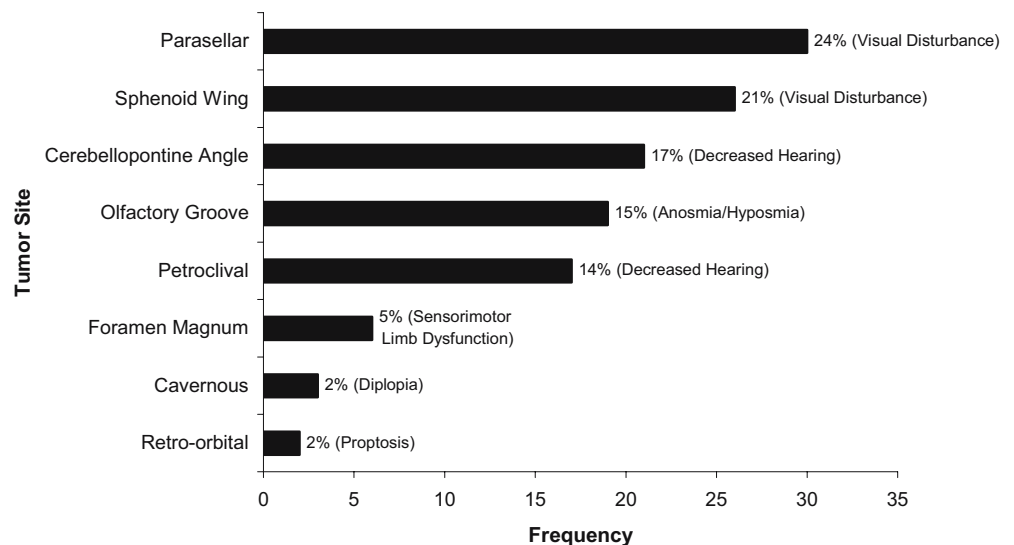


Table 1 Employed variables of LS and our modified grading systems (NA not applicable, CN cranial nerve)

Variable (LS grading system)	Score	Variable (our modified system)	Definition/source	Score
NA	NA	Optic apparatus involvement	Visual loss, optic atrophy and/or papilledema	1
3rd CN dysfunction	1	Cavernous sinus neural involvement	Dysfunction of CN III, V, and/or VI	1
5th CN dysfunction	1			
6th CN dysfunction	1			
NA	NA	Facial-auditory Involvement	Dysfunction of facial and/or auditory nerve	1
NA	NA	Caudal cranial nerve involvement	Dysfunction of 9th, 10th and/or 11th CN	1
Multiple fossa involvement	1	Multiple fossa involvement and/or vessel encasement	Derived from imaging studies	1
Vessel Encasement	1			
Previous radiosurgery	1	Adjuvant treatment	Previous radiosurgery	1
Total	6	Total		6

The presence of these abnormalities per se correlated significantly with sub-total resection of the tumour ($P < 0.05$).

Of the total 124 patients, 66 (52%) had undergone gross total resection of the tumour and the tumour had been partially resected in the remaining 58 (48%). Twenty-two tumours fulfilled the necessary criteria for grade zero according to our modified grading system, while six of them were not resected totally. Linear regression analysis was performed for the totally resected tumour proportion (TRP) versus the “score”, which yielded the following regression equations for the two grading systems:

$$\text{TRP} = -0.128 \times (\text{LS Score}) + 0.7613$$

$$\text{and TRP} = -0.1487 \times (\text{Modified Score}) + 0.8955$$

The Pearson correlation coefficients for scores of the LS and modified grading systems were found to be 0.9585 and

0.9976, respectively, where their difference was statistically significant ($P < 0.01$, Fig. 5).

Collapsing the score data of the two systems yielded new data (grades) being depicted in Fig. 6. The overall mortality and complication rates were 11.3% and 26%, respectively. The most prevalent complications included (1) cranial nerve involvement (27%), (2) hemiparesis due to infarction (11.2%), (3) meningitis (4.8%), (4) CSF leakage (4%), (5) hydrocephalus and hematoma (2.5%), (6) cerebellar dysfunction (9.5%), and (7) non-neurological complications (7.5%). Fourteen patients passed away in the immediate post-operative period. Two deaths were not directly related to surgery (renal failure and pulmonary embolism), and cerebellopontine angle and sphenoid wing meningiomas had the highest mortality rate. However, more patients should be studied to conclude any statistical inference between grade and mortality/morbidity rates.

Fig. 3 Schematic diagram depicting the topographic location of cranial nerves and vasculature of the skull base and the corresponding score attributed to their involvement. Note that each score correlates with specific anatomical region within the skull base, the sum of which yields the total score

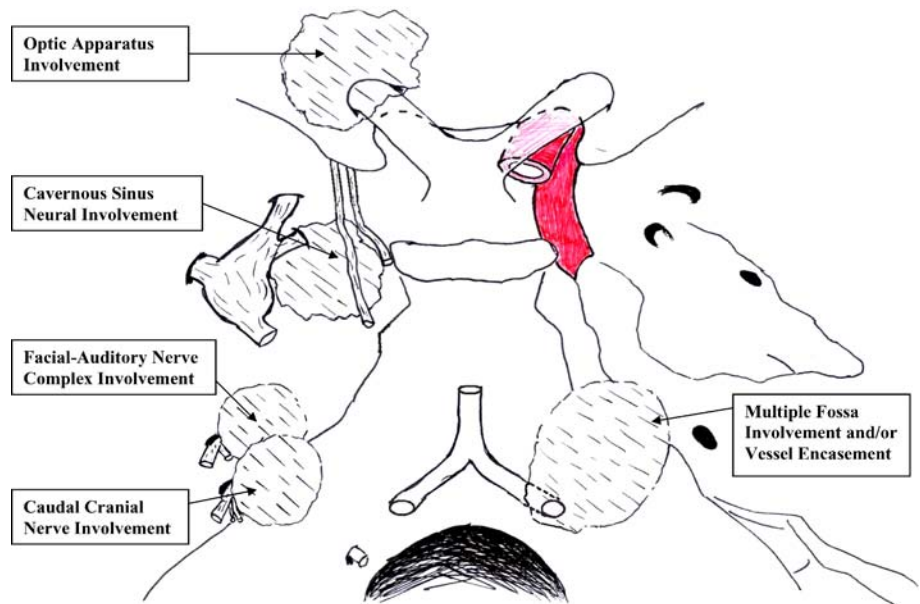


Table 2 Corresponding grades and scores in the LS and our modified grading systems

Score	Grade
0	0
1, 2	I
3, 4	II
5, 6	III

Discussion

Meningiomas of the cranial base have been under special focus prior to the evolution of highly sophisticated approaches and instrumental armamentarium for skull base surgery, and it is not surprising that these tumours still remain among the most challenging problems that mandate a special treatment tailored for each patient [2, 4, 9, 11, 19, 21, 22, 30]. Their management requires extensive knowledge, expertise and experience in the realms of histology, molecular biology, hormonal biochemistry and functional/surgical anatomy of the skull base [9, 23, 24], as well as a modern interdisciplinary facility. Nevertheless, what seems crucial to every neurosurgeon at the time of confrontation with such a tumour, is the answer to this question: “Can it be resected totally?” There has been a great deal of industrious effort to find a logical and satisfactory answer to this question since Harvey Cushing described these challenging tumours for the first time [6]. However, there have been, of course, many solutions proposed to confine the complexity of the matter.

Follow-up studies on natural course of petroclival meningiomas have shown that the extent of resection is an important factor in predicting the clinical outcome of the malady. Therefore, prediction of the degree of resection accomplished pre-operatively may prevent a fait accompli at the time of surgery [12, 28].

Also, Cusimano et al. [7] have performed a major retrospective study on the tumours of the cavernous sinus. Their results have shown that meningiomas of the cavernous sinus are the most difficult tumours to resect, have the worst outcome among all tumours of the region and cause the most

devastating complications after surgery [7]. Their investigation emphasises the importance of prognostication for meningiomas of the cavernous sinus region, and presumably their results may be applicable to the whole cranial base.

Goel et al. [10] have performed a great study on 70 tuberculum sellae meningioma cases. They proposed a justified grading system based on clinical and radiological criteria. Their clinical criteria included (1) the duration of symptoms, (2) visual status of the patient before surgery, (3) other neurological deficits, (4) diabetes mellitus and hypertension regarded as co-morbid factors, and (5) age of the patient. Their grading system also uses such radiological criteria as the presence of peri-tumoural edema, internal carotid and/or anterior cerebral artery encasement, tumour nature and severity of the associated hydrocephalus, if present. Although it casts special scrutiny on tuberculum sellae meningiomas, the major drawbacks are lack of simplicity and applicability to the whole cranial base. The present modified system has both simplicity and bedside applicability based solely on pre-operative findings.

Sindou [26] has proposed “peri-tumoural edema” and “presence of nourishing pial vessels to the tumour”, as factors influencing surgical prognosis in meningiomas, yet not suggested any classification for various locations of meningiomas remembering that basal meningiomas seem to be unique in many aspects. Besides, the “presence of nourishing pial vessels to the tumour” could not be assessed prior to surgery. Our modified grading system puts the cranial base meningiomas at the centre of focus and, furthermore, is easily applicable prior to surgery.

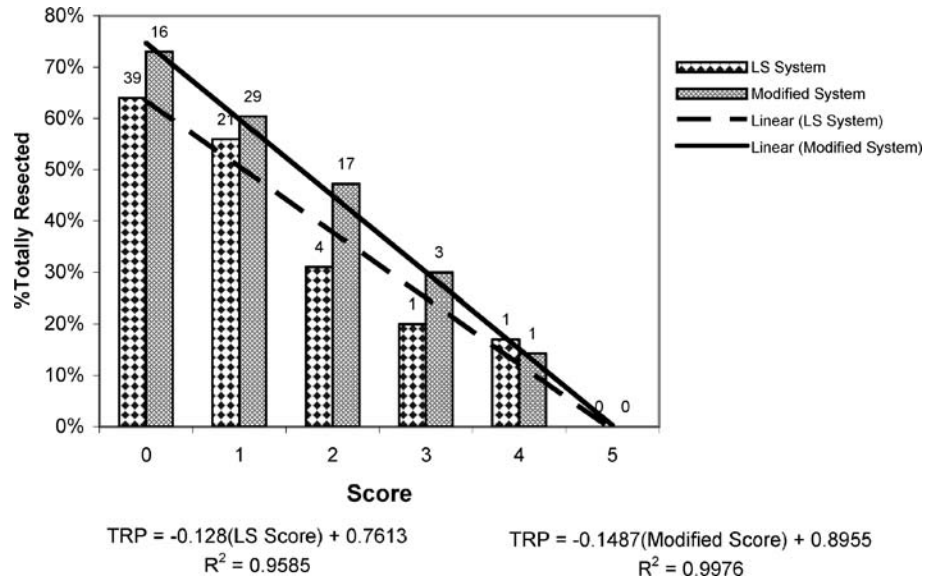
The first investigation to construct a grading system for prediction of outcome and extent of resection in skull base meningiomas has been performed by Levine et al. [19] yielding a high degree of correlation between the grade of the tumour and degree of resection. However, only three of the cranial nerves (namely, III, V and VI) are addressed, and other neural structures, such as the optic, facial, auditory and lower cranial nerves, whose significant contribution and correlation

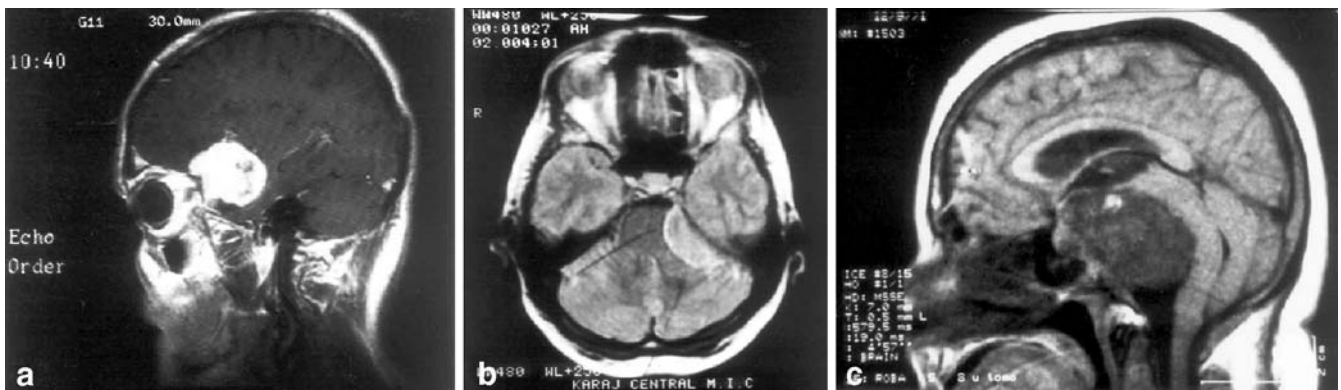

Fig. 4a–c Illustrative cases showing skull base meningiomas with different grades. **a** Sagittal paramedian T1-weighted MR image with gadolinium enhancement of a clinoidal meningioma with grade II (anterior and middle fossa involvement, visual disturbance and 6th nerve palsy) in a 51-year-old male. The tumour was totally resected through a pterional approach. **b** Axial T2-weighted MR image of a cerebellopontine angle meningioma with grade II (5th cranial nerve involvement, facial-auditory nerve complex involvement and dis-

turbance of caudal cranial nerves) in a 50-year-old female. The tumour was subtotally resected through a retrosigmoid approach. **c** T1-weighted mid-sagittal MR image of a huge petroclival meningioma with grade III (papilledema, 6th nerve palsy, facial-auditory nerve complex involvement, hoarseness and multiple fossa involvement). The tumour was partially resected through a retrosigmoid approach. The patient developed massive cerebellar infarction post-operatively

Fig. 5 Linear regression analysis for scores of totally resected tumours according to LS grading system and our modified grading system. *Numbers on top of columns indicate the total number of patients having undergone gross total resection in each group*



to tumour resectability have been proven in the current study, do not appear in the LS grading system ($P < 0.05$).

One of the important determinants in resectability is the involvement of cranial nerves. There is a common belief among neurological surgeons that resection of a tumour with potential harm to the cranial nerves is much more difficult than that of a mass that has not produced nerve dysfunction [17]. It is prudent to assert that tumour resectability is not affected by the involvement of different cranial nerves in the same way.

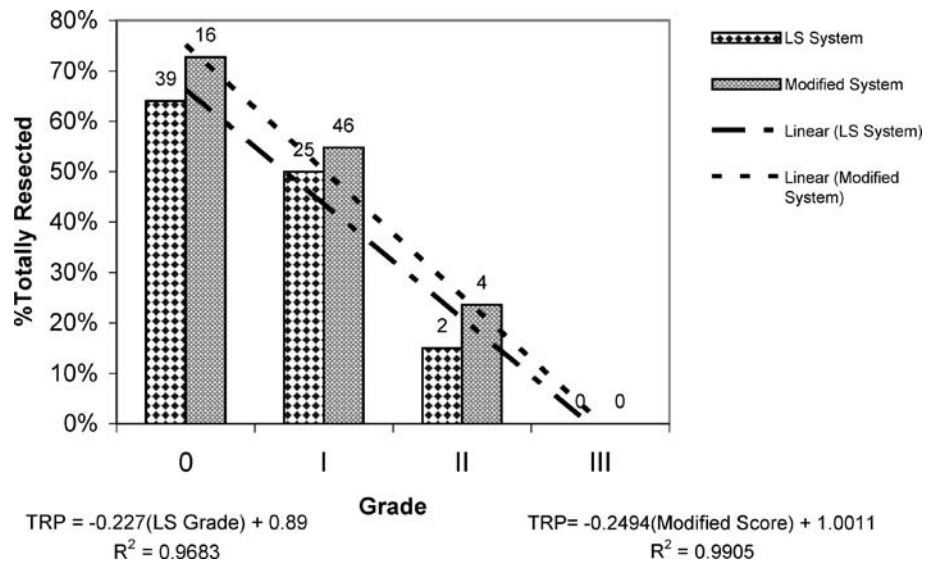
We have found a significant correlation between visual disturbance, optic atrophy with subtotal resection of the tumour ($P < 0.05$). Although discrete involvement of cranial nerves III, V, and VI correlated well with subtotal tumour resection ($P < 0.05$), these variables have been included solely as a binary criterion, such that its value switches between 0 (no III, V and VI neuropathy) and 1 (at least one of the nerves is dysfunctional) ($P < 0.01$). Trochlear nerve dysfunction has been omitted because of high probability of misdiagnosis of its dysfunction [19].

Paresis of the facial nerve was also found to be an ominous sign for tumour resectability, since it could not be easily preserved during surgery, and this is a reason to attempt subtotal resection. Besides, most of facial palsies caused by tumoural compression of the nerve are associated with some degree of auditory nerve involvement. This has been the basis for inclusion of these variables (CN VII and/or VIII dysfunction) as a single criterion. The presence of facial and/or auditory nerve dysfunction well correlated with subtotal resection of the tumour ($P < 0.05$). This may be indicative of their dysfunction as a key factor in neurosurgical decision-making.

The lower cranial nerves IX, X, XI are usually involved in petroclival, cerebellopontine angle, and foramen magnum meningiomas. Dysfunction of any of these nerves has been assumed a single score, yielding a significant correlation with the extent of resection of the tumour ($P < 0.05$).

Levine et al. [19] did not address the actual nature of cranial nerve palsies in the subgroup having undergone radiosurgery, so that the net effect of this factor, i.e. its

Fig. 6 Linear regression analysis for grades of totally resected tumours according to LS grading system and our modified grading system. *Numbers on top of columns indicate the total number of patients having undergone gross total resection in each group*



influence on resectability may be either due to inherent difficulty of surgery, perceived at the first surgical attempt which led to radiosurgical treatment or secondary changes in tumour consistency induced by radiosurgery. On the other hand, cranial nerve dysfunctions directly related to radiosurgical complications may be erroneously attributed to the invasive behaviour of the tumour and factitiously escalate the corresponding score and grade. Although none of our patients had a previous radiosurgery session for treatment of a cranial base meningioma, we did not exclude this variable, considering its high predicting value in the survey of Levine and co-workers. Expectant studies may further evaluate this feature.

Levine et al. [19] have reported a series of 232 patients having undergone surgery for basal meningiomas and proposed a grading system based on preoperative data [19]. They have mentioned that involvement of the optic nerve and lower cranial nerves were found to be of little predictive value, therefore being omitted in their study, possibly because of a paucity of posterior fossa cases in their survey. Therefore, larger number of patients might be necessary to yield statistical significance regarding these points [14]. On the other hand, this sub-category comprised an important proportion of our patients (35.5%). Considering Fig. 1, one recognises that the involvement of lower cranial nerves has been observed commonly in tumours involving lower regions in the posterior cranial base [5, 28, 31]. This means that many tumours of this region might attain a low grade in the original system proposed by Levine and co-workers, while they could not be resected totally because of intricate neurovascular relationships, hence diminishing the predictive value of the LS grading system in a large series of patients suffering from posterior fossa meningiomas. Although the difference between the Pearson correlation coefficient obtained from the LS grading system and that of our modified grading system seems to be negligible (0.9683 versus 0.990), analysis of the difference (*z*-score) unmasks a significant difference between them ($P < 0.01$).

Grade zero patients did well and all except six underwent a total resection. The cause for subtotal resection has been limited access to the petroclival location in two patients and recurrent tumour in three. The last one was a jugular foramen meningioma in a 35-year-old lady without any preoperative cranial nerve symptoms.

Conclusion

Numerous studies have coined predictive factors for resection and outcome of different types of cranial base meningiomas. However, few of them have considered cranial base meningiomas on the whole, obviously caused by complexity of the matter. These studies have focused on various aspects of these tumours and with the introduction of newer surgical approaches and the novel therapeutic technique of radiosurgery, new horizons have appeared in promotion of the outcome for these patients. Our study has tried to revise the LS system, possibly enhancing the simplicity and communicability as well as correlation significance.

Acknowledgement The authors are indebted to Dr Arash Nazari for preparation of the schematic diagram.

References

1. Akagami R, Napolitano M, Sekhar LN (2002) Patient-evaluated outcome after surgery for basal meningiomas. *Neurosurgery* 50:941–949
2. Al-Mefty O (1999) Proposed grading system to predict the extent of resection and outcomes for cranial base meningiomas. *Neurosurgery* 45:221–230 (Comment)
3. Bakay L (1984) Olfactory groove meningiomas: the missed diagnosis. *JAMA* 251:53–55
4. Bindal R, Goodman JM, Kawasaki A, Purvin V, Kuzma B (2003) The natural history of untreated skull base meningiomas. *Surg Neurol* 59:87–92
5. Couldwell WT, Fukushima T, Giannotta SL, Weiss MH (1996) Petroclival meningiomas: surgical experience in 109 cases. *J Neurosurg* 84:20–28
6. Cushing H, Eisenhardt L (1938) Meningiomas: their classification, regional behavior, life history, and surgical end results. Charles C Thomas, Springfield
7. Cusimano MD, Sekhar LN, Sen CN, Pomonis S, Wright DC, Biglan AW, Jannetta PJ (1995) The results of surgery for benign tumours of the cavernous sinus. *Neurosurgery* 37:1–10
8. Desai R, Bruce J (1994) Meningiomas of the cranial base. *J Neurosurg* 20:255–279
9. Englehard HH (2001) Progress in the diagnosis and treatment of patients with meningiomas. Part I: Diagnostic imaging, preoperative embolization. *Surg Neurol* 55:89–101
10. Goel A, Muzumdar D, Desai KI (2002) Tuberculum sellae meningioma: a report on management on the basis of a surgical experience with 70 patients. *Neurosurgery* 51:1358–1364
11. Iwai Y, Yamanaka K, Yasui T, Komiyama M, Nishikawa M, Nakajima H, Kishi H (1999) Gamma knife surgery for skull base meningiomas: the effectiveness of low-dose treatment. *Surg Neurol* 52:40–45
12. Jung HW, Yoo H, Peak SH, Choi KS (2000) Long term outcome and growth rate of subtotally resected petroclival meningiomas. *Neurosurgery* 46:567–575
13. Jallo GI, Benjamin V (2002) Tuberculum sellae meningiomas: microsurgical anatomy and surgical technique. *Neurosurgery* 51:1432–1440
14. Kawase T (1999) Proposed grading system to predict the extent of resection and outcomes for cranial base meningiomas. *Neurosurgery* 45:221–230 (Comment)
15. Kinjo T, Al-Mefty O, Ciric I (1995) Diaphragma sellae meningiomas. *Neurosurgery* 36:1082–1092
16. Kinjo T, Mukawa J, Koga H, Shingaki T (1997) An extensive cranial base meningioma extending bilaterally into Meckel's cave: case report. *Neurosurgery* 40:615–618
17. Kuratsu JI, Kochi M, Ushio Y (2000) Incidence and clinical features of asymptomatic meningiomas. *J Neurosurg* 92:766–770
18. Lee JH, Jeun S, Evans J, Kosmorsky G (2001) Surgical management of clinoidal meningiomas. *Neurosurgery* 48:1012–1021
19. Levine ZT, Buchanan RI, Sekhar LN, Rosen CL, Wright DC (1999) Proposed grading system to predict the extent of resection and outcomes for cranial base meningiomas. *Neurosurgery* 45:221–230
20. Mathiesen T, Lindquist C, Kihlström L, Karlsson B (1996) Recurrence of cranial base meningiomas. *Neurosurgery* 39:2–9
21. Olivero WC, Lister JR, Elwood PW (1995) The natural history and growth rate of asymptomatic meningiomas: a review of 60 patients. *J Neurosurg* 83:222–224
22. Roberti F, Sekhar LN, Kalavakonda C, Wright DC (2001) Posterior fossa meningiomas: surgical experience in 161 cases. *Surg Neurol* 56:8–21

23. Pieper DR, Al-Mefty O (1999) Management of intracranial meningiomas secondarily involving the infratemporal fossa: radiographic characteristics, pattern of tumour invasion, and surgical implications. *Neurosurgery* 45:231–235
24. Pieper DR, Al-Mefty O, Hanada Y, Buechner D (1999) Hyperostosis associated with meningioma of the cranial base: secondary changes or tumour invasion. *Neurosurgery* 44:742–747
25. Samii M, Carvalho GA, Tatagiba M, Matthies C (1997) Surgical management of meningiomas originating in Meckel's cave. *Neurosurgery* 41:767–772
26. Sindou A (1993) Prognostic factors in the surgery for intracranial meningioma. Role of the tumoural size and arterial vascularization originating from the pia mater. Study of 150 cases [in French]. *Neurochirurgie* 39:337–347
27. Tsutsumi K, Ohno H, Okada Y, Fujimaki T, Kirino T (1999) Fenestrated oculomotor nerve caused by meningioma around the cavernous sinus: a surgical pitfall in tumour removal: case report. *Neurosurgery* 44:395–396
28. Spallone A, Makhmudov UB, Mukhamedjanov DJ, Tcherekajev VA (1999) Petroclival meningioma: an attempt to define the role of skull base approaches in their surgical management. *Surg Neurol* 51:412–420
29. Stafford SL, Pollock BE, Foote RL, Link MJ, Gorman DA, Schomberg PJ, Leavitt JA (2001) Meningioma radiosurgery: tumour control, outcomes, and complications among 190 consecutive patients. *Neurosurgery* 49:1029–1038
30. Van Havenbergh T, Carvalho G, Tatagiba M, Plets C, Samii M (2003) Natural history of petroclival meningiomas. *Neurosurgery* 52:55–64
31. Voss NF, Vrionis FD, Heilman CB, Robertson JH (2000) Meningiomas of the cerebellopontine angle. *Surg Neurol* 53:439–447