



# Optic nerve sheath diameter asymmetry in healthy subjects and patients with intracranial hypertension

Andrea Naldi<sup>1</sup> · Paolo Provero<sup>2,3</sup> · Alessandro Vercelli<sup>1,4</sup> · Mauro Bergui<sup>5</sup> · Anna Teresa Mazzeo<sup>6</sup> · Roberto Cantello<sup>7</sup> · Giacomo Tondo<sup>8</sup> · Piergiorgio Lochner<sup>9</sup>

Received: 21 June 2019 / Accepted: 11 September 2019 / Published online: 5 October 2019  
© Fondazione Società Italiana di Neurologia 2019

## Abstract

**Background** Ultrasonography of the optic nerve sheath diameter (ONSD) is used for the non-invasive assessment of increased intracranial pressure (ICP). ONSD values are usually obtained by averaging the measurements of the two eyes, but asymmetric ONSD dilation is possible, leading to potentially inaccurate ICP estimation when using binocular averaging. In addition, few data are available about the asymmetry of the ONSD and the use of the maximum ONSD value between eyes for raised ICP detection. The aim of the study was to evaluate the interocular ONSD asymmetry in healthy subjects and patients with intracranial hypertension (IH) by ultrasonography and to investigate whether the maximum ONSD could be as useful as the binocular assessment.

**Methods** Forty healthy subjects and 40 patients with IH (20 with idiopathic intracranial hypertension and 20 with intracerebral hemorrhage) who underwent transorbital sonography were retrospectively enrolled. The prevalence and degree of ONSD asymmetry were compared among groups; ONSD median binocular and maximum values were compared.

**Results** Forty-two out of 80 subjects (52.5%) showed significant ONSD asymmetry, without significant differences in prevalence among groups ( $p = 0.28$ ). The median asymmetry was higher in patients than in healthy subjects (0.45 mm vs 0.23 mm;  $p = 0.007$ ), without significant differences between the two pathologies ( $p = 0.58$ ). Both binocular and maximum ONSD measurements were significantly higher in patients with IH than in controls ( $p < 0.001$ ).

**Conclusions** Interocular ONSD asymmetry occurs both in healthy subjects and, more consistently, in patients with IH. Both binocular and maximum ONSD may be useful markers for increased ICP detection.

**Keywords** Optic nerve sheath diameter · Intracranial hypertension · Idiopathic intracranial hypertension · Intracerebral hemorrhage · Transorbital sonography · Asymmetry

## Introduction

Elevated intracranial pressure (ICP) may be indirectly evaluated by measuring the optic nerve sheath diameter (ONSD) [1]. The rationale resides in the anatomical continuity between

the subarachnoid space of the optic nerve sheaths and that of the brain, allowing the circulation of cerebrospinal fluid (CSF) from the perichiasmatic cistern to the ocular regions [2]. With increasing ICP, the pushing pressure drives a larger amount of CSF toward the orbital spaces. As a result, the ONSDs enlarge

✉ Andrea Naldi  
naldi.andrea@yahoo.it

<sup>1</sup> Department of Neuroscience “Rita Levi Montalcini”, University of Turin, Turin, Italy

<sup>2</sup> Department of Molecular Biotechnology and Health Sciences, University of Turin, Turin, Italy

<sup>3</sup> Center for Translational Genomics and Bioinformatics, San Raffaele Scientific Institute IRCCS, Milan, Italy

<sup>4</sup> Neuroscience Institute Cavalieri Ottolenghi, Orbassano, Italy

<sup>5</sup> Neuroradiology, Department of Neuroscience “Rita Levi Montalcini”, University of Turin, Turin, Italy

<sup>6</sup> Anesthesia and Intensive Care, Department of Surgical Sciences, University of Turin, Turin, Italy

<sup>7</sup> Department of Translational Medicine, Section of Neurology, Università del Piemonte Orientale, Novara, Italy

<sup>8</sup> Vita-Salute San Raffaele University, Milan, Italy

<sup>9</sup> Department of Neurology, Saarland University Medical Center, Homburg, Germany

and optic disc elevation develops over time. However, the CSF transmission may be limited at the level of the optic canals where the composition of the subarachnoid space changes, becoming subdivided in small compartments and narrowing its lumen to a capillary size [3]. This specific architecture, made of thick pillars and trabeculae, is assumed to be responsible for the quantity and speed with which the CSF can be transferred to the optic sheaths, and its large inter-individual variability may explain the documented occurrence of asymmetric ONSD enlargement and unilateral papilledema [4, 5]. Furthermore, no data on individual interocular differences have been reported.

The ONSD may be explored with various techniques, transorbital sonography being one of the most promising due to its non-invasiveness, feasibility, and high diagnostic accuracy [6]. The application fields of this method in the clinical practice have been recently described [7]. Despite the anatomical remarks cited above, most ultrasonographic studies consider ONSD measurements as an average of binocular values, rather than the maximum value between the two eyes, leading to possible errors in estimating ICP, given the potential physiological asymmetry.

The aim of this study was to evaluate the variability, in term of symmetry, of the ONSD, by using ultrasonography in healthy subjects and patients with intracranial hypertension (IH), and to establish whether the maximum value of the ONSD could be as useful as the binocular assessment.

## Materials and methods

### Subjects

We retrospectively reviewed ONSD data from 80 subjects, collected from a dataset available from the authors [8, 9]. All participants were  $\geq 18$  years old; exclusion criteria were ocular trauma, glaucoma, and significant orbital mass. Forty normal subjects who underwent general medical, ophthalmological, and neurological evaluation to rule out signs and symptoms of IH and ocular pathologies were included in the healthy group. Forty patients, matched for gender but not for age, composed the IH group, and included 20 consecutive subjects with idiopathic intracranial hypertension (IIH) and 20 consecutive patients with primary acute supratentorial intracerebral hemorrhage (ICH).

Patients with IIH were recruited at the “Franz Tappeiner” Hospital of Merano Hospital between March 2014 and November 2015; raised ICP was established (after ONSD evaluation) by lumbar puncture with a CSF opening pressure  $\geq 25$  cm H<sub>2</sub>O according to the Friedmann diagnostic criteria [10]. ICH patients were admitted to the “Maggiore della Carità” Hospital of Novara from January to December 2017; elevated ICP

was determined by clinical conditions and cerebral CT scan. Radiologically, we considered only medium- to large-size cerebral hemorrhages ( $\geq 30$  ml) with at least two of the following: midline shift  $\geq 3$  mm, collapsed 3rd ventricle, hydrocephalus, compression of cisterns, and effacement of sulci with evidence of substantial edema [11, 12]. Hematoma size was calculated using the ABC/2 score (if rounded or ellipsoid shape) or ABC/3 score (irregular or multinodular) [13, 14]. Contextually, at least one clinical sign of elevated ICP had to be present, including bradycardia, altered consciousness, vomit, headache, pupillary abnormalities, or uncontrolled hypertension.

### Transorbital sonography

Transorbital ONSD sonography was performed following a previously described protocol using a Toshiba Medical System Aplio 300 (Nasu, Japan; linear probe 7.5–11 MHz with lateral resolution  $< 0.4$  mm) for healthy subjects and ICH patients, and a Toshiba Aplio ultrasound system XG (Toshiba Medical Systems, Nasu, Japan; linear probe 7.2–14 MHz, lateral resolution  $< 0.4$  mm) for IIH patients [15]. Ultrasonographic evaluations were performed by two skilled neurosonologists (A.N. and P.L.); all measurements were taken off-line by a single expert operator (P.L.) to reduce inter-observer variability. ONSD was calculated as the distance between the external hyperechogenic borders surrounding the optic nerve, corresponding to the periorbital subarachnoid space.

ONSD was evaluated on the axial plane in triplicate for each eye. Binocular ONSD was obtained by averaging these values between the eyes, while maximum ONSD was obtained by first averaging the three measurements for each eye and then taking the maximum of the two values.

### Statistical analysis

Statistical analysis was performed using the R software, version 3.6.0 [16]. For each subject, the ONSD asymmetry was evaluated as the absolute value of the difference between the mean ONSD of the two eyes; statistical significance was assessed using Welch's *t* test, with multiple testing correction performed with the Benjamini-Hochberg method at a false discovery rate of 5%. For group comparison, categorical variables were expressed as numbers and percentages and compared among groups with Fisher's exact test. Continuous variables, expressed as median and quartiles (Q1, Q3), were compared among more than two groups with the Kruskal-Wallis test, and between two groups with the Mann-Whitney *U* test.

## Results

Demographic data, mean ONSD values, and asymmetry are summarized in Table 1. The median age of subjects was 72.5 (range 44.75–79) and was significantly lower in IHH patients (37 (29–47.25),  $p < 0.001$ ), as expected for the pathology; gender did not differ between the three subgroups ( $p = 0.114$ ).

Forty-two out of 80 subjects (52.5%) showed a significant ONSD asymmetry between eyes at a false discovery rate of 5%, and the difference in prevalence among groups was not significant (16 for healthy subjects, 14 for ICH patients, and 12 for IHH;  $p = 0.28$ ). The median asymmetry was higher in patients with IH than in normal subjects (0.45 mm vs 0.23 mm,  $p = 0.007$ , Fig. 1a); when stratifying by pathology, the significance was confirmed for ICH patients ( $p = 0.012$ ), while the result for IHH patients was close to significance ( $p = 0.07$ ) when compared with the healthy group (Fig. 1b). There was no significant difference between ICH and IHH patients ( $p = 0.58$ ). For ICH patients, there was no significant correspondence between the hemorrhage site and the side of the larger ONSD ( $p = 0.41$ ).

Both the binocular and maximum ONSD values were significantly higher in the IH group (independently of the pathology) compared with the healthy group (both  $p < 0.001$ , Fig. 2a, b), with no significant differences among the two pathologies ( $p = 0.12$  and  $p = 0.15$ , respectively).

## Discussion

This study documented for the first time in a clinical context the occurrence and degree of interocular ONSD asymmetry by using transorbital sonography in healthy and pathological subjects with IH. Ultrasonography of the ONSD has been proposed as a non-invasive technique to evaluate ICP and ONSD behavior in various conditions. The sheath diameter may increase or shrink in response to ICP changes, but above a

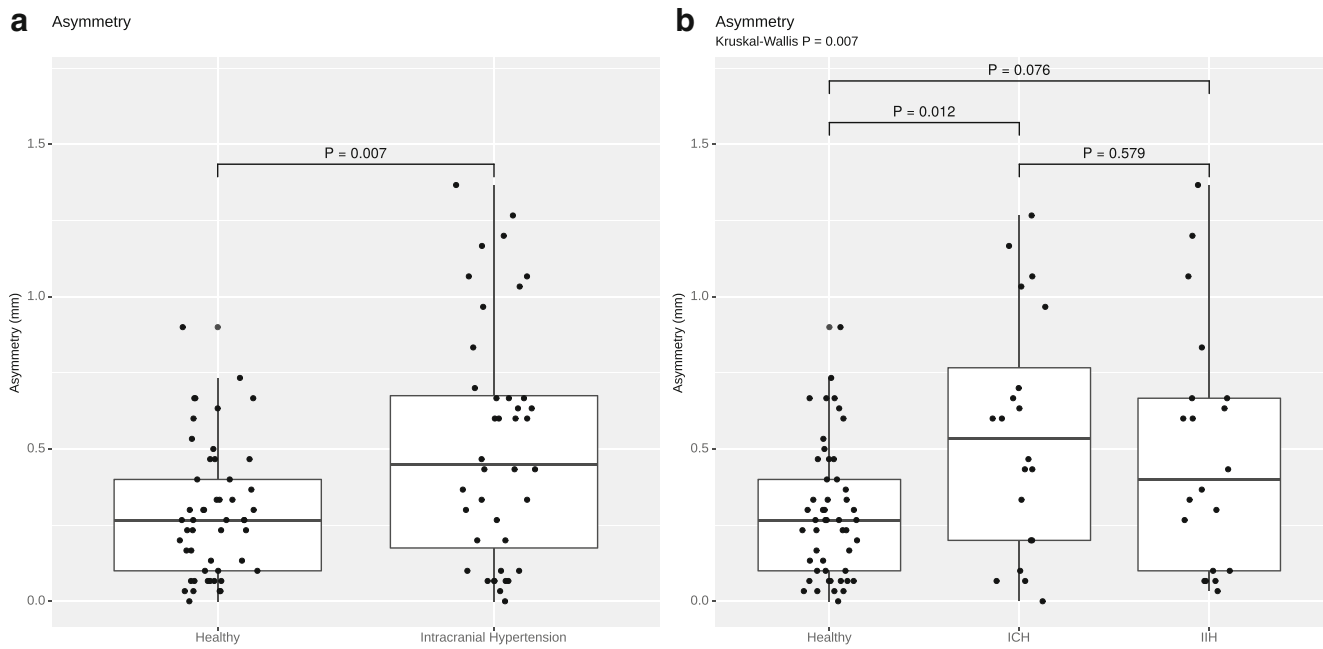
dilation threshold the enlargement seems to be irreversible [17, 18]. However, the exact reaction of the ONSD and the optic disc upon ICP variation remains elusive and different mechanisms may be involved in the orbital response, including optic atrophy, CSF and ocular pressure, and changes in the lamina cribrosa or optic nerve structures [19]. Regarding the anatomical aspects, some authors emphasized the role of the optic canals in the transmission of the CSF toward the optic sheaths [4]. Specifically, the thick arachnoid trabeculae and pillars that compose the complex meshwork of the optic canals may limit or even prevent the flow of CSF in the course of IH, determining a disproportionate expansion of ONSDs and unilateral papilledema [20–22]. In addition, an elevated inter-individual variability of optic canal conformation among humans and animals has been described [5, 21]. However, to our knowledge, no data are available about the interocular asymmetry of the ONSD between eyes both in normal conditions and following elevated ICP, particularly in a clinical setting where only isolated descriptions of asymmetry are mentioned [22]. Nevertheless, most ultrasonographic and radiological studies related to this topic evaluated the binocular ONSD value, without considering this anatomical variability, which may limit the enlargement of the optic sheaths, thus potentially leading to an inaccurate ICP estimation.

Our results documented an asymmetry of the ONSD of the two sides, both in healthy individuals and in patients with IH. The asymmetry increased following raised ICP, confirming the anatomical finding of a different architecture of the optic canals: If the CSF may not be adequately conveyed toward one of them because of a different composition in the trabecular network thickness, the two ONSDs may enlarge asymmetrically. No differences were observed between IHH and ICH subjects, suggesting that the asymmetry was independent on the cause and mechanism of intracranial hypertension. In fact, while in IHH increased ICP may be related to a pathological process involving the whole brain, in ICH it is a consequence

**Table 1** Demographic characteristics, binocular/maximum ONSD values, and asymmetry between eyes in healthy and pathological subjects

	Age	Gender (F)		
Healthy	75 (61.25–78.75)	47.5%		
Patients	63 (38–79.25)	62.5%		
ICH	79.5 (76.25–86.25)	50%		
IHH	37 (29–47.25)	66.7%		
	ONSD binocular (mm)	ONSD max (mm)	Asymmetry (mm)	
Healthy	4.72 (4.57–4.83)	4.73 (4.65–4.87)	0.23 (0.07–0.42)	
Patients	6.54 (6.22–7.03)	6.65 (6.31–7.23)	0.45 (0.18–0.68)	
ICH	6.66 (6.36–6.97)	6.77 (6.50–7.24)	0.53 (0.20–0.77)	
IHH	6.37 (6.09–7.05)	6.48 (6.15–7.05)	0.40 (0.10–0.67)	

All values are expressed as median (quartiles). F, female; ONSD, optic nerve sheath diameter; ICH, intracerebral hemorrhage; IHH, idiopathic intracranial hypertension



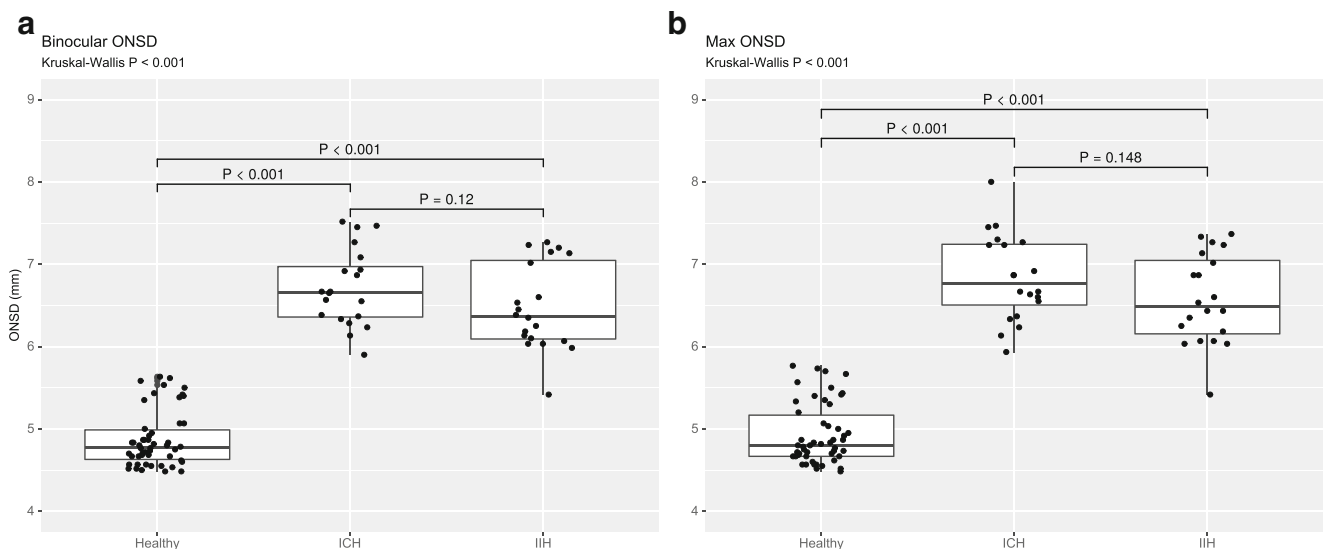
**Fig. 1** Degree of asymmetry (expressed in millimeters) in healthy subjects and patients with intracranial hypertension (a) and subgroup analysis dividing the cases by pathology (b). ICH, intracerebral hemorrhage; IIH, idiopathic intracranial hypertension

of a focal event. Interestingly, there was no association between the side of cerebral hemorrhage and the maximal ONSD dilation, further suggesting that anatomical aspects may influence the ONSD behavior.

The binocular ONSD assessment is a well-known technique for assessing increased ICP; conversely, only few studies evaluated the role of maximum ONSD for this purpose [23–25]. In our series, both binocular and maximum ONSD were significantly higher in patients than in healthy subjects; thus, both measures could be useful for the detection of elevated ICP. However, considering the asymmetry and the

possibility of a missing or reduced enlargement of the ONSD, ideally maximum ONSD could be a more precise and quicker measurement, especially when asymmetry is present.

There are some limitations to this study, mainly related to its retrospective design and to the small sample size. In ICH patients, diagnosis of IH was based on clinical and radiological findings, without directly measuring ICP. Finally, ONSD values were recorded by using two different sonographic machines. Further studies in a larger population are needed to confirm these results.



**Fig. 2** Binocular (a) and maximum (b) ONSD values in patients with intracranial hypertension and healthy subjects. ONSD, optic nerve sheath diameter; ICH, intracerebral hemorrhage; IIH, idiopathic intracranial hypertension

## Conclusions

An interocular ONSD asymmetry exists in normal subjects and patients with elevated ICP, with a larger extent in IH. If present, the asymmetry should be considered for correct ICP estimation. Both binocular ONSD measurements and maximum ONSD may be useful for the evaluation of raised ICP.

**Acknowledgments** The authors thank the AGING Project – Department of Excellence – DIMET, Università del Piemonte Orientale, which contributed to the organization of the study.

## Compliance with ethical standards

**Conflict of interest** The authors declare that they have no conflict of interest.

## References

- Khan MN, Shallwani H, Khan MU, Shamim MS (2017 Apr 5) Noninvasive monitoring intracranial pressure – a review of available modalities. *Surg Neurol Int* 8:51. [https://doi.org/10.4103/sni.sni\\_403\\_16](https://doi.org/10.4103/sni.sni_403_16)
- Sahu S, Swain A (2017) Optic nerve sheath diameter: a novel way to monitor the brain. *J Neuroanaesthesiol Crit Care* 4:S13–S18. [https://doi.org/10.4103/jnacc.jnacc\\_73\\_16](https://doi.org/10.4103/jnacc.jnacc_73_16)
- Hayreh SS (2011) Structure of the Optic Nerve. In: *Ischemic optic neuropathies*. © Springer-Verlag, Berlin Heidelberg. [https://doi.org/10.1007/978-3-642-11852-4\\_2](https://doi.org/10.1007/978-3-642-11852-4_2)
- Hayreh SS (1984) The sheath of the optic nerve. *Ophthalmologica* 189:54–63. <https://doi.org/10.1159/000309386>
- Killer HE, Laeng HR, Flammer J, Groscurth P (2003) Architecture of arachnoid trabeculae, pillars, and septa in the subarachnoid space of the human optic nerve: anatomy and clinical considerations. *Br J Ophthalmol* 87:777–781
- Robba C, Santori G, Czosnyka M, Corradi F, Bragazzi N, Padayachy L, Taccone FS, Citerio G (2018 Aug) Optic nerve sheath diameter measured sonographically as non-invasive estimator of intracranial pressure: a systematic review and meta-analysis. *Intensive Care Med* 44(8):1284–1294. <https://doi.org/10.1007/s00134-018-5305-7>
- Lochner P, Czosnyka M, Naldi A, Lyros E, Pelosi P, Mathur S, Fassbender K, Robba C (2019) Optic nerve sheath diameter: present and future perspectives for neurologists and critical care physicians. *Neurol Sci*. <https://doi.org/10.1007/s10072-019-04015-x>
- Lochner P, Fassbender K, Leismeister M, Nardone R, Orioli A, Brigo F, Stolz E (2018) Ocular ultrasound for monitoring pseudotumor cerebri syndrome. *J Neurol* 265(2):356–361. <https://doi.org/10.1007/s00415-017-8699-1>
- Naldi A, Pivetta E, Coppo L, Cantello R, Comi C, Stecco A, Cerrato P, Lesmeister M, Lochner P (2019 May) Ultrasonography monitoring of optic nerve sheath diameter and retinal vessels in patients with cerebral hemorrhage. *J Neuroimaging* 29(3):394–399. <https://doi.org/10.1111/jon.12604>
- Friedmann DI, Liu GT, Digre KB (2013 Sep 24) Revised diagnostic criteria for the pseudotumor cerebri syndrome in adults and children. *Neurology* 81(13):1159–1165. <https://doi.org/10.1212/WNL.0b013e3182a55f17>
- Lang EW, Ren Ya Z, Preul C, Hugo HH, Hempelmann RG, Buhl R, Barth H, Klinge H, Mehdorn HM (2001 Aug) Stroke pattern interpretation: the variability of hypertensive versus amyloid angiopathy haemorrhage. *Cerebrovasc Dis* 12(2):121–130
- Ohle R, McIsaac SM, Woo MY, Perry JJ (2015) Sonography of the optic nerve sheath diameter for detection of raised intracranial pressure compared to computer tomography: a systematic review and meta-analysis. *J Ultrasound Med* 34:1285–1294. <https://doi.org/10.7863/ultra.34.7.1285>
- Kothari RU, Brott T, Broderick JP, Barsan WG, Sauerbeck LR, Zuccarello M, Khoury J (1996) The ABCs of measuring intracerebral hemorrhage volumes. *Stroke* 27(8):1304–1305
- Huttner HB, Steiner T, Hartmann M, Köhrmann M, Jüttler E, Mueller S, Wikner J, Meyding-Lamade U, Schramm P, Schwab S, Schellinger PD (2006 Feb) Comparison of ABC/2 estimation technique to computer-assisted planimetric analysis in warfarin-related intracerebral parenchymal hemorrhage. *Stroke* 37(2):404–408
- Ertl M, Barinka F, Torka E, Altmann M, Pfister K, Helbig H, Bogdahn U, Gamulescu MA, Schlachetzki F (2014 Oct) Ocular color-coded sonography – a promising tool for neurologists and intensive care physicians. *Ultraschall Med* 35(5):422–431. <https://doi.org/10.1055/s-0034-1366113>
- R Core Team (2019) R: a language and environment for statistical computing. R Foundation for statistical computing, Vienna URL <https://www.R-project.org>
- Hansen HC, Lagrèze W, Krueger O, Helmke K (2011 Sep) Dependence of the optic nerve sheath diameter on acutely applied subarachnoid pressure – an experimental ultrasound study. *Acta Ophthalmol* 89(6):e528–e532. <https://doi.org/10.1111/j.1755-3768.2011.02159.x>
- Bäuerle J, Niesen WD, Egger K, Buttler KJ, Reinhard M (2016 Mar-Apr) Enlarged optic nerve sheath in aneurysmal subarachnoid hemorrhage despite normal intracranial pressure. *J Neuroimaging* 26(2):194–196. <https://doi.org/10.1111/jon.12287>
- Bidot S, Clough L, Saindane AM, Newman NJ, Bioussé V, Bruce BB (2016 Jun) The optic canal size is associated with the severity of papilledema and poor visual function in idiopathic intracranial hypertension. *J Neuroophthalmol* 36(2):120–125. <https://doi.org/10.1097/WNO.0000000000000318>
- Bidot S, Bruce BB, Saindane AM, Newman NJ, Bioussé V (2015 Mar) Asymmetric papilledema in idiopathic intracranial hypertension. *J Neuroophthalmol* 35(1):31–36. <https://doi.org/10.1097/WNO.0000000000000205>
- Hayreh SS (2016) Pathogenesis of optic disc edema in raised intracranial pressure. *Prog Retin Eye Res* 50:108–144. <https://doi.org/10.1016/j.preteyeres.2015.10.001>
- Skoloudík D, Herzig R, Fadmá T, Bar M, Hradílek P, Roubec M, Jelínková M, Sanák D, Král M, Chmelová J, Herman M, Langová K, Kanovsky P (2011 Feb) Distal enlargement of the optic nerve sheath in the hyperacute stage of intracerebral haemorrhage. *Br J Ophthalmol* 95(2):217–221. <https://doi.org/10.1136/bjo.2009.172890>
- Young AM, Guilfoyle MR, Donnelly J, Scoffings D, Fernandes H, Garnett M, Agrawal S, Hutchinson PJ (2017 Mar) Correlating optic nerve sheath diameter with opening intracranial pressure in pediatric traumatic brain injury. *Pediatr Res* 81(3):443–447. <https://doi.org/10.1038/pr.2016.165>
- Tarzamni MK, Derakhshan B, Meshkini A, Merat H, Fouladi DF, Mostafazadeh S, Rezakhah A (2016) The diagnostic performance of ultrasonographic optic nerve sheath diameter and color Doppler indices of the ophthalmic arteries in detecting elevated intracranial pressure. *Clin Neurol Neurosurg* 141:82–88. <https://doi.org/10.1016/j.clineuro.2015.12.007>
- Agrawal A, Cheng R, Tang J, Madhok DY (2019 Jun) Comparison of two techniques to measure optic nerve sheath diameter at risk for increased intracranial pressure. *Crit Care Med* 47(6):e495–e501. <https://doi.org/10.1097/CCM.00000000000003742>

**Publisher's note** Springer Nature remains neutral with regard to jurisdictional claims in published maps and institutional affiliations.