



# Preoperative botulinum toxin A (BTA) and intraoperative fascial traction (IFT) in the management of complex abdominal wall hernias

Henning Niebuhr<sup>1</sup> · Felix Wegner<sup>2</sup> · Halil Dag<sup>1</sup> · Wolfgang Reinpold<sup>1</sup> · Guido Woeste<sup>3</sup> · Ferdinand Köckerling<sup>4</sup>

Received: 9 June 2024 / Accepted: 26 August 2024  
© The Author(s) 2024

## Abstract

**Introduction** Preoperative botulinum toxin A (BTA) administration to the lateral abdominal wall has been widely used since its introduction for treating complex abdominal wall defects and loss of domain (LOD) hernias. Intraoperative fascial traction (IFT) is an established technique for complex abdominal wall hernias exceeding a width of 10 cm and has also shown auspicious results. We present our single center data including 143 consecutive cases combining both techniques from 2019 to 2023. Aim of the study was to develop an algorithm for a tailored approach for very large and complex ventral abdominal wall hernias.

**Methods** Consecutive patients treated with preoperative BTA and IFT from August 2019 to December 2023 were identified in our prospectively maintained database and reviewed retrospectively. Metrics included intraoperative findings and short-term (30 days) postoperative outcomes.

**Results** 143 patients were included in our retrospective analysis. The mean age was 58.9 years and 99% of all patients had an ASA Score of II or III with a mean body mass index of 32.4 kg/m<sup>2</sup>. The mean intraoperative reduction of fascia-to-fascia after BTA and IFT was 9.81 cm. 14 patients either had a lateral defect or a combination of a midline and lateral hernia. An additional uni- or bilateral transverse abdominis release (TAR) was necessary in 43 cases (30.1%). The overall surgical site occurrence rate (SSO) was 30.1% of which 13.8% were surgical site infections (SSI). Re-operation and SSO rates were significantly higher if an additional TAR was performed (both  $p=0.001$ ;  $\alpha=0.05$ ).

**Conclusions** IFT in combination with BTA is a transformative and clinically proven tool in the surgeons' toolbox. It might be an easier, and less invasive alternative to other available techniques in many cases, but it should not be looked at as an ultimate stand-alone method to treat all complex W3 hernias.

**Keywords** Ventral hernia repair · IFT · Fascial traction · Fasciotens · Incisional hernia · Abdominal wall reconstruction · Botox

## Introduction

Abdominal wall hernias are among the most common conditions requiring visceral and abdominal wall surgery. Even when considering advanced techniques for abdominal

wall closure, incisional hernia rates between 4 and 15% are reported after laparotomy [1–3]. Being burdened by an incisional hernia has a huge impact on body image and physical functioning [4]. Additionally, it has high socio-economic significance [5].

According to the midline incisional hernia guidelines of the European Hernia Society (EHS) for defects up to 10 cm in width (W1, W2 hernias), mesh augmentation in the retro-muscular plane and primary fascial closure is strongly recommended [6]. According to the classification of the EHS for complex W3 hernias (defects above 10 cm in width), the hernia gap can no longer be closed without tension. Therefore, complex reconstruction procedures and, if necessary, bridging with a mesh are required [7]. For the treatment of complex hernias, there are no internationally accepted

✉ Henning Niebuhr  
h.niebuhr@hernie.de

<sup>1</sup> Hamburg Hernia Center, Hamburg, Germany

<sup>2</sup> Agaplesion Bethesda Hospital Bergedorf, Hamburg, Germany

<sup>3</sup> Agaplesion Elisabethenstift Darmstadt, Darmstadt, Germany

<sup>4</sup> Hernienzentrum Vivantes Humboldt-Klinikum Berlin, Berlin, Germany

evidence-based recommendations or guidelines regarding the restoration of abdominal wall integrity. Depending on the extent of the abdominal wall defect and the individual patient conditions, different surgical procedures are used.

In the past, adequate treatment was usually only possible by using a form of component separation (CS). Since the 1990s, the anterior open component separation according to Ramirez, described by Albanese in 1951 [8, 9], has been of particular importance as one of the possible standard procedures in the treatment of very large abdominal wall and incisional hernias [10–12]. The principle of the operation consists of sufficient medialisation of the rectus compartments by deliberately weakening the lateral abdominal wall muscles via an incision of the external aponeurosis on both sides [13].

Possible disadvantages of this technique are the high risk of wound healing disorders (up to 48.2%) as a result of widespread detachment of the subcutaneous tissue, an increased rate of hematomas and seromas, and even skin necrosis due to compromised blood supply [11, 12]. A technical modification of the open Ramirez technique is the endoscopically assisted CS, as performed e.g. by Jørgensen et al. [14].

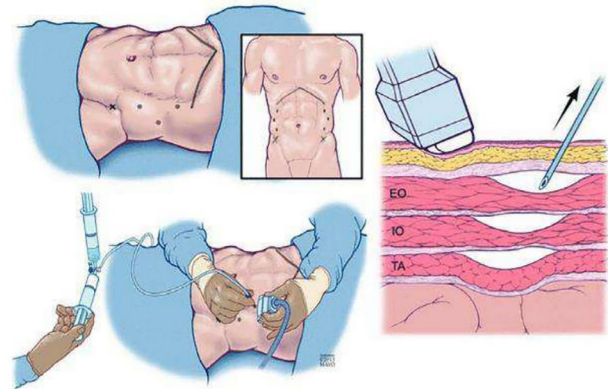
One way of avoiding the wide subcutaneous epifascial mobilisation is the posterior CS. First described by Carbonell in 2008 and subsequently modified as transversus abdominis muscle release (TAR) [15]. After longitudinal incision of the posterior sheet of the rectus sheath and dissection of the retro rectus space, the transverse muscle is released close to the semilunar line while sparing the vascular nerve bundles, allowing the retromuscular space to be widened on both sides, up to the psoas muscle if necessary (See Fig. 1) [13, 15].

Medialisation of the abdominal wall between 8.1 cm and 11.4 cm can be achieved using TAR in a cadaveric model [16]. However, with every CS technique, an abdominal muscle or its fascia is irrevocably dissected and thus functionally

inactivated, with possible long-term complications such as lateral abdominal wall weakness, poor posture, or bulging.

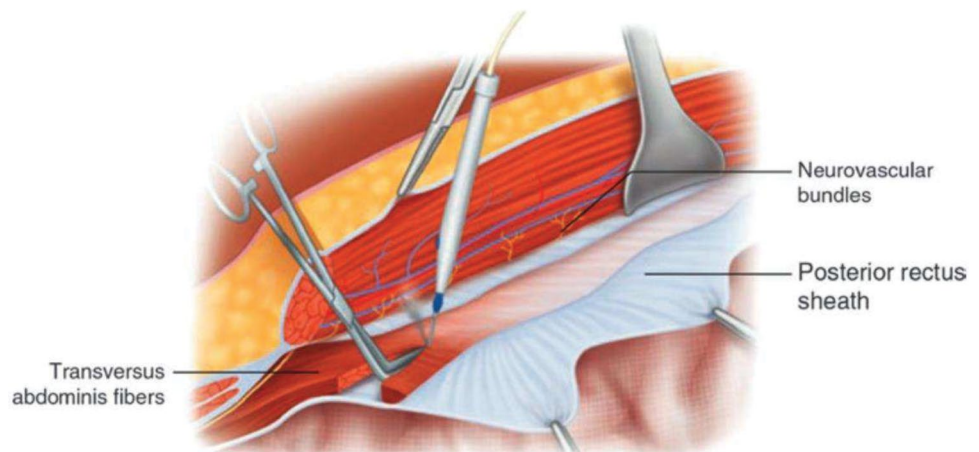
A relatively new procedure in the treatment of complex hernias is the use of botulinum toxin A (BTA), a neurotoxic protein, which leads to a temporary relaxation of the muscles. There are a variety of described protocols for the application of BTA. Most commonly, BTA is administered 4 weeks before surgery [18]. The amount of BTA used and the number of injection sites also vary. Usually, at least 100 units per side with 3–5 injection locations per side are administered (see Fig. 2) [19–21]. The effect of the BTA injection results in a significant rejuvenation and elongation of the oblique abdominal wall muscles with a simultaneous reduction of the horizontal hernia diameter, which has been impressively demonstrated in several studies [20, 22].

A meta-analysis showed a significant elongation of the lateral abdominal wall of 3.2 cm for each side if BTA was used preoperatively. The transverse hernia width was also



**Fig. 2** Ultrasound-guided application of botulinum toxin A—reproduced from Zendejas B, Khasawneh MA, Srwantstyan B, Jenkins DH, Schiller HJ, Zielinski MD. Outcomes of chemical component paralysis using botulinum toxin for incisional hernia repairs. *World J Su* [23]

**Fig. 1** Cutting the transverse abdominis fibres during transversus abdominis release—reproduced from Martin-del-Campo, L.A., Novitsky, Y.W. (2019). Technique: transversus abdominis release. In: Davis, Jr., S., Dakin, G., Bates, A. (eds) *The SAGES Manual of Hernia Surgery*. Springer, Cham. [https://doi.org/10.1007/978-3-319-78411-3\\_18](https://doi.org/10.1007/978-3-319-78411-3_18) [17]



significantly decreased; however, the results were heterogeneous. Furthermore, it also significantly increases the fascial closure rate [24].

### Intraoperative fascial traction (IFT)

Despite the development of different methods as described above, large incisional hernias are still a prominent problem for abdominal wall surgeons in a growing number of operations on increasingly older and often obese patients. Hernia sizes of 10–25 cm transverse extension and up to 30 cm longitudinal extension is not uncommon. A particular problem with these complex hernias is the so-called loss-of-domain situation, in which a large part of the organs is no longer in the abdominal cavity but in the hernia sac [2, 3].

Eucker pursued the idea of avoiding component separation to preserve the integrity of the lateral abdominal wall in the treatment of W3 hernias when he performed intraoperative vertical fascial traction for the first time in Basel to achieve direct closure of a complex hernia [25]. For the success of the procedure, complete muscular relaxation during the approximately 30 min of traction is required. The first results of the treatment of ten patients were published by Eucker in 2017 [25]. The risk of tissue damage due to the tearing out of sutures or clamps in the case of excessive traction or the risk of insufficient traction forces must thus be accepted. The lack of standardisation entailed certain dangers and made it necessary to quantify the traction force.

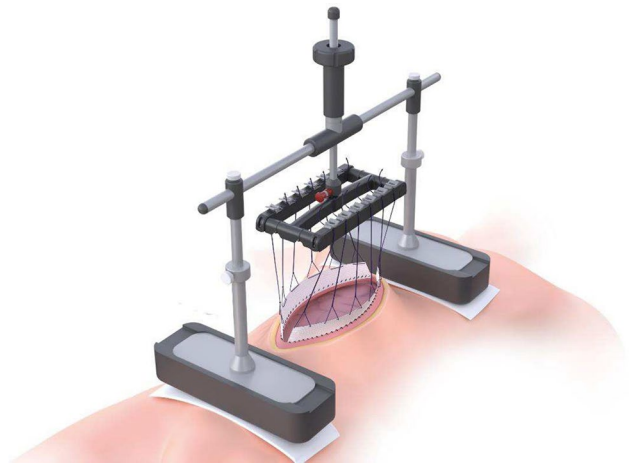
At the same time, the first results of perioperative traction of the abdominal wall in the treatment of laparoscopy patients using the fasciotens®Abdomen device were obtained. This innovative technique to avoid abdominal wall retraction in the open abdomen not only antagonizes the retraction but also helps to recover already retracted fascia [26–28].

This technique made it possible to quantify the traction forces applied to the fascia perioperatively in a standardized way. Traction forces of approx. 7–8 kg were applied perioperatively to the fascia to prevent fascial retraction in the treatment of open abdomen (see Fig. 3).

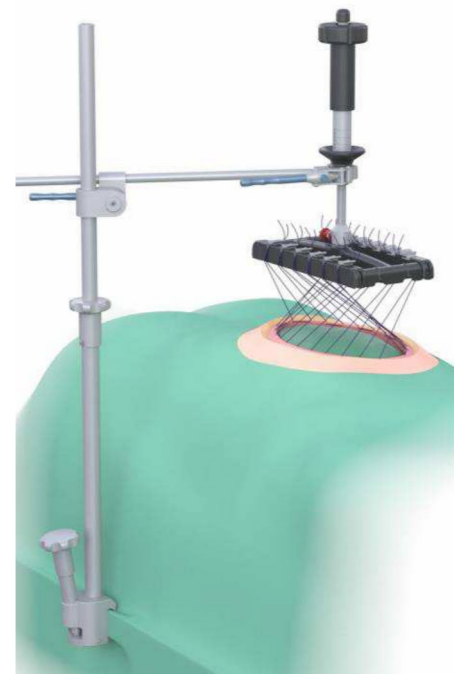
In the first intraoperative treatments of W3 hernias using the fasciotens®Abdomen published by Niebuhr et al., traction forces of more than 10 kg were required [29]. This need for quantification led to the development of the new device fasciotens®Hernia for IFT (see Fig. 4), which allows quantification of traction forces of up to approx. 20 kg.

Figure 5 shows the intraoperative procedure as well as the medial advancement of the lateral abdominal wall during traction.

Based on the experience gained with the technique, IFT was further developed to create a more atraumatic procedure. For this purpose, the diagonally crossed sutures are passed



**Fig. 3** Vertical fascial traction using fasciotens®Abdomen (courtesy of Fasciotens GmbH, Cologne, Germany)

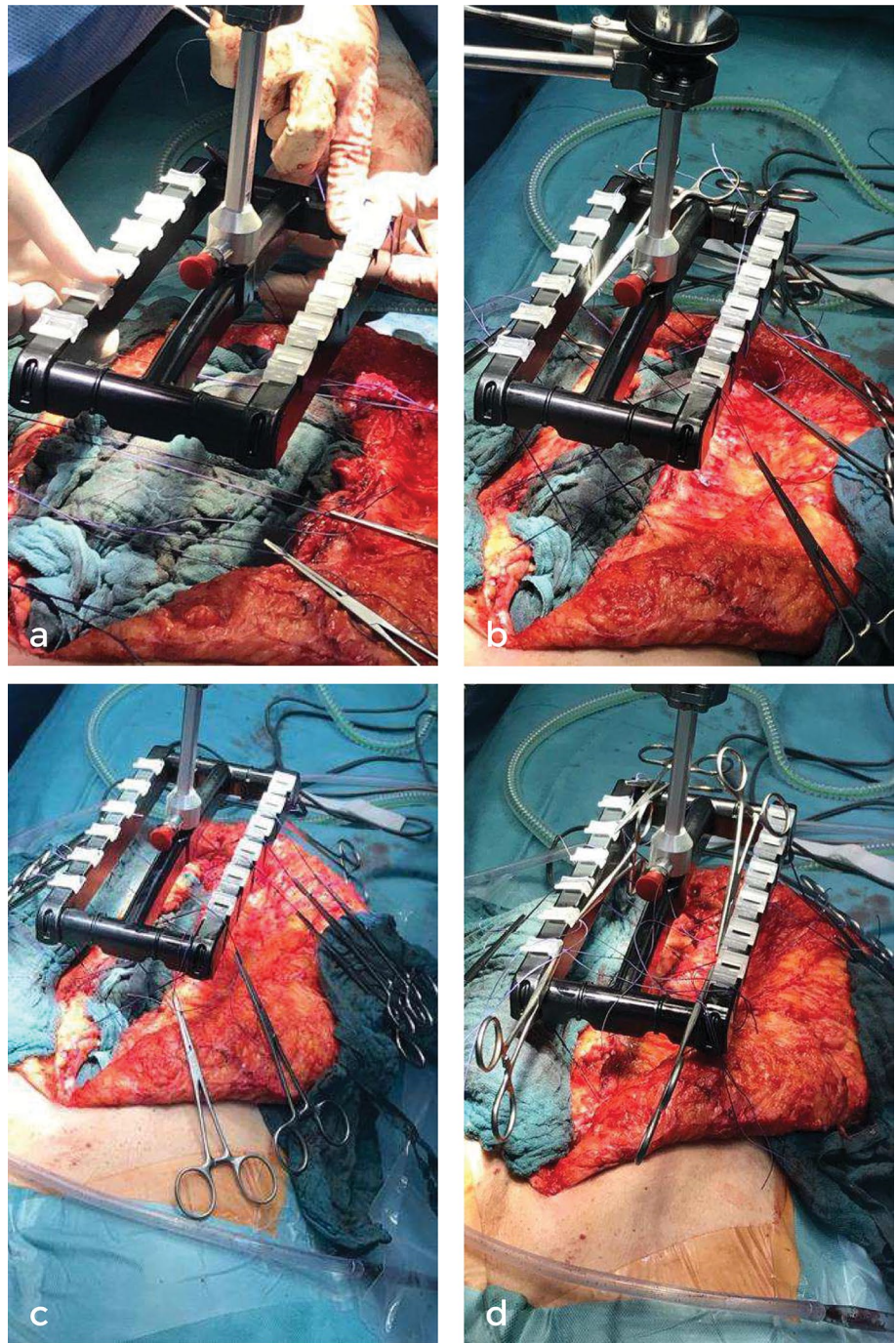


**Fig. 4** Schematic depiction of IFT using fasciotens®Hernia in combination with fasciotens®Carrier (Courtesy of Fasciotens GmbH, Cologne, Germany)

transcutaneously through the abdominal wall (see Fig. 6). The transcutaneous application of the traction sutures is advantageous as only relatively small skin incisions corresponding to the length of the initial scar are required. This provides a cosmetically more attractive result.



**Fig. 5** Intraoperative myofascial advancement during IFT for anterior rectus sheath: **a** situs before IFT **b** situs after 10 min of IFT **c** situs after 15 min of IFT **d** complete fascial closure after 25 min of IFT (courtesy of Fasciotens GmbH, Cologne, Germany)



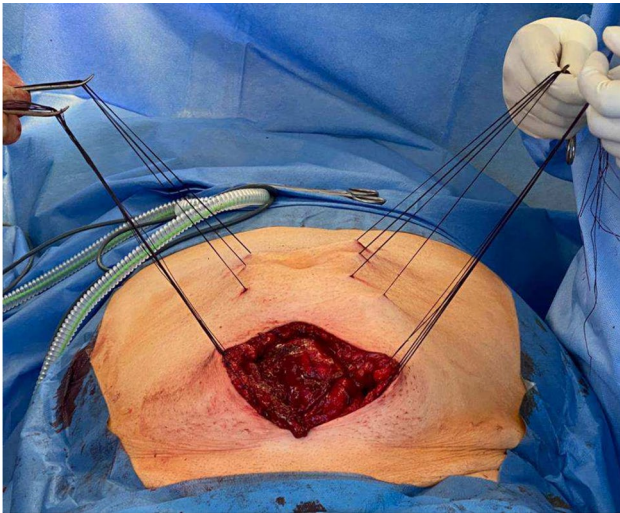
## Material and methods

### Patient population

Patients from the Hamburg Hernia Center treated between August 2019 and December 2023 have been included in this study. All patients had an incisional or recurrent incisional hernia with a preoperatively measured defect diameter above 10 cm (measured either in CT or MRI scan).

### Surgical procedure

All patients were pretreated with BTA 4 weeks before surgery. 200 IU of Botox® (AbbVie, North Chicago, USA) diluted with 0.9% saline were used at 3 injection points per side as previously described [23]. Every hernia repair was intraoperatively approached by preparing the hernia sac (if possible), restrained adhesiolysis and retrorectus dissection as described by Rives and Stoppa. The posterior rectus sheets were reconstructed either by restoring the midline or



**Fig. 6** MILOS (mini or less open sublay) approach for complex ventral hernia repair in combination with transcutaneous traction sutures for IFT (courtesy of Hamburg hernia centre)

if not possible, bridged using hernia sac. In case of an additional lateral defect or, if a wider mesh overlay was deemed necessary by the surgeon, an additional uni- or bilateral TAR was added. All patients received mesh augmentation in Sublay (retrorectus) position using PVDF meshes (DynaMesh®-CICAT, FEG Textiltechnik, Aachen, Germany). If a low-tension closure of the anterior rectus sheets was not possible, IFT was carried out using fasciotens®Hernia (Fasciotens GmbH, Essen, Germany). For preparation of IFT, 12 poly-filamentel surgical sutures (Vicryl™Plus, USP 2, Ethicon®, USA) (6 U-sutures distributed equally on each side) are sutured about 1 cm lateral to the margin of the anterior rectus sheets on each side with a stitch length of 2–3 cm. The sutures are then clamped diagonally into the suture retention frame of the IFT device. Traction forces of approx. 14–18 kg have been applied in this cohort. In addition, the traction sutures were regularly (every two minutes) retightened during the traction phase of 30 min to support myofascial advancement. If midline restoration was still not possible, an additional component separation was performed (if not done before) to achieve a closure of the anterior rectus sheets. Lastly, if complete closure was still not possible, a second PVDF mesh (DynaMesh®-CICAT, FEG Textiltechnik, Aachen, Germany) was inserted in sublay position and the margins of the anterior rectus sheets were sewn to it.

### Clinical outcomes

Patient-related data (age, gender, BMI and ASA score) were collected as described below. Complete closure rate of the anterior rectus sheets and Surgical Site Occurrences (SSO) were the primary clinical endpoints. Additionally, defect

width (anterior rectus sheets) before and after IFT was measured intraoperatively in each case.

### Data collection

All cases treated with a combination of BTA and IFT between August 2019 and December 2023 were identified. Informed consent was given by all patients to use anonymised data for future research prior to surgery. Patient data were prospectively collected and included in the German hernia registry *Herniamed* [30]. Patient characteristics were retrospectively retrieved from the *Herniamed* registry. Intra- and postoperative outcomes and data were retrospectively retrieved individually for each patient from medical files. Data analysis was carried out using Minitab® Statistical Software Version 21.3 (Minitab, LLC; State College, Pennsylvania, USA). Chi-square or Fisher's exact test was used for comparison between groups. The level of significance was determined with  $\alpha=0.05$ . Unless otherwise stated, the mean, median, standard error of the mean (SEM) and range are given.

### Results

IFT has been used in our hernia centre since August 2019 using the fasciotens®Abdomen device and since April 2021 using the specially designed fasciotens®Hernia device.

All patients had an incisional or recurrent incisional hernia. 5 patients only had a lateral defect, 129 had a defect in the midline and nine patients had a combination of both. The patient collective was nearly balanced between male and female. 99% of patients had comorbidities and mean BMI was  $32.4 \text{ kg/m}^2 \pm 0.9$  (mean and SEM) Table 1 shows the patient characteristics.

68.5% of patients had a hernia size above 15 cm. The maximum fascial distance (width) was measured intraoperatively before and after IFT. The mean intraoperative fascial distance was reduced from  $16.87 \pm 0.40$  cm to  $4.72 \pm 0.30$  cm and the myofascial advancement amounted to  $9.81 \pm 0.27$  cm (mean  $\pm$  SEM). The mean operation time was  $183.6 \pm 4.67$  min (mean  $\pm$  SEM). (Table 2).

Regarding the 30 days postoperative outcome, the patient collective was divided into the following subgroups (Fig. 7).

The complete fascial closure rate in subgroup 1 was 95.6%, in subgroup 2 78.7% and in subgroup 3 32.4%. An additional TAR was performed in 15.6% (subgroup 1), 29.5% (subgroup 2) and 48.6% (subgroup 3) of the cases. The overall TAR rate in the patient collective was 30.0%. Intestinal injury was the only observed intraoperative complication with two cases in subgroup 2 (2/61) and 3 cases in subgroup 3 (3/37). The rate of postoperative surgical site occurrences (SSO) was 24.4% in subgroup 1, 27.9%



**Table 1** Patient characteristics of the collective (n = 143)

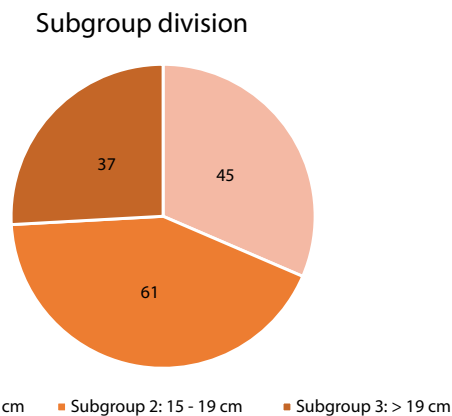
Patient characteristics (n = 143)	
Gender (male/female)	47%/53%
Age (years)	
Mean $\pm$ SEM	58.9 $\pm$ 1.2
Median, range	59 (26–88)
Body mass index (kg/m <sup>2</sup> )	
Mean $\pm$ SEM	32.4 $\pm$ 0.9
Median, range	30.0 (21.2–88.5)
ASA	
I	1.0%
II	47.2%
III	51.8%
IV	0%

SEM standard error of the mean

**Table 2** Intra- and postoperative measurements

Intra- and postoperative measurements (n = 143)	
Fascial distance before IFT (cm)	
Mean $\pm$ SEM	16.87 $\pm$ 0.40
Median, range	15 (8–44)
Fascial distance after IFT (cm)	
Mean $\pm$ SEM	4.72 $\pm$ 0.30
Median, range	4 (0–19)
Reduction of fascia distance (cm)	
Mean $\pm$ SEM	9.81 $\pm$ 0.27
Median, range	10 (2–22)
Operative time (min)	
Mean $\pm$ SEM	183.6 $\pm$ 4.67
Median, range	180 (67–473)
Length of stay (days)	
Mean value $\pm$ SEM	7.67 $\pm$ 0.48
Median, range	6.5 (2–49)

SEM standard error of the mean

**Fig. 7** Patient collective divided in three subgroups

in subgroup 2 and 40.5% in subgroup 3 (Table 3). This resulted in an overall SSO rate of 30.1%. The observed SSO varied per subgroup and are shown in Fig. 8. Non-surgical postoperative complications (urinary tract infection, pneumonia, pulmonary embolism, acute renal failure, apoplexy) occurred in 7.7% of all cases. A comparison of the complication rates of patients treated with IFT only or with IFT and additional TAR showed a complication rate of 22% and 48.8% respectively (Fig. 9). Thereby, the SSO rate was significantly higher in the IFT plus TAR group ( $p=0.001$ ;  $\alpha=0.05$ ). None of the cases developed an abdominal compartment syndrome (ACS) postoperatively. No device related complications occurred. A re-operation was necessary in 11.1% (subgroup 1), 16.4% (subgroup 2), 18.9% (subgroup 3) of the cases. However, performing a TAR also had a significant influence on the overall re-operation rate ( $p=0.001$ ;  $\alpha=0.05$ ). The mean length of stay was  $7.67 \pm 0.48$  days (mean and SEM).

## Discussion

This retrospective analysis included 143 patients treated with a combination of BTA and IFT. The aim was to propose an algorithm for complex abdominal wall repair. By categorising the defects by subgroups, it clearly shows that IFT in combination with BTA is sufficient in defects below 15 cm in diameter. The complete fascial closure rate (95.56%) and re-operation rate (11.1%) are comparable with results from TAR procedures by other specialised hernia centres [31]. However, the SSO rate of 24.4% appears to be higher compared to other studies but mainly consisted of subcutaneous seroma [32]. Additional TAR was necessary in subgroup 1 in seven cases where 42.9% of these patients either had a lateral or additional lateral defect.

If the defect width exceeds 15 cm, abdominal wall repair becomes even more challenging, and different techniques must be combined to achieve a reconstruction of the abdominal wall [33]. In our cohort, 68.5% of all patients had a hernia diameter of 15 cm or above. Naturally, a higher SSO and re-operation rate is anticipated in this patient group. Interestingly, an additional TAR led to a significantly higher rate of SSO (22% vs 48.8%,  $p=0.001$ ,  $\alpha=0.05$ ) as well as a significantly higher rate of re-operation ( $p=0.001$ ,  $\alpha=0.05$ ). Accordingly, due to the larger defect size, the rate of additional TAR was higher in cases with a diameter of 15 cm and above (subgroup 2–29.5%, subgroup 3–48.6%). Nevertheless, further studies are needed to determine if reducing the wound area and using a more economical preparation compared to established CS techniques can lower the overall complication rate.

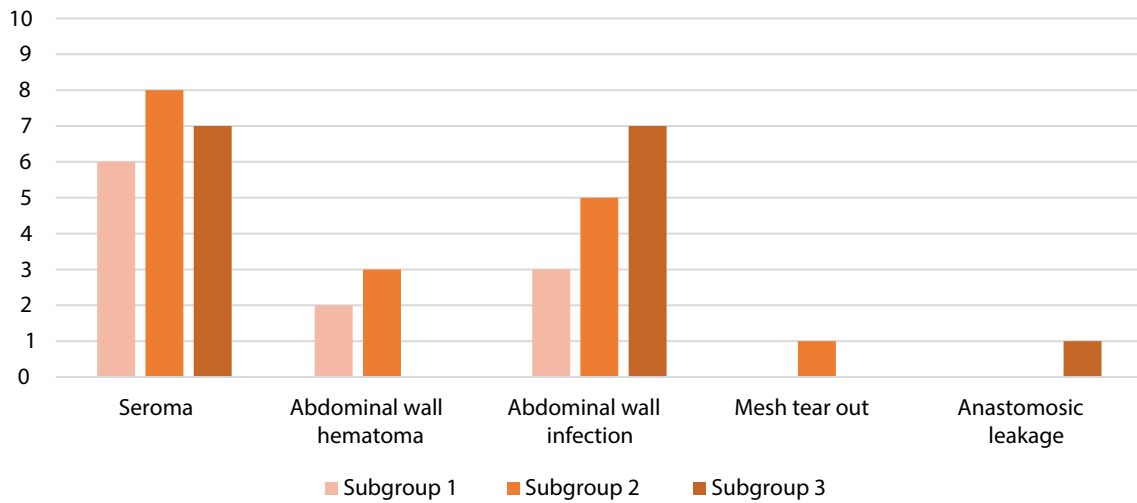
To minimize access trauma, the length of the skin incision can furthermore be limited to the diameter of the hernia

**Table 3** Subgroup analysis

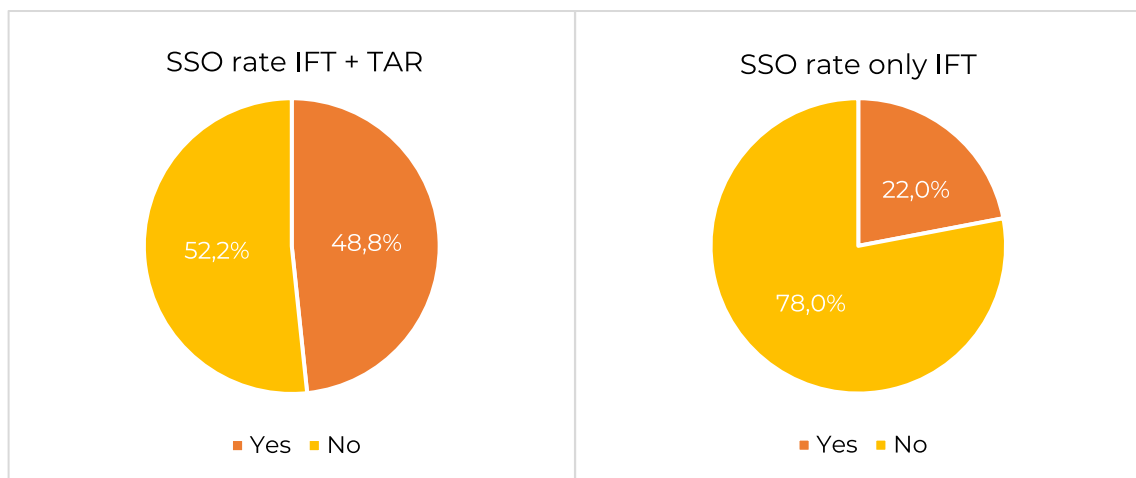
Subgroup analysis (n = 143)			
	Subgroup 1	Subgroup 2	Subgroup 3
Defect width [cm]	< 15	15–19	> 19
Lateral or additional lateral defect rate [%]	8.9	11.5	10.8
Closure rate [%]	95.6	78.7	32.4
TAR rate [%]	15.6	29.5	48.6
Intraoperative complication rate [%]	0	3.3	8.1
SSO [%]	24.4	27.9	40.5
SSI [%]	8.9	9.8	24.3
Re-operation [%]	11.1	16.4	18.9

SSO surgical site occurrences, SSI surgical site infections

### Postoperative Surgical Complications



**Fig. 8** Classification of postoperative surgical complications per subgroup



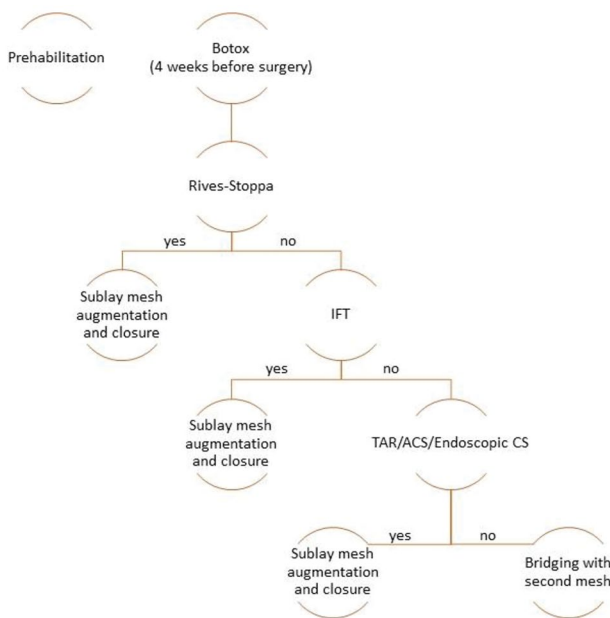
**Fig. 9** Postoperative surgical complication rates in comparing only IFT and IFT plus TAR

gap (depending on the size of the W3 hernia) according to the principles of the MILOS procedure [34]. Traction of the fascia can still be performed over the entire length of the defect using transcutaneous crossed traction, which we now use in most cases (see Fig. 6).

Based on the results described above, we have developed our Hamburg algorithm for the treatment of complex abdominal wall hernias (see Fig. 10):

All patients who have a midline hernia referred to our hernia center with a preoperatively measured defect width above 10 cm (either CT scan or MRI) are pretreated with BTA 4 weeks prior to surgery, since a midline restoration by only performing a Rives-Stoppa repair is very unlikely according to EHS classification [7]. Following our algorithm, we perform a retrorectus dissection as described by Rives-Stoppa. The posterior rectus sheets are reconstructed either by restoring the midline (if possible) or bridged using the hernia sac. In case of an additional lateral defect or, if deemed necessary by the surgeon regarding mesh overlay, an additional uni- or bilateral TAR is performed. All patients receive mesh augmentation (PVDF mesh in most cases) in Sublay (retrorectus) position. If a low-tension closure of the anterior rectus sheets is not possible, IFT is carried out. If midline restoration is still not possible, we normally perform additional component separation (if not done before) and if still not sufficient add a mesh bridging.

Preoperative rehabilitative measures such as smoking cessation and weight reduction should be considered in each case, regardless of the intraoperative technique



**Fig. 10** Hamburg algorithm for complex ventral and lateral abdominal wall hernias

chosen. Furthermore, in case of dermal fungal infections or pre-existing skin lesions, patients are referred to wound specialists for pretreatment.

Further studies on this algorithm regarding its efficacy, long-term complications and recurrences, and comparisons against other techniques are in progress.

However, in our opinion, the true value of the technique is the possibility to achieve low-tension midline closure without altering the anatomy of the lateral abdominal wall. Furthermore, IFT can be used to downsize very large defects and to support restoration of the abdominal wall in combination with other techniques. Therefore, the positive results of the combined treatment encourage us to continue on our chosen path.

### Long-term results

This retrospective analysis focused on intraoperative findings and short-term (30 days) postoperative outcomes. However, due to the novelty of IFT, long-term results are not yet available. Eucker et al. reported one recurrence in the long-term follow-up of his cohort of 33 AWEX patients [35]. However, an ongoing multicentre follow-up study on the long-term results of IFT involving 100 patients is nearing completion.

### Procedure expense

Since IFT is carried out using a specially designed medical device, additional costs for the device must be added. In our cohort, we had a mean operative time of 183.6 min including 30 min of IFT. Novitsky et al. reported a mean operative time for cases using TAR of 251 min in 428 cases which leads to a difference of 67 min on average [36]. In cases, where especially TAR is not necessary, using BTA and IFT could lead to an operative time reduction.

### Myofascial elongation

Since the introduction of BTA for component relaxation of the lateral oblique muscles, it has a largely growing number of users and has shown very promising results [20, 37, 38]. Nowadays, we normally combine BTA and IFT in all cases with hernia width above 10 cm. However, it remains unclear how much each technique contributes to the overall result. Nevertheless, a measurable effect of fascial traction on the lateral abdominal wall was demonstrated in a recently published cadaver study [39]. The median myofascial advancement reaches about 10 cm after IFT in fresh frozen specimens, which is comparable with the clinical results achieved in patients with abdominal wall defects. Furthermore, the medial and lateral compartments of the abdominal wall are accessible to IFT. However, in our cadaveric model, the



myofascial advancement was higher in the medial compartment. A limitation of IFT and BTA are L1 and L3 hernias (according to EHS classification). Due to the anatomical attachment of the lateral oblique muscles and fascia to the iliac crest inferolateral and to the ribs superiorly, the benefit of stretching the myofascial tissue in these cases seems to be limited.

### Mesh size

Further studies must show whether an extended space for mesh positioning will still be required for successful and recurrence-free midline closure of large, complex W3 hernias—even with loss-of-domain. This is all the more interesting because the IFT procedure utilises a relatively narrow mesh in the sublay position in the retro rectus space (Rives-Stoppa) to leave the oblique abdominal wall muscles and fascia intact.

### Abdominal compartment syndrome (ACS) in complex hernia repair

A life-threatening complication in complex ventral hernia repairs is the ACS [40, 41]. ACS is defined as an elevated intra-abdominal pressure above 20 mmHg in combination with a newly developed organ failure [42]. Hence, it is necessary to continuously monitor the intraabdominal pressure (with a bladder catheter) postoperatively for 24–48 h. Furthermore, the patient should be monitored in the ICU postoperatively and urinary output as well as ventilation parameters must be monitored meticulously to notice early signs of ACS [41].

### Limitations

For reasons of radiation protection and practicability, CT scans have not been performed after BTA administration. It is therefore not possible to quantify the myofascial advancement achieved by BTA pretreatment alone. However, each patient had a CT scan or MRI prior to surgery for preoperative planning. As this retrospective analysis focused on short-term 30-days outcome, no follow-up data was collected or included for this publication. However, since recurrence rates are one of the key outcome parameters in hernia repair, future studies should focus on answering the question whether IFT (in combination with BTA) can reduce the occurrence of recurrent hernias. In addition, comparative studies with more established techniques (e.g. TAR) are needed to determine firstly which patients benefit from each technique and secondly what added value IFT offers for the repair of complex abdominal wall defects.

## Conclusion

IFT in combination with BTA is a transformative and clinically proven tool in the surgeons' toolbox. It might be an easier, and less invasive alternative to other available techniques in many cases, but it should not be looked at as an ultimate stand-alone method to treat all complex W3 hernias. This is especially true in cases with a hernia defect width above 15 cm or additional lateral defects in which a combination of different techniques (e.g., TAR) is necessary. Based on our results, we propose our Hamburg algorithm.

**Data availability** Not applicable.

## Declarations

**Conflict of interest** The authors declare no conflict of interest.

**Ethical approval** Ethical review and approval was not required for the study on human participants in accordance with the local legislation and institutional requirements.

**Human and animal rights** This article does not contain any study with animals performed by any of the authors.

**Informed consent** The patients/participants provided their written informed consent to participate in this study.

**Open Access** This article is licensed under a Creative Commons Attribution-NonCommercial-NoDerivatives 4.0 International License, which permits any non-commercial use, sharing, distribution and reproduction in any medium or format, as long as you give appropriate credit to the original author(s) and the source, provide a link to the Creative Commons licence, and indicate if you modified the licensed material. You do not have permission under this licence to share adapted material derived from this article or parts of it. The images or other third party material in this article are included in the article's Creative Commons licence, unless indicated otherwise in a credit line to the material. If material is not included in the article's Creative Commons licence and your intended use is not permitted by statutory regulation or exceeds the permitted use, you will need to obtain permission directly from the copyright holder. To view a copy of this licence, visit <http://creativecommons.org/licenses/by-nc-nd/4.0/>.

## References

1. Gignoux B, Bayon Y, Martin D et al (2021) Incidence and risk factors for incisional hernia and recurrence: retrospective analysis of the French national database. *Colorectal Dis* 23:1515–1523. <https://doi.org/10.1111/codi.15581>
2. Höer J, Lawong G, Klinge U, Schumpelick V (2002) Einflussfaktoren der Narbenhernienentstehung Retrospektive Untersuchung an 2.983 laparotomierten Patienten über einen Zeitraum von 10 Jahren: Retrospektive Untersuchung an 2.983 laparotomierten Patienten über einen Zeitraum von 10 Jahren. *Chirurg* 73:474–480. <https://doi.org/10.1007/s00104-002-0425-5>

3. Le Huu NR, Mege D, Ouaiissi M et al (2012) Incidence and prevention of ventral incisional hernia. *J Visc Surg* 149:e3–e14. <https://doi.org/10.1016/j.jvisurg.2012.05.004>
4. Van Ramshorst GH, Eker HH, Hop WCJ et al (2012) Impact of incisional hernia on health-related quality of life and body image: a prospective cohort study. *Am J Surg* 204:144–150. <https://doi.org/10.1016/j.amjsurg.2012.01.012>
5. Mischinger H-J, Kornprat P, Werkgartner G et al (2010) Bauchdeckenverschluss bei Narbenhernien und Herniationen nach Laparostoma. *Chirurg* 81:201–210. <https://doi.org/10.1007/s00104-009-1818-5>
6. Sanders DL, Pawlak MM, Simons MP et al (2023) Midline incisional hernia guidelines: the European Hernia Society. *Br J Surg* 110:1732–1768. <https://doi.org/10.1093/bjs/znad284>
7. Muysoms FE, Miserez M, Berrevoet F et al (2009) Classification of primary and incisional abdominal wall hernias. *Hernia* 13:407–414. <https://doi.org/10.1007/s10029-009-0518-x>
8. Albanese AR (1951) Gigantic median xipho-umbilical eventration; method for treatment. *Rev Asoc Med Argent* 65:376–378
9. Albanese AR (1966) Liberating incisions in the treatment of large supraumbilical eventrations. *Prensa Med Argent* 53:2222–2227
10. Ramirez OM, Ruas E, Dellon AL (1990) “Components separation” method for closure of abdominal-wall defects: an anatomic and clinical study. *Plast Reconstr Surg* 86:519–526. <https://doi.org/10.1097/00006534-199009000-00023>
11. Lowe JB, Garza JR, Bowman JL et al (2000) Endoscopically assisted “components separation” for closure of abdominal wall defects. *Plastic Reconstruct Surg* 105:720–730. <https://doi.org/10.1097/00006534-200002000-00039>
12. Breuing K, Butler CE, Ferzoco S et al (2010) Incisional ventral hernias: Review of the literature and recommendations regarding the grading and technique of repair. *Surgery* 148:544–558. <https://doi.org/10.1016/j.surg.2010.01.008>
13. Carbonell AM, Cobb WS, Chen SM (2008) Posterior components separation during retromuscular hernia repair. *Hernia* 12:359–362. <https://doi.org/10.1007/s10029-008-0356-2>
14. Jensen KK, Henriksen NA, Jorgensen LN (2014) Endoscopic component separation for ventral hernia causes fewer wound complications compared to open components separation: a systematic review and meta-analysis. *Surg Endosc* 28:3046–3052. <https://doi.org/10.1007/s00464-014-3599-2>
15. Novitsky YW, Elliott HL, Orenstein SB, Rosen MJ (2012) Transversus abdominis muscle release: a novel approach to posterior component separation during complex abdominal wall reconstruction. *Am J Surg* 204:709–716. <https://doi.org/10.1016/j.amjsurg.2012.02.008>
16. Majumder A, Martin-del-Campo LA, Miller HJ et al (2020) Evaluation of anterior versus posterior component separation for hernia repair in a cadaveric model. *Surg Endosc* 34:2682–2689. <https://doi.org/10.1007/s00464-019-07046-9>
17. Martin-del-Campo LA, Novitsky YW (2019) Technique: transversus abdominis release. In: Davis SS, Dakin G, Bates A (eds) *The SAGES manual of hernia surgery*. Springer International Publishing, Cham, pp 237–248
18. Seretis F, Chrysikos D, Samolis A, Troupis T (2021) botulinum toxin in the surgical treatment of complex abdominal hernias: a surgical anatomy approach, current evidence and outcomes. *In Vivo* 35:1913–1920. <https://doi.org/10.21873/invivo.12457>
19. Rodriguez-Acevedo O, Elstner KE, Jacombs ASW et al (2018) Preoperative botulinum toxin A enabling defect closure and laparoscopic repair of complex ventral hernia. *Surg Endosc* 32:831–839. <https://doi.org/10.1007/s00464-017-5750-3>
20. Ibarra-Hurtado TR, Nuño-Guzmán CM, Miranda-Díaz AG et al (2014) Effect of botulinum toxin type A in lateral abdominal wall muscles thickness and length of patients with midline incisional hernia secondary to open abdomen management. *Hernia* 18:647–652. <https://doi.org/10.1007/s10029-014-1280-2>
21. Elstner KE, Jacombs ASW, Read JW et al (2016) Laparoscopic repair of complex ventral hernia facilitated by pre-operative chemical component relaxation using botulinum toxin A. *Hernia* 20:209–219. <https://doi.org/10.1007/s10029-016-1478-6>
22. Nielsen MØ, Bjerg J, Dorfelt A et al (2020) Short-term safety of preoperative administration of botulinum toxin A for the treatment of large ventral hernia with loss of domain. *Hernia* 24:295–299. <https://doi.org/10.1007/s10029-019-01957-1>
23. Zendejas B, Khasawneh MA, Srwantstyan B et al (2013) Outcomes of chemical component paralysis using botulinum toxin for incisional hernia repairs. *World J Surg* 37:2830–2837. <https://doi.org/10.1007/s00268-013-2211-6>
24. Timmer AS, Claessen JJM, Atema JJ et al (2021) A systematic review and meta-analysis of technical aspects and clinical outcomes of botulinum toxin prior to abdominal wall reconstruction. *Hernia* 25:1413–1425. <https://doi.org/10.1007/s10029-021-02499-1>
25. Eucker D, Zerz A, Steinemann DC (2017) Abdominal wall expanding system obviates the need for lateral release in giant incisional hernia and laparostoma. *Surg Innov* 24:455–461. <https://doi.org/10.1177/1553350617718065>
26. Fung Stephen N, Vaghiri S, Ashmawy H, Kropil F, Rehders A, Knoefel WT (2019) Fasciotens© abdomen ICU: novel device prevents abdominal wall retraction and facilitates early abdominal wall closure of septic open abdomen. *Surg Case Stud* 4:354–358. <https://doi.org/10.32474/SCSOAJ.2019.04.000177>
27. Hees A, Willeke F (2020) Prevention of fascial retraction in the open abdomen with a novel device. *Case Rep Surg* 2020:1–6. <https://doi.org/10.1155/2020/8254804>
28. Gombert A, Eickhoff R, Doukas P et al (2021) Vollständiger Bauchdeckenverschluss bei offenem Abdomen nach notfallmäßiger komplexer Aortenrekonstruktion bei „mid-aortic syndrome“ durch Anwendung von Fasciotens Abdomen® im Fall eines 16-jährigen Patienten. *Gefäßchirurgie* 26:56–60. <https://doi.org/10.1007/s00772-020-00707-3>
29. Niebuhr H, Aufenberg T, Dag H et al (2021) Intraoperative fascia tension as an alternative to component separation. A prospective observational study. *Front Surg* 7:616669. <https://doi.org/10.3389/fsurg.2020.616669>
30. Stechemesser B, Jacob DA, Schug-Paß C, Köckerling F (2012) Herniamed: an Internet-based registry for outcome research in hernia surgery. *Hernia* 16:269–276. <https://doi.org/10.1007/s10029-012-0908-3>
31. Zolin SJ, Krpata DM, Petro CC et al (2023) Long-term clinical and patient-reported outcomes after transversus abdominis release with permanent synthetic mesh: a single center analysis of 1203 patients. *Ann Surg* 277:e900–e906. <https://doi.org/10.1097/SLA.0000000000005443>
32. Wegdam JA, Thoelen JMM, Nienhuijs SW et al (2019) Systematic review of transversus abdominis release in complex abdominal wall reconstruction. *Hernia* 23:5–15. <https://doi.org/10.1007/s10029-018-1870-5>
33. Serafio-Gómez JL, Aragón-Quintana C, Bustillos-Ponce M et al (2023) Effective management of giant ventral hernias: a comprehensive approach combining preoperative botulinum toxin application, modified Ramírez’s component separation, and rives-stoppa hernioplasty. *Cureus*. <https://doi.org/10.7759/cureus.48967>
34. Niebuhr H, Malaibari ZO, Köckerling F et al (2022) Intraoperative Faszientraktion (IFT) zur Behandlung großer ventraler Hernien: Eine retrospektive Analyse von 50 Fällen. *Chirurg* 93:292–298. <https://doi.org/10.1007/s00104-021-01552-0>
35. Eucker D, Rüedi N, Luedtke C et al (2022) Abdominal wall expanding system. Intraoperative abdominal wall expansion as a technique to repair giant incisional hernia and laparostoma. *New*

- and long-term results from a three-center feasibility study. *Surg Innov* 29:169–182. <https://doi.org/10.1177/15533506211041477>
36. Novitsky YW, Fayeziadeh M, Majumder A et al (2016) Outcomes of posterior component separation with transversus abdominis muscle release and synthetic mesh sublay reinforcement. *Ann Surg* 264:226–232. <https://doi.org/10.1097/SLA.0000000000001673>
  37. Dias ERM, Rondini GZ, Amaral PHF et al (2023) Systematic review and meta-analysis of the pre-operative application of botulinum toxin for ventral hernia repair. *Hernia* 27:807–818. <https://doi.org/10.1007/s10029-023-02816-w>
  38. Whitehead-Clarke T, Windsor A (2021) The use of botulinum toxin in complex hernia surgery: achieving a sense of closure. *Front Surg* 8:753889. <https://doi.org/10.3389/fsurg.2021.753889>
  39. Niebuhr H, Reinhold W, Morgenroth F et al (2024) Assessment of myofascial medialization following intraoperative fascial traction (IFT) in a cadaveric model. *Hernia*. <https://doi.org/10.1007/s10029-024-03003-1>
  40. Barbosa E, Ferreira F (2017) Minimally invasive component separation for the repair of large abdominal wall defects. In: Latifi R (ed) *Surgery of complex abdominal wall defects*. Springer International Publishing, Cham, pp 125–139
  41. Quintela C, Freire L, Marrana F et al (2021) Quaternary abdominal compartment syndrome in complex ventral hernias. *Int J Abdom Wall Hernia Surg* 4:39. [https://doi.org/10.4103/ijawhs.ijawhs\\_43\\_20](https://doi.org/10.4103/ijawhs.ijawhs_43_20)
  42. Kirkpatrick AW, Roberts DJ, De Waele J et al (2013) Intra-abdominal hypertension and the abdominal compartment syndrome: updated consensus definitions and clinical practice guidelines from the World Society of the Abdominal Compartment Syndrome. *Intensive Care Med* 39:1190–1206. <https://doi.org/10.1007/s00134-013-2906-z>

**Publisher's Note** Springer Nature remains neutral with regard to jurisdictional claims in published maps and institutional affiliations.