

# Assessments of inclinations of the mandibular fossa by computed tomography in an Asian population

Cheng-Kuan Wu · Jui-Ting Hsu · Yen-Wen Shen ·  
Jin-Hua Chen · Wu-Chung Shen · Lih-Jyh Fuh

Received: 11 August 2010 / Accepted: 25 January 2011 / Published online: 12 February 2011  
© Springer-Verlag 2011

**Abstract** This study aims to evaluate the inclinations of right and left sides the mandibular fossa in Asian population using computed tomography (CT) images and determine its effects according to the parameters of gender, age, and asymmetry. CT images of the heads of 198 Asian subjects [95 females aged  $44.2 \pm 20.7$  years, range 11–88 years; and 103 males aged  $44.5 \pm 19.7$  years, range 15–98 years] were selected. The following eight parameters characterizing the inclinations of the mandibular fossa were measured by medical imaging software: anterior and posterior inclinations on the left and right sides on a sagittal view, and medial and lateral inclinations on the left and right sides on a coronal view. The anterior inclination was

significant steeper in males than in females on both the left and right sides. A moderate positive correlation was found between age and anterior inclinations on the left and right sides. None of the other parameters were significantly affected by age or gender. None of the parameters differed significantly between the right and left sides of the mandibular fossa in males, females, or all subjects. The anterior inclination of the mandibular fossa was affected by aging and gender becoming steeper in Asians males than females. Besides, there were no asymmetry in the right and left side inclinations of the mandibular fossa.

**Keywords** Mandibular fossa · Age · Gender · Bilateral · Computed tomography

---

**Clinical relevance** The values of the mandibular fossa inclination can be used for the articulator set up for clinical oral rehabilitation and to reduce the clinical errors and adjustment time.

---

C.-K. Wu · J.-T. Hsu · Y.-W. Shen · L.-J. Fuh (✉)  
School of Dentistry, College of Medicine,  
China Medical University,  
91 Hsueh-Shih Road,  
Taichung 40402, Taiwan  
e-mail: ljfuh@mail.cmu.edu.tw

Y.-W. Shen · L.-J. Fuh  
Department of Dentistry, China Medical University and Hospital,  
Taichung, Taiwan

J.-H. Chen  
Graduate Institute of Biostatistics and Biostatistics Center,  
China Medical University,  
Taichung 404, Taiwan

W.-C. Shen  
Department of Radiology, China Medical University Hospital,  
Taichung, Taiwan

## Introduction

The anatomy of the masticatory system suggests that occlusion might be influenced by characteristics of the temporomandibular joint (TMJ) [1]. The inclinations of the mandibular fossa play an important role in condyle movement [1]. Many dentists and researchers have investigated the morphology of the mandibular fossa [2], with most of the studies evaluating the relationship between occlusion [3, 4], TMJ disorders [5–7], and the morphology of the mandibular fossa [8]. In contrast, few studies have investigated age, gender, and asymmetry of the inclinations of the mandibular fossa between its right and left sides.

Some studies have investigated inclinations of the mandibular fossa based on parameters such as gender, age, and asymmetry of the angles of the articular tubercle [3, 9–11]. Cohlmiä et al. [3] found that the articular slopes (posterior inclination of the articular tubercle and anterior inclination of the mandibular fossa) were steeper in males

than in females, whereas Seward [8] claimed that there was no significant gender difference. Comparisons of the posterior inclination of the articular tubercle by age have also produced discrepant results [9–11]. Angel et al. [9] reported that the inclination of the articular tubercle increased with aging, whereas Moffett et al. [10] stated that it decreased with aging, mainly due to attrition and bone remodeling. Wish-Baratz et al. [11] found no relationship between age and the posterior inclination of the articular tubercle. Moreover, the literature contains inconsistent reports on the inclinations of the mandibular fossa on its right and left sides. Cohlmiä et al. [3] found that the posterior inclination of the articular tubercle was steeper on the left side than on the right side, where others reported that it was steeper on the right side [11, 12].

Several tools are available to study the morphology of the TMJ and condylar movement. In the past decades, plain radiographs such as panoramic radiographs, transcranial lateral oblique radiographs, and tomograms have been used to study the bony morphology of the TMJ [1]. Gilboa et al. [13] indicated that panoramic films can provide the anatomic incline of the posterior slope of the articular tubercle in dry skulls. Jasinovicus et al. [12] investigated the influences of age, gender, ethnicity, and number of teeth of the articular tubercle in dry skulls. Clark and Evans [14] demonstrated that the pathways of condyle movement in three-dimensional space could be reproduced by fully adjustable articulators. In addition, some researchers [15–17] have evaluated the dynamic condylar movement using virtual articulators. In addition to these approaches, computed tomography (CT) imaging allows the morphology of the TMJ to be measured noninvasively and *in vivo*. CT makes it possible to measure various parameters of TMJ skeletal morphology both accurately and comprehensively.

Whilst the morphology of the mandibular fossa has been studied previously [9–11], information on Asian populations is still rare, especially on the factors of age, gender, and asymmetry of the inclinations of the mandibular fossa between its right and left sides. The aim of this study was therefore to determine the effects of gender, age, and asymmetry of the right and left sides on the inclinations (anterior, posterior, medial, and lateral angles) of the mandibular fossa in an Asian population by using CT images.

## Materials and methods

### Selection of patients and CT scanning setup

The CT images of the head of 198 Asian subjects [95 females aged  $44.2 \pm 20.7$  years (mean  $\pm$  SD), range 11–88 years; and 103 males aged  $44.5 \pm 19.7$  years, range 15–98 years] were selected from the Radiology Department of

China Medical University and Medical Center. All the CT images included the complete head, and those with edentulous mouths or an incomplete mandibular fossa were excluded. The subjects who had received surgery to the TMJ or related structures were excluded from this study. The CT images were obtained (LightSpeed, General Electric, Milwaukee, WI, USA) with the following technical parameters: 1.25-mm increments, 120 kV, 300–400 mAs, 240-mm field of view, and  $512 \times 512$  pixels. All CT images were obtained between December 2007 and July 2009. The ethical issues of this study were approved by the institutional research board of China Medical University and Medical Center.

### Measurements of inclinations of the mandibular fossa

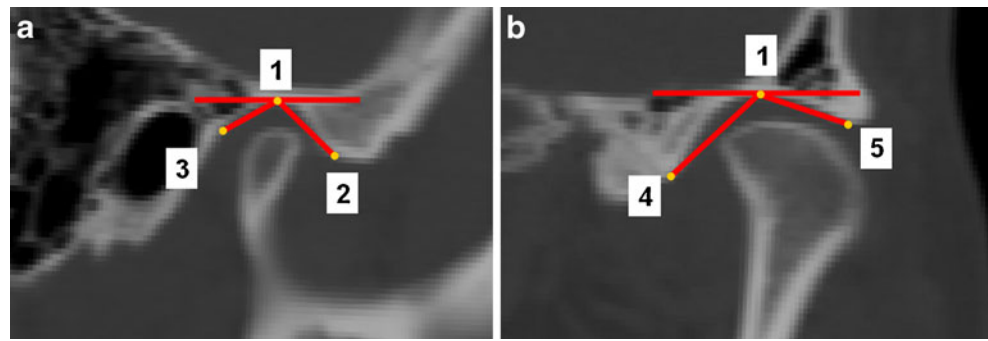
Before measuring the inclinations of the mandibular fossa, the coordinate system of each head was created in professional medical imaging software (Mimics 10.0, Materialise, Leuven, Belgium) using the “reslice” function, where the head was rotated first in the Frankfort horizontal (FH) plane parallel to the horizontal plane, followed by continued rotation with the head centered on the mid-sagittal plane of the image perpendicular to the FH plane (making the head face to the anatomy frontal view). The inclination of the mandibular fossa was measured in Mimics using the “angle measurement” function.

The slices in the coronal and sagittal planes containing the top of the mandibular fossa were selected as the pivot for the angle measurements (point #1 in Figs. 1a and 1b). The anterior and posterior inclinations of the mandibular fossa were measured on both sides of the selected sagittal plane: RA and LA refer to the anterior inclinations and RP and LP refer to the posterior inclinations of the mandibular fossa on its right and left sides, respectively. The anterior inclination was the angle between the tangent line of the posterior slope of the articular tubercle and the FH plane, while the posterior inclination was the line through the pivot and squamotympanic fissure (point #3 in Fig. 1a). The medial and lateral inclinations of the mandibular fossa were measured on the both sides of the selected coronal plane: RM and LM refer to the medial inclinations and RL and LL refer to the lateral inclinations of the mandibular fossa on its right and left sides, respectively. The medial inclination was the line through the pivot and petrosquamous fissure (point #4 in Fig. 1b), while the lateral inclination was the line through the pivot and the turning point of the lateral crest (point #5 in Fig. 1b).

### Statistical analysis

To test the reliability of “reslice” procedure, the same observer made repeated measurements on 41 samples.

**Fig. 1** The selected sagittal (a) and coronal (b) planes on the right side. Point #1: the top of the mandibular fossa; point #2: turning point of the posterior slope of the articular tubercle; point #3: squamotympanic fissure; point #4: petrosquamous fissure; point #5: turning point of the lateral crest



Paired *t* tests were performed and reliability coefficients were calculated. The reliability of the “reslice” function was found to be statistically acceptable ( $p > 0.05$ ). The intrarater and interrater reliabilities of angle measurements were tested by two observers repeating measurements five times on ten samples. Repeated measures analysis of variance (ANOVA) and the intraclass correlation coefficient (ICC) were used to determine the intrarater and interrater reliabilities of the angle measurements, respectively.

The effects of gender on the inclinations of the mandibular fossa were assessed using the two-sample *t* test. Pearson’s correlation coefficient was used to quantify the correlations of age with LA, LP, LL, LM, RA, RP, RL, and RM. Differences in the inclinations of the mandibular fossa on its left and right sides for each of the anterior, posterior, medial, and lateral directions were estimated by paired *t* test. The cutoff for statistical significance was a *p* value of 0.05. All the statistical analyses were performed by the SAS statistical package (SAS Institute, Cary, NC, USA).

**Results**

**Intrarater and interrater reliability of the measurement**

The intrarater error was determined by the inclinations of the mandibular fossa for eight angles (RA, LA, RP, LP, RM, LM, RL, and LL) measured five times by a single examiner; the *p* values of repeated measures ANOVA tests were within the range 0.066–0.969, and the ICC values were within the range 0.856–0.967. In addition, the interrater error was determined by the inclinations of the mandibular fossa for eight angles (RA, LA, RP, LP, RM, LM, RL, and LL) measured once by each of two examiners; the ICC values were within the range 0.855–0.969. An ICC of  $\geq 0.7$  is usually considered satisfactory, indicating that there was a strong correlation in the measurements between our two examiners.

**Effect of gender on inclinations of the mandibular fossa**

The average angles of the eight parameters in the male and female groups and for all subjects are listed in Table 1. LA, LP, and RA were significantly steeper in males than in females, with the correlation being weaker for LP. The other five parameters did not differ significantly with gender.

**Effect of age on inclinations of the mandibular fossa**

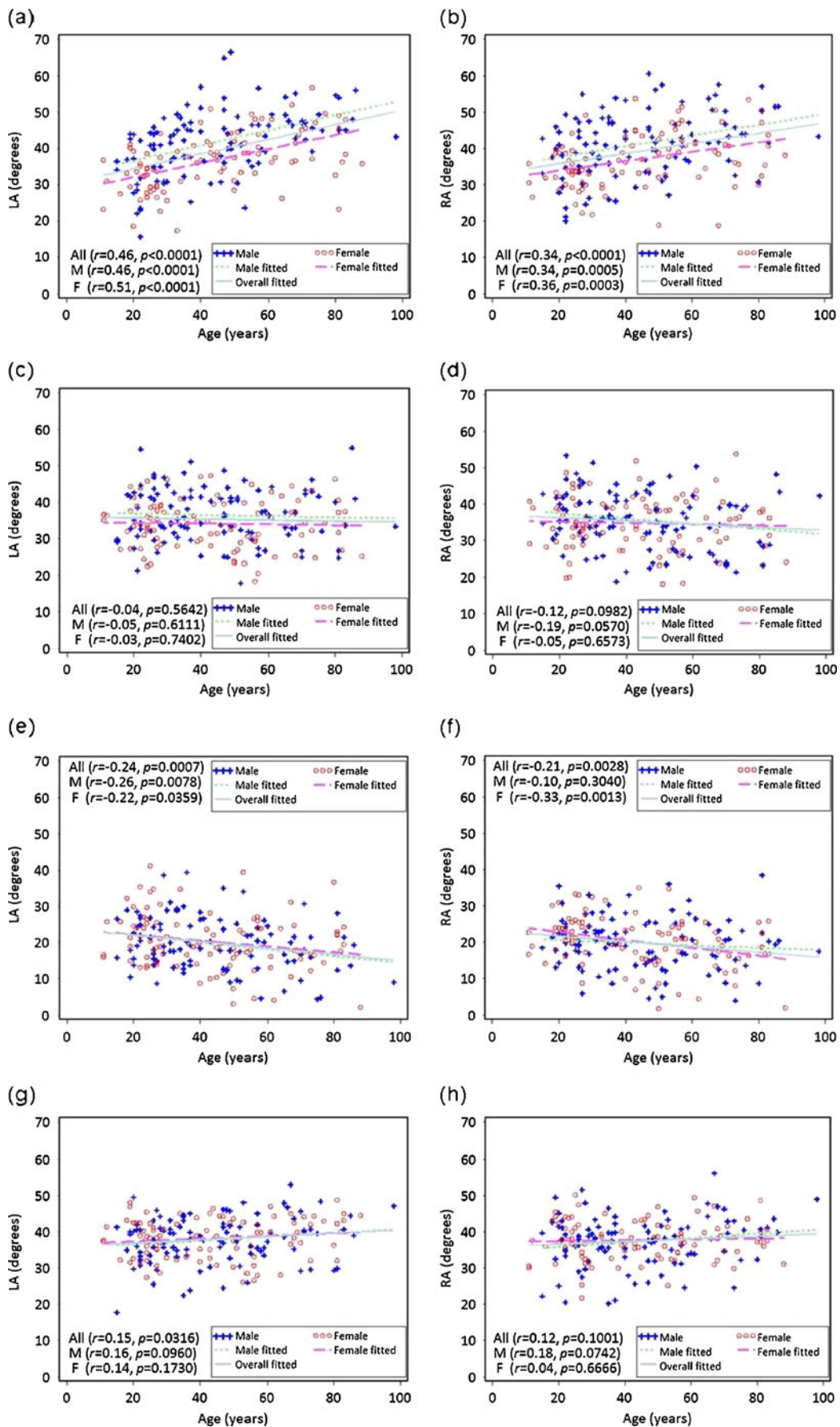
The anterior inclinations tended to increase with age (Fig. 2). Table 2 lists the continuous variables and Pearson’s correlation coefficients with age as a variable. Age had a greater effect on the anterior inclination of the mandibular fossa than on its other inclinations. In addition, a moderate positive correlation was found between age and anterior

**Table 1** Comparisons of inclinations of the mandibular fossa with gender

Variable	All (N=198) Mean±SD	Females (N=95) Mean±SD	Males (N=103) Mean±SD	<i>p</i> value*
LA	39.3±8.7	36.8±7.8	41.7±8.9	<0.0001
LP	35.3±7.1	34.1±6.6	36.4±7.3	0.0197
LL	19.9±7.5	20.2±7.8	19.6±7.2	0.5813
LM	38.0±5.9	38.2±5.5	37.7±6.4	0.5530
RA	39.2±8.4	37.0±7.4	41.2±8.7	0.0004
RP	35.1±7.6	34.7±7.5	35.6±7.6	0.3858
RL	19.9±6.9	20.2±6.9	19.7±7.0	0.6120
RM	37.5±6.1	37.7±5.5	37.3±6.7	0.6228

RA mean anterior inclination of the mandibular fossa on its right side; LA mean anterior inclination of the mandibular fossa on its left side; RP mean posterior inclination of the mandibular fossa on its right side; LP mean posterior inclination of the mandibular fossa on its left side; RM mean medial inclination of the mandibular fossa on its right side; LM mean medial inclination of the mandibular fossa on its left side; RL mean lateral inclination of the mandibular fossa on its right side; LL mean lateral inclination of the mandibular fossa on its left side

\*two-sample *t* test between male and female groups



◀ **Fig. 2** Relationships between age and inclination of the mandibular fossa in males (*M*, blue crosses and green dotted lines), females (*F*, red circles and purple dotted lines), and all subjects (*All*, light blue lines): **a** LA, **b** RA, **c** LP, **d** RP, **e** LL, **f** RL, **g** LM, and **h** RM

angles of the mandibular fossa on its right and left sides (RA and LA). In addition, the effect of age on inclinations of the mandibular fossa did not differ significantly with gender.

Effect of side on inclinations of mandibular fossa

Table 3 lists the mean and standard deviation values of the inclinations of the mandibular fossa on its right and left sides. There were no significant differences between the right and left sides of the mandibular fossa in any of the parameters for males, females, and all subjects.

**Discussion**

The TMJ is a complex three-dimensional structure of the human body. In the past decades, plain radiographs, such as panoramic radiographs, transcranial lateral oblique radiographs, and tomograms have been used to study the bony morphology of the TMJ [1]. However, the bony morphology of the TMJ cannot be precisely assessed in the superimposed images when using plain radiographs [18]. Therefore, many studies have directly assessed cadavers in an invasive manner [8, 11, 12, 19–21]. In contrast to cadaver-based studies, CT imaging is a useful approach to obtaining spatial information on bony structures in vivo [18, 22]. The present study evaluated the morphology of the mandibular fossa using CT in an Asian population. The information obtained in this study could provide guidelines to dentists for operating an articulator and to manufacturers for improving the design of articulators.

Based on intrarater reliability testing, the *p* values of repeated measures ANOVA tests were within the range 0.066–0.969. Although the low intrarater error shows that there was no significant difference in multiple measurements made by a single rater, there was a large variation in the *p* values, which might be due to the mean value of lateral inclination of the mandibular fossa being about 20°. Therefore, whilst a variation of less than about 2° could result in a statistically significant difference, such a small difference may not be clinically significant.

LA and RA were steeper in males than in females. Cohlma et al. [3] also found that the anterior inclinations of the mandibular fossa on the right and left sides were steeper in males than in females. However, they measured the inclinations of the mandibular fossa in a Caucasian population using tomography, in contrast to the use of CT in the present study. However, some researchers have indicated that the inclinations of the mandibular fossa were not affected by gender [8, 18]. One possible reason for this discrepancy is the use of different methodologies: Meng et al. [18] used the inclinations of the mandibular fossa in the middle reformation plane, which is perpendicular to the mandibular fossa-mediolateral dimension, rather than in the sagittal plane containing the top of the mandibular fossa. The LP differed significantly between the males and females, but the significance of this difference was lower for LP (*p*=0.0197) than for LA (*p*<0.0001), and RA (*p*<0.0001). The actual (small) difference between males and females in LP might not be clinically significant (34.1±6.6 for females and 36.4±7.3 for males). Because of small differences might lead to statistical difference, this might be the reason why the actual difference between males and females of LP and RP seem very small, but RP does not display statistical difference as LP between males and females.

The statistical analyses revealed a significant correlation between age and anterior inclinations of the mandibular fossa in the sagittal plane (LA and RA), which is consistent with the results of Angel et al. [9]. However, Wish-Baratz

**Table 2** Comparisons of inclinations of the mandibular fossa with age

Variable	All ( <i>N</i> =198)		Females ( <i>N</i> =95)		Males ( <i>N</i> =103)	
	CORR	<i>p</i> value	CORR	<i>p</i> value	CORR	<i>p</i> value*
LA	0.46	<0.0001	0.51	<0.0001	0.46	<0.0001
LP	-0.04	0.5642	-0.03	0.7402	-0.05	0.6111
LL	-0.24	0.0007	-0.22	0.0359	-0.26	0.0078
LM	0.15	0.0316	0.14	0.1730	0.16	0.0960
RA	0.34	<0.0001	0.36	0.0003	0.34	0.0005
RP	-0.12	0.0982	-0.05	0.6573	-0.19	0.0570
RL	-0.21	0.0028	-0.33	0.0013	-0.10	0.3040
RM	0.12	0.1001	0.04	0.6666	0.18	0.0742

*CORR* Pearson's correlation coefficient between age and inclination

\*Pearson's correlation coefficient test

**Table 3** Comparisons of inclinations of the mandibular fossa on its right and left sides

Variable	Left side		Right side		Difference		<i>p</i> value
	Mean	±SD	Mean	±SD	Mean	±SD	
All ( <i>N</i> =198)							
A	39.3	±8.7	39.2	±8.4	0.13	±6.4	0.7693
P	35.3	±7.1	35.1	±7.6	0.13	±5.9	0.7550
L	19.9	±7.5	19.9	±6.9	-0.01	±6.0	0.9834
M	38.0	±5.9	37.5	±6.1	0.50	±5.2	0.1745
Females ( <i>N</i> =95)							
A	36.8	±7.8	37.0	±7.4	-0.28	±6.6	0.6799
P	34.1	±6.6	34.7	±7.5	-0.60	±5.9	0.3299
L	20.2	±7.8	20.2	±6.9	0.03	±5.1	0.9480
M	38.2	±5.5	37.7	±5.5	0.54	±5.2	0.3129
Males ( <i>N</i> =103)							
A	41.7	±8.9	41.2	±8.7	0.52	±6.2	0.4020
P	36.4	±7.3	35.6	±7.6	0.80	±5.9	0.1695
L	19.6	±7.2	19.7	±7.0	-0.05	±6.8	0.9419
M	37.7	±6.4	37.3	±6.7	0.47	±5.2	0.3648

*A* anterior inclinations of the mandibular fossa on both sides;  
*P* posterior inclinations of the mandibular fossa on both sides;  
*M* medial inclinations of the mandibular fossa on both sides;  
*L* lateral inclinations of the mandibular fossa on both sides  
 \*paired *t* test between right and left sides

et al. [11] reported no age-related differences in the angles of the articular tubercle. Nevertheless, Moffett et al. [10] reported that the inclination of the posterior slope of the articular tubercle (equal to the anterior inclination of the mandibular fossa as used in this study) would decrease due to attrition and bone remodeling of the condyle process and mandibular fossa. The positive correlation between age and anterior inclination found in this study might be due to a physiological mechanism inducing the convergence of the incisal guidance and condylar guidance. Dawson et al. [23] indicated that in normal occlusion in humans the inclination of the incisal guidance is steeper than that of the condylar guidance; the condyles should rotate around their transverse axis to compensate for this angular difference during mandibular protrusion movement. This difference could be harmonized by a physiological mechanism that

decreases the inclination of the incisal guidance or increases the inclination of the condylar guidance. Moreover, the inclination of the incisal guidance decreases with aging due to attrition, while that of the condylar guidance increases due to deepening of the mandibular fossa by bone remodeling.

We found no significant differences in the inclinations of the mandibular fossa between its right and left sides. This finding contradicts those of previous researches [3, 11, 12]. Cohlmiä et al. [3] found that the posterior inclination of the articular tubercle was steeper on the left side than on the right side. This might be due to them using superior border of the tomographic film as the reference plane, and not the FH plane as used in the present study. In addition, Jasinevicius et al. [12] and Wish-Baratz et al. [11] reported that the posterior inclination of the articular tubercle was

**Table 4** Comparisons of inclinations of the mandibular fossa found in previous studies and the present study

	Seward (1976) [8]	Cohlmiä et al. (1996) [3]	Bilgin et al. (2000) [21]	Jasinevicius et al. (2005) [12]	Gilboa et al. (2008) [13]	This study
Ethnicity	Australian aborigine	Caucasian	Anatolian	Negroes/ Caucasian (American)	NA	Mongolian (Taiwanese)
Sample type	Cadaver	Tomogram	Cadaver	Cadaver	Panorex	CT
Reference plane	FH plane	Superior border in tomography	FH plane	FH plane	FH plane	FH plane
Measurement approach	Circle template	NA	Gradient of inflection point	NA	Top of mandibular fossa and bottom of articular tubercle	Line through reference points

NA not available

steeper on the right side than on the left side. These discrepancies might be due to the use of different methods by the previous researches and the current study, or to ethnicity differences.

The findings of the present study for the inclinations of the mandibular fossa are both consistent and inconsistent with those of previous studies [3, 8–13, 18, 24]. The main reasons could be the inclusion of subjects with different ethnicities and the evaluation approaches applied. Most of the studies cited above were based on cadaver measurements, but various evaluation approaches were applied. Moreover, our use of CT measurement allows full evaluations and measurements of bony structures in living samples. In addition, the samples were larger in the present study.

When the patient receives a dental prosthesis, an inharmonious occlusion may evoke clinical symptoms such as headache, TMJ disorders, or muscular pain. One of the goals of prosthetic dentistry is to restore missing oral structures and establish an optimum occlusion. A fundamental requirement is for the prosthesis to be consistent with mandibular movement. The facebow transfer and intraoral or extraoral records can facilitate occlusal adjustment of prosthesis. The jaw relationship and facebow transfer are especially important in patients needing full-mouth rehabilitation, and the clinical adjustments required in such cases take more time. Moreover, the setting of condylar guidance angles in commercially available semi-adjustable articulators is not based on scientific data. Therefore, the data obtained in this study could be used to establish a scientific database for further setting the condylar guidance.

The inclinations of the mandibular fossa as reported in the literature and found in the present study are compared in Table 4. The study of Cohlmaia et al. [3] used the superior border of the tomographic film as the reference plane to measure the inclination of the mandibular fossa, whereas all of the other previous studies [8, 12, 13, 21] selected the FH plane as the reference plane. Three of the previous studies directly assessed cadavers, another study used panoramic radiographic images of cadavers, while the fifth study used tomographic images to evaluate the inclination of the mandibular fossa. Each study used its own definition when measuring inclinations of the mandibular fossa. For example, Seward [8] used a template of the best-fit circle to determinate the inclination, Bilgin et al. [21] used the gradient of the reflection point on the anterior slope of the mandibular fossa to represent its inclination, and Gilboa et al. [13] used the line crossing the top of the mandibular fossa and the bottom of the articular tubercle. We were interested in determining how the morphology of the mandibular fossa varied with ethnicity, but this was not possible due to the nonavailability of raw data from the previous studies.

This study was subject to some limitations. First, the aim of this study was to determine the inclinations of the mandibular fossa in an Asian population, and hence, care is required when applying the statistical results in other ethnicities. Second, although almost 200 subjects were included, which is many more than in the previous cadaver-based studies, larger samples might be needed to accurately represent the entire Asian population, especially in younger and older subjects (e.g., younger than 20 years and older than 70 years). Third, the use of CT imaging, as well as cadaver-based studies in the literature, only provides information on the geometry of bony structures. Factors related to the dynamic function of mandible, such as mastication and chewing cannot be evaluated by a CT approach. More data are needed to confirm the correlation between the anatomy of the mandibular fossa and functional movement. Therefore, care is required when attempting to apply the experimental data obtained in this study to the setting of the articulator.

## Conclusion

CT is a useful tool for noninvasively evaluating the spatial characteristics of bony structures. According to the scientific data obtained in this study, the investigated parameters mainly affected the anterior inclination of the mandibular fossa. The anterior inclination of the mandibular fossa was steeper in males than in females, and it increased significantly with aging. In addition, there was symmetry of the inclinations of the mandibular fossa on its right and left sides. The data obtained in this study could be used to establish a scientific database for further clinical applications.

**Acknowledgments** This research was supported by National Science Council, Taiwan (Grant numbers: NSC 97-2314-B-039 -024 -MY3 and NSC 96-2815-C-039-041-B). The authors thank Professors Che-Shoa Chang, Yuh-Yuan Shiau, Heng-Li Huang, Chun-Pin Lin, and Chun-Cheng Hung for their suggestions in this study. The authors also wish to thank Li-Na Liao from Biostatistics Center and Department of Public Health, China Medical University for her assistance of statistical analysis.

**Conflict of interest** No authors of this study have any financial and personal relationships with other people or organizations, which could result in an inappropriate influence of this study.

## References

- Okeson JP (2008) Management of temporomandibular disorders and occlusion. Mosby Elsevier, St. Louis
- Badel T, Marotti M, Keros J, Kern J, Krolo I (2009) Magnetic resonance imaging study on temporomandibular joint morphology. *Coll Antropol* 33:455–460

3. Cohlmia JT, Ghosh J, Sinha PK, Nanda RS, Currier GF (1996) Tomographic assessment of temporomandibular joints in patients with malocclusion. *Angle Orthod* 66:27–35
4. Ogawa T, Koyano K, Suetsugu T (1998) Correlation between inclination of occlusal plane and masticatory movement. *J Dent* 26:105–112
5. Kerstens HC, Tuinzing DB, Golding RP, Van der Kwast WA (1989) Inclination of the temporomandibular joint eminence and anterior disc displacement. *Int J Oral Maxillofac Surg* 18:228–232
6. Al-Jabrah OA, Al-Shumailan YR (2006) Prevalence of temporomandibular disorder signs in patients with complete versus partial dentures. *Clin Oral Investig* 10:167–173
7. Casanova-Rosado JF, Medina-Solis CE, Vallejos-Sanchez AA, Casanova-Rosado AJ, Hernandez-Prado B, Avila-Burgos L (2006) Prevalence and associated factors for temporomandibular disorders in a group of Mexican adolescents and youth adults. *Clin Oral Investig* 10:42–49
8. Seward FS (1976) Tooth attrition and the temporomandibular joint. *Angle Orthod* 46:162–170
9. Angel JL (1948) Factors in temporomandibular joint form. *Am J Anat* 83:223–246
10. Moffett BC Jr, Johnson LC, McCabe JB, Askew HC (1964) Articular remodeling in the adult human temporomandibular joint. *Am J Anat* 115:119–141
11. Wish-Baratz S, Hershkovitz I, Arensburg B, Latimer B, Jellema LM (1996) Size and location of the human temporomandibular joint. *Am J Phys Anthropol* 101:387–400
12. Jasinevicius TR, Pyle MA, Lalumandier JA, Nelson S, Kohrs KJ, Sawyer DR (2005) The angle of the articular eminence in modern dentate African-Americans and European-Americans. *Cranio* 23:249–256
13. Gilboa I, Cardash HS, Kaffe I, Gross MD (2008) Condylar guidance: correlation between articular morphology and panoramic radiographic images in dry human skulls. *J Prosthet Dent* 99:477–482
14. Clark JR, Evans RD (2001) Functional occlusion: I. A review. *J Orthod* 28:76–81
15. Bisler A, Bockholt U, Kordass B, Suchan M, Voss G (2002) The virtual articulator. *Int J Comput Dent* 5:101–106
16. Kordass B, Gartner C, Sohnel A, Bisler A, Voss G, Bockholt U, Seipel S (2002) The virtual articulator in dentistry: concept and development. *Dent Clin North Am* 46:493–506, vi
17. Gartner C, Kordass B (2003) The virtual articulator: development and evaluation. *Int J Comput Dent* 6:11–24
18. Meng F, Liu Y, Hu K, Zhao Y, Kong L, Zhou S (2008) A comparative study of the skeletal morphology of the temporomandibular joint of children and adults. *J Postgrad Med* 54:191–194
19. Ingervall B (1972) Range of sagittal movement of the mandibular condyles and inclination of the condyle path in children and adults. *Acta Odontol Scand* 30:67–87
20. Ichikawa W, Laskin DM (1989) Anatomic study of the angulation of the lateral and midpoint inclined planes of the articular eminence. *Cranio* 7:22–26
21. Bilgin T, Sulun T, Ergin U, Kursoglu P, Beyli M, von Fraunhofer JA (2000) Evaluation of the slope of the articular eminence and the transverse angle of the glenoid fossa in an Anatolian population. *Cranio* 18:220–227
22. Hsu JT, Chang CH, Huang HL, Zobitz ME, Chen WP, Lai KA, An KN (2007) The number of screws, bone quality, and friction coefficient affect acetabular cup stability. *Med Eng Phys* 29:1089–1095
23. Dawson P (2007) *Functional occlusion: from TMJ to smile design*. Mosby Elsevier, St. Louis
24. Ricketts RM (1950) Variations of the temporomandibular joint as revealed by cephalometric laminagraphy. *Am J Orthod* 36:877–898