

## Deep brain stimulation for movement disorders. Considerations on 276 consecutive patients

Angelo Franzini · Roberto Cordella · Giuseppe Messina · Carlo Efsio Marras · Luigi Michele Romito · Francesco Carella · Alberto Albanese · Michele Rizzi · Nardo Nardocci · Giovanna Zorzi · Edvin Zekay · Giovanni Broggi

Received: 16 November 2010 / Accepted: 5 May 2011 / Published online: 20 May 2011  
© Springer-Verlag 2011

**Abstract** The links between Stn DBS and advanced Parkinson disease, and between GPi DBS and dystonia are nearly universally accepted by the neurologists and neurosurgeons. Nevertheless, in some conditions, targets such as the ventral thalamus and the Zona Incerta may be considered to optimize the results and avoid the side effects. Positive and negative aspects of current DBS treatments justify the research of new targets, new stimulation programs and new hardware. Since 1993, at the Istituto Nazionale Neurologico “Carlo Besta” in Milan, 580 deep brain electrodes were implanted in 332 patients. 276 patients were affected by movement disorders. The DBS targets included Stn, GPi, Voa, Vop, Vim, CM–pf, cZi, IC. The long-term follow-up is reported and related to the chosen target. DBS gave a new therapeutic option to patients affected by severe movement disorders, and in some cases resolved life-threatening pathological conditions that would otherwise result in the death of the patient, such as in status dystonicus, and post-stroke hemiballismus. Nevertheless, the potential occurrence of severe

complications still limit a wider use of DBS. At today, the use of DBS in severe movement disorders is strongly positive even if further investigations and studies are needed to unveil potential new applications, and to refine the selection criteria for the actual indications and targets. The experience of different targets may be useful to guide and tailor the target choice to the individual clinical condition.

**Keywords** Deep brain stimulation · Movement disorders

### Introduction

Deep brain stimulation (DBS) allows in interacting with the nervous system networks known to be distorted in specific movement disorders, such as Parkinson’s disease (PD), dystonic syndromes and essential tremor. We report the experience of the National Neurological Institute “C. Besta” in 270 consecutive patients, operated on along 10 years, affected by severe movement disorders refractory to conservative treatments. Our results and considerations are described “target by target” to underline the concept that single “anatomical” target that has showed to be successful in the control of movement disorders, might be functionally involved in the physiopathology of different neurological diseases, i.e. the Zona Incerta has been successfully targeted for PD, essential tremor (ET) and also for refractory partial motor epilepsy. Furthermore, this review suggests how in the future the choice of DBS targets might be more patient-oriented, thus tailored on the specific clinical features of the disease. The reported experiences, include DBS of the subthalamic nucleus (Stn), globus pallidus pars interna (GPi), ventral thalamic nuclei (Voa/Vop/Vim/), caudal zona incerta (cZi), and preliminary data on the stimulation of the posterior limb of the internal

A. Franzini · R. Cordella (✉) · G. Messina · C. E. Marras · M. Rizzi · E. Zekay · G. Broggi  
Department of Neurosurgery, Fondazione IRCCS Istituto Neurologico “C. Besta”, Via Celoria 11, 20133 Milan, Italy  
e-mail: rcordella@istituto-besta.it

L. M. Romito · F. Carella · A. Albanese  
Department of Neurology, Fondazione IRCCS Istituto Neurologico “C. Besta”, Via Celoria 11, 20133 Milan, Italy

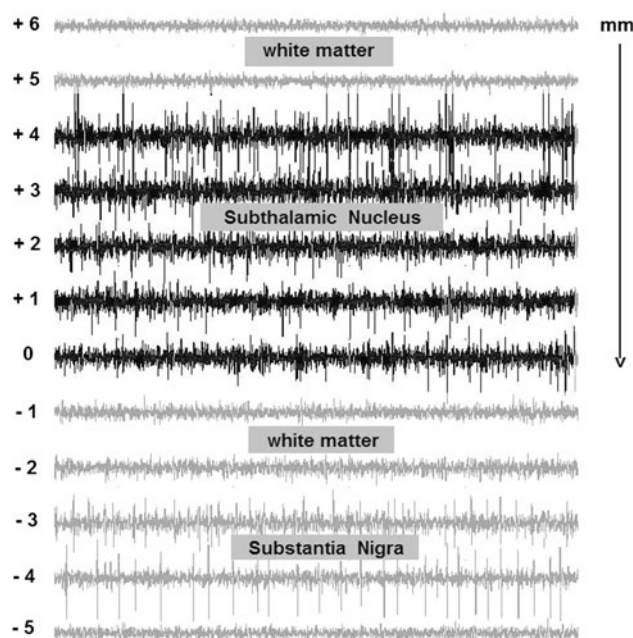
N. Nardocci · G. Zorzi  
Department of Child Neurology, Fondazione IRCCS Istituto Neurologico “C. Besta”, Via Celoria 11, 20133 Milan, Italy

L. M. Romito · A. Albanese  
Università Cattolica di Milano, Largo Gemelli 1,  
20100 Milan, Italy

capsula (IC) and the centrum medianum parafacicularis complex (CM–pf).

### Surgical methodology

Surgery is performed either in awake patients under local anesthesia, or in general anesthetized when poor cooperation is expected (as in children). DBS procedures are always performed under stereotactic conditions with the Leksell (Elekta Inc., Atlanta GA, USA), CRW (Radionics, Burlington, MA, USA) and Micromar (Micromar Inc., Sao Paulo, Brazil) frames. Computerized tomography (CT) is our radiological examination of choice to recognize the anterior and posterior commissures in the stereotactic space after positioning of the headframe. A probabilistic stereotactic digitalized atlas registered to the anterior commissure (AC)–posterior commissure (PC) line is utilized for the preliminary determination of the target coordinates. The stereotactic CT images are then merged with the preoperative magnetic resonance images (MR; T1 and fast spin-echo inversion recovery sequences with double dose of contrast agent) and a second computation of the target coordinates is performed with the neuronavigation system (Stealth Station Treon SofamorDanek, Medtronic Inc. Minneapolis, MN, USA) analyzing the merged images registered to the mid-commissural point. Finally, the two sets of data are matched, and the definitive coordinates, along with the planned trajectory, are adapted to the individual patient anatomy. A rigid cannula is then inserted through a small hand drilled burr hole (5-mm diameter) and through the opened dura mater; the cannula is then indwelled till 15 mm above the estimated target. A high impedance microelectrode (250  $\mu\text{m}$  tip, and impedance 1–1.5 M $\Omega$ ; FHC Inc., Bowdoinham ME, USA) is then introduced within the cannula and advanced progressively to the target. Microrecording trajectories are performed with 0.5–1 mm steps, and 1–5 mm beyond the target along the single planned trajectory (Fig. 1). If microrecordings fulfil the localizing criteria, the definitive electrode (Medtronic Inc. Minneapolis, MN, USA; St. Jude Inc., St. Paul MN, USA) is placed at the target through the same rigid cannula after the microelectrode withdrawal. Macrostimulation through the definitive electrode is then performed in bipolar configuration between the two proximal contacts and between the two distal contacts. At this stage of the procedure, clinical evaluations of the awake patient and electromyographic (EMG) recordings in the anaesthetized patient allow to search for positive clinical response and/or for the emergence of side effects. If microrecordings and macrostimulation imply the accuracy of the estimated target, the electrode is secured to the burr hole with biological glue (Cryolife Inc., Kennesaw GA, USA), and a titanium



**Fig. 1** Raw electrophysiological traces recorded during the placement of the DBS leads in the Stn of a PD patient. On the left is reported the distance of the high impedance microelectrode to the stereotactic target (0). From 6 to 4 mm above, the target there were no action potentials meaning that the microelectrode is crossing the white matter. From 4, till the target, it is possible to notice an increase in the background noise and the appearance of the high frequency and randomly distributed action potentials. These are typical electrophysiological features of the Stn neurons in PD patients. Below the target, the microelectrode is out of the Stn and within the white matter. Indeed, no action potentials were recorded. At 3-mm below the target, it has been recorded a high-frequency discharge rate and a regular pattern, which is typical of the substantia nigra *pars reticulata* (SNr) neurons

microplate. The free distal plug of the electrode is then leaved beneath the galea ready for the connection to the extension lead and internal pulse generation (IPG). On the other hand, when microrecordings, and/or clinical evaluation, and EMG monitoring suggest a suboptimal electrode placement, a new trajectory is planned trough the same burr hole. It has to be remarked that about 70% of our procedures have required 1 trajectory per side, 20% required two trajectories and only 10% required three or more trajectories.

### DBS targets

#### Subthalamic nucleus

In the past three decades, the introduction of chronic high-frequency DBS of different targets (Bechtereva et al. 1975; Kringelbach et al. 2007), mainly the ventro-intermediate nucleus of thalamus (Vim) (Benabid et al. 1987), the globus pallidus internus (GPi) (Siegfried and Lippitz 1994)

and the subthalamic nucleus (Stn) (Benazzouz et al. 1993; Benabid et al. 1994), has injected a great deal of excitement into the scientific community with regard to the treatment of severe Parkinson's disease (PD), obtaining major results and potential new insights into pathophysiological mechanism of the disease. Currently, high-frequency Stn DBS is considered the preferred surgical method to treat PD patient as it has effectively provided significant improvement of the motor conditions of patients with motor fluctuations and dyskinesias, and has allowed to reduce antiparkinsonian medication (Anderson et al. 2005; Benabid et al. 2009; Limousin and Martinez-Torres 2008). At today, the decision in favor of the Stn or the GPi is still far from be clear. Interestingly, both GPi and Stn DBS resulted effective in improving PD symptoms after 12 months of stimulation. Stn DBS appeared to be more effective than GPi in improving bradykinesia, and in the reduction of the levodopa dosages. On the other hand, both Stn and GPi stimulation improved dyskinesia, although the latter induced higher improvements (Anderson et al. 2005). Several papers have been published about the 3–4 years postoperative follow-up of the implant of this target (Kleiner-Fisman et al. 2003; Pahwa et al. 2005; Rodriguez-Oroz et al. 2005; Romito et al. 2002; Visser-Vandewalle et al. 2005; Zibetti et al. 2008), while there is still a paucity of data at long term, in particular at five (Krack et al. 2003; Romito et al. 2009; Schupbach et al. 2005; Simonin et al. 2009; Wider et al. 2008) and 8 years (Fasano et al. 2010) after Stn implant. More recently, there are a few reports supporting the role of Stn DBS in treating primary, tardive (Sun et al. 2007), and cervical dystonia patients (Kleiner-Fisman et al. 2007; Ostrem et al. 2011).

#### Operated series and results (1999–2010)

In our Institute, since 1999, 138 patients (73 males and 45 females) with PD underwent bilateral stereotactic guided Stn implants (Table 1), and received continuous stimulation for the subsequent years. Long-term follow-up is available in 118 patients, whose had a diagnosis of PD according to the UK Parkinson's disease Brain Bank criteria (Hughes et al. 1992) and fulfilled the recommendations of the CAPSIT-PD panel (Defer et al. 1999). The patients had a mean ( $\pm$ SD) age at PD onset of 44.3 ( $\pm$ 8.0) years, an age at implant of 56.5 ( $\pm$ 7.5) years with disease duration of 12.6 ( $\pm$ 7.2) years and a mean levodopa response of 60.1%. Main outcome measures of this study were the (1) motor efficacy of Stn stimulation, defined as the UPDRS motor score variation between the preoperative condition without medication and the condition with stimulation on, but without medication and the (2) combined motor efficacy of stimulation and medication, defined by the variation of the UPDRS motor score between the preoperative score without medication and the postoperative score with stimulation turned on and with medication. UPDRS dyskinesia score and duration of motor fluctuations and levodopa equivalent daily dosage (LEDD) (measured in mg) were computed for each patient. At last follow-up (FU) (mean  $41.4 \pm 33.1$  months), the motor efficacy of Stn stimulation was 56.4% ( $p < 0.001$ ) and the combined motor efficacy of stimulation and medication was 65.3% ( $p < 0.001$ ). The motor efficacy of Stn stimulation was not evenly distributed: rest tremor had the most remarkable changes, followed by rigidity, gait, lower limb akinesia, upper limb akinesia, gait and postural

**Table 1** DBS targets and movement disorders

Targets	Tot patients	Indications	Coordinates related to the AC–PC midpoint
Stn	138	Parkinson's disease	$X = \pm 12; Y = -4; Z = -4;$
GPi	76	62 Dystonias (5 dystonic storm) 1 Tourette's syndrome 13 Parkinson's disease	$X = \pm 19; Y = 2; Z = -6$
Vim\Voa\Vop	35	18 Essential tremor 7 MS tremor 9 Post-traumatic tremor 1 Hemiballismus	$X = \pm 14; Y = -1; Z = 0$
cZi/RARPL	23	23 Parkinson's disease	$X = \pm 12; Y = -7; Z = -4$ $X = \pm 10; Y = -5; Z = -3$
IC	2	1 Post-stroke fixed dystonia 1 Post-stroke spasticity	$X = \pm 17; Y = -7; Z = + 2$
CM–pf	2	2 Parkinson's disease	$X = \pm 8/10; Y = -12/14; Z = 0$
Tot	276		

dysfunctions; speech item was not improved. Dyskinesias were improved in all the patients after implant. The duration and severity of motor fluctuation, the severity of off-period dystonia were markedly reduced in all the patients during the period of observation. The mean preoperative LEDD ( $961.3 \pm 519.2$ ) was greatly reduced during the first 6 months after implant and stabilized at values around 62% ( $p < 0.001$ ) of the pre-implant dose at last follow-up. Ten patients were without dopaminergic medication after implant, 14 patients took only dopamine agonists and 3 were only on controlled release levodopa preparations. Surgical adverse events were reported in a minority of the patients. Two patients had a brain hematoma with hemiplegia; a patient presented an unexplained fracture of the extracranial portion of the lead and underwent successful re-implant; two patients had monolateral stimulation system removal due to infection. The stimulation side effects were present in 29% of patients: hypophonia occurred in 17 patients; dysarthria was present in 11 patients. All the patients gained weight after surgery; the patients' weight averaged  $62.4 \pm 11.6$  kg before surgery and increased by 11.4% to  $69.5 \pm 12.8$  kg at the time of last follow-up ( $p = 0.001$ ). Weight gain was remarked as unacceptable by about 10% of patients. In addition in the presented series were reported no cardiovascular events. Overall, these data indicate that chronic Stn DBS is efficacious in controlling levodopa-responsive parkinsonian symptoms and allows to maintain a long-lasting reduction in dopaminergic treatment. The safety profile is positive.

#### Globus pallidus pars interna

In the 1930s, Russel Meyers performed, via craniotomy, selected basal ganglia lesions for the treatment of movement disorders, including the globus pallidus (Bakay 2008). After these experiences, burdened by high-mortality rate, in the 1950s Wycis and Spiegel (1950) used a stereotactic system to perform selective pallidal lesions for the treatment of PD. In the next decades, the attention shifted from the pallidum to the thalamic targets, which lesions allowed a better tremor control, although the side effects, such as dysarthria and ataxia were common, particularly when lesions were bilateral. In the early 1990s Laitinen, recovering the studies of his mentor Leksell (Svennilson et al. 1960), showed encouraging results in the treatment of PD, through the lesions of the posteroventrolateral part of the globus pallidus internus (GPi) (Laitinen et al. 1992). In those years, the group of Grenoble gave a pivotal contribution to the worldwide diffusion of DBS by defining the target and parameters of stimulation for the treatment of PD (Pollak et al. 1993). In the following years, Siegfried and Wellis (1997) treated a Parkinsonian patient with bilateral GPi stimulation. The authors used the target

defined by Leksell and Laitinen, which has showed satisfactory long-term results. Only in the late 1990s, several other groups started to stimulate GPi for the treatment of dystonia (Coubes et al. 1999). Krauss et al. (1999), followed by Coubes et al. (2000), reported the first series of patients. In 2000, our group suggested that also dystonic storm could be successfully treated by GPi-DBS, with the resolution of the life-threatening situation (Angelini et al. 2000). In the past decade, GPi has been assessed as the best therapeutic stimulation target for severe forms of dystonia in both adults (Kupsch et al. 2006; Mueller et al. 2008; Vidailhet et al. 2005), and in pediatric population, as also underlined by our group (Zorzi et al. 2005). Globus pallidus internus plays a relevant role in the motor output from basal ganglia to the cortex in the context of the basal ganglia-thalamo-cortical loops. The GPi portion where sensorimotor neurons are located, and from which ansa lenticularis emerges to reach the motor thalamus, is the ventroposterolateral portion. Although there is a little variety in the stereotactic coordinates, most frequently the tip of the electrodes, as suggested by Laitinen et al. (1992), is located 3–6 mm under the intercommissural plane, 2–3 mm anteriorly the mid-commissural point and 20–22 mm lateral to midline. To avoid side effects related to the proximity of internal capsule, many authors prefer to set the coordinates more laterally, while optic tract involvement is prevented by a more dorsal positioning. Intraoperative microrecording and macrostimulation allow to verify the best functional electrodes location in relation to the possible side effects.

#### Operated patients and results (1999–2010)

Out of 62 dystonic patients submitted to Gpi-DBS (Table 1), a total of 47 patients are available for follow-up (26 adults and 21 with age lower than 18 years) with different types of dystonia, diagnosed according to the Fahn's criteria (Fahn et al. 1998). All of them had bilateral GPi electrode implantation. Neurologists followed adult patients, belonging to the Group 1, while pediatric neurologists treated the pediatric-adolescent group (Group 2). Preoperative clinical evaluation included in all patients assessment of dystonia with videotape recordings and the administration of the Burke Fahn Marsden Dystonia Rating Severity score (BFMDRS). After surgery, all the patients were evaluated every month, and the clinical status was assessed through videotape recordings and the BMFDRS. The overall mean follow-up is 50 months. In the Group 1, the mean age of dystonia onset was 12.9 years (range 0.5–63 years), and the mean age at time of surgery was 33.7 years (range 18–68 years); the higher age at onset of dystonia (a case of Meige syndrome) was 68 years. Fifteen patients were affected by a primary form of dystonia (10


generalized and 5 segmental), while 11 patients were affected by generalized secondary dystonia. In Group 2, the mean age of disease onset was 4.9 years (range 0.5–15 years), and the mean age at the time of surgery was 12.2 years (range 4–24 years). All the patients had a generalized dystonia, 17 patients suffered from a primary form, while 4 from a secondary one. Five patients developed during the course of the disease a status dystonicus. Four of them had a primary dystonia and the remaining had a secondary form. All but two patients affected by neuroleptics induced dystonia (tardive dystonia) did not improve immediately after surgery; the response was delayed and appeared after a time ranging between 1 week and 6 months (Fig. 2). Clinical improvements were recorded in the first month in 70% of cases. However, in whole responders, patients (pediatric and adult patients) were observed within the first year. According to the BFMDRS scores, in the adults the mean improvement was 40.2% (ranging between 7.7 and 94%), with a better outcome for patients with primary dystonia (45.2 vs. 33.3 in the patient affected by the secondary form); the two cases with the neuroleptic-induced form showed an amelioration of 42 and 80% (Table 2). Our experience in these patients showed a short time lapse (72 h) between the delivery of electrical current to GPi and the maximal beneficial effect (Franzini et al. 2005a). The patient affected by Meige's syndrome gained a benefit of 94%, after 36 months of follow-up. In the childhood onset dystonia, the postoperative BMFDRS score (Table 3) resulted in a mean improvement of 42.1% (ranging between 0 and 92.9%): in the primary form was noticed a better amelioration (43.1 vs. 37.5% in the secondary dystonia). The patients affected by a primary form, with the genetic mutation DYT1+ (3 in the Group 1 and 2 in the Group 2), had a mean improvement of 63.8% (range 43.1–92%). In addition, it has been noticed that patients with mobile forms had a superior response to high-frequency stimulation of the GPi, axial dystonic postures and movement responded to a greater extent compared to oromandibular dystonia, fixed dystonic postures or task specific dystonia such as writing dystonia; moreover, a better outcome could be reached in cases with short disease duration; for this reason, we strongly recommend an early surgery to avoid muscle retraction and skeletal deformities. On the other hand, in the 20% of patients of the Group 2, we reported a long-term efficacy reduction, despite an optimal regulation of the stimulation parameters. Furthermore, in one pediatric patient suffering from a severe form of secondary dystonia, who was successfully treated by GPi-DBS 2 years before, the stimulation device on the right side became infected because of the skin erosion of the head along the path of the connector. When considering the risk of relapse of erosion, because of the thinness of the patient, a right pallidotomy was then

performed by the DBS electrode, before its subsequent, definitive removal. A long-lasting stable control of dystonia was observed, and 9 months after the lesioning procedure, with the left DBS electrode still active, the BFMDRS was the same as that recorded with bilateral stimulation (Marras et al. 2009). We observed a higher incidence of complications in dystonic patients versus PD patients—hardware-related: migration of the electrode in four cases; breaking of the electrodes in two cases. One patient had dislodgement of the left electrode to a position close to the left amygdala: he developed behavioral changes consisting on depression, psychotic symptoms and heightened pain perception (Piacentini et al. 2008); related to the surgical procedure: infection in five cases; intracranial hemorrhage in one case. In one case, dysarthria and dysphagia were related to the bilateral stimulation and recovered activating only one electrode. All the complications, other than haemorrhage, were successfully managed. Our series showed that GPi-DBS is a safe and effective therapeutic option in the treatment of severe, and also life-threatening, forms of dystonia. The large variability in results suggests a major role of careful preoperative selection of the patients. Finally, it has to be remarked that worst results have been obtained in 11 patients affected by dystonia due to cerebral palsy. One more patient (a female aged 28 years at implant) with a drug refractory Tourette's syndrome, underwent bilateral GPi implant: the postoperative improvement of the Yale Global Tic Severity Scale (YGTSS) was of 75% and this result was maintained stable up to the last follow-up at 4 years. Bilateral GPi DBS has been also utilized in 13 PD patients in which levodopa-induced dyskinesias were the prominent symptoms. In all cases, DBS achieved the disappearance or the marked reduction in dyskinesias. The reduction in drug dosage ranged between 20 and 40%, maintaining satisfying control of the disease. None of these patients presented speech problems, but two patients after 4 years of chronic stimulation developed severe akinesia resistant to levodopa therapy.

#### Thalamic ventral nuclear complex (Voa\Vop\Vim)

The ventrolateral thalamus was targeted for PD symptoms by Hassler for the first time in 1952. Subsequently in 1967, Cooper did the same in the treatment of multiple sclerosis (MS) tremor. Autopsies of the patients submitted to lesions have suggested the involvement in the origin of tremor of the ventralis oralis posterior (Vop) and ventralis intermedius (Vim) nuclei (Parrent 1998). Also Hassler et al. found that also high-frequency stimulation of the Vim nucleus of the thalamus dramatically reduced tremor (Hassler et al. 1960). The first series of patients with parkinsonian tremor treated with Vim DBS have been reported in the late

**Fig. 2** Patient included in our series affected by segmental cervical and right upper limb dystonia submitted to GPi DBS at our Institute. *Upper right* Preoperative condition. *Upper left* 3 months after GPi DBS; *lower left* three-dimensional stereotactic atlas referred to the AC–PC line and plane. *Lower right* 6 months after GPi DBS



**Table 2** Mean pre/post-op BFMDRS scores in adults dystonias

	Mean pre-op score BFMDRS	Mean post-op score BFMDRS (mean follow-up 4 years)	Pre-op/post-op mean (%) BFMDRS improvement
Overall	60.3	37.1	23.2 (40.2)
Generalized primary dystonia	58.0	35.5	22.5 (40.5)
Segmental primary dystonia	35.0	12.4	22.6 (54.8)
Primary dystonia DYT1+	50.7	16.7	34.0 (63.9)
Primary dystonia	50.4	27.8	22.6 (45.2)
Neuroleptics induced dystonia	53.0	18.25	34.75 (65.6)
Secondary dystonia	73.8	49.8	24.0 (33.3)

**Table 3** Mean pre/post-op BFMDRS scores in child dystonias

	Mean pre-op score BFMDRS	Mean post-op score BFMDRS (mean follow-up 4 years)	Pre-op/post-op mean (%) BFMDRS improvement
Overall	70.9	44.3	26.1 (42.1)
Generalized primary dystonia DYT1+	45.5	14	26.5 (63.8)
Generalized primary dystonia DYT1–	73.0	46.9	26.1 (40.4)
Primary dystonia	69.8	43.0	26.2 (43.1)
Secondary dystonia <sup>a</sup>	75.5	49.6	25.9 (37.5)

<sup>a</sup> Cerebral palsy patients are included in this group

nineties (Benabid et al. 1989). In the following years, the number of reports dealing with the efficacy of chronic high-frequency Vim DBS increased consistently, also including post-traumatic tremor (Broggi et al. 1993; Koller et al. 1997, 2001; Limousin et al. 1999; Schuurman et al. 2000). The Vim nucleus has also been reported as a successful target for DBS in tremor associated with

phenylketonuria, mercury poisoning and genetic syndromes (Geny et al. 1996; Kudo et al. 2001; Nikkiah et al. 2004; Payne et al. 2005; Schramm et al. 2005). Bilateral stimulation of Vim has been more helpful than unilateral stimulation in the treatment of head, voice and midline tremor (Benabid et al. 1991; Taha et al. 1999). Despite the efficacy of bilateral Vim stimulation nevertheless, it should

be used cautiously due to potential adverse effects related to stimulation, such as dysarthria, gait, and postural impairment. Although Vim nucleus is an optimal target in essential tremor (ET), in parkinsonian tremor it should not be used as primary target because of poor benefit on bradykinesia and rigidity (Pahwa et al. 2006). To treat tremor in MS patients, many authors have targeted the Vim, instead some others have preferred the Vop suggesting better control of the ataxic component of tremor (Critchley and Richardson 1998). Bittar et al. (2005) have used Vop only in patients with distal tremor. Foote described improvement of symptom in a post-traumatic tremor patient stimulating simultaneously Vim and ventralis oralis anterior (Voa/Vop) through two electrodes implant aimed to interact with the pallido- and cerebellothalamic circuits (Deuschl et al. 2001; Foote and Okun 2005). Broggi et al. (2006) reported good results in 12 patients following Voa-Vop-Zona incerta high-frequency stimulation. Four patients were affected by multiple sclerosis, three by post-traumatic tremor, and five by parkinsonian tremor (Broggi et al. 2006). The Vim nucleus is bordered by the internal capsule laterally, and posterior by the ventralis caudalis (Vc) nucleus. The electrode is typically placed at the anterior border of Vim to ensure that stimulation does not extend caudally to Vc, evoking intolerable paraesthesias. Several authors have reported the optimal coordinates of targeting the Vim nucleus (Benabid et al. 1991; Ondo et al. 1998). The AC-PC plane is the optimal axial plane for the electrode tip ( $Z = 0$  in the commissural coordinates system). The most used  $X$  and  $Y$  coordinates for Vim targeting are 5 mm posterior ( $Y = -5$ ) and 13 mm lateral to the mid-commissural point ( $X = 13$  mm) (Table 1). The optimal lateral coordinate may vary with the degree of brain atrophy and third ventricle dimensions. Somatotopic representation of body segments within the Vim nucleus consists in a more lateral localization of the upper limb and hand ( $x = 12$ – $14$  from the midline), while the inferior limb and the foot are more medially represented ( $x = 10$ – $12$ ). Intraoperative microrecordings and macrostimulation should be performed to identify the upper limb somatotopy in the thalamus to guide the laterality of lead placement.

After targeting, it is important to test the implanted lead with intraoperative stimulation through a temporarily connected external pulse generator. This method allows the confirmation of tremor suppression with high-frequency stimulation, and to calculate the thresholds for stimulation-induced side effects. Parameters of chronic definitive electrical stimulation are 130–180 Hz; 60–90  $\mu$ s; 0.5–3 volts. The most commonly reported stimulation related adverse events are paresthesias, dysarthria, gait disorders, and disequilibrium, although they are frequently viewed as mild and tolerable, or amenable to reprogramming (Benabid et al. 1991; Limousin et al. 1999; Pahwa et al. 2006).

#### Operated patients and results (1993–2010)

34 patients (age 19–78 years) underwent ventral thalamus DBS (Voa, Vop, Vim) to treat drug refractory non-parkinsonian tremor (Table 1). The youngest patient was affected by post-traumatic tremor of the right upper limb, and the older one was affected by essential tremor of the left side of the body. The aetiology of tremor was post-lesional in 9 cases (trauma, ischemia, surgical sequelae), essential tremor (ET) in 18 patients, and in 7 it was associated with multiple sclerosis (MS). 13 patients required bilateral DBS implants for bilateral tremor. The best results despite the age and duration of the disease have been obtained in patients affected by essential tremor prevailing on one side (6 right side, 5 left side): this group includes 11 patients who had 90% tremor reduction or complete tremor disappearance, and all returned to normal life without side effects related to the chronic thalamic stimulation (Table 4). At the time of batteries exhaustion (3–5 years after surgery) tremor was still controlled by stimulation in all cases after the IPG replacement. Contralateral tremor on the untreated side appeared or worsened in all cases, but no contralateral implant was performed. Similar results have been obtained in the control of tremor in patients affected by bilateral essential tremor (6 cases); however, all these patients complained mild to severe speech impairment due to stimulation-induced dysarthria. One of these patients developed

**Table 4** Patients population and clinical out come to Vim DBS

Diagnosis (n)		Clinical out come (mean follow-up 8 years)
Post-traumatic tremor (9)	6 Unilateral	6 Unilateral: improvement <sup>a</sup>
	3 Bilateral	3 Bilateral: improvement with speech impairment
Essential tremor (18)	11 Unilateral	11 Unilateral: improvement
	7 Bilateral	6 Bilateral: improvement with speech impairment 1 Bilateral: poor
MS tremor (7)	4 Unilateral	4 Unilateral: improvement
	3 Bilateral	3 Bilateral: improvement with speech impairment
Post-stroke hemiballismus (1)	Unilateral	Improvement

<sup>a</sup> >50% of tremor reduction

postural imbalance, which disappeared turning off bilaterally the stimulation. Also in post-lesion tremor, the best results have been obtained with unilateral implants (6 cases), while speech impairment has been noticed with bilateral thalamic implants (3 patients). DBS in MS patients allowed to control the tremor, but not to control the associated ataxia that consistently limited the execution of finalistic movements. Dramatic improvement was obtained in extremely severe syndromes (4 cases) characterized by high-amplitude distressing tremor of bilateral limbs and head in completely invalidated patients. In this latter group, it was noticed the disappearance of tremor, but not the restoration of finalistic movements. In addition, bilateral surgery was associated with speech impairment, but all the patients regained calm and relaxed postures. Finally, in one of these patient, surgery was followed by a relapse of the demyelinating disease. The best results with thalamic DBS are expected in unilateral ET despite the age and duration of the disease. Patients should be warned that bilateral surgery may be associated with speech impairment (Table 4). Alternative targets for the treatment of tremor such as the centrum medianum nucleus (CM) of the thalamus and the caudal zona incerta (cZi) have been investigated to reduce speech side effects, and to improve the control of the ataxic component of some invalidating tremor syndromes. However, at today, the efficacy of these two latter targets is still experimental, indeed more data are required. Anyway in patients with medication-resistant invalidating tremor, deep brain stimulation of the ventral nuclear complex of the thalamus (Voa, Vop, Vim) should be considered (Lyons et al. 2003). Vim DBS has been also performed to stop continuous abnormal movements in one patient who developed hemiballismus after a small mesencephalic stroke. Almost 2 years after the insult, there was the onset of high disabling hemiballismus to the contralateral hemisoma with self-mutilation episodes. In addition, the patient had jactitation that was not possible to control, and all the symptoms were refractory to conservative therapy (tetrabenazine and antipsychotics drugs). Owing to his clinical condition, the patient underwent tracheal intubation and deep sedation in the intensive care unit. Vim DBS allowed the withdrawal of the patient from the intensive care unit, and his return to normal life 10 h after the DBS was turned on. At today (8 months follow-up), the DBS is still effective in controlling the tremor.

#### Caudal zona incerta and prelemniscal radiations

Zona incerta (Zi), also described by Forel (1877) as the “region of which nothing certain can be said”, is a thalamus-derived region (Jones 1985) lying medially and laterally along the posterior portion of the subthalamic nucleus (Stn). In the last decades, several studies confirmed

the structural, physiological and functional complexity of this deep brain structure, where a great variety of connections to different sites of the central nervous system have been reported (Mitrofanis 2005; Nicoletti et al. 1995; Roger and Cadusseau 1985; Romanowski et al. 1985). The heterogeneity of Zi suggests its role in different neurological function including visceral activity (Mok and Mogenson 1986), arousal (Shammah-Lagnado et al. 1985), attention (Ficalora and Mize 1989) and both posture and locomotion (Vives and Mogenson 1985). According to the results reported by previous reports (Houdart et al. 1965; Munding 1965; Patel et al. 2003) that showed interesting data after stereotactic lesions of Zi for PD, in recent years, Zi-DBS has been proposed as symptomatic treatment for both bilateral and unilateral PD (Voges et al. 2002; Kitagawa et al. 2005; Plaha et al. 2006, 2008; Velasco et al. 2001). However, at today, the role of cZi DBS remains anecdotic and still need to be experimentally validate. Voges et al. (2002) have noticed that the percentage of motor score improvement in PD patients was correlated to the stimulation energy, the best results were achieved when the active electrode was located onto the fiber tracts close to the Stn. Plaha et al. (2006) reported that stimulation of neighboring dorsal and dorsomedial zones [pallidofugal fibers and rostral Zi (rZi)] allowed a significant therapeutic benefit of parkinsonian symptoms. Consequently, the Bristol group started to treat patients affected by advanced PD candidates to DBS targeting three different, but contiguous, areas: Stn, rZi/pallidofugal fibers and caudal Zi (cZi). Outcomes emphasized that high-frequency stimulation of cZi resulted in greater improvement in contralateral motor performance, including tremor, rigidity and bradykinesia. Also, Herzog et al. (2007) have described three parkinsonian patients treated by Stn DBS, in whose stimulation was not effective in controlling dyskinesias. All the patients improved the dyskinesias following Zi stimulation. Moreover, several authors suggested that Stn stimulation for PD may harbor a certain amount of side effects, including speech impairment, cognitive decline, and behavior disturbance (Benabid et al. 2009; Piasecki and Jefferson 2004; Saint-Cyr et al. 2000). Plaha et al. (2008) suggested that stimulation of cZi permitted a lower incidence of speech deterioration, and supposed a better neuropsychological outcome. Moreover, Velasco et al. (2001) suggested an alternative target to Stn to treat advanced PD. These authors implanted DBS electrodes in the prelemniscal radiations (Raprl) medially to the Stn and very close to the Zi. The surgical methodology to target cZi or Raprl is the same of Stn implants with intraoperative microrecordings and macrostimulation at the target. The definitive electrode implant is posterior to the subthalamic boundaries localized with microrecordings (cZi) and medially to Stn for the Raprl. The target coordinates of cZi related to



the mid-commissural point are  $X = 12$ ,  $Y = -7$ ,  $Z = -4$ , while those for the Raprl are  $X = 10$ ,  $Y = -5$ ,  $Z = -3$  (Table 1).

#### Operated patients and results (2003–2010)

19 patients affected by advanced PD (age 60–72 years) have been selected for stimulation of the cZi and/or the Raprl due to the presence of mild speech impairment and/or behavioral diseases, such as depression and apathia. These patients have been treated with bilateral DBS of the cZi (11 patients), bilateral implants within the Raprl (4 cases) and asymmetric implants (Raprl on one side and cZi on the contralateral side) in four cases. The long-term results at 2–7 years follow-up (mean 4 years) are closely similar to the long-term results obtained with Stn DBS with an incidence of speech impairment of 36% and depression of 18%. No differences between the Raprl and cZi chronic stimulation have been found in our series. In addition, the asymmetrical implants could not prevent speech impairment and behavioral side effects. Anyways, these results suggest that the volume of the target within the so-called subthalamic region actually exceeds the volume of the subthalamic nucleus itself, also including the cZi and the Raprl, which enlarge the target posterior and medially in areas not characterized by the typical multi-units neuronal activity of the Stn cells. The cZi has also been targeted to treat refractory epilepsy originating in the central motor cortex in one patient affected by post-traumatic epilepsy, and in one patient affected by focal motor cortex dysplasia. cZi DBS has also been used to treat partial motor seizures' status epilepticus in one patient affected by Rasmussen encephalitis. The well-documented connections between the Zi and the contralateral motor cortex supported the rationale for this original DBS application (Franzini et al. 2008b). DBS induced up to 85% decrease of the number of seizures in the post-traumatic patient, and 50% seizure rate reduction in the patient affected by cortical dysplasia. In the third patient, cZi DBS allowed the disappearance of the status epilepticus (Franzini et al. 2008b). Finally, it has to be remarked that cZi may be stimulated with the same electrode targeting the caudal portion of Voa–Vop nuclei, if a proper stereotactic trajectory is planned (70° sagittal angle to the commissural plane and 20° coronal angle). Recently, four patients affected by PD with tremor prevailing on one side underwent this procedure with the 3,387 Medtronic electrode (4 stimulating contacts along 12 mm) connected to the Activa PC pulse generator. Complete tremor control has been obtained with activation of the proximal thalamic contacts and with activation of the distal cZi contacts; the Activa PC pulse generator allowed to stimulate both regions with different current intensities and different electric fields and stimulating programs. In

conclusion, these targets might represent a valid option to Stn in the treatment of PD and tremor, and according to our experience, it might be also hypothesized that cZi DBS might be effective to treat motor partial epileptic seizure refractory to drugs and amenable to ablative surgery.

#### Posterior limb of the internal capsule

Adams et al. (1974) were the first to describe pain relief after chronic stimulation of the posterior limb of the internal capsule (IC) in patients with central pain (Fields and Adams 1974; Hosobuchi et al. 1975; Kumar et al. 1997; Levy et al. 1987; Namba et al. 1984, 1985; Turnbull et al. 1980; Young et al. 1985). IC stimulation has also been employed to improve movement disorders, including spasticity due to trauma, tremor of the upper limb, cerebral palsy, and dystonia (Cooper et al. 1980, 1982). In a case described by Irving Cooper in 1980, pain and spasticity, caused by a car accident, were relieved by implanting DBS leads in the pulvinar and in the posterior limb of IC. Other authors reported that electrical stimulation of this latter region in chronic pain patients induced motor responses accompanied by pain relief (Namba et al. 1985). The mechanisms underlying pain relief by IC stimulation are not clear. Unlike the stimulation of the peri-ventricular gray matter (PVG) and periaqueductal gray (PAG), the IC DBS is not correlated with an increase in the endorphin levels (Akil et al. 1978) and should involve a pain inhibiting pathway different from the opiate-mediated system. Experimental models have been employed to identify the neural systems involved in IC stimulation (Nishimoto et al. 1984). In animal models, these authors demonstrated that train of electrical pulses delivered to IC elicited suppression of activity of nociceptive neurons in thalamic sensory nucleus. Furthermore, IC stimulation in cats has been demonstrated to have inhibitory effect on deafferentation hyperactivity in neurons of the spinal trigeminal nucleus (Namba et al. 1984).

#### Operated series and results (2001–2010)

We have implanted DBS leads to stimulate the motor fibers of the posterior limb of the internal capsule, adjacent to the sensory thalamus to treat central pain, spasticity and fixed dystonia of the lower limb. In our opinion, this target represents a valid option in the treatment of pain and spasticity of the lower limb as an alternative to motor cortex stimulation (MCS) recently proposed for post-stroke syndromes involving the upper limb and hand (Franzini et al. 2000, 2003). In fact, IC chronic stimulation may interact with the same sensory-motor neural networks supposed to be involved in the mechanism of action of MCS, but works better when the inferior limb is involved

due to the cortical representation of the lower limbs, which lies in the interhemispheric fissure, thus not an easy target for the placement of epidural electrodes. Stimulation of the posterior limb of the internal capsule (IC) has been employed to treat post-stroke neuropathic pain of the lower limb in two male patients, and in a 31-year-old woman who had post-stroke fixed dystonia of the foot (inward rotation) (Franzini et al. 2008a, 2009). Both patients with post-stroke neuropathic pain reported improvement of the pain from the DBS at long-term follow-up (5 and 2 years, respectively). In one of these, the pain control has been in parallel with an improvement in gait clumsiness and spasticity of the contralateral leg and foot (Franzini et al. 2008a). The last one was affected by a post-stroke-fixed dystonia of the foot, and had a dramatic improvement of focal dystonia 2 days after the implant. At the 24 months follow-up, the clinical benefit of the procedure has continued to be maintained and the patient does not show any neurological signs associated with a stimulation-related side effects. The definitive stereotactic coordinates related to the commissural system midpoint were 17 mm lateral (*X*), 7 mm posterior (*Y*), and 2 mm above the commissural plane (*Z*) (Table 1). The stimulation parameters ranged between 80 and 100 Hz, 60 ms, 1 V. In our experience, IC DBS has been effective to treat pain, spasticity and fixed postures of the inferior limb in post-stroke syndromes, and may be a valid alternative to MCS in selected cases.

#### Centro median–parafascicular complex of the thalamus

After 2 years of the introduction of the functional stereotactic technique by Wycis and Spiegel (1950), Hécaen et al. (1949) performed the first stereotactic lesion of the centro median–parafascicular (CM–pf) complex for the treatment of intractable pain. Leksell et al. (1972) performed radio-surgical lesions within the CM–pf complex to treat chronic and neoplastic pain. More recently, a large number of CM thalamotomies aimed to alleviate intractable nociceptive and neuropathic pain have been reported by Weigel and Krauss (2004). In 1978, CM DBS was proposed for the treatment of drug refractory epileptic seizures not amenable to resective surgery; in particular, Velasco et al. treated a certain number of patients affected by tonic–clonic seizures, atypical absences and Lennox–Gastaut syndromes (Velasco et al. 2007a, b, c, 1995). The rationale for this application was the hypotheses that CM may act as a relay in the non-specific reticulo-thalamo-cortical pathways involved in the generalization of seizures through the modulation of cortical excitability (Albe-Fessard and Besson 1973). CM–pf DBS has been also utilized in the field of movement disorders in the treatment tremor in PD patients as suggested in 1999 by Caparros-Lefebvre et al. (1999) and recently by Mazzone et al. (2006). However, at

today, this target in the treatment of tremor is still under debate and further experimental validation is required. Finally, DBS of the CM–pf complex has been proposed for the treatment of patients affected by Gilles de La Tourette syndrome refractory to conservative therapy (Visser-Vandewalle et al. 2003) This preliminary published data propose that CM–pf might be a valid target to treat this rare, but invalidating disease (Visser-Vandewalle et al. 2003; Servello et al. 2008).

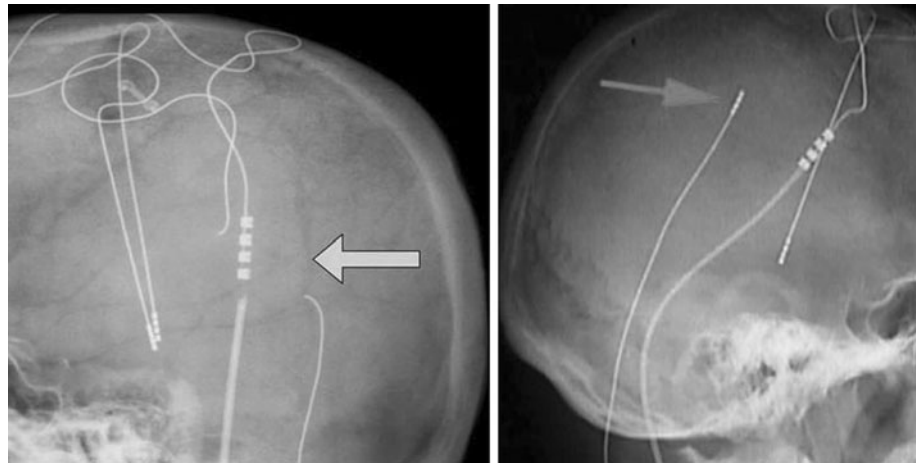
#### Operated patients (1993–2010)

Our experience about CM–Pf DBS is limited regarding the number of treated patients, but includes all the classical indications. Two patients underwent CM DBS for chronic pain with only transitory benefits. Four patients underwent CM DBS for Lennox Gastaut syndromes; in these epileptic patients, the electrodes have been implanted within the more lateral portion of the nucleus as suggested by Velasco et al. (2007b). The authors have proposed that the best stereotactic coordinates for CM are 8–10 mm lateral from the commissural line, the *y* close to the anterior border of the PC, and the *z* at the plane of the AC–PC line (Table 1). The stimulation parameters are set at 130 Hz, 300–450  $\mu$ s, and 2 V (Velasco et al. 2007b; Cukiert et al. 2009). Only one of these patient obtained significant reduction in the number of seizures (>50%) during the first 6 months of follow-up. Better results have achieved in two patients affected by PD in which CM–pf DBS allowed to control the tremor, and to improve the associated bradykinesia and rigidity. CM–pf DBS has been performed contralateral to a right Vop–cZi implant in a parkinsonian patient highly invalidated by severe tremor of the four limbs and head, and by a severe speech impairment. The implant resulted in excellent control of tremor on both sides and head, but the goal to preserve the speech through a thalamic asymmetrical implant could not be achieved (when both the electrodes are activated the patient complains severe dysarthria which disappear when the stimulation is delivered only to one side either if Vim–cZi or CM–pf is turned off). In our opinion, CM–pf is a good target for unilateral tremor when associated to bradykinesia and rigidity in Parkinsonian patient but cannot prevent speech impairment in bilateral implant.

#### Complications

The incidence of complications is related to 580 electrodes implants in 332 consecutive patients operated on between 1993 and 2010. Massive brain hemorrhage with fatal outcome occurred in two cases (0.3%); permanent neurological deficits due to deep hemorrhage occurred in six patients; of which, one was a Vim implant and the other

**Fig. 3** Hardware failure: *Right* spontaneous fracture of the lead outside the skull; *left* upward migration of the deep brain electrode outside the intracranial space



Stn implant (1%). Transient neurological deficits due to deep hemorrhage occurred in 8 patients (1.4%); postoperative seizures occurred in 7 patients (1.2%), hardware removal due to infection occurred in 32 cases (5.5%) 6 of which had cerebral abscess at the origin of the stereotactic trajectory (0.9%); hardware failure occurred in 30 patients (5%); late electrode migration (Fig. 3) occurred in 20 patients (3.4%) of which 8 were under 14 years. The reported risk rates are referred to single electrode implant surgery, patients who need more than one electrode implant may expect a higher risk rate.

## Conclusions

Deep brain stimulation might represent a new therapeutic option to patients affected by severe movement disorders, and in some elective cases, it allows to control life-threatening pathological conditions, such as in status dystonicus and post-stroke hemiballismus, which consequence might be the death of the patient. In the overall series, the higher benefits in patients DBS responders were an improvement of the quality of life. In fact, some young patients, go back to work and to social activities, as for instance in those affected by either primary or tardive dystonia or advanced Parkinson's disease. Nevertheless, as a consequence of the lack of definitive clinical approval, some DBS targets still require further scientific investigations, and careful evaluation of the long-term follow ups, as for example in the treatment of childhood onset dystonia and in patients with behavior diseases comorbidity. In many cases, DBS has showed a synergic action with conservative therapies, which include drugs, physical rehabilitation, and psychotherapy. On the other hand, some issues still limit the wider application of DBS. Among the many limitations, it is noteworthy to mention the incidence of complications, which in a few

cases may be extremely invalidating or even fatal. Furthermore, the hardware complications might reduce the benefits of DBS in term of quality of life. It is our opinion how the next challenges of DBS might be to deal with the patients selection. In fact, every therapeutic application deals with a variable number of non-responders patients, whose might be exposed to the surgical risks. This latter consideration is particularly true for those patients affected by movement disorders, whose might undergo to useless procedures, as a consequence of either the loss of improvement or the appearance of stimulation related side effects, such as speech impairment and/or postural instability as showed in PD patients. In conclusion, it is our opinion that the experience of DBS in the treatment of movement disorders is strongly positive and further investigations and studies must be encouraged in the search for several new indications and targets definition, as well to refine the patients selection criteria.

## References

- Adams JE, Hosobuchi Y, Fields HL (1974) Stimulation of internal capsule for relief of chronic pain. *J Neurosurg* 41:740–744
- Akil H, Richardson DE, Hughes J, Barchas JD (1978) Enkephalin-like material elevated in ventricular cerebrospinal fluid of pain patients after analgesic focal stimulation. *Science* 201:463–465
- Albe-Fessard D, Besson JM (1973) Convergent thalamic and cortical projection—the non-specific system. In: Iggo A (ed) *Handbook of sensory physiology. Somatosensory system*, vol 2. Springer, Berlin, pp 490–560
- Anderson VC, Burchiel KJ, Hogarth P, Favre J, Hammerstad JP (2005) Pallidal versus subthalamic nucleus deep brain stimulation in Parkinson disease. *Arch Neurol* 62:554–560
- Angelini L, Nardocci N, Estienne M, Conti C, Dones I, Broggi G (2000) Life-threatening dystonia-dyskinesias in a child: successful treatment with bilateral pallidal stimulation. *Mov Disord* 15:1010–1012
- Bakay R (2008) *Movement disorder surgery: the essentials*. Thieme, New York

- Bechtereva NP, Bondartchuk AN, Smirnov VM, Meliutcheva LA, Shandurina AN (1975) Method of electrostimulation of the deep brain structures in treatment of some chronic diseases. *Confin Neurol* 37:136–140
- Benabid AL, Pollak P, Louveau A, Henry S, de RJ (1987) Combined (thalamotomy and stimulation) stereotactic surgery of the VIM thalamic nucleus for bilateral Parkinson disease. *Appl Neurophysiol* 50:344–346
- Benabid AL, Pollak P, Hommel M, Gaio JM, de Rougemont J, Perret J (1989) Treatment of Parkinson tremor by chronic stimulation of the ventral intermediate nucleus of the thalamus. *Rev Neurol (Paris)* 145:320–323
- Benabid AL, Pollak P, Gervason C, Hoffmann D, Gao DM, Hommel M et al (1991) Long-term suppression of tremor by chronic stimulation of the ventral intermediate thalamic nucleus. *Lancet* 337:403–406
- Benabid AL, Pollak P, Gross C, Hoffmann D, Benazzouz A, Gao DM et al (1994) Acute and long-term effects of subthalamic nucleus stimulation in Parkinson's disease. *Stereotact Funct Neurosurg* 62:76–84
- Benabid AL, Chabardes S, Mitrofanis J, Pollak P (2009) Deep brain stimulation of the subthalamic nucleus for the treatment of Parkinson's disease. *Lancet Neurol* 8:67–81
- Benazzouz A, Gross C, Féger J, Boraud T, Bioulac B (1993) Reversal of rigidity and improvement in motor performance by subthalamic high-frequency stimulation in MPTP-treated monkeys. *Eur J Neurosci* 5(4):382–389
- Bittar RG, Hyam J, Nandi D, Wang S, Liu X, Joint C et al (2005) Thalamotomy versus thalamic stimulation for multiple sclerosis tremor. *J Clin Neurosci* 12:638–642
- Broggi G, Brock S, Franzini A, Geminiani G (1993) A case of posttraumatic tremor treated by chronic stimulation of the thalamus. *Mov Disord* 8:206–208
- Broggi G, Franzini A, Tringali G, Ferrali P, Marras C, Romito L et al (2006) Deep brain stimulation as a functional scalpel. *Acta Neurochir Suppl* 99:13–19
- Caparros-Lefebvre D, Blond S, Feltin MP, Pollak P, Benabid AL (1999) Improvement of levodopa induced dyskinesias by thalamic deep brain stimulation is related to slight variation in electrode placement: possible involvement of the centre median and parafascicular complex. *J Neurol Neurosurg Psychiatry* 67:308–314
- Cooper IS, Upton AR, Amin I (1980) Reversibility of chronic neurological deficits. Some effects of electrical stimulation of the thalamus and internal capsule in man. *Appl Neurophysiol* 43:244–258
- Cooper IS, Upton AR, Amin I (1982) Reversibility chronic cerebral stimulation (CCS) and deep brain stimulation (DBS) in involuntary movement disorders. *Appl Neurophysiol* 45:209–217
- Coubes P, Echenne B, Roubertie A, Vayssière N, Tuffery S, Humbertclaude V, Cambonie G, Claustres M, Frerebeau P (1999) Treatment of early-onset generalized dystonia by chronic bilateral stimulation of the internal globus pallidus. Apropos of a case. *Neurochirurgie* 45:139–144
- Coubes P, Roubertie A, Vayssiere N, et al. (2000) Treatment of DYT1-generalised dystonia by stimulation of the internal globus pallidus. *Lancet* 355:2220e1
- Critchley GR, Richardson PL (1998) Vim thalamotomy for the relief of the intention tremor of multiple sclerosis. *Br J Neurosurg* 12:559–562
- Cukiert A, Burattini JA, Cukiert CM, Argentoni-Balochi M, Baisezung C, Forster CR, et al. (2009) Centro-median stimulation yields additional seizure frequency and attention improvement in patients previously submitted to callosotomy. *Seizure* 18:588–592
- Defer GL, Widner H, Marie RM, Remy P, Levivier M (1999) Core assessment program for surgical interventional therapies in Parkinson's disease (CAPSIT-PD). *Mov Disord* 14:572–584
- Deuschl G, Raethjen J, Lindemann M, Krack P (2001) The pathophysiology of tremor. *Muscle Nerve* 24:716–735
- Fahn S, Bressman SB, Marsden CD (1998) Classification of dystonia. *Adv Neurol* 78:1–9
- Fasano A, Romito LM, Daniele A, Piano C, Zinno M, Bentivoglio AR, Albanese A (2010) Motor and cognitive outcome in patients with Parkinson's disease 8 years after subthalamic implants. *Brain* 133:2664–2676
- Ficalora AS, Mize RR (1989) The neurons of the substantia nigra and zona incerta which project to the cat superior colliculus are GABA immunoreactive: a double-label study using GABA immunocytoche mistry and lectin retrograde transport. *Neuroscience* 29:567–581
- Fields HL, Adams JE (1974) Pain after cortical injury relieved by electrical stimulation of the internal capsule. *Brain* 97:169–178
- Foote KD, Okun MS (2005) Ventralis intermedius plus ventralis oralis anterior and posterior deep brain stimulation for posttraumatic Holmes tremor: two leads may be better than one: technical note. *Neurosurgery* 56:E445
- Forel A (1877) Untersuchungen über die Haubenregion und ihre oberen Verknüpfungen im Gehirn des Menschen und einiger Säugethiere, mit Beiträgen zu den Methoden der Gehirnuntersuchung. *Archiv für Psychiatrie und Nervenkrankheiten* 7:393–495
- Franzini A, Ferroli P, Servello D, Broggi G (2000) Reversal of thalamic hand syndrome by long-term motor cortex stimulation. *J Neurosurg* 93:873–875
- Franzini A, Ferroli P, Dones I, Marras C, Broggi G (2003) Chronic motor cortex stimulation for movement disorders: a promising perspective. *Neurol Res* 25:123–126
- Franzini A, Marras C, Ferroli P, Zorzi G, Bugiani O, Romito L, Broggi G (2005) Long-term high-frequency bilateral pallidal stimulation for neuroleptic-induced tardive dystonia Report of two cases. *J Neurosurg* 102:721–725
- Franzini A, Cordella R, Nazzi V, Broggi G (2008a) Long term chronic stimulation of internal capsule in post-stroke pain and spasticity-case report long term results and review of the literature. *Stereotact and Funct Neurosurg* 86:179–183
- Franzini A, Messina G, Marras G, Villani F, Cordella R, Broggi G (2008b) Deep brain stimulation of two unconventional targets in refractory non-resectable epilepsy. *Stereotact Funct Neurosurg* 86:373–381
- Franzini A, Messina G, Marras C, Molteni F, Cordella R, Soliveri P, Broggi G (2009) Poststroke fixed dystonia of the foot relieved by chronic stimulation of the internal capsule's posterior limb. *J Neurosurgery* 111:1216–1219
- Geny C, Nguyen JP, Pollin B, Feve A, Ricolfi F, Cesaro P et al (1996) Improvement of severe postural cerebellar tremor in multiple sclerosis by chronic thalamic stimulation. *Mov Disord* 11:489–494
- Hassler R, Riechart T, Munginer F, Umbach W, Ganglberger JA (1960) Physiological observations in stereotaxic operations in extrapyramidal motor disturbances. *Brain* 83:337–350
- Hécaen H, Talairach J, David M, Dell MB (1949) Coagulations limitées du thalamus dans les algies du syndrome thalamique. *Rev Neurol* 81:917–931
- Herzog J, Pinsker M, Wasner M, Steigerwald F, Wailke S, Deuschl G, Volkmann J (2007) Stimulation of subthalamic fibre tracts reduces dyskinesias in STN-DBS. *Mov Disord* 22:679–684
- Hosobuchi Y, Adams JE, Rutkin B (1975) Chronic thalamic and internal capsule stimulation for the control of central pain. *Surg Neurol* 4:91–92
- Houdart R, Mamo H, Dondoy M, Cophignon J (1965) Results of subthalamic coagulations in Parkinson's disease (apropos of 50 cases). *Rev Neurol (Paris)* 112:521–529
- Hughes AJ, Daniel SE, Kilford L, Lees AJ (1992) Accuracy of clinical diagnosis of idiopathic Parkinson's disease: a clinico-

- pathological study of 100 cases. *J Neurol Neurosurg Psychiatry* 55:181–184
- Jones EG (1985) *The thalamus*. Plenum Press, New York
- Kitagawa M, Murata J, Uesugi H, Kikuchi S, Saito H, Tashiro K, Sawamura Y (2005) Two-year follow-up of chronic stimulation of the posterior subthalamic white matter for tremor-dominant Parkinson's disease. *Neurosurgery* 56:281–289
- Kleiner-Fisman G, Fisman DN, Sime E, Saint-Cyr JA, Lozano AM, Lang AE (2003) Long-term follow up of bilateral deep brain stimulation of the subthalamic nucleus in patients with advanced Parkinson disease. *J Neurosurg* 99:489–495
- Kleiner-Fisman G, Liang GSL, Moberg PJ, Ruocco AC, Hurtig HI, Baltuch IH et al (2007) Subthalamic nucleus deep brain stimulation for severe idiopathic dystonia: impact on severity, neuropsychological status, and quality of life. *J Neurosurg* 107:29–36
- Koller W, Pahwa R, Busenbark K, Hubble J, Wilkinson S, Lang A et al (1997) High-frequency unilateral thalamic stimulation in the treatment of essential and parkinsonian tremor. *Ann Neurol* 42:292–299
- Koller WC, Lyons KE, Wilkinson SB, Troster AI, Pahwa R (2001) Longterm safety and efficacy of unilateral deep brain stimulation of the thalamus in essential tremor. *Mov Disord* 16:464–468
- Krack P, Batir A, Van BN, Chabardes S, Fraix V, Ardouin C et al (2003) Five-year follow-up of bilateral stimulation of the subthalamic nucleus in advanced Parkinson's disease. *N Engl J Med* 349:1925–1934
- Krauss JK, Pohle T, Weber S, Ozdoba C, Burgunder JM (1999) Bilateral stimulation of globus pallidus internus for treatment of cervical dystonia. *Lancet* 354:837–838
- Kringelbach ML, Jenkinson N, Owen SL, Aziz TZ (2007) Translational principles of deep brain stimulation. *Nat Rev Neurosci* 8:623–635
- Kudo M, Goto S, Nishikawa S, Hamasaki T, Soyama N, Ushio Y et al (2001) Bilateral thalamic stimulation for Holmes' tremor caused by unilateral brainstem lesion. *Mov Disord* 16:170–174
- Kumar K, Toth C, Nath RK (1997) Deep brain stimulation for intractable pain. A 15-years experience. *Neurosurgery* 40:736–747
- Kupsch A, Benecke R, Müller J, Trottenberg T, Schneider GH, Poewe W et al (2006) Pallidal deep-brain stimulation in primary generalized or segmental dystonia. *N Engl J Med* 355:1978–1990
- Laitinen LV, Bergenheim AT, Hariz MI (1992) Leksell's posteroventral pallidotomy in the treatment of Parkinson's disease. *J Neurosurg* 76:53–61
- Leksell L, Meyerson BA, Forster DM (1972) Radiosurgical thalamotomy for intractable pain. *Confin Neurol* 34:264
- Levy RM, Lamb S, Adams JE (1987) Treatment of chronic pain by deep brain stimulation: long term follow-up and review of the literature. *Neurosurgery* 21:885–893
- Limousin P, Martinez-Torres I (2008) Deep brain stimulation for Parkinson's disease. *Neurotherapeutics* 5:309–319
- Limousin P, Speelman JD, Gielen F, Janssens M (1999) Multicentre European study of thalamic stimulation in parkinsonian and essential tremor. *J Neurol Neurosurg Psychiatry* 66:289–296
- Lyons KE, Pahwa R, Comella CL, Eisa MS, Elble RJ, Fahn S et al (2003) Benefits and risks of pharmacological treatments for essential tremor. *Drug Saf* 26:461–481
- Marras C, Zorzi G, Lenardi C, Rizzi M, Messina G, Alimehmeti R, et al. (2009) A Deep brain stimulation electrode used for radiofrequency lesion of the globus pallidus internus in dystonia. *Stereotact Funct Neurosurg* 87:348–352. [Epub 2009 Sep 10]
- Mazzone P, Stocchi F, Galati S, Insola A, Altibrandi MG, Modugno N et al (2006) Bilateral implantation of centromedian-parafascicularis complex and GPi: a new combination of unconventional targets for deep brain stimulation in severe Parkinson disease. *Neuromodulation* 9:221–228
- Mitrofanis J (2005) Some certainty for the “zone of uncertainty”? Exploring the function of the zona incerta. *Neuroscience* 130:1–15
- Mok D, Mogenson G (1986) Contribution of zona incerta to osmotically induced drinking in rats. *J Am J Physiol* 251:R823–R832
- Mueller J et al (2008) Deep-brain stimulation for Dystonia Study Group Pallidal deep brain stimulation improves quality of life in segmental and generalized dystonia: results from a prospective, randomized sham-controlled trial. *Mov Disord* 23:131–134
- Munding F (1965) Stereotaxic interventions on the zona incerta area for treatment of extrapyramidal motor disturbances and their results. *Confin Neurol* 26:222–230
- Namba S, Nakao Y, Matsumoto Y, Ohmoto T, Nishimoto A (1984) Electrical stimulation of the posterior limb of the internal capsule for treatment of thalamic pain. *Appl Neurophysiol* 47:137–148
- Namba S, Wani T, Shimizu Y, Fujiwara N, Namba Y, Nakamura S, Nishimoto A (1985) Sensory and motor responses to beep brain stimulation Correlation with anatomical structures. *J Neurosurg* 63:224–234
- Nicolelis MA, Chapin JK, Lin RC (1995) Development of direct GABAergic projections from the zona incerta to the somatosensory cortex of the rat. *Neuroscience* 65:609–631
- Nikkhah G, Prokop T, Hellwig B, Lucking CH, Ostertag CB (2004) Deep brain stimulation of the nucleus ventralis intermedius for Holmes (rubral) tremor and associated dystonia caused by upper brainstem lesions Report of two cases. *J Neurosurg* 100:1079–1083
- Nishimoto A, Namba S, Nakao Y, Matsumoto Y, Ohmoto T (1984) Inhibition of nociceptive neurons by internal capsule stimulation. *Appl Neurophysiol* 47:117–127
- Ondo W, Jankovic J, Schwartz K, Almaguer M, Simpson RK (1998) Unilateral thalamic deep brain stimulation for refractory essential tremor and Parkinson's disease tremor. *Neurology* 51:1063–1069
- Ostrem JL, Racine CA, Glass GA, Grace JK, Volz MM, Heath SL, Starr PA (2011) Subthalamic nucleus deep brain stimulation in primary cervical dystonia. *Neurology* 76:870–878
- Pahwa R, Wilkinson SB, Overman J, Lyons KE (2005) Preoperative clinical predictors of response to bilateral subthalamic stimulation in patients with Parkinson's disease. *Stereotact Funct Neurosurg* 83:80–83
- Pahwa R, Lyons KE, Wilkinson SB, Simpson RK Jr, Ondo WG, Tarsy D et al (2006) Long-term evaluation of deep brain stimulation of the thalamus. *J Neurosurg* 104:506–512
- Parrent AG (1998) Overview of the surgical treatment of movement disorders. In: Tasker RR, Gildenberg, PL (eds), *Textbook of stereotactic and functional neurosurgery*. McGraw Hill, New York, pp 995–1003
- Patel NK, Heywood P, O'Sullivan K, McCarter R, Love S, Gill SS (2003) Unilateral subthalamotomy in the treatment of Parkinson's disease. *Brain* 126:1136–1145
- Payne MS, Brown BL, Rao J, Payne BR (2005) Treatment of phenylketonuria-associated tremor with deep brain stimulation: case report. *Neurosurgery* 56:E868
- Piacentini S, Romito L, Franzini A, Granato A, Broggi G, Albanese A (2008) Mood disorder following DBS of the left amygdaloid region in a dystonia patient with a dislodged electrode. *Mov Disord* 23:147–150
- Piasecki SD, Jefferson JW (2004) Psychiatric complications of deep brain stimulation for Parkinson's disease. *J Clin Psychiatry* 65:845–849
- Plaha P, Ben-Shlomo Y, Patel NK, Gill SS (2006) Stimulation of the caudal zona incerta is superior to stimulation of the subthalamic nucleus in improving contralateral parkinsonism. *Brain* 129:1732–1747. [Epub 2006 May 23]

- Plaha P, Khan S, Gill SS (2008) Bilateral stimulation of the caudal zona incerta nucleus for tremor control. *J Neurol Neurosurg Psychiatry* 79:504–513. [Epub 2007 Nov 23]
- Pollak P, Benabid AL, Gross C, Gao DM, Laurent A, Benazzouz A et al (1993) Effects of the stimulation of the subthalamic nucleus in Parkinson disease. *Rev Neurol (Paris)* 149:175–176
- Rodriguez-Oroz MC, Obeso JA, Lang AE, Houeto JL, Pollak P, Rehncrona S et al (2005) Bilateral deep brain stimulation in Parkinson's disease: a multicentre study with 4 years follow-up. *Brain* 128:2240–2249
- Roger M, Cadusseau J (1985) Afferents to the zona incerta in the rat: a combined retrograde and anterograde study. *J Comp Neurol* 241:480–492
- Romanowski CA, Mitchell IJ, Crossman AR (1985) The organisation of the efferent projections of the zona incerta. *J Anat* 143:75–95
- Romito LM, Scerrati M, Contarino MF, Bentivoglio AR, Tonali P, Albanese A (2002) Long-term follow up of subthalamic nucleus stimulation in Parkinson's disease. *Neurology* 58:1546–1550
- Romito LM, Contarino MF, Vanacore N, Bentivoglio AR, Scerrati M, Albanese A (2009) Replacement of dopaminergic medication with subthalamic nucleus stimulation in Parkinson's disease: long-term observation. *Mov Disord* 24:557–563
- Saint-Cyr JA, Trépanier LL, Kumar R, Lozano AM, Lang AE (2000) Neuropsychological consequences of chronic bilateral stimulation of the subthalamic nucleus in Parkinson's disease. *Brain* 123:2091–2108
- Schramm P, Scheihing M, Rasche D, Tronnier VM (2005) Behr syndrome variant with tremor treated by VIM stimulation. *Acta Neurochir (Wien)* 147:679–683 (discussion 83)
- Schupbach WM, Chastan N, Welter ML, Houeto JL, Mesnage V, Bonnet AM et al (2005) Stimulation of the subthalamic nucleus in Parkinson's disease: a 5 year follow up. *J Neurol Neurosurg Psychiatry* 76:1640–1644
- Schuurman PR, Bosch DA, Bossuyt PM, Bonsel GJ, van Someren EJ, de Bie RM et al (2000) A comparison of continuous thalamic stimulation and thalamotomy for suppression of severe tremor. *N Engl J Med* 342:461–468
- Servello D, Porta M, Sassi M, Brambilla A, Robertson MM (2008) Deep brain stimulation in 18 patients with severe Gilles de la Tourette syndrome refractory to treatment: the surgery and stimulation. *J Neurol Neurosurg Psychiatry* 79:136–142
- Shammah-Lagnado SJ, Negrão N, Ricardo JA (1985) Afferent connections of the zona incerta: a horseradish peroxidase study in the rat. *Neuroscience* 15:109–134
- Siegfried J, Lippitz B (1994) Bilateral chronic electrostimulation of ventroposterolateral pallidum: a new therapeutic approach for alleviating all parkinsonian symptoms. *Neurosurgery* 35:1126–1129 (discussion 1129–1130)
- Siegfried J, Wellis G (1997) Chronic electrostimulation of ventroposterolateral pallidum: follow-up. *Acta Neurochir Suppl* 68:11–13
- Simonin C, Tir M, Devos D, Kreisler A, Dujardin K, Salleron J et al (2009) Reduced levodopa-induced complications after 5 years of subthalamic stimulation in Parkinson's disease: a second honeymoon. *J Neurol* 256:1736–1741
- Sun B, Chen S, Zhan S, Le W, Krahl SE (2007) Subthalamic nucleus stimulation for primary dystonia and tardive dystonia. *Acta Neurochir Suppl* 97:207–214
- Svennilson E, Torvik A, Lowe R, Leksell L (1960) Treatment of parkinsonism by stereotactic thermolesions in the pallidal region. A clinical evaluation of 81 cases. *Acta Psychiatr Scand* 35:358–377
- Taha JM, Janszen MA, Favre J (1999) Thalamic deep brain stimulation for the treatment of head, voice, and bilateral limb tremor. *J Neurosurg* 91:68–72
- Turnbull IM, Shulman R, Woodhurst WB (1980) Thalamic stimulation for neuropathic pain. *J Neurosurg* 52:486–493
- Velasco F, Velasco M, Velasco AL, Jiménez F, Marquez I, Rise M (1995) Electrical stimulation of centromedian thalamic nucleus in control of seizures: long term studies. *Epilepsia* 36:63–71
- Velasco F, Jiménez F, Pérez ML, Carrillo-Ruiz JD, Velasco AL, Ceballos J et al (2001) Electrical stimulation of the prelemniscal radiation in the treatment of Parkinson's disease: an old target revised with new techniques. *Neurosurgery* 49:293–306 (discussion 306–308)
- Velasco AL, Velasco F, Velasco M, Jiménez F, Carrillo-Ruiz JD, Castro G (2007a) The role of neuromodulation of the hippocampus in the treatment of intractable complex partial seizures of the temporal lobe. *Acta Neurochir (Suppl)* 97:329–332
- Velasco F, Velasco AL, Velasco M, Jiménez F, Carrillo-Ruiz JD, Castro G (2007b) Deep brain stimulation for treatment of the epilepsies: the centromedian thalamic target. *Acta Neurochir (Suppl)* 97:337–342
- Velasco AL, Velasco F, Velasco M, Trejo D, Castro G, Carrillo-Ruiz JD (2007c) Electrical stimulation of the hippocampal epileptic foci for seizure control: a double-blind, longterm follow-up study. *Epilepsia* 48:1895–1903
- Vidailhet M, Vercueil L, Houeto JL, Krystkowiak P, Benabid AL, Cornu P et al (2005) Bilateral deep-brain stimulation of the globus pallidus in primary generalized dystonia. *N Engl J Med* 352:459–467
- Visser-Vandewalle V, Temel Y, Boon P, Vreeling F, Colle H, Hoogland G et al (2003) Chronic bilateral thalamic stimulation: a new therapeutic approach in intractable Tourette syndrome Report of three cases. *J Neurosurg* 99:1094–1100
- Visser-Vandewalle V, van der LC, Temel Y, Celik H, Ackermans L, Spincemaille G, Caemaert J (2005) Long-term effects of bilateral subthalamic nucleus stimulation in advanced Parkinson disease: a 4 year follow-up study. *Parkinsonism Relat Disord* 11:157–165
- Vives F, Mogenson GJ (1985) Electrophysiological evidence that the mediodorsal nucleus of the thalamus is a relay between the ventral pallidum and the medial prefrontal cortex in the rat. *Brain Res* 344:329–337
- Voges J, Volkmann J, Allert N, Lehrke R, Koulousakis A, Freund HJ, Sturm V (2002) Bilateral high-frequency stimulation in the subthalamic nucleus for the treatment of Parkinson disease: correlation of therapeutic effect with anatomical electrode position. *J Neurosurg* 96:269–279
- Weigel R, Krauss JK (2004) Center median–parafascicular complex and pain control. Review from a neurosurgical perspective. *Stereotact Funct Neurosurg* 82:115–126
- Wider C, Pollo C, Bloch J, Burkhard PR, Vingerhoets FJ (2008) Long-term outcome of 50 consecutive Parkinson's disease patients treated with subthalamic deep brain stimulation. *Parkinsonism Relat Disord* 14:114–119. [Epub 2007 Sep 5]
- Wycis HT, Spiegel EA (1950) The effect of thalamotomy and pallidotomy upon involuntary movements in chorea and athetosis. *Surg Forum* 1:329–332
- Young RF, Kroening R, Fulton W, Feldman RA, Chambi I (1985) Electrical stimulation of the brain in the treatment of chronic pain. Experience over 5 years. *J Neurosurg* 62:389–396
- Zibetti M, Pesare M, Cinquepalmi A, Rosso M, Bergamasco B, Ducati A, Lanotte M, Lopiano L (2008) Antiparkinsonian therapy modifications in PD patients after STN DBS: a retrospective observational analysis. *Parkinsonism Relat Disord* 14:608–612
- Zorzi G, Marras C, Nardocci N, Franzini A, Chiapparini L, Maccagnano E et al (2005) Stimulation of the globus pallidus internus for childhood-onset dystonia. *Mov Disord* 20:1194–1200