



Butterfly needle tap and suction (BTS) technique: a treatment for recurrent chronic subdural hematoma after burr hole craniostomy

Shun Yamamoto¹ · Yoshitaka Nagashima² · Hideki Maki¹ · Yusuke Nishimura² · Yoshio Araki^{2,3} · Masahiro Nishihori² · Tomoyuki Noda¹ · Tasuku Imai¹ · Teppei Kawabata¹ · Masahiro Ueno¹ · Yasumasa Nishida¹ · Ryuta Saito²

Received: 29 December 2022 / Accepted: 1 March 2023 / Published online: 15 March 2023
© The Author(s), under exclusive licence to Springer-Verlag GmbH Austria, part of Springer Nature 2023

Abstract

Background In this study, we propose a butterfly needle tap and suction (BTS) technique for recurrent chronic subdural hematoma (CSDH) as an alternative to reoperation with burr hole craniostomy (BHC) and investigate its efficacy and safety. The procedure involves percutaneous puncture through the burr hole created during the previous surgery and subsequent hematoma evacuation using a butterfly needle.

Methods This retrospective study included patients who underwent BTS for CSDH at Ogaki Municipal Hospital between January 2017 and December 2020. The follow-up CT scans were reviewed after several weeks. We evaluated the number of percutaneous punctures required to resolve CSDH during the BTS technique, the volume of the evacuated hematoma, and procedure-related complications.

Results Twenty-six patients were enrolled in the study, 21 of whom achieved resolution of the hematoma using punctures with the BTS technique alone (mean, 2.2 ± 1.5). Five patients had a recurrence of hematoma after one or more punctures during the BTS technique, and they underwent reoperation with BHC according to the surgeon's decision or patient requests. Among the 55 punctures, 43.0 ± 16.0 ml of hematoma was evacuated per puncture. The evacuated hematoma volume was 41.9 ± 16.4 ml in the BTS-alone group and 49.4 ± 12.9 ml in the reoperation group, with no significant difference ($p = 0.25$). Three patients complained of a headache during the puncture procedure, and no other complications, including intracranial hemorrhage or infection, were reported therein.

Conclusions The BTS technique is an effective alternative to reoperation with BHC.

Keywords Butterfly needle · Chronic subdural hematoma · Burr hole craniostomy · Twist drill craniostomy · Percutaneous puncture

Abbreviations

BTS	Butterfly needle tap and suction
CSDH	Chronic subdural hematoma
BHC	Burr hole craniostomy
TDC	Twist drill craniostomy
CT	Computed tomography

Introduction

Chronic subdural hematoma (CSDH) is a common neurological condition particularly in elderly patients. The incidence of CSDH has been increasing with an aging population worldwide [18]. CSDH is a public health problem with an estimated 1-year incidence of 5–58/100,000 cases [5]. The treatment methods were determined according to the patient's neurological symptoms and clinical conditions. Although surgery continues to play an important role in treatment, the surgical procedure and management of CSDH remain controversial. Several surgical techniques are available for CSDH, including burr hole craniostomy (BHC), twist drill craniostomy (TDC), and craniotomy. Previous studies have established BHC with closed-system drainage or irrigation as the most common standard treatment [10, 15, 17, 19].

✉ Yoshitaka Nagashima
y-nagashima@med.nagoya-u.ac.jp

¹ Department of Neurosurgery, Ogaki Municipal Hospital, Ogaki, Japan

² Department of Neurosurgery, Nagoya University School of Medicine, Nagoya, Japan

³ Department of Neurosurgery, Japanese Red Cross Aichi Medical Center Nagoya Daini Hospital, Nagoya, Japan

Regardless of the selection of these surgical procedures, CSDH has a considerable recurrence rate ranging from approximately 10 to 20% [3, 6, 9, 11, 12, 14]. This considerably high rate is particularly problematic in an aging society with greater comorbidities, where less-invasive procedures are expected to be of greater importance because of these comorbid medical conditions [9, 18]. Nevertheless, the available literature concerning the management of recurrent CSDH is relatively scarce compared with its of first-time onset.

Some patients may exhibit the resolution of residual hematoma after the initial surgery, yet for those with severe neurological symptoms, reoperation and readmission may be indicated. For the patients with mild neurological symptoms, we performed a percutaneous puncture technique called the butterfly needle tap and suction (BTS) technique, which involves a percutaneous puncture through the burr hole created during the previous operation and subsequently draining the hematoma with a butterfly needle. This procedure can be performed in an outpatient clinic without admission, and it is much less invasive than reoperation. The aim of this study was to establish a less invasive treatment for recurrent chronic subdural hematoma by providing a comprehensive description of the BTS technique and examining its safety and efficacy.

Materials and methods

Patient selection

Patients with symptomatic CSDH recurrence after BHC who underwent hematoma evacuation using the BTS technique between January 2017 and December 2020 were retrospectively recruited in this study. All patients who underwent BHC for a primary chronic subdural hematoma were discharged after confirmation via head computed tomography (CT). To reassess the patients' head CT scans and neurological symptoms approximately 2–6 weeks later, a follow-up appointment was scheduled at an outpatient clinic. During the follow-up period, in patients with thick hematoma and midline shift, as detected on head CT, along with minor neurologic symptoms, we proposed to perform hematoma evacuation using the BTS technique in an outpatient clinic. Patients with severe neurological symptoms who required admission, such as those with unconsciousness or severe paralysis, underwent reoperation with BHC. Prior to the first BHC, all patients underwent routine blood tests, including blood coagulation, and patients with obvious coagulation disorders were excluded from BTS. This technique was not also performed in patients taking multiple antithrombotic drugs, even if their coagulation test was normal; however, it was performed in patients taking a single antithrombotic drug. Patients with signs of infection around the surgical site

or active systemic infections were also excluded from this treatment. Among patients who underwent BTS, the analysis excluded those whose follow-up was terminated before hematoma resolution was confirmed by the head CT. The human ethics review committee at our institution approved the study protocol.

Surgical procedure

The BTS technique, performed in an outpatient clinic with patient consent, was performed on patients who met the study criteria. The distance from the skin to the hematoma was measured on head CT (< 19 mm) to confirm that the needle was long enough to reach the hematoma and that it did not reach the brain parenchyma. The patient was placed in a bed and had to lie down to maintain the appropriate position for needle insertion. The operator stood on the side of the patient to observe the previous surgical skin incision and to verify that the superficial temporal artery was not injured by the procedure. The wound was draped and sterilized to reduce the risk of infection from the wound. Thereon, the operator punctured the hematoma percutaneously through the burr hole with a butterfly needle (NIPRO Safe Touch PSV, 23G × 3/4, 0.6 × 19 mm) connected to a 20 ml syringe. Once the hematoma was confirmed to flow back into the needle, the progression was stopped accordingly. Subsequently, a slight negative pressure was applied by slowly pulling out the syringe, and the hematoma was evacuated at a speed of approximately 5 ml/min (Fig. 1). The syringe was replaced upon completion, and the evacuation procedure was continued. The procedure was halted when a patient complained of a headache or heaviness of

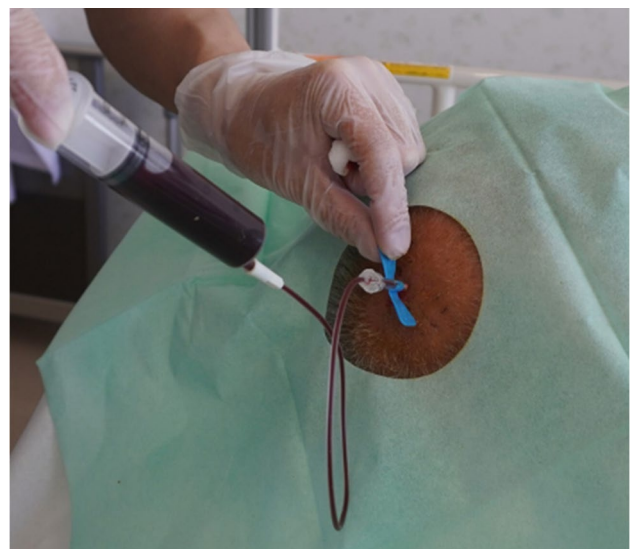

Fig. 1 Photograph of a percutaneous puncture by the BTS technique

the head since the headache could be a sign of a drastic change in intracranial pressure. The volume of the evacuated hematoma was measured and recorded. In patients with bilateral hematomas, the operator could perform punctures through bilateral burr holes if necessary. In most cases, the patient's clinical symptoms improved immediately after hematoma evacuation. Finally, after the procedure, the patients were allowed to rest for at least 30 min on the bed to observe their neurological status. After observation, their vital signs were measured, and neurological stability was confirmed accordingly. The follow-up CT scans were reviewed several weeks later. The indication for further BTS was determined by the respective physician based on the neurological symptoms and head CT images. If an additional puncture was necessary, we performed a repeat puncture until the hematoma decreased in size. Reoperation with BHC was performed if the neurological symptoms severely worsened or if the patient requested BHC rather than further BTS. In general, we followed each patient until the resolution of the hematoma was confirmed, although based on the patient's request or at the physician's judgment in cases of low prospects of further recurrence, follow-up could be discontinued.

Data analysis

Demographic data collected from the medical records included age, sex, whether the hematoma was unilateral or bilateral, neurological symptoms at the first recurrence, antithrombotic medication use, date from the initial BHC to the first puncture using the BTS technique, complications related to the procedure, amount of hematoma aspiration, and the number of percutaneous punctures required for hematoma resolution. The patient's overview included the dates from the first BHC to the first CT scan in the outpatient setting, the dates of BTS and reoperation with BHC, and the duration until the hematoma completely disappeared on head CT. Patient data were analyzed in two groups: the BTS-alone group, in which hematoma resolution was achieved using the BTS technique alone; and the reoperation group, in which hematoma resolution was achieved by reoperation with BHC after one or more punctures using the BTS technique. We also examined whether the amount of hematoma aspirated was associated with CSDH recurrence. The relationship between the amount of evacuated hematoma at each puncture and recurrence was evaluated among the BTS-alone groups. Analyses were performed using the EZR software (Jichi Medical University, Saitama, Japan) [7]. The Mann–Whitney U test or Fisher's exact test was used for comparison, and statistical significance was set at $p < 0.05$.

Results

Thirty patients underwent percutaneous puncture for CSDH recurrence during the observation period. Four patients were excluded because they discontinued outpatient follow-up before hematoma resolution was confirmed. In two patients, the surgeons decided to finish the follow-up despite a certain amount of remaining hematoma. The other two patients were unable to continue their outpatient follow-ups due to transfer to other medical care facilities. Finally, 26 consecutive patients were included in this study. All patients had minor symptomatic recurrence during outpatient follow-up after initial BHC for CSDH at the Ogaki Municipal Hospital. The characteristics of the patients at the first puncture using the BTS technique are shown in Table 1.

The mean age of the patients was 78.8 ± 8.1 years, and 19 of whom (73%) were male. Eighteen (69%) patients had unilateral hematomas, and eight (31%) had bilateral hematomas. Regarding antithrombotic medications, none took anti-coagulants, while five (19%) took antiplatelet medication.

Table 1 Demographic data of the patients at the first puncture by BTS technique

Variable	Value
No. of patients	26
Age*	78.8 (8.1)
Sex	
Male	19 (73%)
Female	7 (27%)
Side of the hematoma	
Right	6 (23%)
Left	12 (46%)
Bilateral	8 (31%)
Antithrombotic drug use	
Anticoagulant	0(0%)
Antiplatelet	5 (19%)
Timing of the first puncture (day)*	31.2 (13.7)
Neurological symptoms at puncture	
Gait disturbance	11 (42%)
Hemiparesis	9 (35%)
Headache	2 (8%)
Epilepsy	1 (4%)
Paresthesia	1 (4%)
Anarhythmia	1 (4%)
Dizziness	1 (4%)
Midline shift at puncture (mm)*	
All	7.5 (2.8)
Unilateral	8.0 (3.1)
Bilateral	5.4 (3.7)

*Mean (SD)

The most common neurological symptoms before the first puncture were gait disturbance and hemiparesis.

A diagram of the observation period for the 26 cases is presented in Fig. 2. The first CT in the outpatient clinic after discharge was performed approximately 2–6 weeks after the first BHC. In 14 cases, BTS was performed on the same day as the CT. The remaining patients underwent their first BTS performed at a later date. All procedures were performed within 139 days of the first BHC, with most procedures conducted within 3 months. The shortest interval to date at which complete resolution of the hematoma was indicated on CT imaging was 81 days (Fig. 3), whereas the longest was 381 days.

The characteristics of the patients who were cured with punctures using the BTS technique alone (BTS-alone group) and those who were cured with reoperation with BHC after one or more punctures using the BTS technique (reoperation group) are presented in Table 2.

Of the 26 patients, 21 were in the BTS-alone group and five were in the reoperation group. All five patients in the reoperation group had hematoma resolution after one reoperation with BHC. All five patients in the reoperation group were male. The only reported complications were headaches in two patients in the BTS-alone group and one in the reoperation group, with no other complications, including intracranial hemorrhage or infection. Of the five patients in the reoperation group, one decided to undergo reoperation because the neurologic symptoms had severely worsened, and the remaining four patients underwent reoperation at their own request when hematoma regrowth had occurred in these cases.

Table 3 shows the number and volume of punctures performed using the BTS technique and the duration of follow-up for each group. The mean number of punctures by the BTS technique was 2.2 ± 1.5 and 1.6 ± 0.9 in the BTS-alone and the reoperation groups, respectively, but the difference was insignificant ($p=0.43$).

The patient who underwent the most frequent BTS technique achieved resolution of hematoma after the seventh puncture. In a total of 55 punctures, 43.0 ± 16.0 ml of hematoma was evacuated per puncture. The evacuated hematoma volume was 41.9 ± 16.4 ml in the BTS-alone group and 49.4 ± 12.9 ml in the reoperation group, with no significant difference ($p=0.25$). There were no significant differences in the follow-up periods of 7.1 ± 3.2 months in the BTS-alone group and 7.8 ± 2.9 months in the reoperation group ($p=0.69$).

The relationship between the amount of hematoma aspirated from each puncture and recurrence was examined among the patients cured by BTS alone. The most recent puncture before the cure was defined as the last puncture, and the other punctures were defined as “other punctures.” Thus, of the 47 punctures in the 21 patients, 21 were the last punctures and 26 were other punctures. The volume of the last puncture was 42.8 ± 19.2 ml, and the volume of the other punctures was 41.3 ± 14.0 ml, with no significant difference ($p=0.92$). The results are shown in Fig. 4.

Discussion

In this study, we evaluated the efficacy and acceptability of the BTS technique after the initial BHC for CSDH. We chose the butterfly needle as the puncture tool since the length of the needle was appropriate for reaching the hematoma in most cases, and the wings could prevent the needle from forwarding too much. Most BTS procedures were performed within 3 months of the initial BHC. Of the 26 consecutive patients, 21 were cured using the BTS technique alone in an outpatient setting. Furthermore, of the five patients who underwent reoperation with BHC, only one had worse symptoms than at the initial presentation during

Fig. 2 Summary of the 26 enrolled cases. The bar chart illustrates the duration between primary BHC and the resolution of the hematoma, as confirmed by a head CT scan. The dates of the first outpatient head CT are represented by inverted triangles, which were conducted approximately between 2 to 6 weeks. The circles and crosses respectively represent the dates of BTS in the outpatient setting and reoperation with BHC across the horizontal time scale

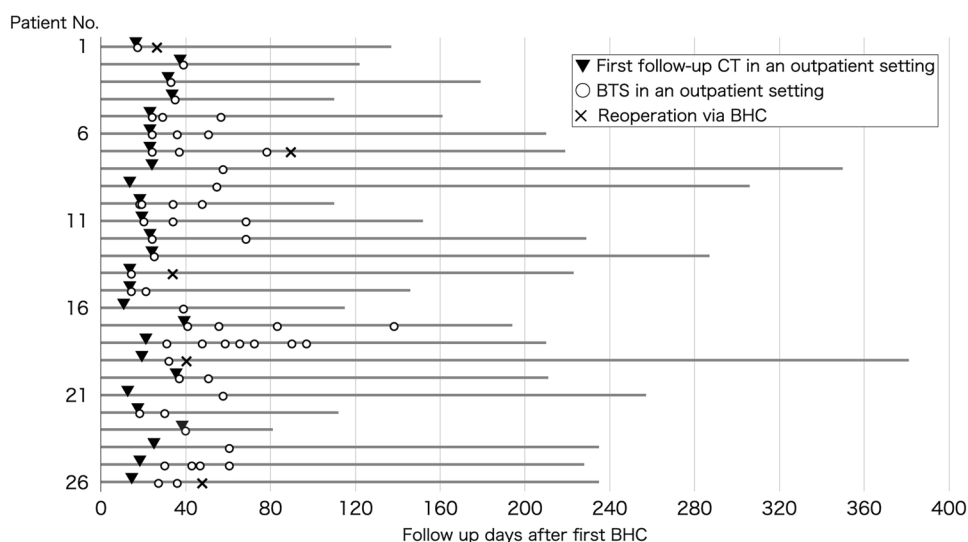
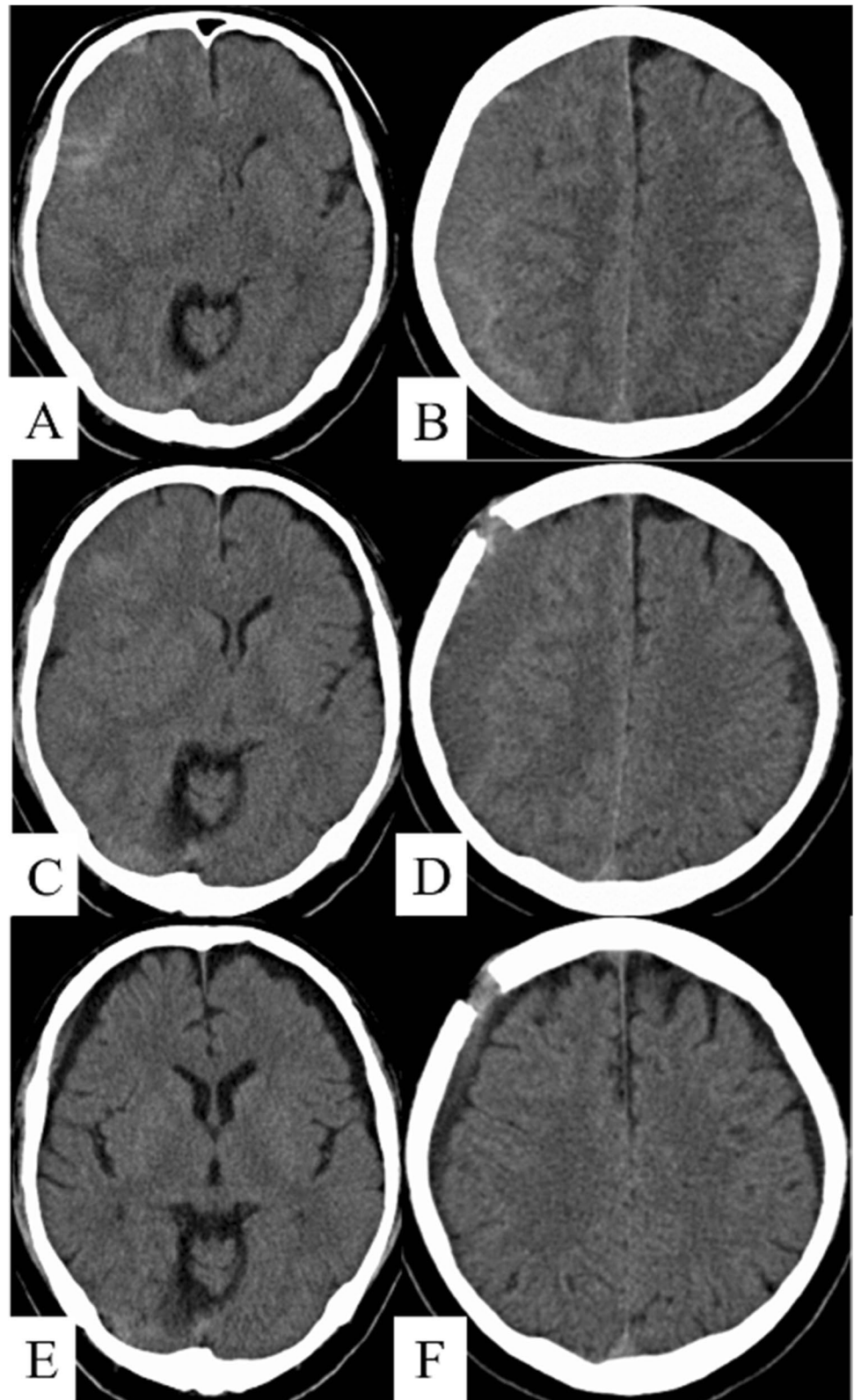


Fig. 3 The clinical course and imaging findings of a 70-year-old man (case 23). He presented with a right chronic subdural hematoma (CSDH) with a midline shift of 13.5 mm (**A**, **B**). After burr hole craniostomy (BHC), the patient experienced a recurrence of CSDH with a midline shift of 12 mm (**C**, **D**). Butterfly needle tap and suction (BTS) was performed through a previous burr hole, and 70 ml of hematoma was evacuated. Follow-up imaging after 81 days (**E**, **F**) showed almost complete resolution of the hematoma



the follow-up period. A total of 55 percutaneous punctures were performed using the BTS technique in 26 patients, among whom, only three complained of headaches during

the procedure. No other complications due to the BTS technique were observed, including intracranial hemorrhage or infection. In our cases, punctures with a single antiplatelet

Table 2 Data and comparison of the two groups

	BTS-alone (<i>N</i> =21)	Reoperation (<i>N</i> =5)	<i>p</i> -value
Age*	78.9 (8.5)	78.6 (6.6)	0.87 [†]
Sex			0.28 [‡]
Male	14 (67%)	5 (100%)	
Female	7 (33%)	0 (0%)	
Side of the hematoma			1.00 [‡]
Unilateral	14 (67%)	4 (80%)	
Bilateral	7 (33%)	1 (20%)	
Antithrombotic drug use	3 (14%)	2 (40%)	0.24 [‡]
Timing of the first puncture (day)*	33.5 (14.1)	21.8 (7.3)	0.08 [†]
Complication			0.49 [‡]
Headache	2 (10%)	1 (20%)	
None	19 (90%)	4 (80%)	

Data depicted as frequency (percentage) or * mean (SD)

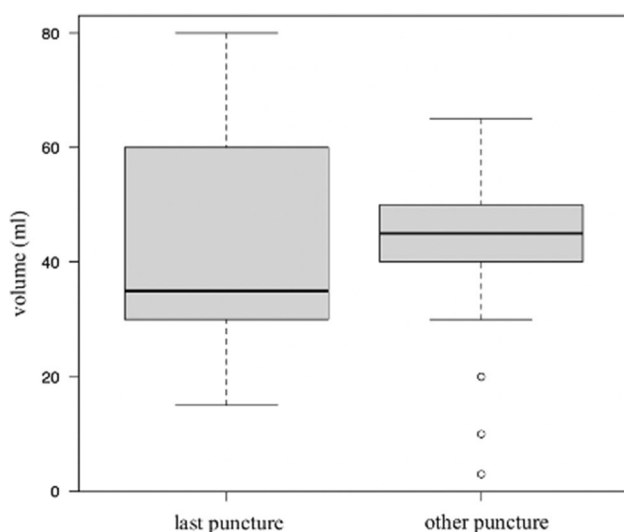
[†]Mann–Whitney U test, [‡]Fisher's exact test

Table 3 The number and the volume of percutaneous punctures and the follow-up period

	BTS-alone (<i>N</i> =21)	Reoperation (<i>N</i> =5)	<i>p</i> -value
No. of punctures performed*	2.2 (1.5)	1.6 (0.9)	0.43 [†]
No. of punctures performed			1.00 [‡]
<i>n</i> =1	9 (43%)	3 (60%)	
<i>n</i> =2	5 (24%)	1 (20%)	
<i>n</i> =3	3 (14%)	1 (20%)	
<i>n</i> =4	3 (14%)		
<i>n</i> =7	1 (5%)		
Hematoma aspiration volume per each punctured (ml)*	41.9 (16.4)	49.4 (12.9)	0.25 [†]
Follow-up period (months)*	7.1(3.2)	7.8(2.9)	0.69 [†]

*Mean (SD)

[†]Mann–Whitney U test, [‡]Fisher's exact test

**Fig. 4** Relationship between percutaneous puncture volume by the BTS technique and CSDH recurrence

agent dosage seemed to be safe in terms of hemorrhagic complications. These results indicate that our BTS technique is potentially safe and may be an effective method for avoiding reoperation and readmission for recurrent CSDH.

Despite the long history of treatment in the neurosurgical field, the surgical procedure and management of CSDH remain controversial. BHC with closed-system drainage or irrigation is considered the standard treatment [10, 15, 17, 19]. TDC is a less invasive procedure performed at the bedside by creating a tiny burr hole in the cranial bone and aspirating the hematoma. Comparisons between BHC and TDC in patients with CSDH have shown equal or similar outcomes in terms of therapeutic efficacy [2, 4, 20, 22]. In some cases, a shorter hospital stay for TDC could result in better clinical outcomes [21]. However, there is a risk of complications since TDC is a blinded procedure. In particular, penetration of the brain during burr hole creation and acute epidural hematoma can result in serious complications [16, 24].

Our BTS technique can also be performed at the bedside; however, the risk of hemorrhagic complications is reduced by addressing several critical points. First, during the first BHC surgery, the dura mater is to be cut in a cruciate fashion and cauterized well enough until the vessels in the burr hole are nearly occluded. As a result, the critical vessels for needle tracts in the BTS technique are treated, and serious bleeding can be prevented in the patient. Second, during the BTS procedure, rapid changes in intracranial pressure and over-drainage should be avoided. These conditions can result in intracranial bleeding remote from the surgical site [1, 8, 23]. Considering these complications, the BTS technique is performed slowly at a speed of 5 ml/min during aspiration to prevent a rapid decrease in intracranial pressure and over-drainage. Some patients complain of headaches during the procedure, which is suspected to be related to a temporary decrease in intracranial pressure. Therefore, we suggest that, in such cases, aspiration should be immediately stopped to prevent hemorrhagic complications. Thus, no intracranial hemorrhage complications, including acute epidural hematoma, were observed in our patient.

In contrast, the BTS technique was considered as effective as TDC in terms of cure. In patients who were cured by percutaneous punctures, the mean number of punctures was 2.2 ± 1.5 in patients who were cured by percutaneous punctures. This indicates that repeated percutaneous punctures could be necessary over a period of time until the resolution of the chronic subdural hematoma. These multiple puncture requirements are also present in the treatment of chronic subdural hematoma with TDC. A prospective study of 118 cases of TDC reported that the mean number of subdural tappings was 3.2 [13]. On the other hand, our study patients underwent one BHC and an average of 2.2 ± 1.5 percutaneous punctures, which is almost the same number of taps reported in the previous TDC study. Thus, our method indicated that the therapeutic effect may be equivalent to that of TDC. With regard to the amount of hematoma aspiration, among the 47 percutaneous punctures performed in the 21 patients treated only with BTS, the 21 punctures that led to cure aspirated an average of 42.8 ± 19.2 ml of hematoma, while 26 punctures that subsequently recurred aspirated an average of 41.3 ± 14.0 ml, with no significant difference. It would have been more preferable for the hematoma to have continued aspiration until completion, yet our concern for bleeding complications from over-aspiration and the cessation of aspiration was prioritized when symptoms, such as headache, occurred. As a result, the aspiration of approximately 40 ml might be a sizable target for BTS.

Our study had several limitations. First, the number of patients in the reoperation group was small, which might have affected the outcome analysis. Second, because this was a retrospective study, the decision to perform percutaneous puncture using the BTS technique and the frequency

of follow-up could have varied among surgeons. Third, the winged needle used in this study was 23 G \times 19 mm in size, although there could be a more appropriate length and thickness. With the optimization of the number of punctures, the volume of evacuated hematoma and established recommendations for reoperation the appropriate follow-up interval should be determined under stricter protocols in the future.

Conclusions

Our BTS technique for recurrent CSDH is safe and may be an effective alternative to reoperations for BHC. It is key that the BTS procedure is performed strictly as described to avoid bleeding and infectious complications.

Data Availability Due to the nature of this research, participants of this study did not agree for their data to be shared publicly, so supporting data is not available.

Declarations

Ethics approval All procedures performed in studies involving human participants were in accordance with the ethical standards of the local Ethical Committee (Ogaki Municipal Hospital Ethical Committee board No. 20227028–4) and with the 1964 Helsinki declaration and its later amendments or comparable ethical standards.

Informed consent Clinical data were collected from the patients using an opt-out method. The requirement for written informed consent for clinical data was waived owing to the observational nature of the study, and we also posted a public notice on the website of Ogaki Municipal Hospital. Informed consent was obtained from all the participants included in the study.

Conflict of interest The authors declare no competing interests.

References

1. Aaron A (2013) Cohen-Gadol: remote contralateral intraparenchymal hemorrhage after overdrainage of a chronic subdural hematoma. *Int J Surg Case Rep* 4:834–836. <https://doi.org/10.1016/j.ijscr.2013.06.014>
2. Almenawer SA, Farrokhyar F, Hong C, Alhazzani W, Manoranjan B, Yarascavitch B, Arjmand P, Baronia B, Reddy K, Murty N, Singh S (2014) Chronic subdural hematoma management: a systematic review and meta-analysis of 34,829 patients. *Ann Surg* 259:449–457. <https://doi.org/10.1097/SLA.0000000000000255>
3. Chon K-H, Lee JM, Koh EJ, Choi HY (2012) Independent predictors for recurrence of chronic subdural hematoma. *Acta Neurochir (Wien)* 154:1541–1548. <https://doi.org/10.1007/s00701-012-1399-9>
4. Ducruet AF, Grobelny BT, Zacharia BE, Hickman ZL, DeRosa PL, Andersen KN, Sussman E, Carpenter A, Connolly ES Jr (2012) The surgical management of chronic subdural hematoma. *Neurosurg Rev* 5:155–69; discussion 169. <https://doi.org/10.1007/s10143-011-0349-y>

5. Holl DC, Volovici V, Dirven CMF, Peul WC, van Kooten F, Jellema K, van der Gaag NA, Miah IP, Kho KH, den Hertog HM, Lingsma HF, Dammers R (2018) Pathophysiology and nonsurgical treatment of chronic subdural hematoma: from past to present to future. *World Neurosurg* 116:402–411.e2. <https://doi.org/10.1016/j.wneu.2018.05.037>
6. Jones S, Kafetz K (1999) A prospective study of chronic subdural haematomas in elderly patients. *Age Ageing* 28:519–521. <https://doi.org/10.1093/ageing/28.6.519>
7. Kanda Y (2013) Investigation of the freely available easy-to-use software 'EZ R' for medical statistics. *Bone Marrow Transplant* 48:452–458. <https://doi.org/10.1038/bmt.2012.244>
8. Kaneshiro Y, Yamauchi S, Urano Y, Murata K (2019) Remote hemorrhage after burr-hole surgery for chronic subdural hematoma: a report of two cases. *Surg Neurol Int* 10:18. https://doi.org/10.4103/sni.sni_108_18
9. Lee JY, Kim B-T, Hwang S-C, Im S-B, Shin D-S, Shin W-H (2012) Indications and surgical results of twist-drill craniostomy at the pre-coronal point for symptomatic chronic subdural hematoma patients. *Società* 52:133–137. <https://doi.org/10.3340/jkns.2012.52.2.133>
10. Lega BC, Danish SF, Malhotra NR, Sonnad SS, Stein SC (2010) Choosing the best operation for chronic subdural hematoma: a decision analysis. *J Neurosurg* 113:615–621. <https://doi.org/10.3171/2009.9.JNS08825>
11. Leroy HA, Aboukaïs R, Reynolds N, Bourgeois P, Labreuche J, Duhamel A, Lejeune JP (2015) Predictors of functional outcomes and recurrence of chronic subdural hematomas. *J Clin Neurosci* 22:1895–1900. <https://doi.org/10.1016/j.jocn.2015.03.064>
12. Mori K, Maeda M (2001) Surgical treatment of chronic subdural hematoma in 500 consecutive cases: clinical characteristics, surgical outcome, complications, and recurrence rate. *Neurol Med Chir(Tokyo)* 41:371–381. <https://doi.org/10.2176/nmc.41.371>
13. Reinges MH, Hasselberg I, Rohde V, Küker W, Gilsbach JM (2000) Prospective analysis of bedside percutaneous subdural tapping for the treatment of chronic subdural haematoma in adults. *J Neurol Neurosurg Psychiatry* 69:40–47. <https://doi.org/10.1136/jnnp.69.1.40>
14. Sakurai S, Kamiyama K, Osato T, Ogino T, Endo H, Mikamoto M, Takahira K, Asanome T, Nakamura H (2016) Retrospective analysis of recurrence risk factors for chronic subdural hematoma. *Jpn J Neurosurg(Tokyo)* 25:748–753. <https://doi.org/10.7887/jjnc.25.748>
15. Santarius T, Kirkpatrick PJ, Ganesan D, Chia HL, Jalloh I, Smielewski P, Richards HK, Marcus H, Parker RA, Price SJ, Kirillos RW, Pickard JD, Hutchinson PJ (2009) Use of drain versus no drains after burr-hole evacuation of chronic subdural haematoma: a randomised controlled trial. *Lancet* 374:1067–1073. [https://doi.org/10.1016/S0140-6736\(09\)61115-6](https://doi.org/10.1016/S0140-6736(09)61115-6)
16. Sucu HK, Gokmen M, Ergin A, Bezircioglu H, Gokmen A (2007) Is there a way to avoid surgical complications of twist drill craniostomy for evacuation of a chronic subdural hematoma? *Acta Neurochir(Wien)* 149:597–599. <https://doi.org/10.1007/s00701-007-1162-9>
17. Thavara BD, Kidangan GS, Rajagopalawarrier B (2019) Comparative study of single burr-hole craniostomy versus twist-drill craniostomy in patients with chronic subdural hematoma. *Asian J Neurosurg* 14:513–521. https://doi.org/10.4103/ajns.AJNS_37_19
18. Uno M, Toi H, Hirai S (2017) Chronic subdural hematoma in elderly patients: is this disease benign? *Neurol Med Chir(Tokyo)* 57:402–409. <https://doi.org/10.2176/nmc.ra.2016-0337>
19. Weigel R, Schmeiedek P, Krauss JK (2003) Outcome of contemporary surgery for chronic subdural haematoma: evidence based review. *J Neurol Neurosurg Psychiatry* 74:937–943. <https://doi.org/10.1136/jnnp.74.7.937>
20. Xu CS, Lu M, Liu LY, Yao MY, Cheng GL, Tian XY, Xiao F, Wan Q, Chen F (2017) Chronic subdural hematoma management: clarifying the definitions of outcome measures to better understand treatment efficacy – a systematic review and meta-analysis. *Eur Rev Med Pharmacol Sci* 21:809–818
21. Xu C, Chen B, Xue L, Xia L, Yang X, Wei M, Hui X, Chen Q, Zheng J, Li Z, Tian X, Cheng G, Xiao F, Lu M (2018) Randomized controlled study on the curative effects of twist-drill craniotomy and burr hole craniotomy in the treatment of chronic subdural hematoma. *Exp Ther Med* 16:959–965. <https://doi.org/10.3892/etm.2018.6265>
22. Yagnik KJ, Goyal A, Van Gompel JJ (2021) Twist drill craniostomy vs burr hole drainage of chronic subdural hematoma: a systematic review and meta-analysis. *Acta Neurochir* 163:3229–3241. <https://doi.org/10.1007/s00701-021-05019-3>
23. Yoo M, Kim J-S (2018) Rapid spontaneous resolution of contralateral acute subdural hemorrhage caused by overdrainage of chronic subdural hemorrhage. *J Neurocrit Care* 11:119–123. <https://doi.org/10.18700/jnc.180051>
24. Yoshino Y, Aoki N, Oikawa A, Ohno K (2000) Acute epidural hematoma developing during twist-drill craniostomy: a complication of percutaneous subdural tapping for the treatment of chronic subdural hematoma. *Surg Neurol* 53:601–604. [https://doi.org/10.1016/s0090-3019\(00\)00240-8](https://doi.org/10.1016/s0090-3019(00)00240-8)

Publisher's note Springer Nature remains neutral with regard to jurisdictional claims in published maps and institutional affiliations.

Springer Nature or its licensor (e.g. a society or other partner) holds exclusive rights to this article under a publishing agreement with the author(s) or other rightsholder(s); author self-archiving of the accepted manuscript version of this article is solely governed by the terms of such publishing agreement and applicable law.