

# Neuroendoscopic aspiration of tumors in the posterior third ventricle and aqueduct lumen: a technical update

Alberto Feletti · Elisabetta Marton · Alessandro Fiorindi · Pierluigi Longatti

Received: 21 March 2013 / Accepted: 8 May 2013 / Published online: 25 May 2013  
© Springer-Verlag Wien 2013

## Abstract

**Background** Small soft ventricular tumors are good candidates for complete removal by a purely endoscopic technique. This approach is particularly interesting for lesions located in the posterior third ventricle and aqueductal lumen.

**Methods** We present our method of endoscopic aspiration through direct contact between the tumor and the working channel of a flexible scope.

**Results** Aspiration without the intermediate use of cannulas is safe and has proved to be effective in the apparently total or partial removal of three soft tumors of different pathologies located in the third ventricle or aqueductal lumen. In one case, a second neuroendoscopy a few months later to repeat endoscopic third ventriculostomy (ETV) offered a unique opportunity to observe the absence of the tumor and the restored anatomy.

**Conclusions** Neuroendoscopy provides a safe, effective way to radically resect small soft tumors in these troublesome locations and can be a valuable alternative to microsurgery.

**Keywords** Neuroendoscopy · Tumor · Aspiration · Third ventriculostomy · Third ventricle · Aqueduct

## Introduction

The resection of tumors of the aqueduct and third ventricle, especially the posterior part, is not without difficulties and potential complications, despite the applied approaches and

techniques. After the first reports published by Gaab in 1998 [8], neuroendoscopy has increasingly focused the interest of neurosurgeons on the pure endoscopic resection of soft tumors smaller than 2 cm [2, 16, 24, 25]. Although this technique requires a strict patients selection and is only indicated in a limited number of cases, it can provide a number of advantages and only a few drawbacks compared to microneurosurgery. Several techniques and tools have been proposed for endoscopic removal of solid tumors: coagulation, dissection by forceps and laser, and aspiration by cannulas. We report our surgical method, providing both a technical description and some illustrative cases in which we have used the direct endoscopic aspiration procedure.

## Procedure

A flexible scope (Karl Storz GmbH and Co., Tuttlingen, Germany) is used with a 3.7 mm diameter and a 1.5 mm working channel. A 14-French peel-away sheath is inserted, as usual, into the right frontal horn through a right precoronal burr hole positioned 2 cm from the midline. The flexible scope is then introduced with a free-hand technique. After quickly inspecting the lateral and third ventricles, the tumor surface is carefully examined, determining whether the lesion is pedunculated and its precise origin. Such close inspection of the external features can give an idea of its consistency. A vegetating aspect, pinkish color, and abundant surface capillaries are all signs that the tumor is amenable to aspiration (Fig. 1). The tumor is then removed with the working channel of the scope placed on the tumor surface and used as a surgical aspirator (Fig. 2). Despite the thin diameter of 1.5 mm, serial aspirations can be performed through the vacuum created by a syringe. This frees the posterior part of the third ventricle, restoring aqueduct patency. Bleeding is simply controlled by continuous irrigation with Ringer's solution. In one case, after tumor

---

Portions of this work were presented in abstract form at the 19th Annual Meeting of the Japanese Society for Neuroendoscopy – Italian-Japanese Joint Meeting 2012, Tokyo, Japan, November 3rd, 2012.

---

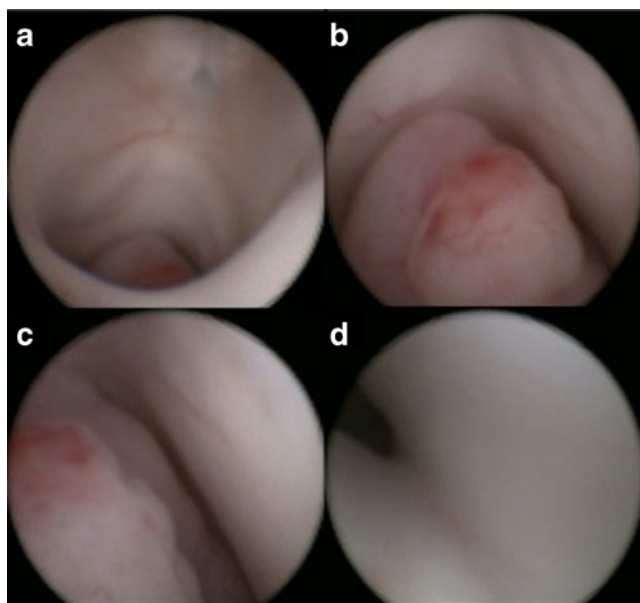
A. Feletti (✉) · E. Marton · A. Fiorindi · P. Longatti  
Department of Neurosurgery, Treviso Hospital, University of Padova, Piazzale Ospedale, 1, 31100 Treviso, Italy  
e-mail: alberto.feletti@gmail.com

aspiration, a blood clot was seen obstructing the aditus of the aqueduct. Accordingly, after aspirating it with the same technique, we also explored the fourth ventricle through the restored aqueduct. A third ventriculostomy is performed in all cases to improve the chances of preventing hydrocephalus.

## Case series

### Case 1

A 22-year-old male patient presented with a 40-day history of worsening headache, associated with nausea in the previous week. Cerebral MRI showed a  $2.1 \times 1.6 \times 1.4$  cm ( $2.4$  cm<sup>3</sup>) mass in the pineal region, extending to the aditus aqueducti mesencephali (Fig. 3). Triventricular hydrocephalus was also present. Neurological examination was normal at admission. The tumor features allowed complete removal (Fig. 1). The postoperative course was uneventful, with resolution of symptoms. An immediate postoperative cerebral MRI confirmed the gross-total resection of the lesion, despite the presence of some blood clots (Fig. 3). Spinal MRI did not show any pathological enhancement after gadolinium injection. The examination was consistent with a diagnosis of anaplastic ependymoma with papillary features (grade III, WHO). The patient underwent conformational radiotherapy (60Gy in 30



**Fig. 1** Endoscopic images of Case 1. **a** Inspection of the third ventricle; the tumor is located in its posterior part. **b** The external features of the tumor are carefully examined; vegetating aspect, pinkish color, and abundant capillaries on the surface are all signs of good aspirability. **c**, **d** The scope is slid along the surfaces of the tumor to determine whether the lesion is pedunculated and its precise origin. The aditus aqueducti is identified under the tumor

fractions), which was completed three months after surgery. No chemotherapy was administered.

Four months after surgery, the patient complained of headache and nausea. Cerebral MRI showed the presence of triventricular hydrocephalus. Cine-flow sequences revealed weak flow through both the third ventriculostomy and the aqueduct. The patient underwent a second neuroendoscopic procedure to repeat ETV. The former stoma site on the floor of the third ventricle, which had probably been incorrectly placed too laterally, was obstructed by a thin membrane, which was opened. The revised ventriculostomy demonstrated clear patency, with effective flow. Subsequently, the posterior aspect of the third ventricle was also accurately explored. No remnant of tumor tissue was observed. The bare choroidal tela and posterior commissure appeared almost anatomically normal, except for the slight ochre color of the posterior commissure caused by the described microbleedings (Fig. 4). The postoperative course was uneventful, with complete resolution of symptoms.

At 1-year follow up, the patient is asymptomatic. Cerebral MRI performed 1 year after initial surgery revealed no pathological enhancements (Fig. 3).

### Case 2

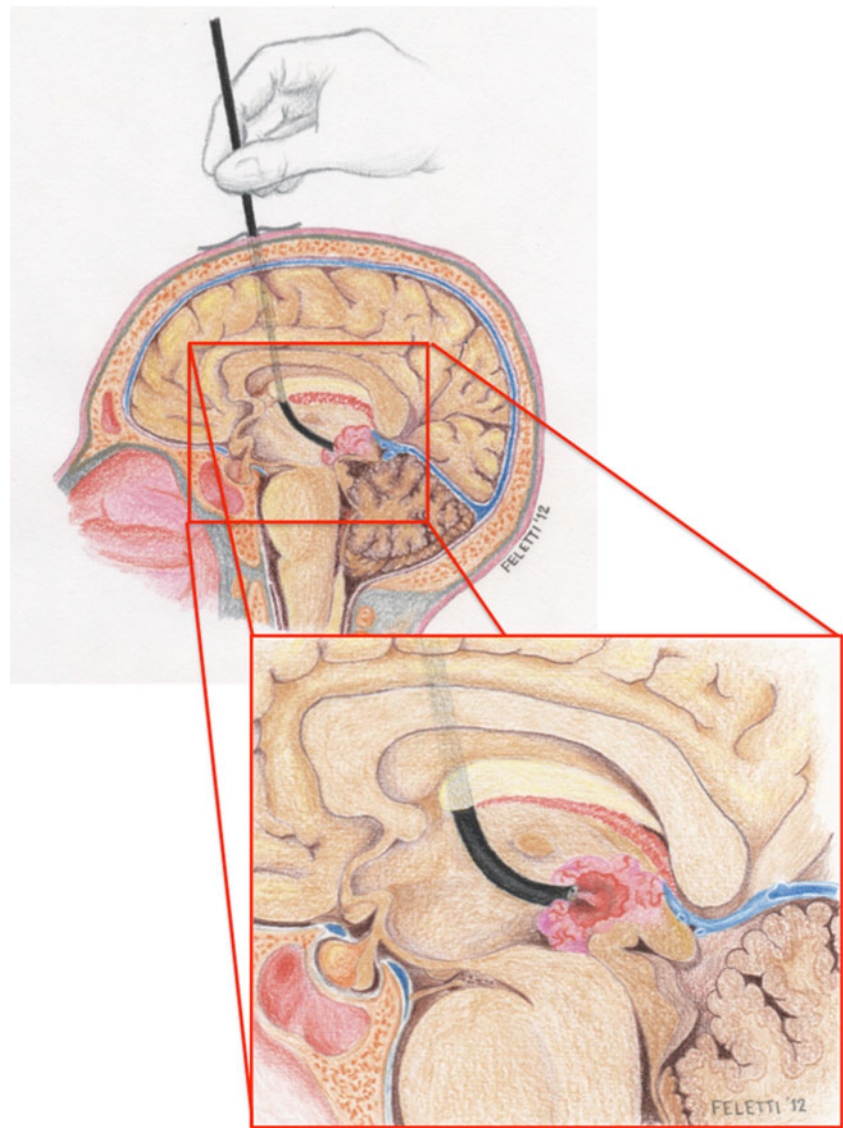
A 48-year-old male patient presented with a one-month history of intense headache with bilateral tinnitus, and gait instability. Cerebral MRI revealed a partially solid, partially cystic lesion in the posterior aspect of the III ventricle, obstructing the aqueduct and causing triventricular hydrocephalus (17 mm maximum diameter). He was admitted to our department with a normal neurological examination. Due to the wide implant, the lesion was only partially removed, enough to free the aqueduct. The postoperative course was uneventful. The patient completely recovered, and MRI showed the resolution of hydrocephalus.

The pathological examination was consistent with a diagnosis of carcinoma with papillary architecture. The patient underwent radiotherapy (RT) and chemotherapy (CT). He is still alive after 9 years.

### Case 3

A 57-year-old man presented with a 2-month history of asthenia, gait difficulties, and disequilibrium. Cerebral MRI showed a lesion of the tectum mesencephali, extending into the aqueduct and reaching the cranial portion of the IV ventricle. A triventricular hydrocephalus was also present. A near-total aspiration was performed. The postoperative course was uneventful. Pathologic examination was consistent with a diagnosis of rosette-forming glioneuronal tumor of the IV ventricle, with atypical characteristics. Despite adjuvant therapy with hyperfractionated radiotherapy and

**Fig. 2** Illustration showing the trajectory of the flexible scope to the posterior aspect of the third ventricle. Some small, soft tumors can be directly aspirated through the working channel just by embedding the tip of the scope into the lesion



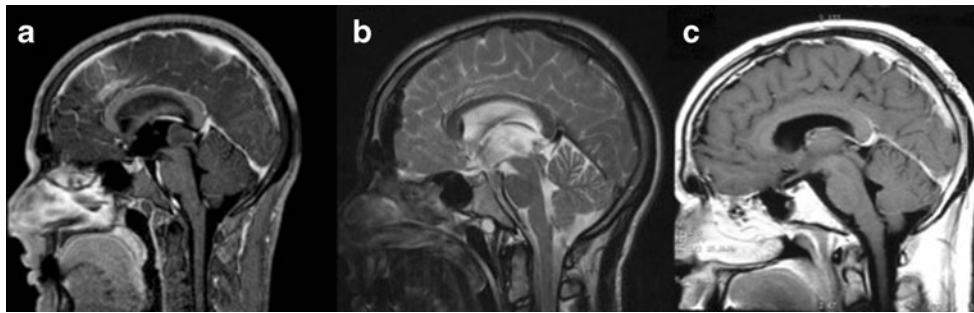
radiosurgery, the tumor rapidly regrew. The patient underwent RT and radiosurgery for recurrences, and died 3 years after diagnosis.

## Discussion

The central location of the third ventricle makes it particularly challenging to reach in open surgery. Microneurosurgical approaches almost always require the dissection and retraction of eloquent and delicate brain structures, and can potentially lead to neurological deficits. This is particularly true of lesions that are deep-seated in the posterior third ventricle or pineal region, accounting for 0.6 % to 0.9 % of all brain tumors [1, 22]. For this reason, in an attempt to reduce mechanical stress on the brain, several neurosurgeons have proposed minimally invasive neuroendoscopic techniques to approach such lesions. Neuroendoscopy has already proved to be effective

and safe in the treatment of purely cystic lesions as colloid cysts [10, 14], and in the resection of purely cystic choroid plexus tumors of the third ventricle [12, 18, 19], cysticercosis cysts of the posterior third ventricle [20], and ependymal cyst of the third ventricle [26].

The application of neuroendoscopy in the resection of solid tumors of the third ventricle is still a matter of technical debate and variants. Some authors have advocated the use of multiple endoscopes or entry sites for additional instrumentation [7, 11]. However, this is technically troublesome and not so minimally invasive. Others have used combined endoscopic and surgical approaches [3, 4], such as introducing wider operative sheaths to remove central neurocytomas [5] or adapting a thoracic port to resect tumors in the lateral or third ventricles [9]. Some authors have reported the use of a dual approach to remove posterior third ventricle tumors (forehead burr hole) and to manage hydrocephalus with ETV (standard frontal burr hole) [6, 23]. New



**Fig. 3** Magnetic resonance imaging of Case 1, showing a  $2.1 \times 1.6 \times 1.4$  cm hypointense tumor in the pineal region, extending to the aditus aqueducti mesencephali (**a**). Triventricular hydrocephalus was also

present. **b** Postoperative MRI confirming the gross-total resection of the lesion. **c** 1-year follow up MRI reveals the absence of local recurrence

tools as the ultrasonic aspiration tip have also been developed in order to expand the spectrum of endoscopic options when facing a solid intraventricular lesion [21].

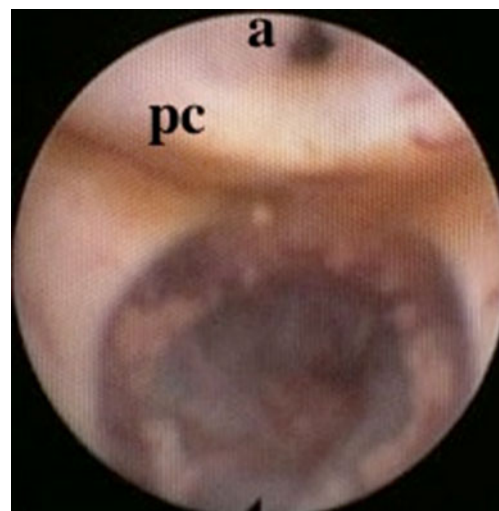
A further step towards an effective, really minimally invasive approach to the third ventricle was made by Gaab in 1998, who partially or totally resected 4 tumors using just a burr hole and a rigid endoscope, with no complications. Bipolar diathermy and grasping and biopsy forceps were used to this end [8].

All the authors agree that the factors potentially limiting this approach are size of the tumor, its consistency, and vascularization. Small, soft tumors no greater than 2 cm are the ones most amenable to neuroendoscopic removal. Unfortunately, tumor consistency is not always clearly predictable, although in our opinion it represents the main feature. Souweidane et al. showed CT scan to be beneficial in excluding calcified and hyperdense tumors, which are usually more cellular than hypodense lesions [25]. In our opinion, however, direct inspection is the definitive way to assess tumor aspirability. For this reason, we always plan an initial endoscopic biopsy, and intraoperatively decide whether tumor aspiration would be feasible.

In all the published cases, the authors report coagulating the tumor surface, followed by the use of several instruments, as the biopsy rongeur, the forceps, and in some cases the diode laser (Table 1). In our view, however, some tumors lend themselves to the use of a flexible scope alone, which can be used as an aspirator by simply embedding its tip into the lesion and carefully applying a pulsating suction action with an external syringe. Although visualization is prevented once the endoscope is placed on the tumor, the tumor can be removed piecemeal due to the small dimensions of the working channel and because the degree of aspiration can be controlled through the syringe. As the aspirated fragments are very small, inadvertent aspiration of surrounding structures is avoided by carefully and accurately positioning the tip of the endoscope on just the tumoral portions. Nonetheless, such a manoeuvre requires an adequate neuroendoscopic training, and should be performed by expert endoscopists only. We have gained extensive experience in the endoscopic aspiration of intraventricular hemorrhagic clots in hemocep-

halus totalis [13]. Direct aspiration with the working channel was also used to empty all our cases of colloid cysts and even brain abscesses [14, 15]. We applied the same technique for the aspiration of particularly soft tumors with high water content. Aspiration can be a simple, useful manoeuvre for removing small, soft tumors. With this technique we were able to resect three tumors (1 gross total removal, 2 partial removals) of the third ventricle/aqueduct. In another 12 cases, either size or stiff fibrotic consistency prevented us from performing anything more than a biopsy. Luther and Souweidane also reported the complete resection of 6 tumors of the third ventricle by aspiration. They did, however, stress the need to perform aspiration through a 6-French endotracheal suction catheter which had been previously angled-cut by the operators themselves, in order to more successfully break the tumor capsule [16, 25]. We agree on the importance of aspiration in such cases. In our experience, a flexible scope with a smaller diameter allows minimal invasiveness but still guarantees effective, direct aspiration.

Tumors connected to the ventricular wall by just a pedicle are the most amenable to this kind of resection, which is particularly



**Fig. 4** Endoscopic appearance at 1-year follow up; a: aqueduct; pc: posterior commissure

**Table 1** Endoscopic removal of third ventricular tumors. Literature review

Author	Pt	Sex, age	Pathology	Ventricle	Size	Hydr	Method	Resection	Compl	ETV	Shunt	Adjuvant therapy	Follow up	Outcome	Local recurrence
Gaab et al., 1998	1	M, 7	Metastatic medulloblastoma	III	<2cm	Yes	Bipolar diathermy, grasping and biopsy forceps	Total		+		CT, RT	41 mos.	Good	No
	2	F, 61	Epidermoid cyst	III	<2cm	Yes	Bipolar diathermy, grasping and biopsy forceps	Partial		Sept		RT	15 mos.	Good	Yes
	3	F, 25	Low-grade astrocytoma	III, aqueduct	<2cm	Yes	Bipolar diathermy, grasping and biopsy forceps			+			12 mos.	Good	No
	4	M, 18	Germinoma	III, pineal region	<2cm	No	Bipolar diathermy, grasping and biopsy forceps					RT	3 mos.	Transient confusion, diabetes insipidus, pituitary insufficiency, memory problems	No
Macarthur et al., 2001	5		Ependymoma	III		Yes	Pin fixation, 1.4mm burr hole, rigid scope, bipolar diathermy, biopsy forceps, No6 French endotracheal suction catheter	Complete	No	+		No	3 yrs.	Good	No
Luther et al., 2005	6	F, 31	Ependymoma	Posterior III	5mm	Yes	1.4cm burr hole, rigid scope, 6mm endoscopic sheath No. 6 French endotracheal suction catheter, blunt dissection.	Complete	No	+		RT	6 mos.	Good	No
Souweidane 2006	7	M, 20	Low-grade glioneuronal tumor	III	1.2cm	Yes	1.4cm burr hole, rigid scope, 6mm endoscopic sheath No. 6 French endotracheal suction catheter, blunt dissection.	Complete	No	+	No		19 mos.	Good	No
	8	M, 49	Ependymoma	III	1.7cm	Yes	1.4cm burr hole, rigid scope, 6mm endoscopic sheath No. 6 French endotracheal suction catheter, blunt dissection.	Complete	No	+	No		26 mos.	Good	No
	9	F, 40	Central neurocytoma	III	1.2cm	Yes	1.4cm burr hole, rigid scope, 6mm endoscopic sheath No. 6 French endotracheal suction catheter, blunt dissection.	Complete	No	+	No		9 mos.	Good	No
	10	F, 31	Ependymoma	Posterior III	0.5cm	Yes	1.4cm burr hole, rigid scope, 6mm endoscopic sheath No. 6 French endotracheal suction catheter, blunt dissection.	Complete	No	+	No		6 mos.	Good	No
	11	F, 39	Central neurocytoma	III	2.4cm	Yes	1.4cm burr hole, rigid scope, 6mm endoscopic sheath No. 6 French endotracheal suction catheter, blunt dissection.	Partial (50%)	No	+	No	RT			
Rosenstengel et al., 2011	12	M, 12	Ependymoma grade III	Posterior III	<2cm	Yes	Right precoronal burr hole, rigid scope	Complete	No	+	No	RT, CT	5 yrs.	Good	No
Present series	13	M, 22	Anaplastic ependymoma	Posterior III	2.1x1.6x1.4cm	Yes	Right precoronal burr hole, flexible scope, direct aspiration with scope	Complete	EVT closure	+	No	RT	1 yr.	Good	No
	14	M, 48	Carcinoma with papillary architecture	Posterior III	17mm	Yes	Right precoronal burr hole, flexible scope, direct aspiration with scope	Partial	No	+	No	RT, CT	9 yrs.	Good	No
	15	M, 57	Rosette forming tumor of the IV ventricle, anaplastic	Tectum mesencephali, aqueduct	2cm	Yes	Right precoronal burr hole, flexible scope, direct aspiration with scope	Partial	No	+	No	RT, radiosurgery	3 yrs.	Died for progression	Yes

*Pt* patient; *Hydr* hydrocephalus; *Compl* complications; *ETV* endoscopic third-ventriculostomy; *Sept* septostomy; *CT* chemotherapy; *RT* radiotherapy

indicated in the subgroup of pedunculated tumors plunging into the aqueduct. In these cases the best results can be achieved as described by Rosenstengel et al., and confirmed by our own cases [24]. Some authors consider hypervascularization to be a contraindication for endoscopic resection of ventricular lesions. However, superficially vascularized tumors are usually softer and therefore good candidates for neuroendoscopic aspiration. Bleeding during aspiration is mainly due to laceration of capillaries or microarteries. In our experience, although it is annoying and delays surgery time, bleeding can usually be controlled by continuous irrigation with Ringer's solution. In general, we used a flexible scope in more than 600 procedures, and never failed to manage intraoperative bleeding. Nonetheless, thorough endoscopic inspection is advisable even in the fourth ventricle, as it permits aspiration of potential clots obstructing CSF flow.

All the authors consider it mandatory to perform a third ventriculostomy during the same procedure. Third ventriculostomy is almost always necessary to cure or prevent hydrocephalus in such cases.

The opportunity to take a second look at the surgery site in one of our patients, in order to redo a third ventriculostomy four months after tumor aspiration, allowed us to observe the complete absence of the tumor and restoration of the normal anatomy of the posterior third ventricle. Although impressive and esthetically rewarding for the surgeon, this evidence could be due at least in part to the radiotherapy performed two months beforehand.

## Conclusion

When a tumor of limited size grows in the posterior third ventricle or plunges into the aqueduct, it can be reasonably reached through a neuroendoscopic procedure, during which not only biopsy, but also partial or gross total soft tumor aspiration are achievable. Tiny soft tumors have been endoscopically aspirated in a few cases reported in the literature. To our knowledge, our case provides for the first time late, direct, visual evidence of the effectiveness of endoscopic gross total aspiration of a soft tumor in the third ventricle.

**Conflict of interest** None.

## References

1. Apuzzo ML, Chandrasoma PT, Cohen D, Zee CS, Zelman V (1987) Computed imaging stereotaxy: experience and perspective related to 500 procedures applied to brain masses. *Neurosurgery* 20:930–937
2. Badie B, Brooks N, Souweidane MM (2004) Endoscopic and minimally invasive microsurgical approaches for treating brain tumor patients. *J Neurooncol* 69:209–219
3. Cai R, Di X (2010) Combined intra- and extra-endoscopic techniques for aggressive resection of subependymal giant cell astrocytomas. *World Neurosurg* 73:713–718
4. Charalampaki P, Filippi R, Welschehold S, Conrad J, Perneczky A (2005) Tumors of the lateral and third ventricle: removal under endoscope-assisted keyhole conditions. *Neurosurgery* 57:302–311
5. Cheng CH, Liu CL, Chen CC, Lin SZ, Cho DY (2010) Single-port endoscopic removal of intraventricular central neurocytoma. *J Clin Neurosci* 17:1417–1420
6. Chibbaro S, Di Rocco F, Makiese O, Reiss A, Poczos P, Mirone G, Servadei F, George B, Crafa P, Polivka M, Romano A (2012) Neuroendoscopic management of posterior third ventricle and pineal region tumors: technique, limitation, and possible complication avoidance. *Neurosurg Rev* 35:331–338
7. Cohen AR (1998) Endoscopic ventricular surgery. *Pediatr Neurosurg* 19(127–134):1993
8. Gaab MR, Schroeder HW (1999) Neuroendoscopic approach to intraventricular lesions. *J Neurosurg* 88:496–505
9. Harris AE, Hadjipanayis CG, Lunsford LD, Lunsford AK, Kassam AB (2005) Microsurgical removal of intraventricular lesions using endoscopic visualization and stereotactic guidance. *Neurosurgery* 56:125–132
10. Horn EM, Feiz-Erfan I, Bristol RE, Lekovic GP, Goslar PW, Smith KA, Nakaji P, Spetzler RF (2008) Treatment options for third ventricular colloid cysts: comparison of open microsurgical versus endoscopic resection. *Neurosurgery* 62:1076–1083
11. Jallo GI, Morota N, Abbott R (1996) Introduction of a second working portal for neuroendoscopy. A technical note. *Pediatr Neurosurg* 24:56–60
12. Kariyattil R, Panikar D (2008) Choroid plexus cyst of the third ventricle presenting as acute triventriculomegaly. *Childs Nerv Syst* 24:875–877
13. Longatti P, Fiorindi A, Martinuzzi A (2005) Neuroendoscopic aspiration of hematocephalus totalis: technical note. *Neurosurgery* 57(4 Suppl):E409
14. Longatti P, Godano U, Gangemi M, Delitala A, Morace E, Genitori L, Alafaci C, Benvenuti L, Brunori A, Cereda C, Cipri S, Fiorindi A, Giordano F, Mascari C, Oppido PA, Perin A, Tripodi M (2006) Cooperative study by the Italian neuroendoscopy group on the treatment of 61 colloid cysts. *Childs Nerv Syst* 22:1263–1267
15. Longatti P, Perin A, Ettore F, Fiorindi A, Baratto V (2006) Endoscopic treatment of brain abscesses. *Childs Nerv Syst* 22:1447–1450
16. Luther N, Souweidane MM (2005) Neuroendoscopic resection of posterior third ventricular ependymoma. Case report. *Neurosurg Focus* 18(6A):E3
17. Macarthur DC, Buxton N, Vloeberghs M, Punt J (2001) The effectiveness of neuroendoscopic interventions in children with brain tumours. *Childs Nerv Syst* 10:589–594
18. Miyagi Y, Natori Y, Suzuki SO, Iwaki T, Morioka T, Arimura K, Maeda Y, Shono T, Matsukado K, Sasaki T (2006) Purely cystic form of choroid plexus papilloma with acute hydrocephalus in an infant. Case report. *J Neurosurg* 105(6 Suppl):480–484
19. Meng H, Feng H, Zhang L, Wang J (2011) Endoscopic removal of a cystic choroid plexus papilloma of the third ventricle: a case report and review of the literature. *Clin Neurol Neurosurg* 113:582–585
20. Neal JH (1995) An endoscopic approach to cysticercosis cysts of the posterior third ventricle. *Neurosurgery* 36:1040–1043
21. Oertel J, Krauss JK, Gaab MR (2008) Ultrasonic aspiration in neuroendoscopy: first results with a new tool. *J Neurosurg* 109:908–911
22. Oi S, Shibata M, Tominaga J, Honda Y, Shinoda M, Takei F, Tsugane R, Matsuzawa K, Sato O (2000) Efficacy of neuroendoscopic

- procedures in minimally invasive preferential management of pineal region tumors: a prospective study. *J Neurosurg* 93:245–253
23. Romano A, Chibbaro S, Makiiese O, Marsella M, Mainini P, Benericetti E (2009) Endoscopic removal of a central neurocytoma from the posterior third ventricle. *J Clin Neurosci* 16:312–316
  24. Rosenstengel C, Baldauf J, Müller JU, Schroeder HW (2011) Sudden intraaqueductal dislocation of a third ventricle ependymoma causing acute decompensation of hydrocephalus. *J Neurosurg Pediatr* 8:154–157
  25. Souweidane MM, Luther N (2006) Endoscopic resection of solid intraventricular brain tumors. *J Neurosurg* 105:271–278
  26. Yano S, Kuroda J, Makino K, Tsuiki H, Morioka M, Kuratsu J (2006) Third ventricular ependymal cyst presenting with acute hydrocephalus. *Pediatr Neurosurg* 42:245–248