

## Case Report

# Choroid plexus papilloma of bilateral lateral ventricle

T. Erman<sup>1</sup>, A. İ. Göçer<sup>1</sup>, Ş. Erdoğan<sup>2</sup>, M. Tuna<sup>1</sup>, F. İldan<sup>1</sup>, and S. Zorludemir<sup>2</sup>

<sup>1</sup>Department of Neurosurgery, Çukurova University, School of Medicine, Adana, Turkey

<sup>2</sup>Department of Pathology, Çukurova University, School of Medicine, Adana, Turkey

Published online February 10, 2003

© Springer-Verlag 2003

## Summary

**Background.** Choroid plexus papillomas are rare, accounting for less than 1% of all intracranial tumours in adults. However, they are relatively more common in childhood and constitute 1.5 to 4% of intracranial tumours. They are most often located in the lateral ventricle, followed by the fourth and third ventricles and, rarely, in the cerebellopontine angle. Bilateral lateral ventricle choroid plexus papilloma is very rare and only a few cases has been reported.

**Clinical presentation.** A 3-year-old boy was admitted to our hospital with a history of irritability and vomiting. Neurological examination on admission was normal. A head computed tomographic scan and magnetic resonance imaging showed tumours in both lateral ventricles, hydrocephalus and a left temporal arachnoid cyst. The bilateral intraventricular mass enhanced densely and homogeneously. A presumptive diagnosis of choroid plexus papillomas was made.

**Intervention.** The initial surgery was performed for removal of the lesion in the right lateral ventricle, and 20 days later removal of the left lateral ventricle tumour was carried out. Bilateral temporoparietal craniotomy and total removal of tumours was performed. Hydrocephalus was controlled by total tumour resection from both sides. The histology of these tumours was the same and revealed choroid plexus papilloma.

**Interpretation.** Bilateral choroid plexus papilloma is extremely rare and distinct from diffuse villous hypertrophy and their surgical approaches are different from each other. Differential diagnosis should be made by MRI preoperatively. If bilateral choroid plexus papilloma is detected, total surgical resection should be performed. Total surgical removal of the neoplasm not only cures the tumour but also may lead to complete resolution of the hydrocephalus.

**Keywords:** Children; choroid plexus papilloma; lateral ventricular tumour.

## Introduction

Intraventricular lesions in children may arise from a variety of pathologies, including subependymal giant cell astrocytoma, astrocytoma, meningioma, ependy-

moma, metastases, choroid plexus carcinoma (CPC), choroid plexus papilloma (CPP), colloid cyst or others [10, 12, 30, 33]. Of these, choroid plexus tumours account for approximately 3% of all primary brain tumours in children, with the majority of cases (up to 90%) having a diagnosis of CPP [10, 12, 30]. The literature for paediatric populations indicates that 67 to 75% of all choroid plexus tumours are located in the lateral ventricles, 15% in the fourth ventricle, and 8% in the third ventricle [10, 12, 16, 28–30].

We present a rare case of bilateral lateral ventricle choroid plexus papilloma and review the literature on this topic.

## Case report

A 3-year-old boy admitted to our hospital with a history of irritability and vomiting. Neurological examination on admission was normal. Contrast and noncontrast head computed tomographic (CT) scan demonstrated bilateral tumour in the lateral ventricles, hydrocephalus and left temporal arachnoid cyst (Fig. 1a,b). Magnetic resonance imaging (MRI) disclosed a bilateral intraventricular tumour centred around the ventricular trigone and hydrocephalus (Fig. 2). The bilateral intraventricular mass was enhanced densely and homogeneously. A presumptive diagnosis of choroid plexus papillomas was made.

**Operative procedure.** A right temporoparietal craniotomy was performed. After the dura was opened, a linear incision in the superior temporal gyrus was made. We attempted to first identify and coagulate the vascular pedicle of the tumour, to reduce blood loss, which was carried out. A greyish-red lobulated vascular lesion in the right lateral ventricle was exposed and total removal of tumour was performed. After surgery, left hemiparesis developed on 19th post-operative day and, CT scans showed tumour in the left lateral ventricle and subdural fluid collection in the right fronto-parietal area (Fig. 3). The second surgical procedure was performed 20 days after

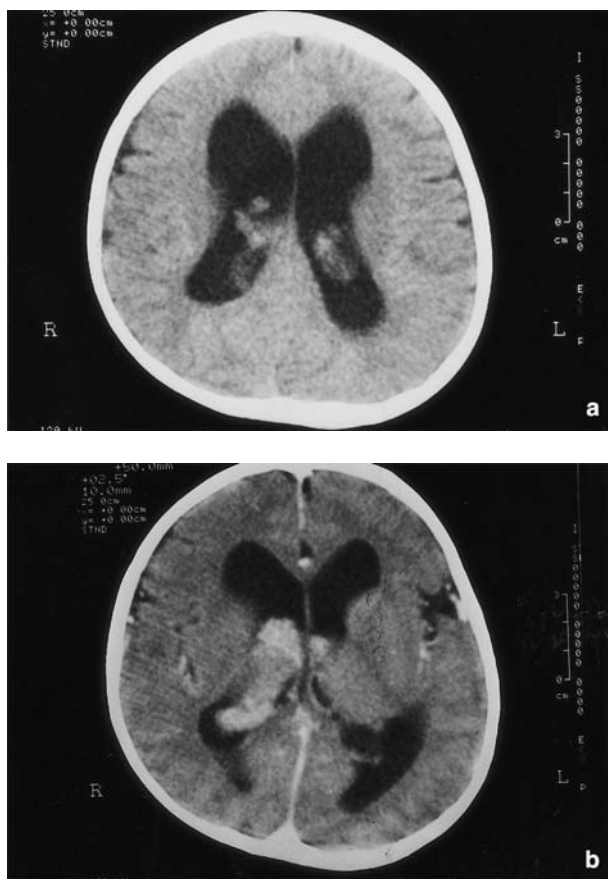


Fig. 1. (a) Axial non-contrast CT scan demonstrating tumour of the lateral ventricles bilaterally and hydrocephalus. (b) Axial contrast enhanced CT scan demonstrating an enhancing tumour of the lateral ventricle bilaterally with hydrocephalus

the first operation. After left temporoparietal craniotomy the dura was opened, a linear incision in the superior temporal gyrus was made. Firstly, the vascular pedicle of the tumour was coagulated and greyish-red lobulated vascular lesion in the left lateral ventricle was exposed and total removal of tumour was achieved (Fig. 4). The patient was discharged 1 week after surgery without neurological deficit.

Histologically typical CPP's were identified. The microscopic examination of both tumours showed arborizing papillae lined with a single layer of columnar epithelium. There were no mitotic figures. The nuclei were basally located and there was no hyperchromasia. No invasion into the surrounding brain was seen (Fig. 5a–c).

One month after surgery, neurological examination was normal. Three month after surgery, neurological examination was normal and MRI scans demonstrated no residual or recurrent tumour and no hydrocephalus (Fig. 6a,b). The patient's hydrocephalus was cured by the bilateral tumour removal.

## Discussion

CPP's are rare, accounting for less than 1% of all intracranial tumours in adults [10, 12, 16, 26, 30]. However, they are relatively more common in childhood and constitute 1.5 to 4% of intracranial tumours

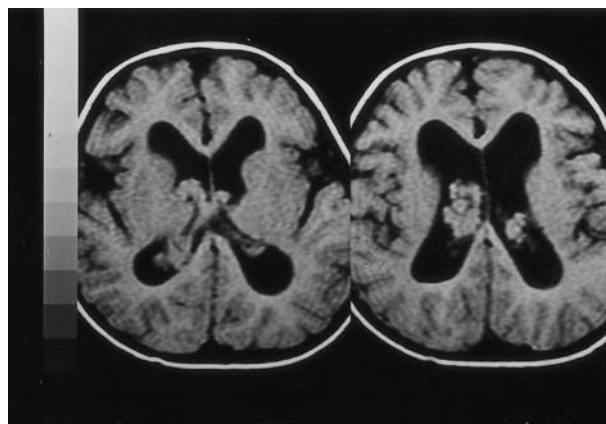


Fig. 2. Axial enhanced MRI demonstrating a lobulated enhancing mass in the bilateral lateral ventricular trigone

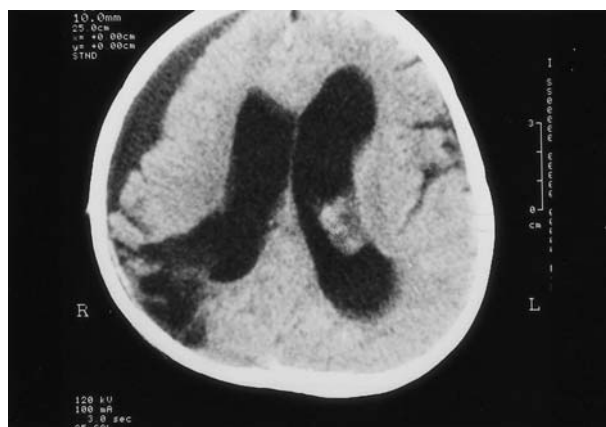


Fig. 3. Axial non-contrast CT scan demonstrating tumour of the left lateral ventricle and subdural fluid collection on the right frontoparietal area

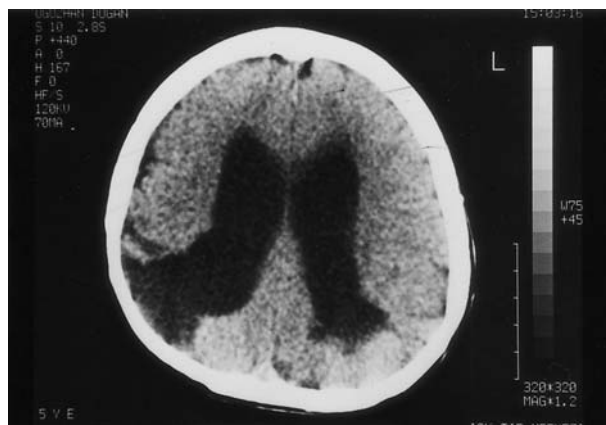


Fig. 4. Axial non-contrast CT scans demonstrating total resection of the tumours

[12, 16, 26, 28, 29]. CPP can be found at all ages, the majority (70%) present in children less than 2 years of age [10, 12, 16, 27–30].

In adults, the CPP is most often located in the fourth ventricle, whereas in children it usually arises in the lateral ventricle, followed by the fourth and third ventricles and, rarely, in the cerebellopontine angle [10, 12, 13, 22, 26, 30]. The previously common belief that the left lateral ventricle is most commonly involved has not been substantiated by more recent reports [3, 6, 14, 15, 19, 20, 23]. Their location in the both lateral ventricles, as in the present case, is very rare and only a few cases have been reported [8, 26]. Matson and Crofton reported 16 cases and collected another 67 from the literature, but only six of these 83 patients had bilateral papillomas [17]. Rovit, *et al.*, [24] reviewed 245 cases of choroid plexus papilloma (11 of their own and 234 from the literature) and found bilateral papillomas in only six cases.

CPPs should be distinguished from bilateral villous hypertrophy. Diffuse villous hypertrophy of the choroids plexus, as described by Davis [7] in 1924, has often been erroneously referred to as bilateral choroid plexus papillomas. A papilloma by definition implies

a discrete mass; thus, it is distinct from villous hypertrophy, in which diffuse enlargement of the choroids plexus in both lateral ventricles with normal histological appearance, is often associated with hypersecretory function. Both lesions have similar histopathological features, so there seem to be some problems with distinguishing choroids plexus papilloma from hypertrophy. Differential diagnosis should be made especially by CT and MRI findings [11]. In the present case, we made a diagnosis of papilloma of the choroid plexus in both lateral ventricles for the following reasons. Computerized tomography and MR images indicated that the choroid plexus papilloma of each lateral ventricles was densely and homogeneously enhanced. Papillomas have a tendency to appear mottled, lobulated, homogeneous enhancing masses without paranchymal invasion and necrosis on MRI scans as in our patient. Their frond-like projections and associated hydrocephalus are characteristic [2, 4, 22, 25, 31, 32].

CPP's have histological features that are very similar to those of the normal choroid plexus. The papilloma's epithelium is more complicated and more cellular than the normal plexus. The normal plexus

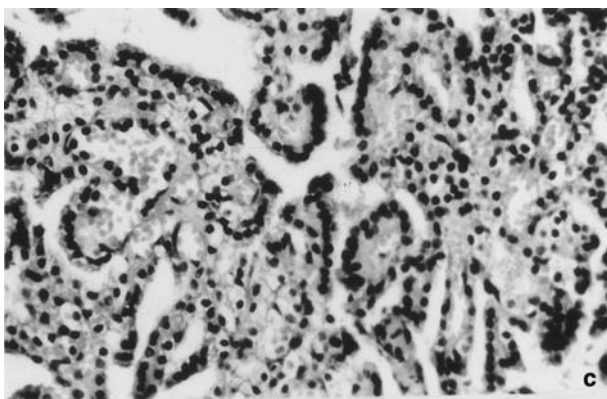
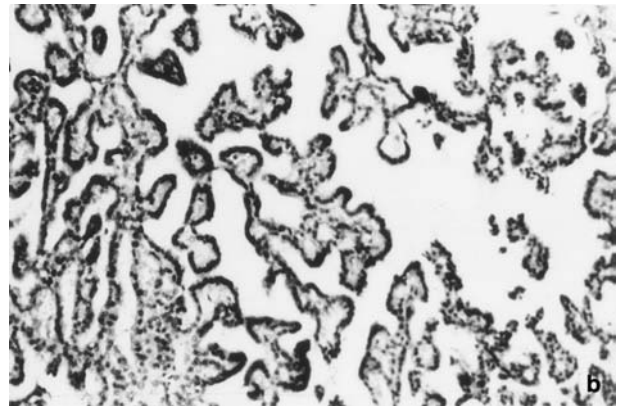
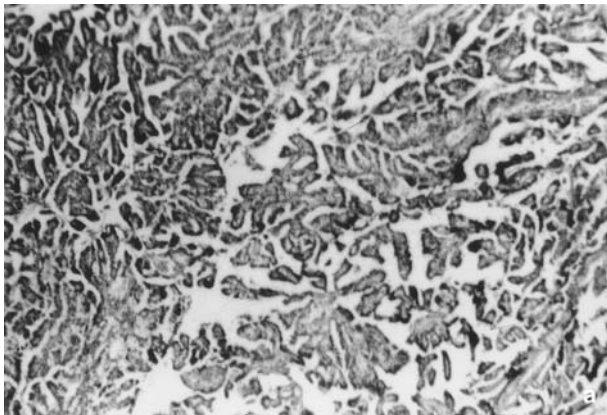


Fig. 5. (a) Choroid plexus papilloma of the right ventricle. Columnar cells rest upon distinct fibrovascular stalks (HE  $\times$  40). (b) Choroid plexus papilloma of the left ventricle (HE  $\times$  100). (c) The epithelial surface of the choroid plexus papilloma (HE  $\times$  200)

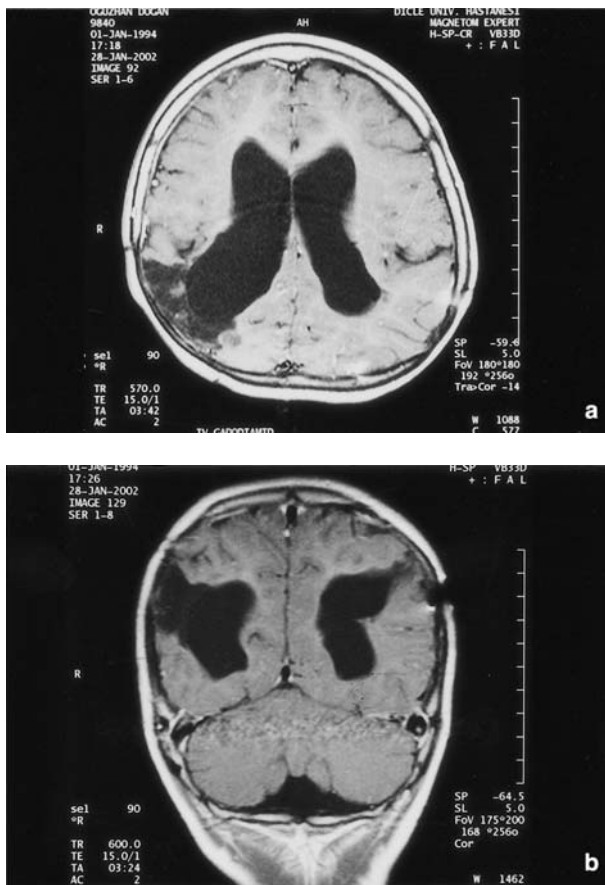


Fig. 6. (a) Postoperative axial MRI demonstrating total resection of the bilateral lateral ventricular trigone tumour without hydrocephalus. (b) Postoperative coronal MRI demonstrating total resection of the bilateral lateral ventricular trigone tumour without hydrocephalus

cells are regularly spaced, domed, cobblestone-like, whereas papillomas have more crowded cells with high nuclear-cytoplasmic ratio. Within the papilloma group, some lesions show significant cytological atypia, increased nuclear-cytoplasmic ratios, and some mitotic figures. These group of lesions are considered as atypical papillomas [5, 19].

With modern neurosurgical practice, a cure should be the aim for all children with CPP. Surgical resection is considered to be the most effective treatment for CPP's, with gross total removal and minimal damage to the surrounding neural elements being the ultimate goal [1, 9, 13, 14, 16, 18, 22, 28, 29]. Choroid plexus papilloma has a very good prognosis when surgery is complete. There is no evidence that adjuvant therapy has any role in the primary management of these children. Management dilemmas of bilateral choroid plexus papillomas are associated with the choice of

surgical procedure, tumour vascularity, the treatment of hydrocephalus and the value of adjuvant therapy.

Ventricular enlargement is seen in association with most but not all CPP's [13]. This may be due to a combination of factors: over production of CSF, obstruction of CSF pathways by the tumour mass, or subarachnoid scarring due to recurrent bleeding from the tumour [6, 12, 13, 16, 20, 26]. Hydrocephalus usually resolves after complete tumour removal and children do not usually require a permanent shunt [25]. The development of microsurgical techniques and meticulous attempts to avoid reflux of bloody CSF into the ventricular system seem to have a favourable impact on hydrocephalus resolution postoperatively [15, 20, 23]. Repeated surgical procedures, which are necessary to control the associated hydrocephalus in bilateral lateral ventricle CPP's, may have played a significant negative role for prognosis. In our patient, hydrocephalus was controlled by bilateral total tumour resection and repeated surgical procedures were not needed to control the associated hydrocephalus.

Because the diagnosis is now facilitated by MRI, a more definitive approach to this condition can be planned. Surgical treatment of the diffuse villous hypertrophy is distinct from bilateral choroid plexus papilloma and differential diagnosis should be made by MRI preoperatively. Craniotomy for open surgical resection of the hypertrophic choroid plexus is associated with considerable morbidity [21]. More recently endoscopic contact coagulation of the hyperplastic choroids plexus has been proposed for avoiding the operative complications of open choroids plexus resection [11, 21].

## Conclusion

Bilateral choroid plexus papilloma is extremely rare and distinct from diffuse villous hypertrophy and their surgical approaches are different from each other. Differential diagnosis should be made by MRI preoperatively. If bilateral choroid plexus papilloma is detected, total surgical resection should be performed. Total surgical removal of the neoplasm not only cures the tumour but also may lead to complete resolution of the hydrocephalus.

## References

1. Ausman JJ, Shrontz C, Chason J, Knighton RS, Pak H, Patel S (1984) Aggressive choroids plexus papilloma. *Surg Neurol* 22: 472-476

2. Berger C, Thiesse P, Lellouch-Tubiana A, Kalifa C, Pierre-Kahn A, Bouffet E (1998) Choroid plexus carcinomas in childhood: clinical features and prognostic factors. *Neurosurgery* 42: 470–475
3. Boyd MC, Steinbok P (1987) Choroid plexus tumours: problems in diagnosis and management. *J Neurosurg* 66: 800–805
4. Britz GW, Kim DK, Loeser JD (1996) Hydrocephalus secondary to diffuse villous hyperplasia of the choroid plexus. Case report and review of the literature. *J Neurosurg* 85(4): 689–691
5. Burger PC, Scheithauer BW (1994) Tumours of the central nervous system. Armed Forces Institute of Pathology, Washington, DC, pp 136–142
6. Chow E, Reardon DA, Shah AB, Jenkins JJ, Langston J, Heide-man RL, Sanford RA, Kun LE, Merchant TE (1999) Pediatric choroid plexus neoplasms. *Int J Radiat Biol Phys* 44(2): 249–254
7. Davis LE (1924) A physio-pathological study of the choroids plexus with the report of a case of villous hypertrophy. *J Med Res* 44: 521–534
8. Di Rocco C, Iannelli A (1997) Poor outcome of bilateral congenital choroids plexus papillomas with extreme hydrocephalus. *Eur Neurol* 37(1): 33–37 (Abstract)
9. Ellenbogen RG, Winston KR, Kupsky WJ (1989) Tumours of the choroid plexus in children. *Neurosurgery* 25: 327–335
10. Greenberg MD (1994) Intraventricular lesions. Greenberg Graphics Inc, Lakeland, pp 203–205
11. Hirano H, Hirahara K, Asakura T, Shimozuru T, Kadota K, Kasamo S, Kasamo S, Shimohonji M, Kimotsuki K, Goto M (1994) Hydrocephalus due to villous hypertrophy of the choroids plexus in the lateral ventricles. Case report. *J Neurosurg* 80(2): 321–323
12. Horská A, Ulug AM, Melhem ER, Filippi CG, Burger PC, Edgar MA, Souweidane MM, Carson BS, Barker PB (2001) Proton magnetic resonance spectroscopy of choroid plexus tumours in children. *J Magn Reson Imaging* 14(1): 78–82
13. James HE (1985) Choroid plexus papillomas. In: Wilkins RH *et al* (eds) *Neurosurgery*, vol 1. McGraw-Hill Book Company, New York, pp 783–785
14. Knierim DS (1990) Choroid plexus tumours in infants. *Pediatr Neurosurg* 16: 276–280
15. Lena G, Genitori L, Molina J, Legatte JRS, Choux M (1990) Choroid plexus tumours in children. Review of 24 cases. *Acta Neurochir (Wien)* 106: 68–72
16. Levy ML, Goldfarb A, Hyder DJ, Gonzales-Gomez I, Nelson M, Gilles FH, McComb JG (2001) Choroid plexus tumours in children: significance of stromal invasion. *Neurosurgery* 48(2): 303–309
17. Matson DD, Crofton FDL (1960) Papilloma of choroids plexus in childhood. *J Neurosurg* 17: 1002–1027
18. Matsuda M, Uzara S, Nakasu S, Handa J (1991) Primary carcinoma of the choroids plexus in the lateral ventricle. *Surg Neurol* 36: 294–299
19. Mc Girr SJ, Ebersold MJ, Scheithauer BW, Quast LM, Shaw EG (1988) Choroid plexus papillomas: long-term follow-up results in a surgically treated series. *J Neurosurg* 69: 843–849
20. Nagib MG, O'Fallon T (2000) Lateral ventricle choroid plexus papilloma in childhood: management and complications. *Surg Neurol* 54: 366–372
21. Philips MF, Shanno G, Duhaime AC (1998) Treatment of villous hypertrophy of the choroids plexus by endoscopic contact coagulation. *Pediatr Neurosurg* 28(5): 252–256
22. Piepmeier JM, Westerveld M, Spencer DD, Sass K (1995) Surgical management of intraventricular tumours of the lateral ventricles. In: Schmidek HH *et al* (eds) *Operative neurosurgical techniques. Indications, methods, and results*, vol 1. WB Saunders Company, Philadelphia, pp 725–742
23. Raimondi AJ, Gutierrez FA (1975) Diagnosis and surgical treatment of choroid plexus papillomas. *Childs Brain* 1: 81–115
24. Rovit RL, Schechter MM, Chodroff P (1970) Choroid plexus papillomas. Observations on radiographic diagnosis. *AJR* 110: 608–617
25. Sanford RA (1995) Surgical management of supratentorial tumours of childhood. In: Schmidek HH *et al* (eds) *Operative neurosurgical techniques. Indications, methods, and results*, vol 1. WB Saunders Company, Philadelphia, pp 571–577
26. Sarkar C, Sharma MC, Gaikward S, Saharma C, Singh VP (1999) Choroid plexus papilloma: a clinicopathological study of 23 cases. *Surg Neurol* 52(1): 37–39
27. Sharma R, Rout D, Gupta AK, Radhakrishnan V (1994) Choroid plexus papillomas. *Br J Neurosurg* 8: 169–177
28. Schijman E, Monges J, Raimondi AJ, Tomita T (1990) Choroid plexus papillomas of the III ventricle in childhood. *Child Nerv Syst* 6: 331–334
29. Spallone A, Pastore FS, Guiffre B (1990) Choroid plexus papillomas in infancy and childhood. *Child Nerv Syst* 6: 71–74
30. Tacconi L, Delfini R, Cantore G (1996) Choroid plexus papillomas: consideration of a surgical series of 33 cases. *Acta Neurochir (Wien)* 138: 802–810
31. Vasquez E, Ball WS, Prenger EC, Castellote A, Crone KR (1991) Magnetic resonance imaging of fourth ventricle choroid plexus neoplasms in childhood. *Pediatr Neurosurg* 17: 48–52
32. Welch K, Strand R, Bresnan M, Cavazzuti V (1983) Congenital hydrocephalus due to villous hypertrophy of the telencephalic choroids plexuses. *J Neurosurg* 59: 172–175
33. Zuccaro G, Sosa F, Cuccia V, Lubieniecky F, Monges J (1999) Lateral ventricle tumours in children: a series of 54 cases. *Childs Nerv Syst* 15(11–12): 774–785

## Comments

Bilateral choroid plexus papillomas are considerably rare; they present specific features and prognosis. The authors report on a case of bilateral choroid plexus papilloma and make an extensive general review of choroid plexus tumours. The review is exhaustive and well organised but would have been of more benefit if it had focussed more specifically on bilateral lesions.

*C. di Rocco*

This is an interesting short report which describes the presentation, imaging characteristics and surgical treatment of a young child with bilateral choroid plexus papillomas. This case is one of a very limited number of bilateral papillomas in the literature.

Another very rare and similar condition is that of diffuse villous hypertrophy. While the authors indicate in their report that there are clear features to distinguish this condition from bilateral papillomas, I suspect in reality the nomenclature is dictated by size rather than by any specific radiological or pathological features. As the authors show, the treatment of the concomitant hydrocephalus with which these patients present can be achieved by excising the lesion.

*P. Chumas*

Correspondence: Tahsin Erman, M.D., Çukurova University School of Medicine, Department of Neurosurgery, Balcalı-Adana, 01330 Turkey.