

## Original Article

# Laparoscopic Transabdominal Preperitoneal Approach for Inguinal Hernia Repair: A Five-Year Experience at a Single Center

ZDRAVKO PERKO<sup>1</sup>, MISLAV RAKIĆ<sup>2</sup>, ZENON POGORELIĆ<sup>3</sup>, NIKICA DRUŽIJANIĆ<sup>1</sup>, and JASENKA KRALJEVIĆ<sup>1</sup>

Departments of <sup>1</sup>Surgery and <sup>3</sup>Pediatric Surgery, University Hospital Split and Split University School of Medicine, Spinčićeva 1, 21 000 Split, Croatia

<sup>2</sup>Department of Surgery, Dubrava Clinical Hospital, Avenija Gojka Šuška 6, 10 000 Zagreb, Croatia

### Abstract

**Purpose.** Laparoscopic hernia repair has emerged as an effective alternative method for treating inguinal hernias. It has several significant advantages over the tension-free open repair now in use. In this report we summarize our laparoscopic hernia repair results and recommendations.

**Methods.** The transabdominal preperitoneal (TAPP) procedures for groin hernias performed between January 2003 and January 2008 at a single center were analyzed retrospectively. Individual surgeon performances were compared to determine whether the rates of complications were related to the level of surgeon experience.

**Results.** A total of 312 TAPP procedures were reviewed, and 284 (91%) of the patients were followed retrospectively. There were 266 (85.25%) males and 46 (14.75%) females. The average age was 57.4 years. The mean length of hospital stay was 2.1 days. The mean duration of surgery was 35 min. Six (1.92%) intraoperative and seven (2.24%) postoperative complications were noted. Two recurrences occurred (0.70%).

**Conclusions.** Laparoscopic TAPP hernia repair has proven to be an efficient method for the treatment of groin hernias at our institution. Most patients can be treated as day-cases, namely they are hospitalized for 1 day, and they demonstrate a low recurrence rate (0.70%). Such low morbidity makes TAPP an attractive method for the routine treatment of groin hernias.

**Key words** Inguinal hernia · Inguinal hernioplasty · Laparoscopy · Transabdominal preperitoneal approach · Learning curve

### Introduction

Inguinal hernias are a common medical problem that can significantly decrease the quality of life. Laparoscopic inguinal hernia repair has shown a great deal of promise as a treatment for the condition.<sup>1</sup> Several studies have demonstrated advantages of laparoscopic over open repair with regard to reduced postoperative pain and an earlier return to work and normal activities.<sup>2–6</sup> Data concerning the recurrence of hernias remain controversial, with rates ranging from 0% to 15% for laparoscopic repair as compared with rates of 0.1% to 4.9% reported for repair using an open technique.<sup>7</sup> The limitations and complications of transabdominal preperitoneal (TAPP) hernia repair have been discussed extensively. However, reports in the literature tend to focus on multicenter, retrospective studies, and assess different techniques simultaneously.<sup>8–17</sup>

The complication rates for TAPP were no higher than those reported for conventional repairs, but new and sometimes unique complications were seen. The data available show an incidence of complications ranging from 6.3% to 15.3% during the learning curve, which decreases to between 2.5% and 7.4% when performed by surgeons more experienced in laparoscopic hernia repair.<sup>8–17</sup> However, these findings are fragmented and do not provide a coherent basis for clear conclusions to be drawn. Furthermore, when repairing recurrent hernias, it does offer an advantage of transabdominal dissection through a previously nondamaged area. Bilateral hernias can be repaired without any additional incisions, and recovery for these patients is much faster than for open procedures. However, unlike laparoscopic cholecystectomy, laparoscopic herniorrhaphy has not been embraced by the surgical community mainly because it requires proficient laparoscopic techniques, and for this reason there is a longer learning curve. The laparoscopic operation exposes the patient to potential complications, mainly with respect to possible visceral

injury, which is not common in an open anterior herniorrhaphy. However, surgical experience might minimize complications.

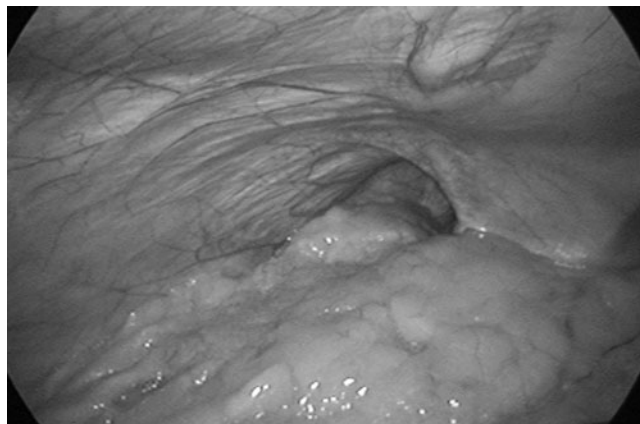
Our experience is based on a homogeneous series of cases treated by a single surgical team at our institution using the TAPP technique and working within standardized operating times. The patients were strictly scheduled for follow-up evaluation, and all complications were noted. In this report, we summarize our laparoscopic hernia repair results and recommendations of other institutions considering using this technique.

### Patients and Methods

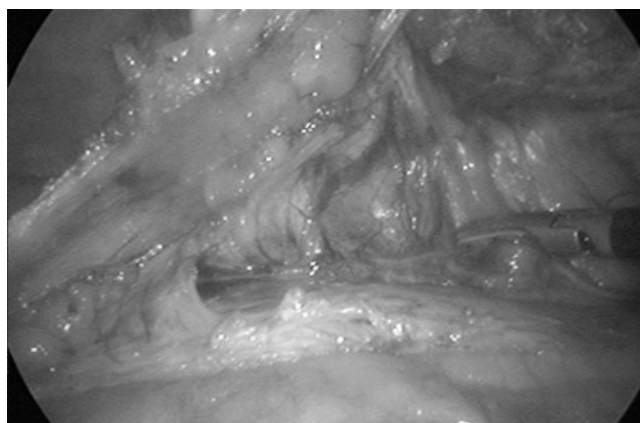This single-center retrospective study analyzes surgery outcomes data collected from patients with inguinal hernias who underwent TAPP hernioplasty in the Department of Digestive Surgery, University Hospital, Split, Croatia, between January 2003 and January 2008. There were no selection criteria for inclusion or exclusion of patients. We collected patient data regarding gender, age, hernia type, duration of hospitalization, length of surgery, complications, and recurrence rates. Patients were asked to fill in a questionnaire after the procedure about their satisfaction with this type of surgery. The surgeon decided the type of intervention used for all of the procedures, with patient consent. If patients did not choose TAPP, they underwent Lichtenstein's repair under local or spinal anesthesia. Each patient made the final decision on the type of procedure that they received.

The follow-up program included postoperative clinical evaluations done at 1, 6, and 12 months after the operation. All intraoperative and postoperative complications were recorded, even those that appeared to be clinically insignificant, so that their true importance could be assessed over time.

General anesthesia was routinely used. During the procedure, all patients are placed in the supine position with both arms tucked against their sides. The patients are also placed in a Trendelenburg position ( $10^{\circ}$ – $20^{\circ}$ ) so that the viscera fall away from the inguinal areas, temporarily reducing the hernia (Fig. 1). Video monitors are placed at the foot of the operation table. The surgeon stands on the side opposite to the hernia, and the assistant surgeon stands opposite the surgeon. Pneumoperitoneum is established through a small supraumbilical incision using a Veress needle. A 10-mm umbilical trocar and laparoscope (Olympus, Tokyo, Japan) is inserted, and the abdominal cavity is examined. All intra-abdominal findings are noted (intra-abdominal pathology, and inguinal hernia defects and hernial sacs). If an asymptomatic hernia sac is identified on the opposite side, our protocol mandates its repair, even though if at the time



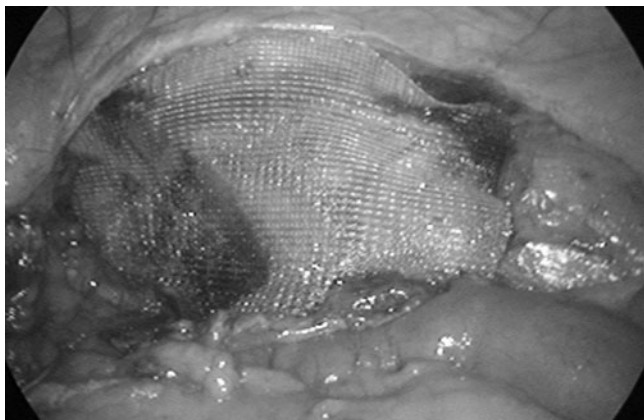
**Fig. 1.** Indirect inguinal hernia



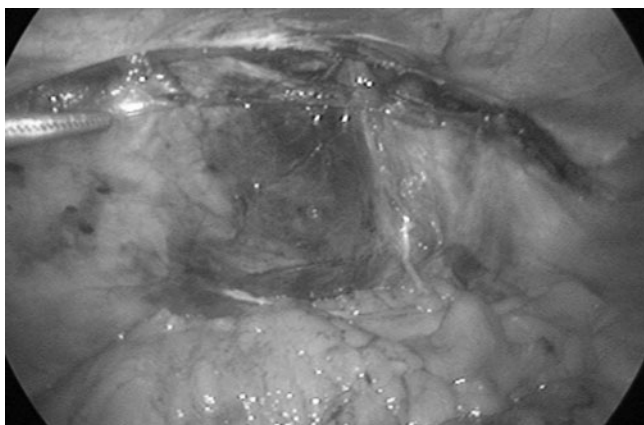
**Fig. 2.** Incision of the peritoneum using Ultracision

we are unsure of its exact clinical significance. Two lateral 5-mm trocars (Olympus) are usually placed in the medioclavicular line lateral to the umbilicus. The exact placement depends on whether the repair is to be unilateral or bilateral. The laparoscope is pointed toward the inguinal canal. The peritoneal defect or hernia is identified, then the lateral umbilical ligament and inferior epigastric vessels are located. A peritoneal incision is made using an Ultracision (Ethicon Endo-Surgery, Cincinnati, OH, USA) at output level 5. The incision is extended from the lateral aspect of the inguinal region to the lateral umbilical ligament. For obese patients, this ligament may have to be transected in order to obtain additional exposure. Peritoneal flaps are then detached (Fig. 2).

Direct and small indirect hernial sacs are fully reduced. Larger indirect sacs are partially dissected and resected. The distal part of a large sac is left in situ. The anatomy is then defined (Cooper's ligament is exposed, as well as the inferior epigastric vessels and the spermatic cord). The iliac vessels are not dissected, but their



**Fig. 3.** Mesh and tack placement



**Fig. 4.** Reapproximation of the peritoneum

positions are clearly identified. Medially, the dissection is carried to the symphysis pubis. A 15 × 10-cm mesh (Proceed, Ethicon Endo-Surgery) is inserted via the 10-mm trocar into the abdominal cavity and deployed over the inguinal region. The mesh is attached to Cooper ligament, around and lateral to the inferior epigastric vessels, using tacks (Protac; Covidien, Mansfield, MA, USA) (Fig. 3).

The medial border of the mesh is adjacent to the symphysis pubis, and the upper part is placed at least 2–3 cm over the hernial defect and internal ring. The peritoneum is then reapproximated with the tacks (Protac; Covidien) (Fig. 4). If there are bilateral hernias, the same procedure is performed on the opposite side using a second mesh. The operation is completed by closing the port site incision skin with sutures.

## Results

During the 5-year period from January 2003 to January 2008, we performed 312 laparoscopic hernia repairs, 266

**Table 1.** Patients' characteristics and procedure statistics

Characteristic		
Patients ( <i>N</i> )	312	
Age, years (range)	57.4	20–86
Male	266	85.25%
Female	46	14.75%
Operation time (total), min (range)	35	25–48
Operation time (unilateral), min (range)	27	21–39
Operation time (bilateral), min (range)	38	33–48
Mean hospital stay, days (range)	2.1	1–7
Intraoperative complications, <i>n</i> (%)	6	1.92%
Postoperative complications, <i>n</i> (%)	7	2.24%
Recurrence, <i>n</i> (%)	2	0.70%

**Table 2.** Distribution of hernias in operated patients

Hernia type	No. of patients		%	
Inguinal	Right	298	94	30.12
	Bilateral		88	28.20
	Left		56	17.95
	Recurrence		60	19.24
Femoral		12	3.84	
Scrotal		2	0.65	
Total number		312	100	

in male patients and 46 in female patients (Table 1). Of these patients, 284 (91%) were monitored in follow-up visits, and 28 (9%) patients were lost to follow-up. The distribution of hernia types in the patients is reported in Table 2. All 312 operations were finished successfully. Six (1.92%) intraoperative and seven (2.24%) postoperative complications occurred during the 5-year period. Complications and the way they were treated are listed in Table 3. All complications were resolved laparoscopically. The most common intraoperative complications were bleeding from the trocar sites or from epigastric vessels. The most common postoperative complications were wound hematoma and wound infection (Table 3). After treatment of these complications, there were no additional complications in these patients. Two recurrences occurred (0.70%). The first patient recurrence occurred 2 years after the surgery and the second occurred 3 years after the surgery. The mean duration of surgery was 35 min (range 25–48 min) and the mean length of the postoperative hospital stay was 2 days (range 1–7 days).

## Discussion

The TAPP approach appears to offer potential advantages, but in practice these advantages over the tension-free open repair are not always realized. Furthermore, concurrent with the development of laparoscopic ingui-

**Table 3.** Intraoperative and postoperative complications

Complication		Treatment	No. of patients (%)
Intraoperative	Bleeding from epigastric vessels	Clip application	2 (0.64)
	Deserosation of the sigmoid colon	Sutured	1 (0.32)
	Bladder injury	Sutured	1 (0.32)
	Bleeding from trocar sites	Electrocoagulation	2 (0.64)
Postoperative	Wound hematoma	Incision, evacuation of hematoma	2 (0.64)
	Wound infection	Incision, evacuation of pus, antibiotics	2 (0.64)
	Scrotum hematoma	Conservative treatment	1 (0.32)
	Consecutive hydrocele	Operation (Winkelmann procedure)	1 (0.32)
	Pneumonia	Antibiotics	1 (0.32)

nal herniorrhaphy, open hernia repair has evolved into a tension-free mesh repair associated with fewer postoperative complications and a more rapid recovery. At present, the two most common techniques for laparoscopic inguinal hernia repair are the TAPP approach and the totally extraperitoneal (TEP) approach. Both approaches involve the insertion of mesh into the preperitoneal space. The ultimate choice between the TAPP and TEP approach rests with the surgeon, and is made according to the careful surgical and medical history, and assessment of risk factors and quality of life. The recurrence rates are very low after both open and laparoscopic mesh repairs, and randomized studies have not shown any significant difference with regard to either adverse effects or recurrence.<sup>10,18,19</sup>

In a TEP repair the peritoneum is not penetrated, and the trocars are placed preperitoneally in a space created between the peritoneum and the fascia. The TEP approach involves the creation of a preperitoneal space posterior to the inguinal canal either with a telescope or, more commonly, with a preperitoneal distention balloon system. As in a TAPP repair, the mesh is tacked to key structures.<sup>1</sup> The major advantage of the TEP approach is avoidance of entry into the peritoneal cavity, and thus a decrease in the potential risk of intraperitoneal adhesions to the mesh, possible bowel injury, and obstructions. Although TEP may provide some advantages over TAPP in terms of postoperative pain and reduced potential intraperitoneal complications, it requires a high level of technical skill associated with a considerable learning curve.<sup>1,20,21</sup> In view of all research on the subject, the TAPP approach is easier to learn and perform than the TEP approach. In our series of 312 hernia repairs we found that the TAPP approach is technically less complicated, provides easier identification of anatomic landmarks, and does not require additional equipment besides that needed for a laparoscopic cholecystectomy.

Several studies have demonstrated a distinct advantage of laparoscopic hernia repair over open mesh repair in terms of reduced postoperative pain and an

earlier return to work and normal activities for the patient.<sup>1,3,4,18,22</sup> Nevertheless, the laparoscopic approach has been slow in gaining popularity among surgeons for several reasons. First, more advanced technical skills are required compared with a conventional Lichtenstein repair. In addition, the long-term results of laparoscopic repair were largely unknown. Moreover, TAPP presents the potential for complications not seen with an open repair. Finally, the surgery itself has undergone considerable refinement in both technique and equipment used. At present, the majority of general surgeons have extensive experience in performing laparoscopic cholecystectomy. However, this knowledge is insufficient to perform a TAPP repair without additional training.

In these previous studies as well as in our present study, large meshes have been used, and this has been shown to correlate with recurrence rates. The choice of mesh must meet the surgeon's needs as well as those of the patient. It must be soft and pliable not only to conform to the patient's anatomy and minimize postoperative stiffness, but also to permit easy insertion through the trocar. Mesh transparency and adhesiveness are also important qualities because wide interstices minimize displacement and help identify structures beneath the mesh. Placement of the mesh behind the epigastric vessels is unnecessary and time consuming. Spiral tacks have replaced staples to fix the mesh into position, and the placement and number of tacks should be consistent. The placement of tacks too close to, or below the ileopubic tract has led to injuries of the lateral femoral cutaneous nerve.<sup>23,24</sup> Careful external abdominal wall pressure will prevent skin penetration by the tack during deployment. Fibrin glue fixation or nonmesh fixation can minimize potential nerve and vascular injuries, but the long-term success rate of these techniques has not been proven.<sup>25,26</sup> Chronic pain and other types of sensory disturbances and discomfort may persist or arise postoperatively.<sup>27</sup> In fact, chronic pain appears to be more common than recurrence of the hernia.<sup>27,28</sup> Following an inguinal hernia repair procedure, more than 30% of all patients who receive an open mesh repair

complained of varying degrees of pain that persisted for at least 1 year postoperatively.<sup>28</sup> In our series, none of the patients presented with postoperative chronic pain.

The Harmonic Scalpel (Ultracision, Ethicon Endo-Surgery) is a very useful tool for laparoscopic surgery<sup>29–34</sup> as well as in laparoscopic inguinal hernia repair.<sup>4</sup> With interrupted usage, we have been able to prevent lateral thermal damage of tissues and thermal injuries of other organs below. Coagulation necrosis, at a standard output power, is greater following a longer application time. Tissue necrosis is also more extensive if the cutting is continuous, compared with interrupted usage with equal duration of application. The minimization of lateral thermal injury is very important, especially when operating near vital areas.<sup>35,36</sup>

Due to the accumulation of experience and technical improvements, complications are now minimal after a laparoscopic hernia repair, but even so, studies indicate comparable complication rates between open and laparoscopic repairs.<sup>3,22</sup> We noted only minor postoperative complications, including wound hematoma, wound infection, scrotum hematoma, bleeding from trocar sites, hydrocele, and pneumonia (Table 3). Open mesh repairs thus appear to have a higher rate of groin hematoma and genital edema.

The main disadvantage of laparoscopic hernial repairs is the additional cost of the equipment required. But the benefits, including a faster recovery and earlier return to work for the patient, outweigh this disadvantage. One of the big advantages of the laparoscopic approach is that it provides an effective means of detecting and repairing a contralateral defect at the time of the operation with only a modest increase in duration of surgery. Therefore, bilateral inguinal hernias can be repaired simultaneously through the same incision by adding only a few minutes to the surgery. This is very cost effective, with unchanged morbidity and recurrence rates.<sup>37–39</sup> Infection rates following the procedure are extremely low, probably because the mesh is placed through the trocar and never touches the skin. As some studies state, the time to do a laparoscopic repair from skin incision to final stitch is as fast as an open mesh repair. In our study, the average duration of surgery was 35 min; 27 min for a unilateral repair and 38 min for a bilateral repair (Table 1). As with laparoscopic cholecystectomy, there is a definite learning curve, but we anticipate that with increasing general laparoscopic experience the learning curve for hernia repair will become shorter.

Recurrence of hernias has been the benchmark by which all repairs are measured. Ridings and Evans reported in their first series of 100 patients an unacceptable 9% recurrence rate.<sup>1</sup> They were inserting a 6 × 5-cm mesh over the site of the hernia, which was stapled to the surrounding tissues. This mesh was not fixed to the symphysis pubis or inguinal ligament. After that the

mesh size was increased to 12 × 7 cm, which immediately reduced the recurrence rate to 2.9%. Since changing to a 15 × 10-cm mesh, no recurrences have been recorded, although the follow-up period is shorter. During this study, we used a 15 × 10-cm mesh and had a very low recurrence rate, with only two (0.70%) patients developing a recurrence. Recurrences occurred at the lateral site, probably because the mesh had been placed too medial. We know that the mesh size was not too small, because we always use the same size of mesh. The two patients with recurrences underwent an open (Lichtenstein's procedure) surgery to repair the recurrence.

## Conclusion

Many surgical techniques for repairing a hernia are available, and a decision about the optimal type of surgery depends on several factors, including age, surgical and medical history, sex, size and type of a hernia (unilateral or bilateral, primary or recurrent, incarcerated or reducible), general medical condition of the patient, and the patient's expectations. When patients are selected properly and surgeons are well-trained and experienced, laparoscopic hernioplasty can achieve excellent results. Because overall outcomes are improved with the surgeon's level of experience, some studies advocate the move toward hernia specialists. A prospective outcome evaluation will determine whether the performance of specialized groups of surgeons can be reproduced.<sup>40</sup> In conclusion, the laparoscopic approach is generally reserved for recurrent and bilateral hernias; however, it is also indicated for cases of a unilateral hernia where the presence of a contralateral hernia is strongly suspected.

## References

1. Ridings P, Evans DS. The transabdominal pre-peritoneal (TAPP) inguinal hernia repair: a trip along the learning curve. *J R Coll Surg Edinb* 2000;45:29–32.
2. Kuhry E, van Veen RN, Langeveld HR, Steyerberg EW, Jeekel J, Bonjer HJ. Open or endoscopic total extraperitoneal inguinal hernia repair? A systematic review. *Surg Endosc* 2007;21:161–6.
3. Saggar VR, Sarangi R. Laparoscopic totally extraperitoneal repair of inguinal hernia: a policy of selective mesh fixation over a 10-year period. *J Laparoendosc Adv Surg Tech A* 2008;18:209–12.
4. Sršen D, Družijanić N, Pogorelić Z, Perko Z, Juričić J, Kraljević D, et al. Quality of life analysis after open and laparoscopic inguinal hernia repair-retrospective study. *Hepatogastroenterology* 2008; 55:2112–5.
5. Takata MC, Duh QY. Laparoscopic inguinal hernia repair. *Surg Clin North Am* 2008;88:157–78.
6. Novitsky YW, Czerniach DR, Kercher KW, Kaban GK, Gallagher KA, Kelly JJ, et al. Advantages of laparoscopic transabdominal preperitoneal herniorrhaphy in the evaluation and management of inguinal hernias. *Am J Surg* 2007;193:466–70.

7. Lovisetto F, Zonta S, Rota E, Bottero L, Faillace G, Turra G, et al. Laparoscopic transabdominal preperitoneal (TAPP) hernia repair: surgical phases and complications. *Surg Endosc* 2007;2: 646–52.
8. Catarci M, Carlini M, Gentileschi P, Santoro E. Major and minor injuries during the creation of pneumoperitoneum: a multicenter study on 12,919 cases. *Surg Endosc* 2001;15:566–9.
9. Duron JJ, Hay JM, Msika S, Gashard D, Domergue J, Gainant A, et al. Prevalence and mechanisms of small intestinal obstruction following laparoscopic abdominal surgery: a retrospective multicenter study. *Arch Surg* 2000;135:208–12.
10. Dedemadi G, Sgourakis G, Karaliotas C, Christofides T, Kouraklis G, Karaliotas C. Comparison of laparoscopic and open tension-free repair of recurrent inguinal hernias: a prospective randomized study. *Surg Endosc* 2006;20:1099–104.
11. Leibl BJ, Schmedt CG, Kraft K, Ulrich M, Bittner R. Scrotal hernias: a contraindication for an endoscopic procedure? Results of a single-institution experience in transabdominal preperitoneal repair. *Surg Endosc* 2000;14:289–92.
12. Mahon D, Decadt B, Rhodes M. Prospective randomized trial of laparoscopic (transabdominal preperitoneal) vs. open (mesh) repair for bilateral and recurrent inguinal hernia. *Surg Endosc* 2003;17:1386–90.
13. McCormack K, Wake B, Perez J, Fraser C, Cook J, McIntosh E, et al. Laparoscopic surgery for inguinal hernia repair: systematic review of effectiveness and economic evaluation. *Health Technol Assess* 2005;9:1–203.
14. Lohsiriwat V, Sridermma W, Akaraviputh T, Boonnuch W, Chinsawangwatthanakol V, Methasate A, et al. Surgical outcomes of Lichtenstein tension-free hernioplasty for acutely incarcerated inguinal hernia. *Surg Today* 2007;37:212–4.
15. Onofrio L, Cafaro D, Manzo F, Cristiano SF, Sgromo B, Ussia G. Tension-free laparoscopic versus open inguinal hernia repair. *Minerva Chir* 2004;59:369–77.
16. Ramshaw B, Shuler FW, Jones HB, Duncan TD, White J, Wilson R, et al. Laparoscopic inguinal hernia repair: lessons learned after 1,224 consecutive cases. *Surg Endosc* 2001;15:50–4.
17. Smith JR, Demers ML, Pollack R, Gregory S. Prospective comparison between laparoscopic preperitoneal herniorrhaphy and open mesh herniorrhaphy. *Am Surg* 2001;67:115–7.
18. Vidović D, Kirac I, Glavan E, Filipović-Cugura J, Ledinsky M, Bekavac-Beslin M. Laparoscopic totally extraperitoneal hernia repair versus open Lichtenstein hernia repair: results and complications. *J Laparoendosc Adv Surg Tech A* 2007;17:585–90.
19. Payne JH, Grininger LM, Izawa MT, Podoll EF, Lindahl PJ, Balfour J. Laparoscopic or open inguinal herniorrhaphy? *Arch Surg* 1994;129:973–9.
20. Catani M, De Milito R, Pietroletti R, Chiaretti M, Spaziani E, Leardi S, et al. Is there a place for intraperitoneal onlay mesh repair (IPOM) of inguinal hernia among laparoscopic techniques? *Hepatogastroenterology* 2004;51:1387–92.
21. Haidenberg J, Kendrick ML, Meile T, Farley DR. Totally extraperitoneal (TEP) approach for inguinal hernia: the favorable learning curve for trainees. *Curr Surg* 2003;60:65–8.
22. Inukai M, Usui Y, Nomura S. The use of totally extraperitoneal endoscopic hernioplasty for the treatment of groin hernia. *Surg Today* 2004;34:932–6.
23. Lantis JC II, Schwaitzberg SD. Tack entrapment of the ilioinguinal nerve during laparoscopic hernia repair. *J Laparoendosc Adv Surg Tech A* 1999;9:285–9.
24. Broin EO, Horner C, Mealy K, Kerin MJ, Gillen P, O'Brien M, et al. Meralgia paraesthetica following laparoscopic inguinal hernia repair. *Surg Endosc* 1995;9:76–8.
25. Lovisetto F, Zonta S, Rota E, Mazzilli M, Bardone M, Bottero L, et al. Use of human fibrin glue (Tissucol) versus staples for mesh fixation in laparoscopic transabdominal preperitoneal hernioplasty: a prospective, randomized study. *Ann Surg* 2007;245: 222–31.
26. Kathouda N. Use of fibrin sealant for prosthetic mesh fixation in laparoscopic extraperitoneal inguinal hernia repair. *Ann Surg* 2001;233:18–25.
27. Mimica Ž, Pogorelić Z, Perko Z, Sršen D, Stipić R, Dujmović D. Effect of surgical incision on pain and respiratory function after abdominal surgery: a randomized clinical trial. *Hepatogastroenterology* 2007;54:2216–20.
28. Hansen MB, Andersen KG, Crawford ME. Pain following the repair of an abdominal hernia. *Surg Today* 2010;40:8–21.
29. Družijanić N, Perko Z, Sršen D, Pogorelić Z, Schwarz D, Juričić J. Peritonization after laparoscopic abdominoperineal resection for low-rectal carcinoma treatment: surgical technique. *Hepatogastroenterology* 2009;56:1028–31.
30. Družijanić N, Perko Z, Kraljević D, Juričić J, Maras Šimunić M, Bilan K, et al. Harmonic scalpel in transanal microsurgery. *Hepatogastroenterology* 2008;55:356–8.
31. Perko Z, Bilan K, Vilović K, Družijanić N, Kraljević D, Juričić J, et al. Partial cecal necrosis treated by laparoscopic partial cecal resection. *Coll Antropol* 2006;30:937–9.
32. Perko Z, Sršen D, Pogorelić Z, Družijanić N, Kraljević D, Juričić J. Laparoscopic subtotal gastrectomy for gastric carcinoma treatment. *Hepatogastroenterology* 2008;55:814–6.
33. Perko Z, Družijanić N, Bilan K, Pogorelić Z, Kraljević D, Juričić J, et al. Laparoscopic colon surgery: our results. *Coll Anthropol* 2008;32:187–91.
34. Perko Z, Bilan K, Pogorelić Z, Družijanić N, Sršen D, Kraljević D, et al. Acute appendicitis and ileal perforation with a toothpick treated by laparoscopy. *Coll Anthropol* 2008;32:307–9.
35. Perko Z, Pogorelić Z, Bilan K, Tomić S, Vilović K, Krnić D, et al. Lateral thermal damage to rat abdominal wall after Harmonic scalpel application. *Surg Endosc* 2006;20:322–4.
36. Pogorelić Z, Perko Z, Družijanić N, Tomić S, Mrkljić I. How to prevent lateral thermal damage to tissue using the harmonic scalpel: Experimental study on pig small intestine and abdominal wall. *Eur Surg Res* 2009;43:235–40.
37. Lau H, Patil NG, Yuen WK. A comparative outcome analysis of bilateral versus unilateral endoscopic extra-peritoneal inguinal hernioplastics. *J Laparoendosc Adv Surg Tech A* 2003;13:153–7.
38. Schmedt CG, Daubler P, Leibl BJ, Kraft K, Bittner R. Laparoscopic Hernia Repair Study Team. Simultaneous bilateral laparoscopic inguinal hernia repair: an analysis of 1336 consecutive cases at a single center. *Surg Endosc* 2002;16:240–4.
39. Shatari T, Nozawa K, Mieno K, Kodaira S. A new method of peritoneal closure following laparoscopic herniorrhaphy. *Surg Today* 1998;28:866–7.
40. Butler RE, Burke R, Schneider JJ, Brar H, Lucha PA. The economic impact of laparoscopic inguinal hernia repair: results of a double-blinded, prospective, randomized trial. *Surg Endosc* 2007; 21:387–90.