



Does pre-operative multifidus morphology on MRI predict clinical outcomes in adults following surgical treatment for degenerative lumbar spine disease? A systematic review

Joe E. Jermy^{1,2} · Phil C. Copley¹ · Michael T. C. Poon^{1,2} · Andreas K. Demetriades^{1,2}

Received: 11 October 2019 / Accepted: 11 April 2020 / Published online: 23 April 2020
© The Author(s) 2020

Abstract

Aim Low back pain (LBP) resulting from degenerative lumbar spine disease is a leading contributor to global disability. Changes in the morphology of the lumbar multifidus muscle on magnetic-resonance imaging (MRI) are associated with worse LBP and disability, but the association between multifidus morphology and post-operative outcomes is not known. The purpose of this systematic review is to examine the relationship between pre-operative multifidus morphology and post-operative changes in pain and disability.

Methods We performed a systematic search using the Cochrane Library, EMBASE, MEDLINE, CINAHL and Scopus databases covering the period from January 1946 to January 2018. The literature was searched and assessed by independent reviewers according to the Preferred Reporting Items for Systematic Reviews and Meta-Analysis (PRISMA) statement. All relevant papers were assessed for risk of bias according to the Quality in Prognosis Studies tool.

Results The initial search yielded 436 studies, of which 6 studies were included in the analysis. Four studies were at a low risk of bias. These studies included a total of 873 patients undergoing spinal surgery. An association between low fat infiltration and greater improvement in LBP and disability following surgery was identified. There was insufficient evidence to identify a relationship between cross-sectional area (CSA) and LBP or disability.

Conclusions This systematic review found evidence for an association between low multifidus fat infiltration on MRI at baseline and greater reductions in measures of LBP and disability following surgical treatment. There is also limited evidence for an association between larger pre-operative multifidus CSA and improvements in disability, but not pain. The findings of this review should be interpreted with caution due to the small quantity of the available literature.

Keywords Low back pain · Degenerative lumbar spine disease · Multifidus morphology · Spinal surgery · Magnetic resonance imaging

Introduction

Low back pain (LBP) is a common and debilitating health problem. It is the leading contributor to global disability, and up to 80% of the population will experience at least one episode in their lifetime [1, 2].

Despite its prevalence, the aetiology of most LBP is uncertain. Trauma, malignancy, infection and other systemic diseases account for approximately 15% of instances, with the majority of remaining cases having no specific cause [3]. A meta-analysis by Endean et al. [4] found that disc degeneration and protrusion, nerve root compression and high-intensity zones on magnetic-resonance imaging (MRI) are reliably associated with non-specific LBP. Additionally, recent evidence suggests that multifidus muscle morphology on MRI is associated with LBP. The multifidus acts to both rotate and stabilise the lumbar spine. Altered morphology, specifically a smaller functional cross-sectional area, in the form of increased fat infiltration or smaller total cross-sectional area, may contribute to LBP and poor function [5–7]. In this text, ‘degenerative lumbar spine disease’ is used to

✉ Andreas K. Demetriades
andreas.demetriades@gmail.com

¹ Edinburgh Spinal Surgery Outcomes Study Group,
Department of Neurosurgery, Western General Hospital,
Edinburgh, United Kingdom

² University of Edinburgh School of Medicine, Western
General Hospital, Edinburgh, United Kingdom

refer to this varied group of pathologies that may ultimately lead to segmental instability, radiculopathy, LBP and diminished function.

Current guidelines suggest that LBP without a specific cause should be managed conservatively through multidisciplinary rehabilitation and pharmacologic therapy where possible [8, 9]. Alternatively, in cases where conservative treatment has failed or in those with concurrent spinal stenosis or radiculopathy, surgical management may be considered [8]. At present, there is some evidence to suggest that changes in the morphology of multifidus following a surgical procedure are associated with worse clinical outcomes, although the magnitude of this effect is unclear [10–14]. Furthermore, the association between the pre-operative morphological condition of multifidus and post-operative clinical outcomes is not well described [15–19].

MRI is the preferred imaging modality to assess spinal pathology and guide suitability for surgical management. Additionally, MRI is a valid method of investigating multifidus musculature, with grading methods using either fat infiltration [20–23] or total cross-sectional area [24] to assess muscle quality. Therefore, pre-operative multifidus morphology on MRI may be a factor influencing clinical outcomes for those with degenerative lumbar spine disease.

Objectives

The objective of this review is to investigate the association between pre-operative multifidus morphology on MRI and post-operative clinical outcome measures of LBP or disability after surgery, in adults with degenerative lumbar spine disease.

Methods

Protocol and registration

The protocol for this review was registered with the PROSPERO systematic review protocol registry (https://www.crd.york.ac.uk/PROSPERO/display_record.php?ID=CRD42018090577).

Eligibility criteria

The review included any published cohort studies and randomised control trials. Studies were included if they examined adults with acute or chronic lumbar spinal pain or radicular leg pain that were managed surgically for treatment of low back pain or radiculopathy. Studies were excluded if they examined asymptomatic adults or those with non-spinal lumbar back or leg pain, such as cancer-related back pain,

pregnancy-related back pain, infection, inflammatory arthritis, stroke, cerebral palsy, or systemic neurological disease. Reviews, commentaries, conference abstracts were excluded.

Clinical and outcome variables

The aim of this review was to identify the longitudinal association between pre-operative multifidus morphology and change in clinical outcome measures of low back pain or disability pre-operatively and at follow-up after surgical treatment. Clinical outcome measures included were pain (measured using a visual analogue scale, McGill pain questionnaire, or a self-efficacy questionnaire), disability (measured using the Oswestry disability index, the Roland-Morris disability questionnaire, a patient-specific functional scale, or equivalent index), work status (defined as return to work or school at follow-up) and health-related quality of life (measured using the euroQOL-5D or equivalent questionnaire).

Information sources

We searched the Cochrane Library, EMBASE (1980 to January 2018), MEDLINE (1946 to January 2018), CINAHL (1937 to January 2018), Web of Science Core Collection (1900 to January 2018), and Scopus (1970 to January 2018) databases. There were no publication year restrictions.

Search

The search was carried out on 24 January 2018, and included keywords such as “back pain”, “magnetic resonance imaging”, “paraspinal muscle”, “multifidus” and “therapeutics”. The search strategies for each database are detailed in our supplemental materials.

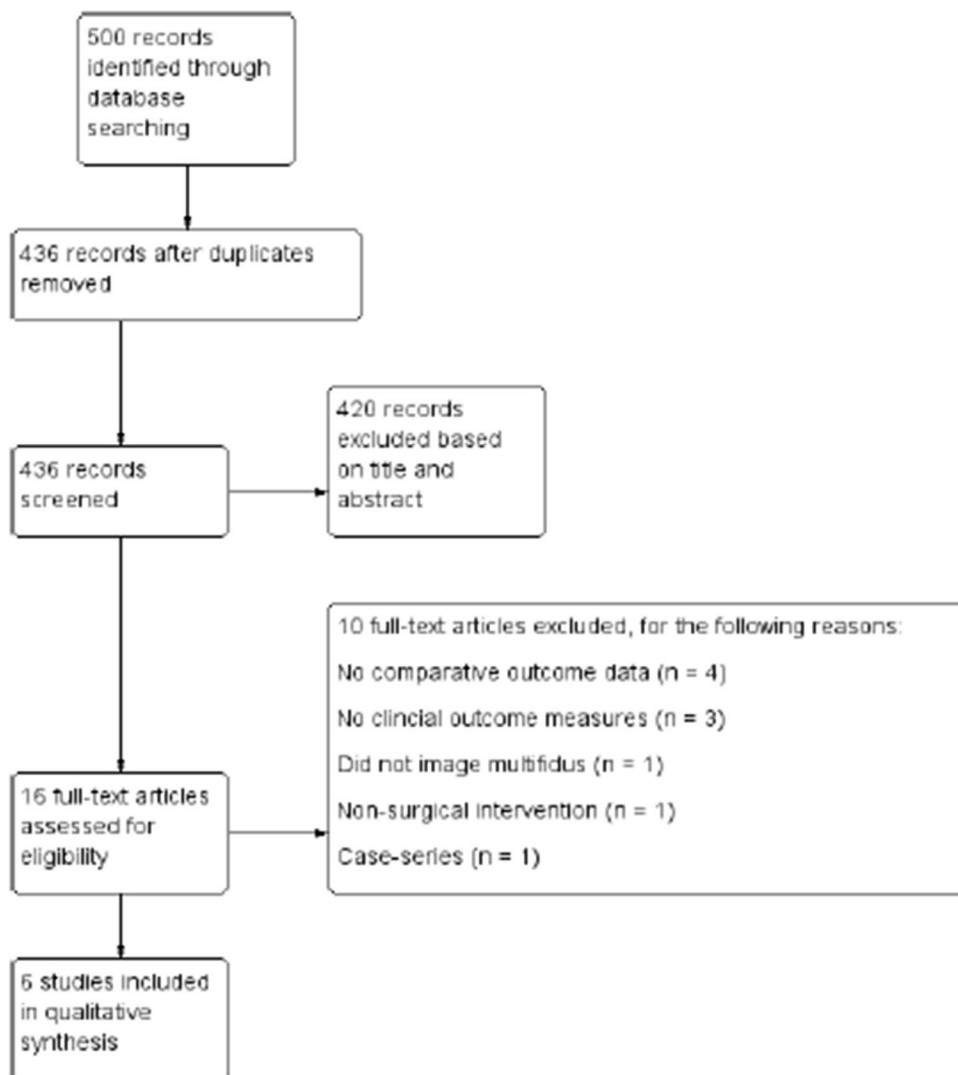
Study selection

We screened titles and abstracts for relevant articles retrieved from the electronic search according to the eligibility criteria detailed above. Full-text articles that were considered relevant were obtained where possible and then assessed in the same manner. The study selection process is illustrated in Fig. 1.

Data collection process

Data were collected using a data extraction form adapted from the Cochrane Public Health Group Data Extraction Template [25]. These data were then entered into a word processing software package. For each paper, two authors completed the data extraction form independently. Disagreements were adjudicated by a third author.

Fig. 1 PRISMA diagram showing the flow of studies through phases of the review



Data items

The data extracted were: study design, method of recruitment, sampling technique, participant demographics, disease examined, intervention performed, method of multifidus morphology measure (cross-sectional area or fat infiltration on MRI) and pre- and post-operative clinical outcome measures.

Risk of bias in individual studies

Risk of bias was assessed using a modified version of the Quality In Prognosis Studies (QUIPS) tool [26], studies were rated as at high, moderate, or low risk of bias across six domains: (1) study participation, (2) study attrition, (3)

Table 1 Method of assessing overall risk of bias using the QUIPS tool [26]

Overall risk of bias	Number of domains out of the total 6 domains in each category		
	Low	Moderate/ unknown	High
Low risk	6	0	0
	4 or 5	1 or 2	0
Moderate risk	3	3	0
	Any	1	1
High risk	Any	≥ 2	1
	Any	Any	≥ 2
	Any	≥ 4	Any

measurement of multifidus morphology, (4) outcome measures, (5) study confounding and (6) statistical analysis and reporting. Overall risk of bias was determined based on the number of domains at moderate or high risk (Table 1). Two authors completed the risk of bias assessment independently, and any disagreements were adjudicated by a third author.

Summary measures

Level of fat infiltration was grouped as “low” (participants with no fat infiltration and mild fat infiltration) or “high” (participants with moderate and severe fat infiltration). An effect size (ES) was estimated using the standardised mean difference (SMD) for graphical illustration. For each study where a standardised mean difference could not be calculated, the effect size detailed in the individual study was reported.

Synthesis of results

A forest plot using a random effects model was generated for comparison between studies. A meta-analysis could not be performed due to significant heterogeneity between studies. Instead, a narrative synthesis was conducted.

Results

Study selection

Details of study selection are shown in Fig. 1. There were 500 titles retrieved from database searches, and 6 studies were included after screening and eligibility assessment. In total, six studies were included for data extraction and analysis.

Study characteristics

Study characteristics are reported in Table 2. Of the six included studies, three were retrospective cohort studies [16–18], two were prospective cohort studies [15, 19], and one was a secondary analysis of a previous randomised control trial [13]. Two studies examined the effect of pre-operative fat infiltration on improvement in LBP (Visual Analogue Scale [VAS]) only [17, 18], two studies examined the effect of pre-operative fat infiltration on improvement in both LBP (VAS) and disability (Oswestry Disability Index [ODI]) [13, 15], one study examined the effect of both pre-operative fat infiltration and cross-sectional area on improvement in disability (ODI) only [19], and one study examined the effect of pre-operative cross-sectional area on improvement in

disability (ODI) only [16]. No studies examined the effect of multifidus cross-sectional area on LBP rating scales. All included studies examined multifidus morphology using validated methods of imaging and grading; however, only two studies used identical methods of grading [17, 18]. For quantification of fat infiltration, two studies used pixel intensity to estimate grade of fat infiltration [17, 18] and three studies used a semi-quantitative visual method [13, 15, 19]. For measurement of cross-sectional area, both studies used manual tracing of muscle cross-sectional area from a digital image [16, 19].

Risk of bias within studies

The results of the risk of bias assessment are reported in Table 3. Overall, two of the included studies were at high risk of bias [15, 16] and four were considered to be at low risk of bias [13, 17–19]. Generally, the QUIPS tool domains at greatest risk of bias were study confounding with three studies being at moderate-to-high risk of selection bias [15, 16, 18] and study attrition with three studies being at moderate-to-high risk of attrition bias [16–18].

Results of individual studies

The six studies included in this review reported the results for 873 participants in total. Overall, all included studies reported a significant relationship between a measure of pre-operative high-quality multifidus muscle (i.e. low fat infiltration and/or greater total CSA) and greater improvement in at least one clinical outcome at follow-up. One study identified a significant relationship between pre-operative multifidus CSA, but not fat infiltration, and greater improvement in clinical outcomes [19]. The studies included all investigated the association between pre-operative multifidus morphology and post-operative clinical outcomes in different ways, and three different surgical interventions were performed across the six studies. As a result, it was not possible to aggregate the results in the form of a meta-analysis; thus, the data are presented as a narrative review.

Fat infiltration and improvement in low back pain

An association between pre-operative multifidus morphology and change in pain at follow-up was apparent in all four studies investigating this relation, such that low fat infiltration was associated with a greater improvement in pain score when compared with moderate-to-high fat infiltration (Table 4) [13, 15, 17, 18]. Three of these studies were at a low risk of bias [13, 17, 18], and one was at a high risk of bias [15].

Table 2 Characteristics of included studies

Author	Study design	Participants	Age (SD)	Disease(s) examined	Intervention performed	Multifidus morphology measure	Imaging method/grading method	Outcome measure (s)
Gu et al. [17]	Retrospective cohort study	401	52.15 (20.34)	Lumbar disc herniation, lumbar stenosis, or lumbar spondylolisthesis	Discectomy and posterior lumbar interbody fusion (PLIF)	Fat infiltration based on tertile divisions: mild, moderate, or severe	T1 MRI/digital quantification method by Hebert et al. [22]	VAS ¹
Guan et al. [18]	Retrospective cohort study	239	44.65 (range 18–65)	Degenerative spondylolisthesis	PLIF and posterolateral fusion (PLF)	Fat infiltration based on tertile divisions: mild, moderate, or severe	T1 MRI/digital quantification method by Hebert et al. [22]	VAS
Le Huec et al. [15]	Prospective cohort study	64	44.0 (7.0)	Degenerative lumbar discopathy	Total disc replacement	Fat infiltration: grade 1 (normal muscle), grade 2 (muscle interspersed with some fat), grade 3 (as much muscle as fat), or grade 4 (more fat than muscle)	MRi/visual quantification method by Goutallier et al. [20]	VAS and ODI ²
Shin et al. [16]	Retrospective cohort study	20	70.4 (5.43)	Degenerative lumbar spinal disease	Decompression and PLIF	Cross-sectional area of multifidus and erector spinae (combined)	T2 MRI/visual quantification method tested internally	ODI
Storheim et al. [13]	Secondary analysis of an RCT	83	41 (2.7)	Degenerative disc disease and chronic LBP	Total disc replacement	Fat infiltration percentage: Grade 0 (<20%), Grade 1 (20–50%) or Grade 2 (>50%)	T2 MRI/visual quantification method by Sorensen et al. [21]	VAS
Zotti et al. [19]	Prospective cohort study	66	67 (range 29–86)	Central lumbar canal stenosis	Lumbar spinal decompression (up to 3 levels)	Fat infiltration: Grade 0 (no fat streaks), Grade 1 (<10%), Grade 2 (10–50%), or Grade 3 (>50%); and cross-sectional area (cm ²)	MRi/fat infiltration: visual quantification method by Kader et al. [23]. Cross-sectional area: method by Hu et al. [24]	ODI

¹VAS Pain measured using a visual analogue scale²ODI Oswestry Disability Index

Table 3 Results of risk of bias assessment across the 6 domains of the QUIPS tool [26]

Author	Participation	Attrition	Prognostic factor measure	Outcome measure	Study confounding	Statistical analysis and reporting
Gu et al. [17]	Low	Moderate	Low	Moderate	Low	Low
Guan et al. [18]	Low	Moderate	Low	Low	Moderate	Low
Le Huec et al. [15]	Moderate	Low	High	Moderate	High	High
Shin et al. [16]	High	High	Moderate	Moderate	High	Moderate
Storheim et al. [13]	Low	Low	Low	Low	Low	Low
Zotti et al. [19]	Low	Low	Low	Low	Low	Low

Table 4 Studies examining pre-operative multifidus fat infiltration and pain

Study	Follow-up (months)	Results	Risk of bias
Gu et al. [17]	48	A significant difference in mean low back pain VAS score (0–10) change was observed between the 3 groups ($p < 0.044$) Low fat infiltration = 4.06 ± 1.33 Moderate fat infiltration = 2.05 ± 1.77 High fat infiltration = 2.99 ± 1.97	Low
Guan et al. [18]	46	A significant difference in mean low back pain VAS score (0–10) change was observed between the 3 groups ($p < 0.001$) Low fat infiltration = 1.91 ± 1.84 Moderate fat infiltration = 1.11 ± 1.25 High fat infiltration = 1.00 ± 1.56	Low
Le Huec et al. [15]	24	Pre-operative fat infiltration at [Kader] grades 1 and 2 leads to a better outcome than grades 3 and 4 ($p = 0.006$)	High
Storheim et al. [13]	24	Adjusted multivariate regression analysis revealed a significant increase in pain scores (VAS 0–100) in grade 1, 2 pre-treatment multifidus versus grade 0 pre-treatment multifidus ($p < 0.04$) Unstandardised beta = 15.36 (0.92–29.79)	Low

Table 5 Studies examining pre-operative multifidus fat infiltration and disability

Study	Follow-up (months)	Results	Risk of bias
Le Huec et al. [15]	24	Pre-operative fat infiltration at [Kader] grades 1 and 2 leads to a better outcome than grades 3 and 4 ($p = 0.006$)	High
Storheim et al. [13]	24	Adjusted multivariate regression analysis revealed a significant increase in ODI scores in grade 1, 2 pre-treatment multifidus versus grade 0 pre-treatment multifidus ($p < 0.01$) Unstandardised beta = 10.39 (2.50–18.28)	Low
Zotti et al. [19]	24	Subjects with lower Kader grade ($n = 19$) demonstrated a trend toward greater improvement in the ODI scores compared to those with higher Kader grades ($n = 47$); however, this did not reach statistical significance	Low

Table 6 Studies investigating pre-operative multifidus cross-sectional area and disability

Study	Follow-up (months)	Results	Risk of bias
Shin et al. [16]	14	The CSA of the paravertebral muscle at the L3–4 and L4–5 levels showed a negative correlation with the post-operative ODI L3–4: $r = -0.582$ ($p < 0.01$) L4–5: $r = -0.568$ ($p < 0.01$)	High
Zotti et al. [19]	24	Comparing low ($< 8.5 \text{ cm}^2$) and high ($\geq 8.5 \text{ cm}^2$) LMM CSA cohorts revealed that only 32% of the low CSA cohort reported an improvement in ODI $> 40\%$, whereas 68% of those with a high CSA had ODI improvement $> 40\%$ ($p < 0.006$)	Low

Fat infiltration and improvement in disability

Evidence for an association between multifidus fat infiltration and improvement in disability is conflicting (Table 5). Of the three studies investigating this relationship, one study at high risk of bias [15] and one study at low risk of bias [13] reported greater reductions in disability at follow-up in those with low fat infiltration compared to moderate-to-high fat infiltration pre-operatively.

Cross-sectional area and improvement in disability

There is limited evidence to suggest a greater multifidus cross-sectional area is associated with an improvement in disability at follow-up (Table 6). One high-risk study identified a moderate correlation between increasing CSA and lower post-operative ODI at follow-up [16], and one low-risk study identified those with a CSA $> 8.5 \text{ cm}^2$ were more likely to report an improvement in ODI $> 40\%$ compared to those with a CSA $< 8.5 \text{ cm}^2$ [19].

Cross-sectional area and improvement in low back pain

No studies investigated the association between pre-operative multifidus CSA and improvement in LBP at follow-up.

Synthesis of results

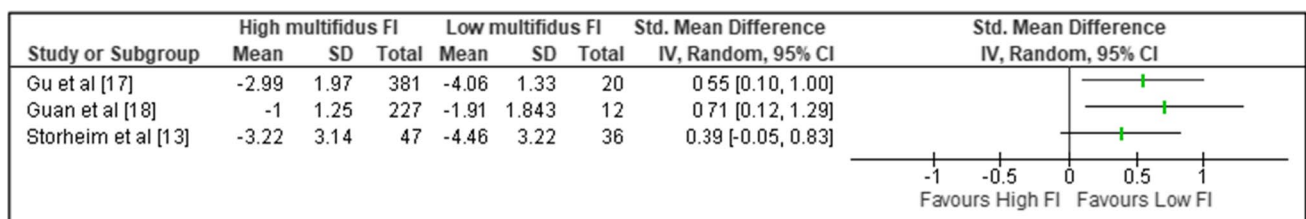
Three of the four studies examining the association between pre-operative multifidus fat infiltration and change in pain (VAS) reported sufficient data for comparison; however, a meta-analysis could not be performed due to significant heterogeneity between studies [13, 17, 18]. A forest plot without the pooled estimate is reported in Fig. 2.

Discussion

The findings of this review suggest a trend for better outcomes following surgery if pre-operative multifidus quality is higher. Although all studies reported improvements in pain and disability after surgery regardless of muscle quality, greater improvement was demonstrated with either low fat infiltration [13, 15, 17, 18] or large.

cross-sectional area [16, 19]. The strongest evidence was for patients with low multifidus fat infiltration having a greater reduction in LBP at follow-up when compared to patients with moderate-to-high fat infiltration [13, 15, 17, 18].

The evidence for low fat infiltration and post-operative reduction in disability is weaker, with only two out of three studies demonstrating a greater reduction compared to moderate-to-high fat infiltration [13, 15, 19]. Patients with larger multifidus CSA demonstrated greater improvement

**Fig. 2** Forest plot showing association between fat infiltration (FI) and post-operative decrease in pain (VAS/10)

in disability; however, only two studies investigated this relationship [16, 19] and no evidence investigating multifidus CSA and post-operative reduction in LBP could be identified. As a result, the evidence for multifidus CSA as a prognostic factor is limited.

Outwith surgical treatment, both smaller CSA and greater level of fat infiltration in the multifidus muscle are associated with LBP, and reduced CSA is predictive of LBP up to 12-months [6, 7]. The ability of the multifidus muscle to stabilise and control movement of the lumbar spine may be a key factor in development of LBP, with evidence suggesting those with LBP have lower activity in multifidus [29]. Additionally, a rehabilitation approach focused on training multifidus can reduce LBP following injury [30]. As patients with poor quality multifidus muscle at diagnosis often experience more severe LBP and disability, it may be that superior multifidus morphology indicates a better starting point for surgery [5–7]. Indeed, three of the included studies reported patients with poor quality multifidus muscle had worse LBP and/or disability at baseline [13, 17, 18], with only one study explicitly adjusting for this during analysis [13].

Low physical activity is associated with poorer multifidus morphology [31], and it may be that LBP in degenerative lumbar spine disease associated with low-quality multifidus muscle is less easily correctable by surgery. It may also be that multifidus morphology is a marker of the likelihood that a patient will engage with post-operative physiotherapy and rehabilitation. Therefore, optimising pre-operatively multifidus morphology through targeted training may improve surgical outcomes. Furthermore, use of ultrasonography is a validated method of evaluating multifidus morphology and may be used as a faster, more cost-effective method of assessing multifidus morphology prior to surgical referral [32, 33].

The potential for muscular atrophy to be a predictor of surgical outcomes is not limited to spinal surgery. Fat infiltration and muscular atrophy of the shoulder rotator cuff on pre-operative MRI has also been found to correlate with worse post-operative outcomes following surgical repair compared to patients with higher quality rotator cuff musculature [27, 28].

Limitations

Research on the predictive value of multifidus morphology is relatively new, and the volume of published literature is small. Thus, the possibility of publication bias could not be eliminated. Attempts to minimise this were made by making the literature search as complete as possible and including research in abstract-only format; however, accounting for results from the unpublished literature was not possible.

Additionally, the included studies were dissimilar in terms of fat infiltration grading technique, surgical intervention and reporting of outcomes for individual patients; thus, a summary statistic of effect size including all the available literature could not be calculated.

Ideally, future studies should report the timing of pre-operative pain score and pre-operative MRI, as well as the period of conservative management prior to surgery. In addition, controlling for greater LBP at baseline will help clarify the effect of poor multifidus morphology on surgical outcomes.

Conclusions

This systematic review found evidence for an association between low multifidus fat infiltration on MRI at baseline and greater reductions in measures of LBP and disability following surgical treatment. There is also limited evidence for an association between larger pre-operative multifidus CSA and improvements in disability, but not pain. The findings of this review should be interpreted with caution due to the small quantity of available literature.

This review highlights the theoretical potential of multifidus morphology as assessed by MRI to be an additional predictor of LBP and disability following surgery. As pre-operative MRI scanning is performed routinely on patients undergoing spinal surgery, it would require minimal change in clinical practice to implement, beyond use of a standardised method to quantify muscle quality. However, there is a need for more high-quality research elucidating this association before recommendations for clinical practice can be made.

Future research should address the methodological limitations of the currently published literature by more completely reporting the source of the sample population and reasons for participant drop-out, incorporating a prospective design, and controlling for potential confounding factors. Additionally, studies further examining the relationship between pre-operative multifidus CSA and improvements in LBP and disability at follow-up are required.

Funding This study was unfunded.

Compliance with ethical standards

Conflict of interest All authors confirm that they have no potential conflict of interest.

Open Access This article is licensed under a Creative Commons Attribution 4.0 International License, which permits use, sharing, adaptation, distribution and reproduction in any medium or format, as long

as you give appropriate credit to the original author(s) and the source, provide a link to the Creative Commons licence, and indicate if changes were made. The images or other third party material in this article are included in the article's Creative Commons licence, unless indicated otherwise in a credit line to the material. If material is not included in the article's Creative Commons licence and your intended use is not permitted by statutory regulation or exceeds the permitted use, you will need to obtain permission directly from the copyright holder. To view a copy of this licence, visit <http://creativecommons.org/licenses/by/4.0/>.

References

- Freeman MD, Woodham MA, Woodham AW (2010) The role of the lumbar multifidus in chronic low back pain: a review. *PM and R* 2(2):142–146
- Hoy D, March L, Brooks P, Blyth F, Woolf A, Bain C et al (2014) The global burden of low back pain: estimates from the global burden of disease 2010 study. *Ann Rheum Dis* 73(6):968–974
- Deyo RA, Weinstein JN (2001) Low back pain. *N Engl J Med* 344(5):363–370
- Endean A, Palmer KT, Coggon D (2011) Potential of MRI findings to refine case definition for mechanical low back pain in epidemiological studies: a systematic review. *Spine* 36(2):160
- MacDonald DA, Moseley GL, Hodges PW (2006) The lumbar multifidus: does the evidence support clinical beliefs? *Manual Ther* 11(4):254–263
- Fortin M, Lazary A, Varga PP, Battie MC (2017) Association between paraspinous muscle morphology, clinical symptoms and functional status in patients with lumbar spinal stenosis. *Eur Spine J* 26(10):2543–2551
- Ranger TA, Cicuttini FM, Jensen TS, Peiris WL, Hussain SM, Fairley J et al (2017) Are the size and composition of the paraspinous muscles associated with low back pain? a systematic review. *Spine J* 17(11):1729–1748
- National Institute for Health and Care Excellence (2016) Low back pain and sciatica in over 16s: assessment and management. NICE guideline (NG59)
- Qaseem A, Wilt TJ, McLean RM, Forcica MA (2017) Noninvasive treatments for acute, subacute, and chronic low back pain: a clinical practice guideline from the American college of physicians. *Ann Intern Med* 166(7):514–530
- Fan SW, Hu ZJ, Zhao FD, Zhao X, Huang Y, Fang XQ (2010) Multifidus muscle changes and clinical effects of one-level posterior lumbar interbody fusion: minimally invasive procedure versus conventional open approach. *Eur Spine J* 19(2):316–324
- Waschke A, Hartmann C, Walter J, Dünisch P, Wahnschaff F, Kalff R et al (2014) Denervation and atrophy of paraspinous muscles after open lumbar interbody fusion is associated with clinical outcome - Electromyographic and CT-volumetric investigation of 30 patients. *Acta Neurochir* 156(2):235–244
- Strube P, Putzier M, Streitparth F, Hoff EK, Hartwig T (2016) Postoperative posterior lumbar muscle changes and their relationship to segmental motion preservation or restriction: a randomized prospective study. *J Neurosurg Spine* 24(1):25–231
- Storheim K, Berg L, Hellum C, Gjertsen O, Neckelmann G, Espeland A et al (2017) Fat in the lumbar multifidus muscles predictive value and change following disc prosthesis surgery and multidisciplinary rehabilitation in patients with chronic low back pain and degenerative disc: two-year follow-up of a randomized trial. *BMC Musculoskeletal Disord* 18(1):145
- Pishnamaz M, Schemmann U, Herren C, Horst K, Lichte P, Hildebrand F, Pape HC, Kobbe P (2018) Muscular changes after minimally invasive versus open spinal stabilization of thoracolumbar fractures: a literature review. *J Musculoskelet Neuronal Interact* 18(1):62
- Le Huec JC, Basso Y, Aunoble S, Friesem T, Bruno MB (2005) Influence of facet and posterior muscle degeneration on clinical results of lumbar total disc replacement: two-year follow-up. *J Spinal Disord Tech* 18(3):219–223
- Shin D-E, Lee Y-S, Lee H-J, Ahn T-K, Jo Y-G, Lee S-J (2015) Relationship of the pre-operative condition of paravertebral muscle with post-operative functional disability in patients with degenerative lumbar spinal disease. *J Korean Soc Spine Surg* 22(4):153–159
- Gu J, Guan F, Zhu L, Guan G, Chi Z, Wang H et al (2016) Risk factors of postoperative low back pain for lumbar spine disease. *World Neurosurg* 94:248–254
- Guan F, Bao R, Zhu L, Guan G, Chi Z, Gu J et al (2017) Risk factors of postoperative low back pain for low-grade degenerative spondylolisthesis: an at least two-year follow-up retrospective study. *World Neurosurg* 107:789–794
- Zotti MGT, Boas FV, Clifton T, Piche M, Yoon WW, Freeman BJC (2017) Does pre-operative magnetic resonance imaging of the lumbar multifidus muscle predict clinical outcomes following lumbar spinal decompression for symptomatic spinal stenosis? *Eur Spine J* 26(10):2589–2597
- Battaglia PJ, Maeda Y, Welk A, Hough B, Kettner N (2014) Reliability of the Goutallier classification in quantifying muscle fatty degeneration in the lumbar multifidus using magnetic resonance imaging. *J Manip Phys Ther* 37(3):190–197
- Sorensen SJ, Kjaer P, Jensen ST, Andersen P (2006) Low-field magnetic resonance imaging of the lumbar spine: reliability of qualitative evaluation of disc and muscle parameters. *Acta Radiol* 47(9):947–953
- Hebert JJ, Kjaer P, Fritz JM, Walker BF (2014) The relationship of lumbar multifidus muscle morphology to previous, current and future low back pain: a 9-year population-based prospective cohort study. *Spine* 39(10):1417–1425
- Kader DF, Wardlaw D, Smith FW (2000) Correlation between the MRI changes in the lumbar multifidus muscles and leg pain. *Clin Radiol* 55(2):145–149
- Hu ZJ, He J, Zhao FD, Fang XQ, Zhou LN, Fan SW (2011) An assessment of the intra- and inter-reliability of the lumbar paraspinous muscle parameters using CT scan and magnetic resonance imaging. *Spine* 36(13):E868–E874
- The Cochrane Public Health Group (2011) Data Extraction and Assessment Template [Internet]. *Cochrane Public Health* [cited 13 April 2018]. Available from: <https://ph.cochrane.org/review-authors>
- Hayden JA, van der Windt DA, Cartwright JL, Côté P, Bombardier C (2013) Assessing bias in studies of prognostic factors. *Ann Intern Med* 158(4):280–286
- Mellado JM, Calmet J, Olona M, Esteve C, Camins A, Perez Del Palomar L, Gine J, Sauri A (2005) Surgically repaired massive rotator cuff tears: MRI of tendon integrity, muscle fatty degeneration, and muscle atrophy correlated with intraoperative and clinical findings. *Am J Roentgenol* 184(5):1456–1463
- Shen PH, Lien SB, Shen HC, Lee CH, Wu SS, Lin LC (2008) Long-term functional outcomes after repair of rotator cuff tears correlated with atrophy of the supraspinatus muscles on magnetic resonance images. *J Shoulder Elbow Surg* 17(1):S1–S7
- Danneels LA, Vanderstraeten GG, Cambier DC, Witvrouw EE, De Cuyper HJ, Danneels L (2000) CT imaging of trunk muscles in chronic low back pain patients and healthy control subjects. *Eur Spine J* 9(4):266–272
- Hides JA, Stanton WR, Mendis MD, Gildea J, Sexton MJ (2012) Effect of motor control training on muscle size and football games missed from injury. *Med Sci Sports Exerc* 44(6):1141–1149

31. Teichtahl AJ, Urquhart DM, Wang Y, Wluka AE, O'Sullivan R, Jones G, Cicuttini FM (2015) Physical inactivity is associated with narrower lumbar intervertebral discs, high fat content of paraspinal muscles and low back pain and disability. *Arthritis Res Ther* 17(1):114
32. Hides JA, Richardson CA, Jull GA (1995) Magnetic resonance imaging and ultrasonography of the lumbar multifidus muscle. Comparison two different modalities. *Spine* 20(1):54–58
33. Wallwork TL, Hides JA, Stanton WR (2007) Intrarater and interrater reliability of assessment of lumbar multifidus muscle

thickness using rehabilitative ultrasound imaging. *J Orthop Sports Phys Ther* 37(10):608–612

Publisher's Note Springer Nature remains neutral with regard to jurisdictional claims in published maps and institutional affiliations.