


# Sternum-splitting anterior approach following posterior decompression and fusion in patients with massive ossification of the posterior longitudinal ligament in the upper thoracic spine: report of 2 cases and literature review

Yoshiharu Kawaguchi<sup>1</sup>  · Shoji Seki<sup>1</sup> · Yasuhito Yahara<sup>1</sup> · Takahiro Homma<sup>2</sup> · Tomoatsu Kimura<sup>1</sup>

Received: 26 May 2017 / Revised: 19 July 2017 / Accepted: 26 July 2017 / Published online: 31 July 2017  
© Springer-Verlag GmbH Germany 2017

## Abstract

**Purpose** Anterior approach to the upper thoracic spine is difficult. It is important for spine surgeons to know the indication and the effect of anterior decompression for upper thoracic lesions and also to recognize the complications which are related to the approach with sternotomy. We present two patients for whom we took the sternum-splitting anterior approach for thoracic ossification of the posterior longitudinal ligament (OPLL) following posterior decompression and fusion surgery; the clinical course and surgical outcome are discussed, with particular reference to complication avoidance and also we review the previous literature.

**Methods** We present two cases with severe upper thoracic OPLL. The maximum occupying ratio of OPLL against the spinal canal was more than 80% in both cases. Posterior decompression and fusion were not effective and, therefore, anterior surgery with sternotomy was carried out.

**Results** Cerebrospinal fluid leak was encountered with the removal of OPLL using the anterior approach. Subsequently, a polyglycolic acid sheet was used to cover the defect in the dura matter; a thoracic drainage system with a continuous suction unit was positioned at the surgical wound to avoid fluid retention in the mediastinum. In addition, we facilitated spinal drainage from the lumbar

level. These procedures resulted in no complication caused by fluid retention in the mediastinum.

**Conclusion** Both a safe surgical approach and preventive measures to alleviate postoperative complications are mandatory in difficult cases with thoracic OPLL.

**Keywords** Thoracic OPLL · Anterior approach · Sternotomy · Manubriotomy · Thoracic myelopathy

## Introduction

Posterior surgery is performed in more than 80% of thoracic OPLL [1]. However, in some cases of thoracic OPLL it is difficult to achieve adequate decompression using the posterior approach. In such cases, anterior decompression is indicated [2–5], but it is difficult to perform for upper thoracic OPLL due to the complex anatomy [6–8]. Various anterior surgical approaches have been reported for upper thoracic lesions, including the transthoracic approach [2], peribrachiocephalic approach [8], median approach with manubriotomy [9–15] and sternotomy [16–18]. Teng et al. reported an approach selection method for surgery in the cervicothoracic junction (CTJ) based on the cervicothoracic angle (CTA) [18]. They divided the lesions in CTJ into three types: (Type A) caudal part of the lesion above CTA, (Type B) caudal part of the lesion within CTA, and (Type C) caudal part of the lesion below CTA. They showed the possible surgical approach according to each type and suggested that Type C might require sternotomy. We encountered upper thoracic OPLL cases in which the initial posterior decompression and fusion were not sufficiently effective; therefore, anterior decompression with sternotomy was performed as a second surgery. Here, we

✉ Yoshiharu Kawaguchi  
zenji@med.u-toyama.ac.jp

<sup>1</sup> Department of Orthopaedic Surgery, Faculty of Medicine, University of Toyama, 2630 Sugitani, Toyama, Toyama 930-0194, Japan

<sup>2</sup> Department of Surgery, Faculty of Medicine, University of Toyama, Toyama, Japan

present the clinical course and surgical outcome of these cases.

### Case 1

An 82-year-old woman with numbness and motor weakness of her lower extremities came to our hospital with the complaint of gait disturbance lasting for 3 months. She had a spastic gait. Neurological examination showed upper thoracic Brown Sequard type myelopathy. She had urinary incontinence. Whole spine CT demonstrated C5–7 continuous type OPLL and T2–9 mixed type OPLL (Fig. 1). The maximum lesion was at the T3 level. The maximum occupancy ratio of OPLL against the spinal canal was 83.1% (12.25/14.75 mm). MRI revealed severe spinal cord compression at the level of T3 and the spinal cord appeared paper thin (Fig. 2).

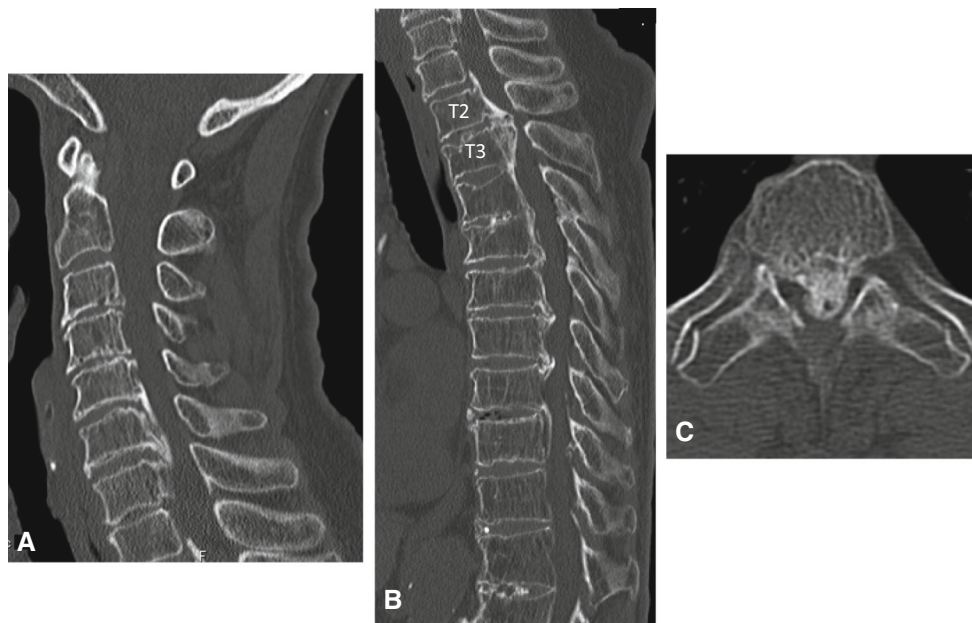
We planned a two-stage operation for posterior decompression and fusion from C3–T5 at the first stage and then anterior decompression with corpectomy of T3 and fusion at the second stage. For posterior decompression and fusion, C3–7 laminoplasty and T1–5 laminectomy with posterior fusion using T1, 2, 4 and 5 bilateral pedicle screws were performed. Numbness and motor weakness of her lower extremities improved just after posterior surgery; however, she complained of gradual worsening of anterior chest girdle pain. At 2 months after posterior surgery, we performed T3 corpectomy and T2–4 anterior interbody fusion with autologous anterior iliac crest under the informed consent. Sternotomy was performed with the

assistance of a chest surgeon (Fig. 3). During corpectomy, a cerebrospinal fluid (CSF) leak was encountered (Fig. 4). A polyglycolic acid sheet was applied to cover the dural defect. A chest drainage system was used from the surgical wound for 2 weeks and a spinal drainage system from the lumbar spine area was also used. The patient had swallowing disturbance due to left recurrent nerve paralysis, but it spontaneously recovered within a month. Her neurological status was improved. She could walk with the aid of a T cane at 2 months after anterior surgery. Decompression was confirmed by postoperative CT and solid fusion at T2–4 was achieved at 2 years after surgery (Fig. 5).

### Case 2

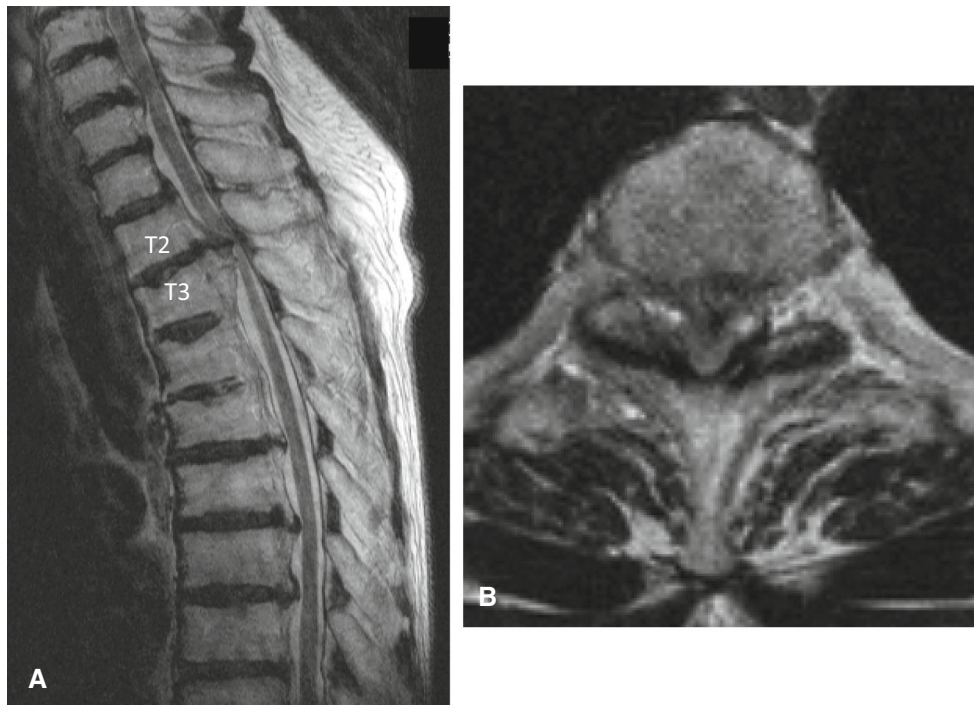
A 69-year-old woman presented to our hospital in a wheelchair with the complaint of gradually deteriorating gait disturbance for 1 month. She was revealed to have T6 transverse type myelopathy. Whole spine CT demonstrated T3–7 mixed type OPLL (Fig. 6) and thoraco-lumbar OPLL from T12 to L2. In particular, the shape of T3–4 OPLL appeared as a beak type shape (Fig. 6). Ossification of the ligamentum flavum (OLF) was found at T3–4 (Fig. 6) and T7–11 levels. The spinal cord was severely compressed by OPLL and OLF at the level of T3–4 which was shown by MRI (Fig. 7). The maximum occupancy ratio of OPLL against spinal canal was 86.1% (11.38/13.21 mm).

We planned a two-stage operation with posterior decompression and fusion from T2–10 at the first stage and

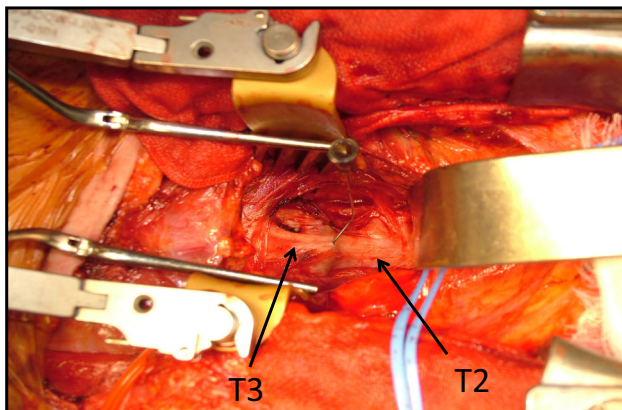


**Fig. 1** An 82-year-old woman with upper thoracic myelopathy (Case 1). **a** CT image of the cervical and thoracic spine. C5–7 continuous type OPLL (**a**) and T2–9 mixed type OPLL (**b**) were seen. Massive

OPLL was observed at T3 level (**c**) and the maximum occupancy ratio of OPLL against the spinal canal was 83.1% at T3 level

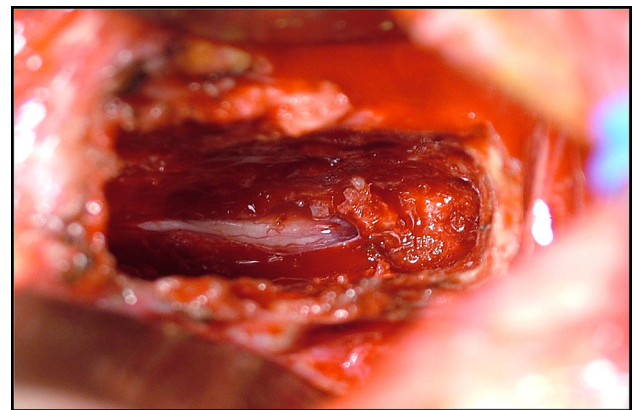


**Fig. 2** T2-weighted MRI sagittal image (a) and axial image (b) in Case 1. The spinal cord was severely compressed at T3 level



**Fig. 3** Anterior surface of the T2–3 vertebral body was exposed. A needle was inserted at the intervertebral disc space as a marker and the level was confirmed by plain radiography (Case 1)

then anterior decompression for the removal of T3–4 OPLL and fusion as a second surgery. Posterior surgery was carried out uneventfully, although transcranial electric motor-evoked potential was not detected throughout the operation. Her neurological findings worsened after the posterior surgery. She had monoparesis at the left lower extremity and sensory disturbance was increased. Spinal cord compression was still observed at the T3–4 level. Therefore, T3–4 OPLL removal and interbody fusion using autologous anterior iliac crest via the anterior approach were carried out 1 week after the posterior surgery. Sternotomy was performed. During the removal of OPLL, a

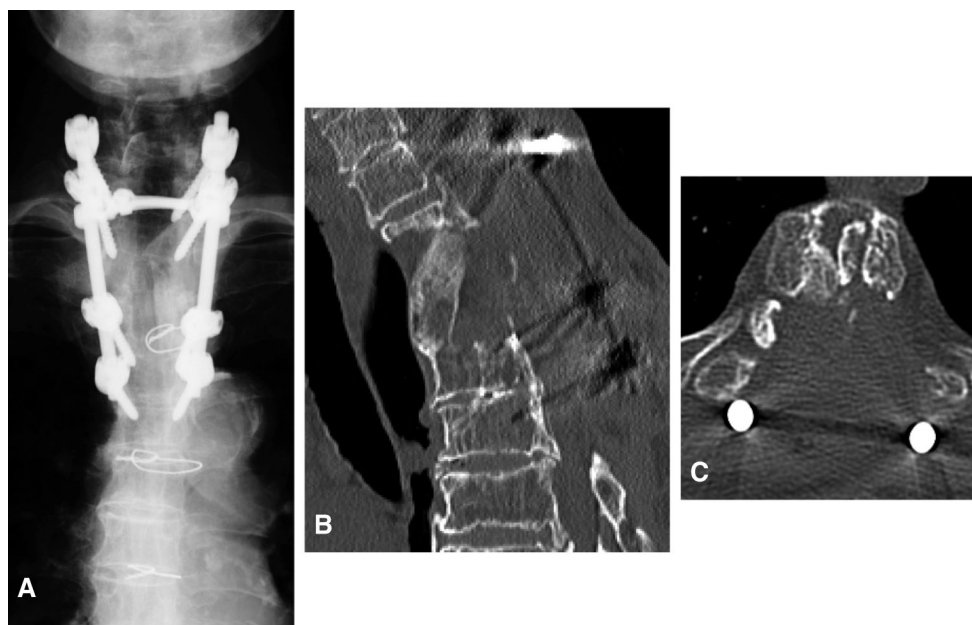


**Fig. 4** Corpectomy of T3 was carried out. The arachnoid was exposed and a cerebrospinal fluid (CSF) leak was encountered. The dura matter was ossified at this lesion (Case 1)

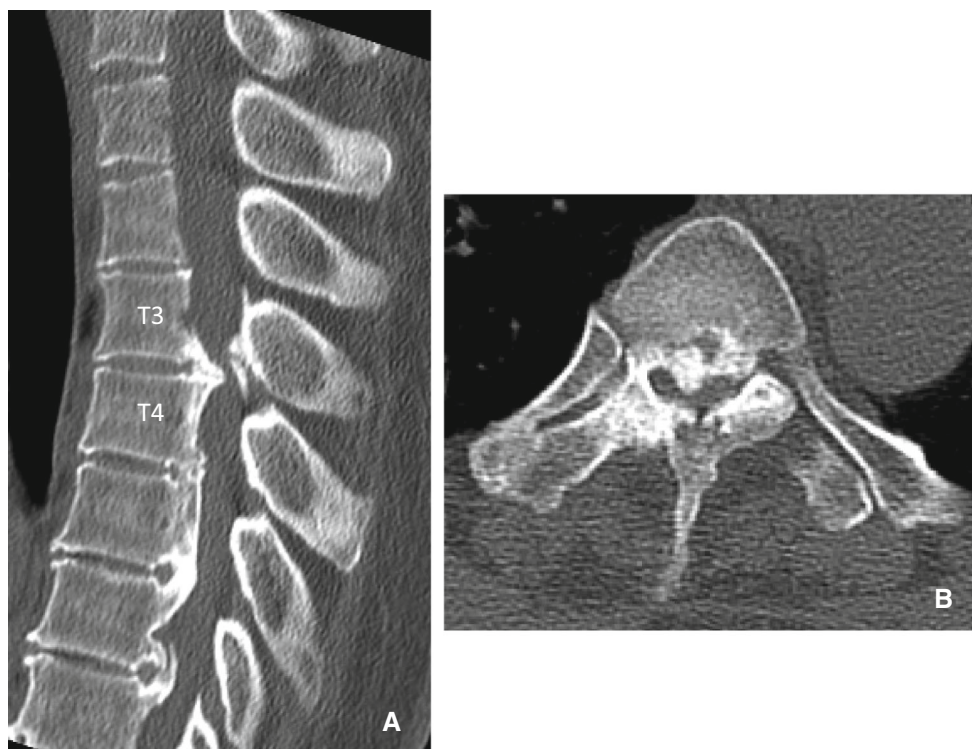
cerebrospinal fluid (CSF) leak was encountered. A polyglycolic acid sheet was applied to cover the dural defect. A chest drainage system and spinal drainage were used. The postoperative course was uneventful and the bone graft was properly located without migration (Fig. 8).

## Discussion

In the present cases, the locations of the main OPLL lesions were T3 and T3–4 levels. These lesions were Type C according to the classification of Teng et al. [18]. In the



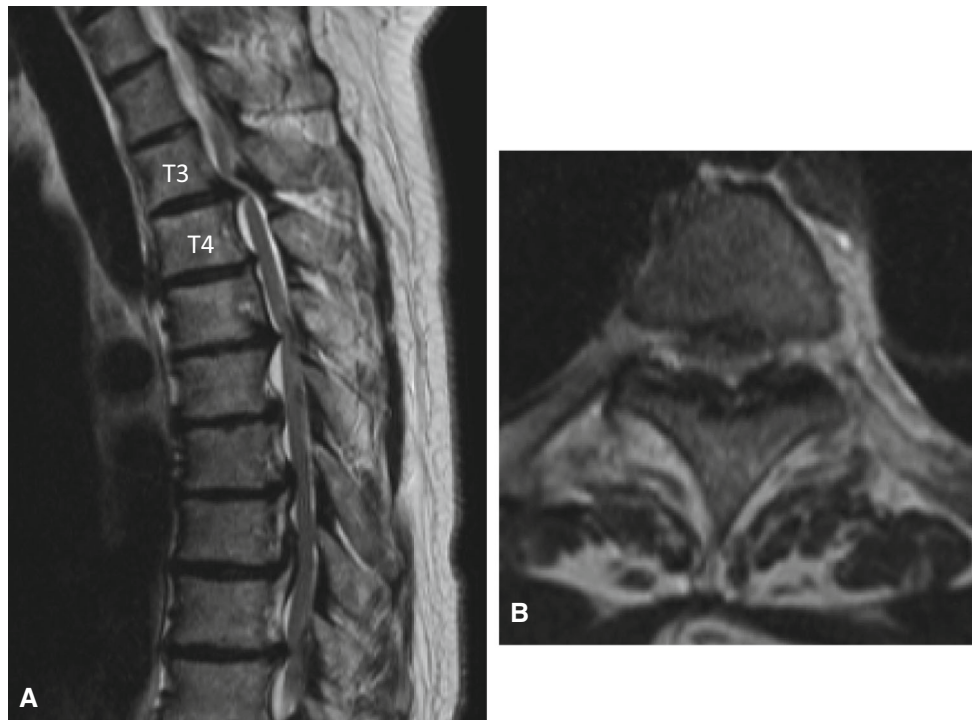
**Fig. 5** Postoperative radiograph (a) and CT images (b, c) at 2 years after surgery in Case 1. Solid fusion was achieved at T2–4 level. Decompression was completed



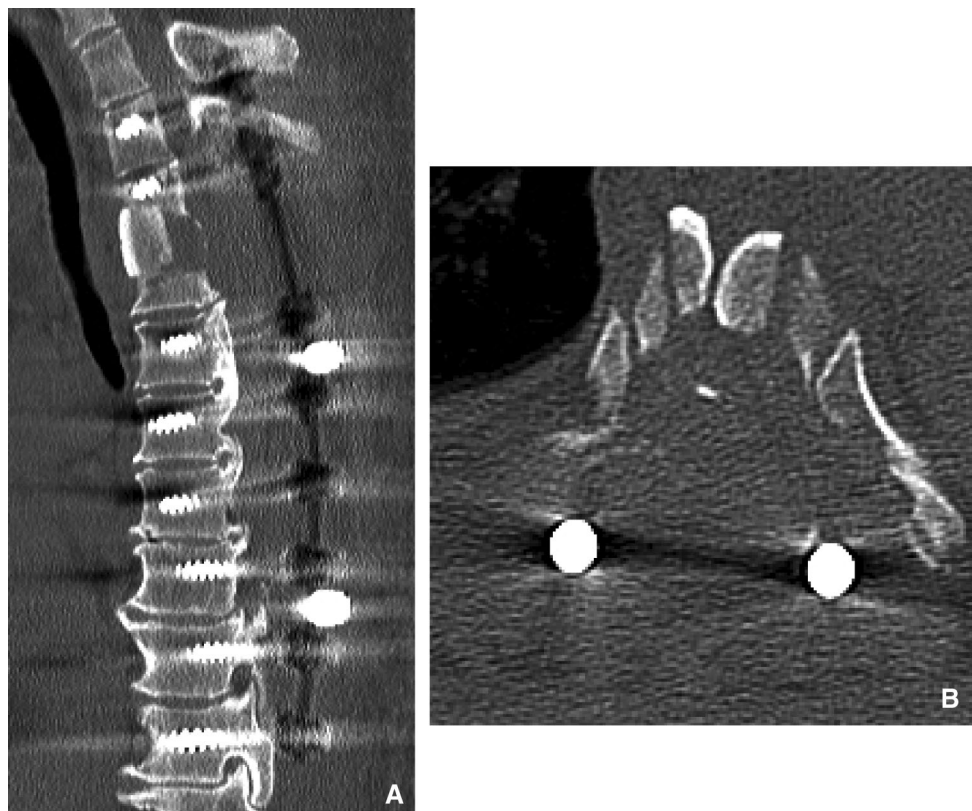
**Fig. 6** A 69-year-old woman with upper thoracic myelopathy (Case 2). CT sagittal image showed T3–7 mixed type OPLL. Beak shape type OPLL was seen at T3–4 level (a). The maximum occupancy ratio of OPLL against the spinal canal was 86.1 % at T3–4 level (b)

present two cases, sternotomy was a reasonable procedure for the anterior approach to thoracic OPLL. This method was also confirmed by the study of Lam and Groff [13]. Sternotomy is often used in open heart surgery. This

approach allows good visualization of the anterior region of the upper thoracic vertebrae. In our cases, the lesions of OPLL were particularly massive. The maximum occupancy ratio was more than 80% in both cases. The spinal



**Fig. 7** T2-weighted MRI sagittal image (a) and axial image (b) in Case 2. Spinal cord was severely compressed by the beak type OPLL at T3–4 level



**Fig. 8** Using the sternum-splitting approach, T3–4 anterior interbody fusion was performed. OPLL was completely resected, as shown by sagittal (a) and axial (b) CT images in Case 2

cord in both cases was already damaged, as noted in their clinical course; thus, the safer approach was preferable. Considering this situation, we chose the anterior decompression with sternotomy for these cases. However, the sternum-splitting approach is difficult to perform; vital structures must be protected, such as the arch of aorta, common carotid artery, innominate vein, thoracic duct, recurrent laryngeal nerve, satellite ganglion, trachea, and esophagus [7]. Some papers have reported the sternum-splitting approach to be invasive [10, 11, 19]. Mihir et al. [11] as well as Hodgson and Stock [19] reported high rates of morbidity and mortality associated with a standard median sternotomy. Based on their results, Luk et al. introduced an anterior approach to the cervicothoracic junction with manubriotomy [10]. However, the manubriotomy might not be sufficient to expose the anterior part of the upper thoracic vertebrae. It might be very difficult to remove the massive ossified lesion by the anterior approach by manubriotomy. The tip of the drill might not reach the lesion because the operative field is too narrow. Further, in the present cases, it might have been difficult to approach the ossified lesion through manubriotomy because the approach direction is from cranial to caudal through manubriotomy, whereas the spinal alignment is lordokyphosis in the upper thoracic spine and this anatomical structure is the disadvantage for the direct approach to the lesions. Based on these concerns, we considered that the sternum-splitting approach was superior to manubriotomy. The approach was very successful. It was easy to reach the ossified lesions and we could perform complete resection of the OPLL.

The anterior approach to the upper thoracic spine has the potential risk of life-threatening complications. Cerebrospinal fluid leak by the removal of OPLL can be encountered [20], and this might cause fluid retention in the mediastinum. We used a polyglycolic acid sheet to cover the defect in the dura matter and a thoracic drainage system with a continuous suction unit at the surgical wound to avoid fluid retention in the mediastinum. In addition, we put in a spinal drainage system from the lumbar level. It was very effective and we did not have any complication due to fluid retention in the mediastinum.

In the present two cases, we undertook a two-staged operation; first posterior decompression and fusion was first done, and second, anterior surgery was carried out. Our strategy for the surgical treatment of cervical OPLL, which is posterior decompression surgery with laminoplasty, remains the initial treatment, and in patients with neurological deterioration during follow-up, anterior decompression surgery is the salvage procedure [21]. We have reported several cases that have been treated according to this strategy and this procedure seems to be effective and safe [21]. In severe OPLL cases, anterior

decompression after posterior decompression is safer than anterior decompression alone. This is because there is no longer a posterior wall as a result of the posterior decompression when anterior decompression is performed as a second surgery. As for the treatment of very severe OPLL cases, a particularly safe surgical approach is mandatory. Therefore, it might be reasonable to consider a two-stage operation.

In conclusion, we presented cases with massive OPLL who underwent anterior resection of OPLL with sternotomy following posterior decompression and fusion surgery. The safe surgical approach to the OPLL and preventive measures for the postoperative complication are mandatory in difficult cases with thoracic OPLL.

#### Compliance with ethical standards

**Conflict of interest** All authors declare that they have no competing interest.

#### References

1. Matsumoto M, Chiba K, Toyama Y et al (2008) Surgical results and related factors for ossification of posterior longitudinal ligament of the thoracic spine: a multi-institutional retrospective study. *Spine (Phila Pa 1976)* 33(9):1034–1041
2. Kojima T, Waga S, Kubo Y et al (1994) Surgical treatment of ossification of the posterior longitudinal ligament in the thoracic spine. *Neurosurgery* 34(5):854–858
3. Ido K, Shimizu K, Nakayama Y et al (1995) Anterior decompression and fusion for ossification of posterior longitudinal ligament in the thoracic spine. *J Spinal Disord* 8(4):317–323
4. Fujimura Y, Nishi Y, Nakamura M et al (1996) Anterior decompression and fusion for ossification of the posterior longitudinal ligament of the upper thoracic spine causing myelopathy: using the manubrium splitting approach. *Spinal Cord* 34(7):387–393
5. Min JH, Jang JS, Lee SH (2008) Clinical results of ossification of the posterior longitudinal ligament (OPLL) of the thoracic spine treated by anterior decompression. *J Spinal Disord Tech* 21(2):116–119
6. An HS, Vaccaro A, Cotler JM et al (1994) Spinal disorders at the cervicothoracic junction. *Spine (Phila Pa 1976)* 19(22):2557–2564
7. An HS, Wise JJ, Xu R (1999) Anatomy of the cervicothoracic junction: a study of cadaveric dissection, cryomicrotomy, and magnetic resonance imaging. *J Spinal Disord* 12(6):519–525
8. Sattarov KV, Fard SA, Patel AS et al (2015) Peribrachiocephalic approaches to the anterior cervicothoracic spine. *J Clin Neurosci* 22(11):1822–1826
9. Kurz LT, Pursel SE, Herkowitz HN (1991) Modified anterior approach to the cervicothoracic junction. *Spine (Phila Pa 1976)* 16(10 Suppl):S542–S547
10. Luk KD, Cheung KM, Leong JC (2002) Anterior approach to the cervicothoracic junction by unilateral or bilateral manubriotomy. A report of five cases. *J Bone Joint Surg Am* 84-A(6):1013–1017
11. Mihir B, Vinod L, Umesh M et al (2006) Anterior instrumentation of the cervicothoracic vertebrae: approach based on clinical and radiologic criteria. *Spine (Phila Pa 1976)* 31(9):E244–E249
12. Falavigna A, Righesso O, Teles AR (2011) Anterior approach to the cervicothoracic junction: proposed indication for manubriotomy based on preoperative computed tomography findings. *J Neurosurg Spine* 15(1):38–47

13. Lam FC, Groff MW (2011) An anterior approach to spinal pathology of the upper thoracic spine through a partial manubriotomy. *J Neurosurg Spine* 15(5):467–471
14. Tarantino R, Donnarumma P, Marruzzo D et al (2013) Anterior surgical approaches to the cervicothoracic junction: when to use the manubriotomy? *Spine J* 13(9):1064–1068
15. Lee JG, Kim HS, Ju CI et al (2016) Clinical features of herniated disc at cervicothoracic junction level treated by anterior approach. *Korean J Spine* 13(2):53–56
16. Knöller SM, Brethner L (2002) Surgical treatment of the spine at the cervicothoracic junction: an illustrated review of a modified sternotomy approach with the description of tricks and pitfalls. *Arch Orthop Trauma Surg* 122(6):365–368
17. Maciejczak A, Radek A, Kowalewski J et al (1999) Anterior transsternal approach to the upper thoracic spine. *Acta Chir Hung* 38(1):83–86
18. Teng H, Hsiang J, Wu C et al (2009) Surgery in the cervicothoracic junction with an anterior low suprasternal approach alone or combined with manubriotomy and sternotomy: an approach selection method based on the cervicothoracic angle. *J Neurosurg Spine* 10(6):531–542
19. Hodgson AR, Stock FE (1956) Anterior spinal fusion. A preliminary communication on the radical treatment of Pott's disease and Pott's paraplegia. *Br J Surg* 44(185):266–275
20. Cho JY, Chan CK, Lee SH et al (2012) Management of cerebrospinal fluid leakage after anterior decompression for ossification of posterior longitudinal ligament in the thoracic spine: the utilization of a volume-controlled pseudomeningocele. *J Spinal Disord Tech* 25(4):E93–E102
21. Kawaguchi Y, Nakano M, Yasuda T et al (2014) Anterior decompressive surgery after cervical laminoplasty in patients with ossification of the posterior longitudinal ligament. *Spine J* 14(6):955–963