

A rare case of non-traumatic, multi-level, bilateral pedicle fractures of the lumbar spine in a 60-year-old patient

Timo Schmid¹  · Paul Heini² · Lorin Benneker¹

Received: 13 September 2016 / Accepted: 2 March 2017 / Published online: 16 March 2017
© Springer-Verlag Berlin Heidelberg 2017

Abstract

Introduction We report a 60-year-old patient who sustained non-traumatic, multi-level, bilateral lumbar pedicle fractures in the setting of unilateral lumbar spondylolysis. A possible fracture mechanism is evaluated and a review of the literature is presented. Whereas contralateral pedicle fractures of lumbar vertebrae with unilateral spondylolysis are well described in young athletes, there is only one case report of multi-level, bilateral pedicle fractures of the lumbar spine in a young patient who sustained a high-impact motorcycle accident. To our knowledge, this is the first report of multi-level, bilateral pedicular fractures of the lumbar spine without a history of trauma.

Methods The clinical case of a 60-year-old patient with lumbar pain radiating in both legs without antecedent trauma is presented. Besides an idiopathic primary adrenal failure, no further co-morbidities existed. Radiologic investigations showed acute bilateral pedicles' fractures of the lumbar vertebrae two to four (L2–4) and a unilateral spondylolysis L4–5. Dorsoventral instrumentation from L1 to L5 was performed in two steps.

Results The patient had no neurological deficits at discharge. Perioperative cortisol substitution was arranged and continued in the course. At final follow-up after 6 years the patient was pain-free and radiographs confirmed complete fusion of L1–5 with mild degeneration of the adjacent segments.

Conclusion The presented fracture pattern has not been described to date. Because of multi-level involvement, instability requiring operative stabilisation was presumed and confirmed during surgery.

Keywords Spine · Lumbar spine · Fracture · Stress fracture · Pedicle fracture

Introduction

Fractures of the vertebral arch are commonly located in the pars interarticularis known as spondylolysis. Rarely, the arch breaks in the pedicles. Those fractures are usually associated with either stress-related activities or previous spine surgery. We present the uncommon case of a patient who sustained bilateral lumbar pedicle fractures of three vertebrae without history of antecedent trauma.

Case report

A 60-year-old woman was referred to our department with progressive lower back pain radiating in both legs since several days. At admission she had full motor function of the lower extremities and no bowel or bladder dysfunction. There was no history of antecedent trauma or spinal surgery. She had local tenderness on palpation but no hematoma or bruising was evident.

CT scans showed bilateral fractures of the pedicles of the lumbar vertebrae two to four (L2–L4) and a spondylolysis of the left pars interarticularis of the fifth lumbar vertebra without spondylolisthesis. Furthermore, radiographs showed a lumbosacral transitional anomaly with a

✉ Timo Schmid
timo.schmid@insel.ch

¹ Department of Orthopaedic Surgery, Inselspital, Bern University Hospital, Bern, Switzerland

² Orthopaedie Sonnenhof, Sonnenhofspital, Bern, Switzerland

dysplastic unilateral transverse process representing a Castellvi type Ia anomaly [1] (Figs. 1, 2).

MRI scans revealed moderate degeneration of the intervertebral discs and facet joints and moderate fatty degeneration of the paraspinal muscles in keeping with the age of the patient (Fig. 3a). There was no sign of a tumour or an inflammatory disease and no hematoma was found around the pedicle fractures or subcutaneously (Fig. 3b).

Stabilisation of the lumbar spine was performed in two steps. In a first procedure dorsolateral spondylodesis with instrumentation from L1 to L5 and a posterolateral interbody fusion L4–5 was performed (Syntes USSII, DBX, Synthes Inc., Oberdorf Switzerland, CycIOS, Mathys Inc., Bettlach, Switzerland, Devex DePuy Inc., Kerkel, Germany). During the surgery the dorsal parts of L2–4 were confirmed to be highly unstable while stable spontaneous fusion of the segment L5/S1 was found. No subcutaneous hematoma or fracture hematoma was evident. In a second procedure, a ventral discectomie and spondylodesis L2/3 and L3/4 via an anterolateral approach was performed. (Synthes SynCage LR, DBX, Synthes Inc, Oberdorf, Switzerland) (Fig. 4).

Postoperative recovery was uneventful and the patient was discharged 6 days after the second intervention without leg pain and with intact neurological function of both legs. During follow-up at 2, 6 and 12 months the patient was pain-free and had full neurological function. Radiographs and computed tomography confirmed stable fusion at L1–5 (Fig. 5). At final follow-up, 6 years after surgery,

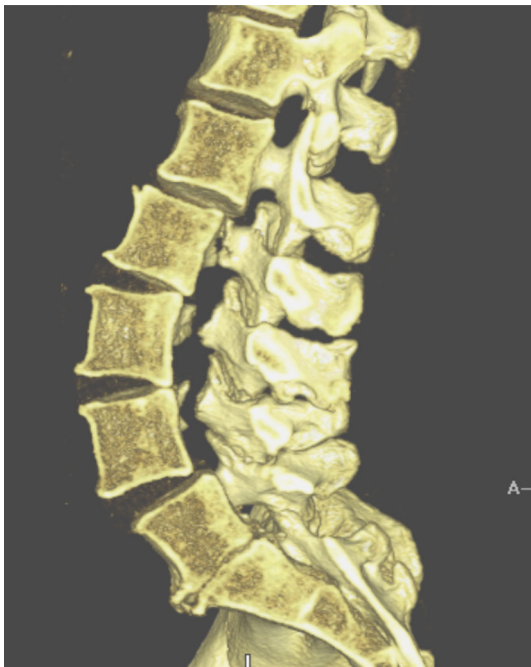

Fig. 1 3D reconstruction illustrating the pedicle fractures of the lumbar vertebrae 2, 3, and 4

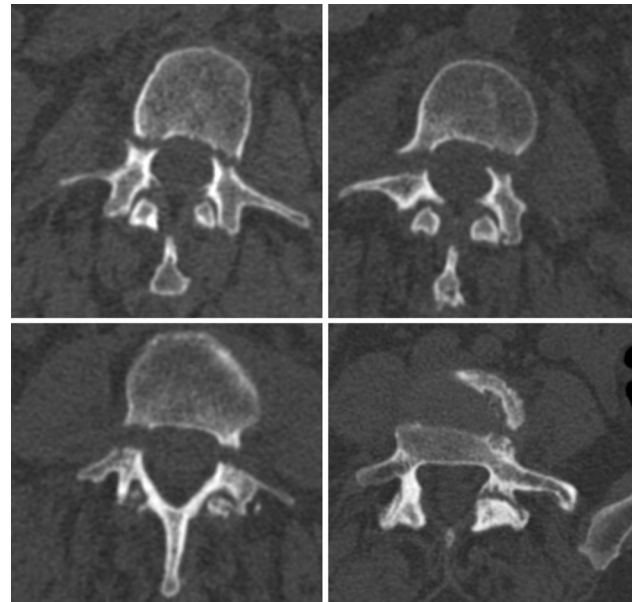


Fig. 2 Axial CT scans showing bilateral pedicle fracture of L2 (upper left), L3 (upper right), and L4 (lower left), and the left-sided spondylolysis L5 with a dysplastic left transverse process

she was still pain-free and radiographs revealed mild degeneration of the adjacent segments (Fig. 6).

Laboratory results at admission showed a decreased sodium (114 mmol/l). Slow compensation of the sodium level was performed. No signs of central pontine myelinolysis were found. Following tests revealed a primary adrenal failure and a hypothyreosis requiring peroral substitutions of cortisol and thyroxin. Further investigations revealed that the patient had a previous transsphenoidal hypophyseal resection of an FSH-producing adenoma 4 years earlier, and steroid substitution due to postoperative secondary adrenal failure had been necessary at that point. However, this secondary adrenal failure had completely resolved 6 months later and, therefore, the steroid substitution had been stopped successfully. Due to this history of hormone substitution the patient had been under regular control of her bone density. A densitometry, which had been performed 4 months before sustaining the fractures, had revealed a normal quality with a bone mineral density of 0.730 g/cm^3 at the proximal femur representing a Z-score of 0.1 standard deviations.

The patient gave a written informed consent for publication of the case.

Discussion

Although the exact aetiology of the presented fractures remains unclear, the absence of antecedent trauma, tumour and infection and the spontaneous fusion of the adjacent

Fig. 3 **a** MRI without any sign of inflammation or tumour. **b** M axial MRI scans of L2 (*left*), L3 (*middle*), and L4 without hematoma formation around the pedicle fractures

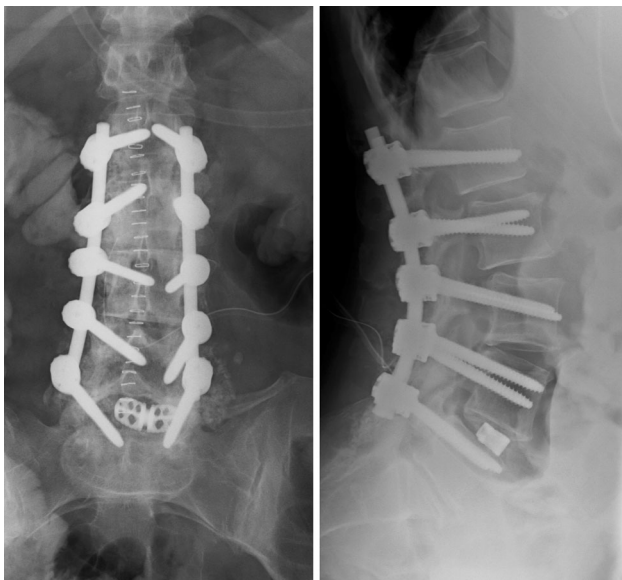
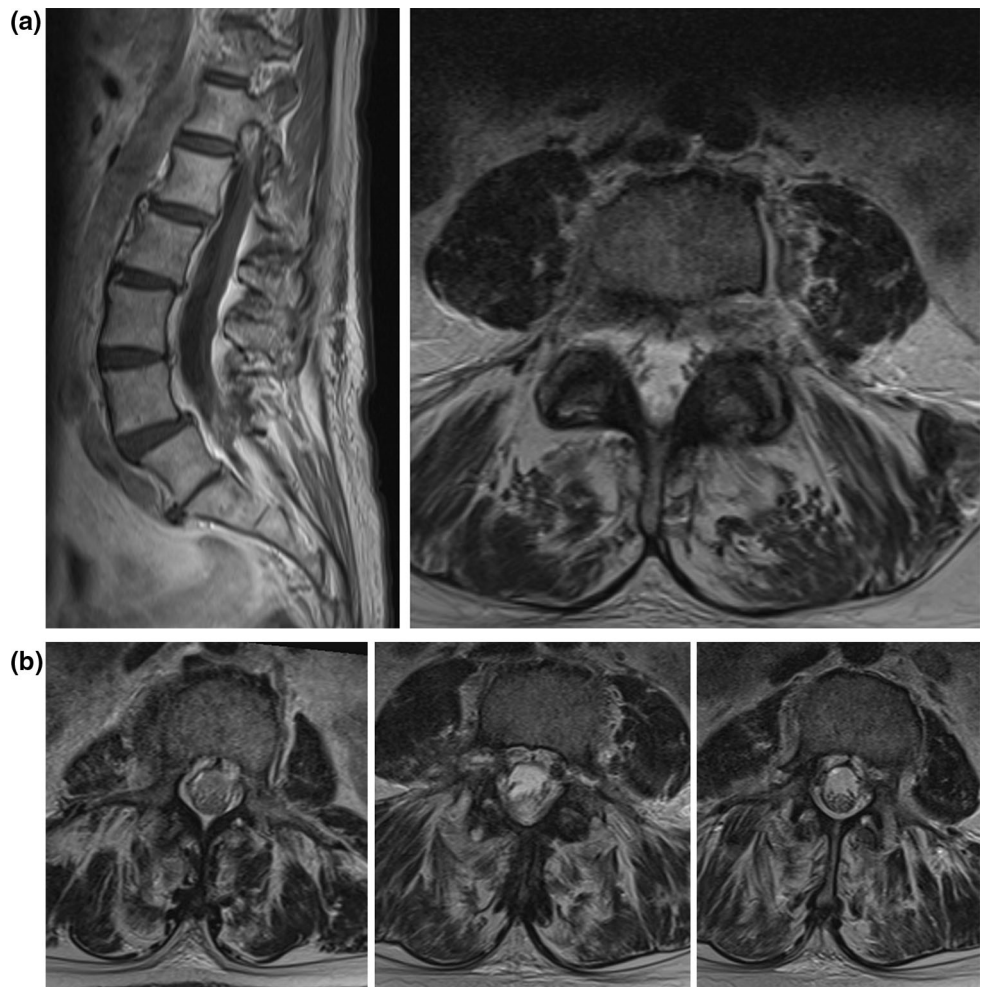


Fig. 4 Standing anteroposterior and lateral radiographs after stabilisation

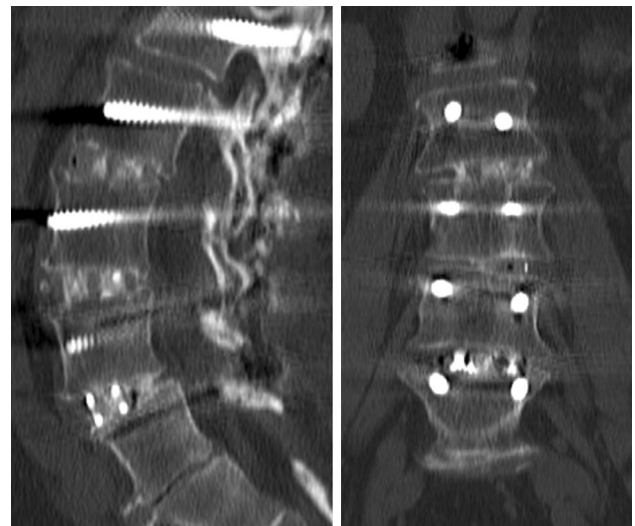

Fig. 5 Follow-up CT after 12 months showing successful anterior and posterior fusion

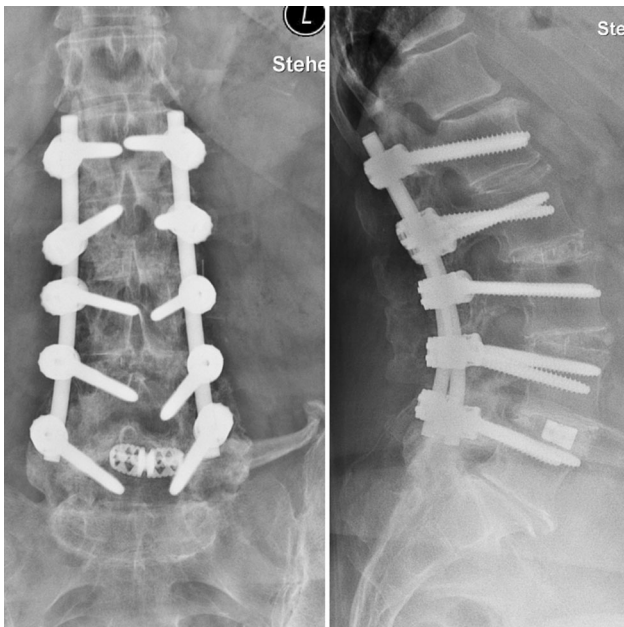


Fig. 6 Follow-up radiographs after 6 years reveal mild degeneration of the adjacent segments Th 12–L1 and L5–S1

level L5/S1 as a possible stress raiser suggest stress fractures as the most likely entity.

Stress fractures of the lumbar spine are seen frequently. Most of these fractures present in the pars interarticularis, known as spondylolysis. In a laboratory study, Cyron [2] could constantly produce pars interarticularis fractures and confirmed this part to be the weakest of the neural arc followed by the pedicles that are the second-most vulnerable part of the vertebra.

Nevertheless, pedicle fractures are rarely seen in clinical practice. Most of these fractures present as contralateral stress fractures in the setting of a pre-existing spondylolysis [3, 4]. The reason is seen in a redistribution of forces, which results in hypertrophy of the pedicle [5–8]. This can be seen on radiographs as vertebral anisocory.

Gunzburg [9] first described a case of bilateral pedicle fractures in addition to spondylolysis and entitled this fracture pattern as pedicolysis. Further reports [10–13] showed pedicle fractures without concomitant spondylolysis. All these patients were young patients who did sports with repetitive movements of the lumbar spine, as for example, swimming. Doita described a case of a bilateral pedicle fracture in a patient with adjacent osteoporosis compression fracture [14].

Another entity of pedicle fractures consists of patients with previous surgical spinal fusion [15, 16]. Although the spontaneous fusion of L5/S1 in our patient might have had the same biomechanical consequences to the adjacent spine as a previous surgical fusion, all those patients had single-level fractures, whereas our patient had fractures at three levels.

So far, there is only one case report about multiple level lumbar pedicle fractures in a young patient who sustained a high-impact accident as a motorcyclist [17]. To our knowledge this is the first report of multiple, bilateral pedicle fractures of the lumbar spine in a patient without antecedent trauma.

There are several descriptions of pedicle defects ascribed to a lack of normal ossification [18–20]. However, the morphologic appearance of the defects and the age of the patient are unlikely to fit in the category of a congenital lesion.

The adrenal failure would be expected to be secondary after previous transsphenoidal hypophyseal resection. Nevertheless, exams showed a primary adrenal failure and primary thyroidal insufficiency. Hypothetically, the hormone disorder might have contributed to the development of the fractures. But ever since the hypophyseal resection, the patient presented in this case report had regular bone density scans, and all scans including the last scan 4 months prior to the event confirmed normal bone quality.

There is no literature to guide the treatment of this fracture pattern. The pathology that most closely resembles this specific situation might be a symptomatic spondylolysis. Non-operative treatment of spondylolysis with a gap has been shown to result in high rates of non-union, even in adolescents and single-level lesions [21, 22]. As all three levels showed gapping fractures, surgical treatment was considered appropriate.

Direct repair was recommended in young patients with minimal spondylolisthesis, no radiculopathy and normal discs [23–25]. Gunzburg reported of good clinical and radiological outcome 6 months after direct repair of a lumbar pedicolysis with a contralateral spondylolysis in a 22-year-old patient [9]. But as the presented patient was 60 years old and had multi-level involvement, direct repair was considered to yield a high risk of non-union. Additionally, to approach the fracture sites for debridement and bone grafting, bilateral transverse process osteotomy over three levels would have been necessary.

Posterolateral fusion of single-level, low-grade slips results in fusion rates between 30 and 100% depending on the study and radiographic criteria used to evaluate the fusion mass. However, in adults there is some evidence that disc degeneration may progress despite a solid posterolateral fusion [26, 27].

In a systematic review of surgical outcome for adult patients with isthmic spondylolisthesis, a combined anteroposterior approach most reliably achieved fusion and successful clinical outcome [28].

Because of the patient's age and multi-level involvement with complete separation of the anterior and posterior parts of the spinal column, a two-step anteroposterior stabilisation was thought to be the appropriate intervention. At

6 years the patient was free of symptoms and had complete radiologic healing with moderate degeneration of the adjacent segments.

Key points

Multiple level, bilateral stress fractures of lumbar vertebrae pedicles are uncommon and have never been previously reported. We present a case of a 60-year-old female patient with bilateral lumbar pedicle fractures of three vertebrae without antecedent trauma or surgery. To our knowledge, this is the first report of non-traumatic, multiple level fractures of lumbar vertebrae pedicles.

Compliance with ethical standards

Conflict of interest None of the authors has any potential conflict of interest.

References

- Castellvi AE, Goldstein LA, Chan DP (1984) Lumbosacral transitional vertebrae and their relationship with lumbar extradural defects. *Spine* 9:493–495
- Cyron BM, Hutton WC (1978) The fatigue strength of the lumbar neural arch in spondylolysis. *J Bone Jt Surg Br* 60:234–238
- Garber JE, Wright AM (1986) Unilateral spondylolysis and contralateral pedicle fracture. *Spine* 11:63–66
- Aland C, Rineberg BA, Malberg M, Fried SH (1986) Fracture of the pedicle of the fourth lumbar vertebra associated with contralateral spondylolysis. Report of a case. *J Bone Jt Surg Am* 68:1454–1455
- Araki T, Harata S, Nakano K, Satoh T (1992) Reactive sclerosis of the pedicle associated with contralateral spondylolysis. *Spine* 17:1424–1426
- Maldague BE, Malghem JJ (1976) Unilateral arch hypertrophy with spinous process tilt: a sign of arch deficiency. *Radiology* 121:567–574. doi:10.1148/121.3.567
- Sherman FC, Wilkinson RH, Hall JE (1977) Reactive sclerosis of a pedicle and spondylolysis in the lumbar spine. *J Bone Jt Surg Am* 59:49–54
- Wilkinson RH, Hall JE (1974) The sclerotic pedicle: tumor or pseudotumor? *Radiology* 111:683–688. doi:10.1148/111.3.683
- Gunzburg R, Fraser RD (1991) Stress fracture of the lumbar pedicle. Case reports of “pediculolysis” and review of the literature. *Spine* 16:185–189
- Amari R, Sakai T, Katoh S, Sairyo K, Higashino K, Tachibana K, Yasui N (2009) Fresh stress fractures of lumbar pedicles in an adolescent male ballet dancer: case report and literature review. *Arch Orthop Trauma Surg* 129:397–401. doi:10.1007/s00402-008-0685-8
- Parvataneni HK, Nicholas SJ, McCance SE (2004) Bilateral pedicle stress fractures in a female athlete: case report and review of the literature. *Spine* 29:E19–E21. doi:10.1097/01.BRS.0000105988.43472.2B
- Ireland ML, Micheli LJ (1987) Bilateral stress fracture of the lumbar pedicles in a ballet dancer. A case report. *J Bone Jt Surg Am* 69:140–142
- Sadiq MZ (2006) Bilateral pedicle stress fracture in the lumbar spine of a sedentary office worker. *Eur Spine J Off Publ Eur Spine Soc Eur Spinal Deform Soc Eur Sect Cerv Spine Res Soc* 15(Suppl 5):653–655. doi:10.1007/s00586-006-0184-y
- Doita M, Ando Y, Hirata S, Ishikawa H, Kurosaka M (2008) Bilateral pedicle stress fracture in a patient with osteoporotic compression fracture. *Eur Spine J*. doi:10.1007/s00586-008-0816-5
- Robertson PA, Grobler LJ (1993) Stress fracture of the pedicle. A late complication of posterolateral lumbar fusion. *Spine* 18:930–932
- Tribus CB, Bradford DS (1993) Bilateral pedicular stress fractures after successful posterior spinal fusion for adult idiopathic scoliosis. *Spine* 18:1222–1225
- Miyamoto H, Sumi M, Kataoka O, Doita M, Kurosaka M, Yoshiya S (2004) Traumatic spondylolisthesis of the lumbosacral spine with multiple fractures of the posterior elements. *J Bone Jt Surg Br* 86:115–118
- Bardsley JL, Hanelin LG (1971) The unilateral hypoplastic lumbar pedicle. *Radiology* 101:315–317. doi:10.1148/101.2.315
- Morin ME, Palacios E (1974) The aplastic hypoplastic lumbar pedicle. *Am J Roentgenol Radium Ther Nucl Med* 122:639–642
- Norman WJ, Johnson C (1973) Congenital absence of a pedicle of a lumbar vertebra. *Br J Radiol* 46:631–633. doi:10.1259/0007-1285-46-548-631
- Fujii K, Katoh S, Sairyo K, Ikata T, Yasui N (2004) Union of defects in the pars interarticularis of the lumbar spine in children and adolescents. The radiological outcome after conservative treatment. *J Bone Jt Surg Br* 86:225–231
- Sairyo K, Sakai T, Yasui N (2009) Conservative treatment of lumbar spondylolysis in childhood and adolescence: the radiological signs which predict healing. *J Bone Jt Surg Br* 91:206–209. doi:10.1302/0301-620X.91B2.21256
- Gillet P, Petit M (1999) Direct repair of spondylolysis without spondylolisthesis, using a rod-screw construct and bone grafting of the pars defect. *Spine* 24:1252–1256
- Kakiuchi M (1997) Repair of the defect in spondylolysis. Durable fixation with pedicle screws and laminar hooks. *J Bone Jt Surg Am* 79:818–825
- Tokuhashi Y, Matsuzaki H (1996) Repair of defects in spondylolysis by segmental pedicular screw hook fixation. A preliminary report. *Spine* 21:2041–2045
- L’Heureux EA Jr, Perra JH, Pinto MR, Smith MD, Denis F, Lonstein JE (2003) Functional outcome analysis including pre-operative and postoperative SF-36 for surgically treated adult isthmic spondylolisthesis. *Spine* 28:1269–1274. doi:10.1097/01.BRS.0000065574.20711.E6
- La Rosa G, Conti A, Cacciola F, Cardali S, La Torre D, Gambadauro NM, Tomasello F (2003) Pedicle screw fixation for isthmic spondylolisthesis: does posterior lumbar interbody fusion improve outcome over posterolateral fusion? *J Neurosurg* 99:143–150
- Kwon BK, Hilibrand AS, Malloy K, Savas PE, Silva MT, Albert TJ, Vaccaro AR (2005) A critical analysis of the literature regarding surgical approach and outcome for adult low-grade isthmic spondylolisthesis. *J Spinal Disord Tech* 18(Suppl):S30–S40