

## Thoracic intervertebral disc calcification and herniation in adults: a report of two cases

Bin Yue<sup>1</sup> · Bohua Chen<sup>1</sup> · Yun-wen Zou<sup>1</sup> · Yong-ming Xi<sup>1</sup> · Xian-feng Ren<sup>1</sup> · Hong-fei Xiang<sup>1</sup> · You-gu Hu<sup>1</sup> · Guoqing Zhang<sup>1</sup>

Received: 17 January 2015/Revised: 26 August 2015/Accepted: 26 August 2015/Published online: 2 September 2015  
© Springer-Verlag Berlin Heidelberg 2015

### Abstract

**Purpose** Acute paraplegia due to thoracic intervertebral disc protrusion and calcification is rare. The purpose of this study was to report two cases with acute paraplegia due to a calcified thoracic disc prolapse, and discuss its clinical diagnosis and surgical treatment with literature reviews.

**Methods** These two cases were verified by patient history, physical examination, laboratory examination, CT and MRI studies, and pathological findings.

**Results** CT scan revealed disc calcification and protrusion at the T11–12 level in case 1 and at the T10–11 level in case 2, respectively. MRI images revealed severe spinal cord compression with a hyperintense central core and surrounding hypointense area in two cases, which were directly connected to the calcified intervertebral nucleus pulposus. Pathological examination revealed calcium deposition. Patients underwent discectomy followed by interbody fusion, and satisfactory therapeutic outcomes were obtained.

**Conclusions** We suggest that decompression surgery should be carried out as early as possible for patients with early spinal myelopathy or paraplegia caused by a calcified protruded disc.

**Keywords** Thoracic disc herniation · Calcification · Paraplegia · Protrusion

### Introduction

Intervertebral disc calcification (IDC) represents a common incidental finding on radiographic examinations. Previous studies have shown that the prevalence of IDC in the general adult population accounts for 5 and 6 % of chest and abdominal radiographs, respectively [1, 2]. Calcification occurs predominately at the cervical spine, followed by the thoracic and lumbar spine. Thoracic disc herniation is relatively uncommon, and has an incidence of approximately one case per million of habitants per year [3]. Thoracic disc herniation usually occurs in the lower third of the thoracic spine. Majority of posterior thoracic disc herniations are quite small and clinically insignificant [4]. Acute paraplegia due to intervertebral disc protrusion and calcification is even rarer. In this study, we describe two cases of acute paraplegia in adults due to spinal cord compression caused by calcified and herniated thoracic discs, and discuss its clinical diagnosis and surgical treatment with literature reviews.

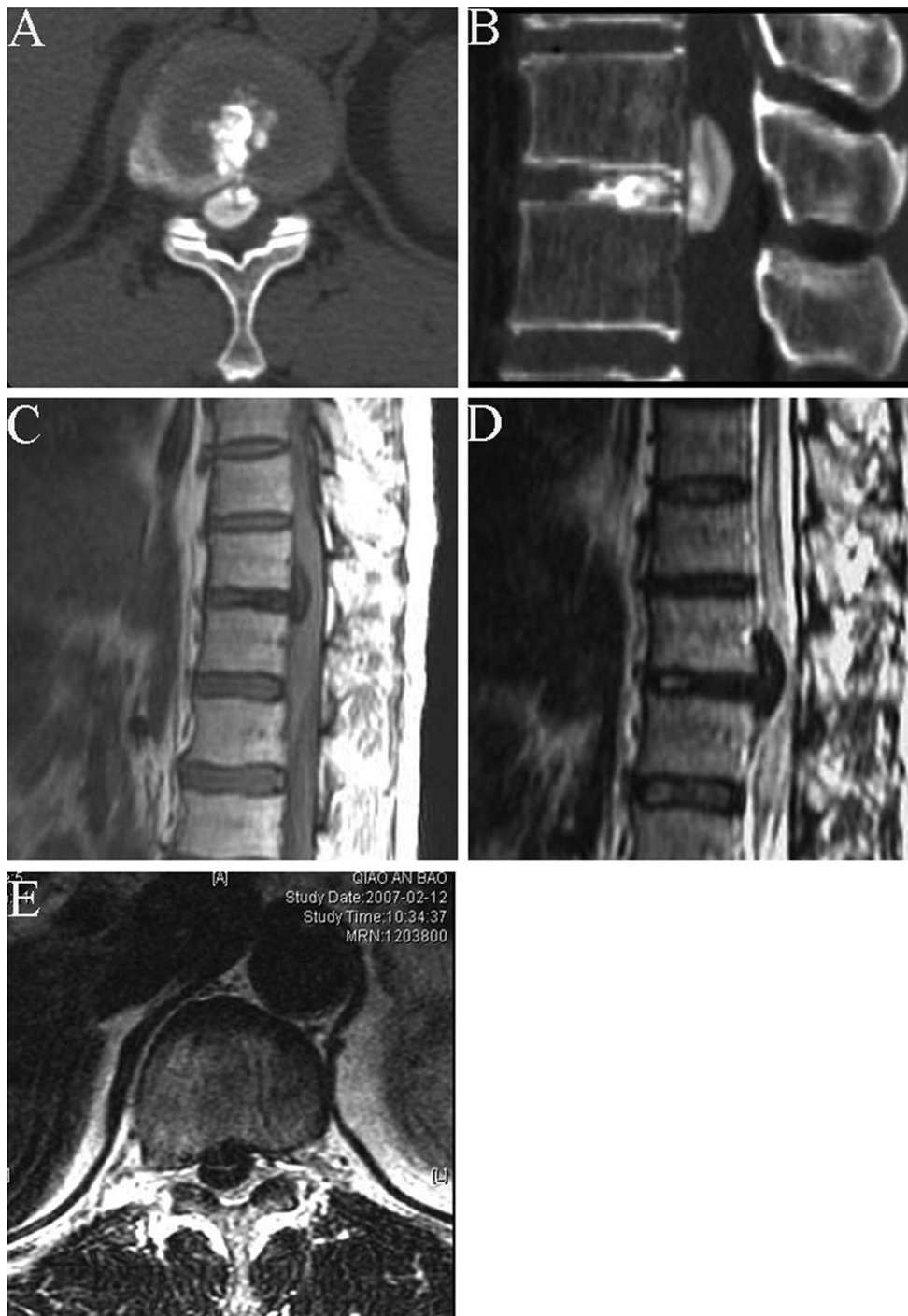
### Case reports

#### Case 1

A 57-year-old male presented with back pain for 40 days, bilateral lower extremity numbness and weakness for 20 days, and bowel or bladder incontinence for 5 days. Physical examination revealed a diminished sensation below the T<sub>11</sub> level, bilateral lower extremity paraplegia (muscle force for zero level), diffuse hyperreflexia (patellar jerk and Achilles tendon reflex for +++), and positive Babinski signs. Laboratory examination revealed that erythrocyte sedimentation rate (6 mm/h), hemogram

✉ Guoqing Zhang  
zhangguoqing100@yeah.net

<sup>1</sup> Department of Spine Surgery, The Affiliated Hospital of Medical College, Qingdao University, LaoShan District, 59 Haier Road, Qingdao 266101, People's Republic of China

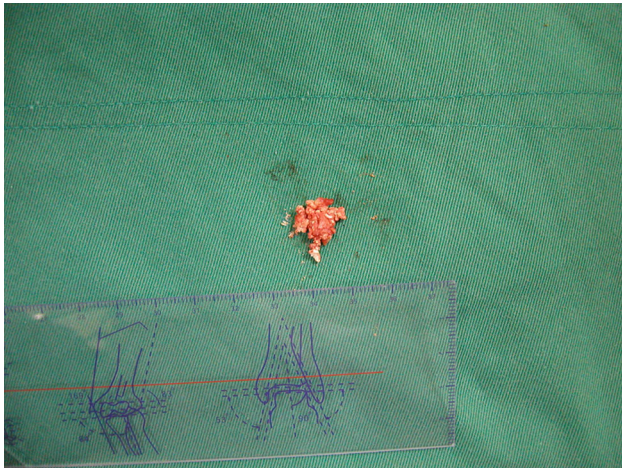


**Fig. 1** CT scan reveals disc calcification and protrusion at the T<sub>11–12</sub> level (a, b). MRI images reveal severe spinal cord compression with a hyperintense central core and surrounding hypointense area, which are directly connected to the calcified intervertebral nucleus pulposus (c, d, e)

(129 mmol/L), calcium (2.21 mmol/L), C-reactive protein (0.93 mmol/L), creatinine (68  $\mu$ mol/L), and blood urea nitrogen (5.47 mmol/L) were within normal limits. Computed tomography (CT) confirmed nucleus pulposus calcification with posterior central herniation within the disc space at the T<sub>11–12</sub> level (Fig. 1a, b). MRI revealed severe

spinal cord compression at the T<sub>11–12</sub> disc level from an anterior lesion, in which there was a hyperintense central core and surrounding hypointense area (Fig. 1c–e). A calcified thoracic intervertebral disc with herniation was initially determined. The patient underwent discectomy by means of a posterior transfacet approach, followed by

interbody fusion with instrumentation. Using a small curette and a pituitary rongeur, the calcified portion of the disc was easily removed in a piecemeal fashion. The remaining calcified substance was removed by continuous irrigation and suction. Intraoperative findings were as follows. The calcified herniated disc was like a semisolid-toothpaste (Fig. 2). Pathological examination revealed degenerative fibrocartilage and calcium deposition. Figure 3 shows a

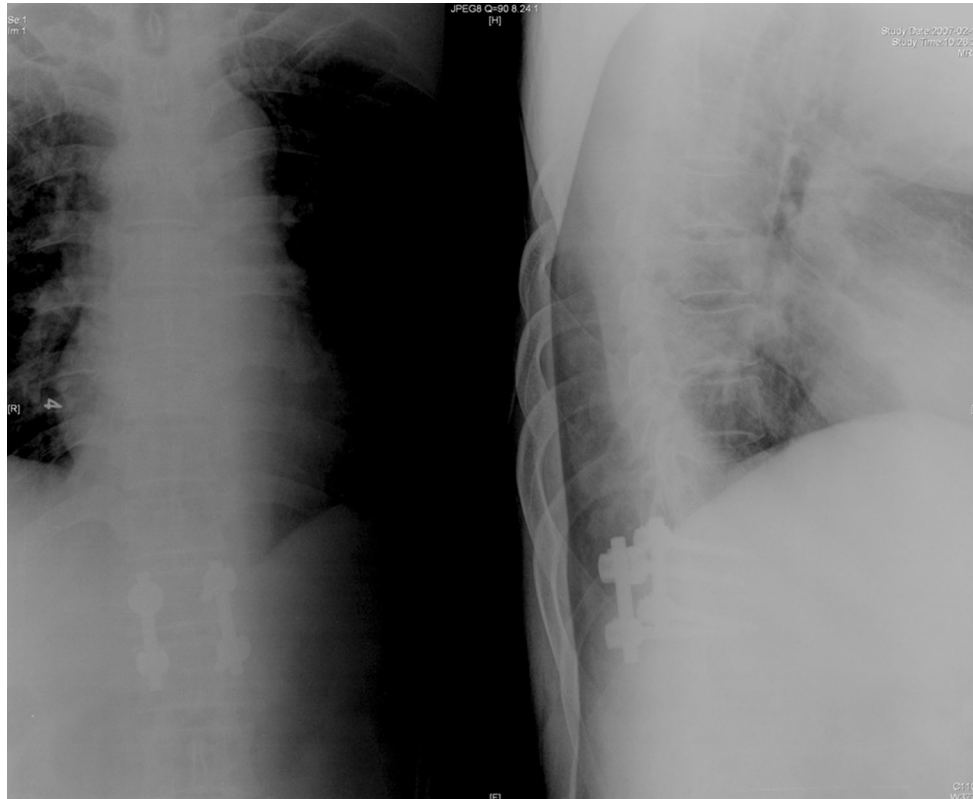


**Fig. 2** The calcified disc was removed

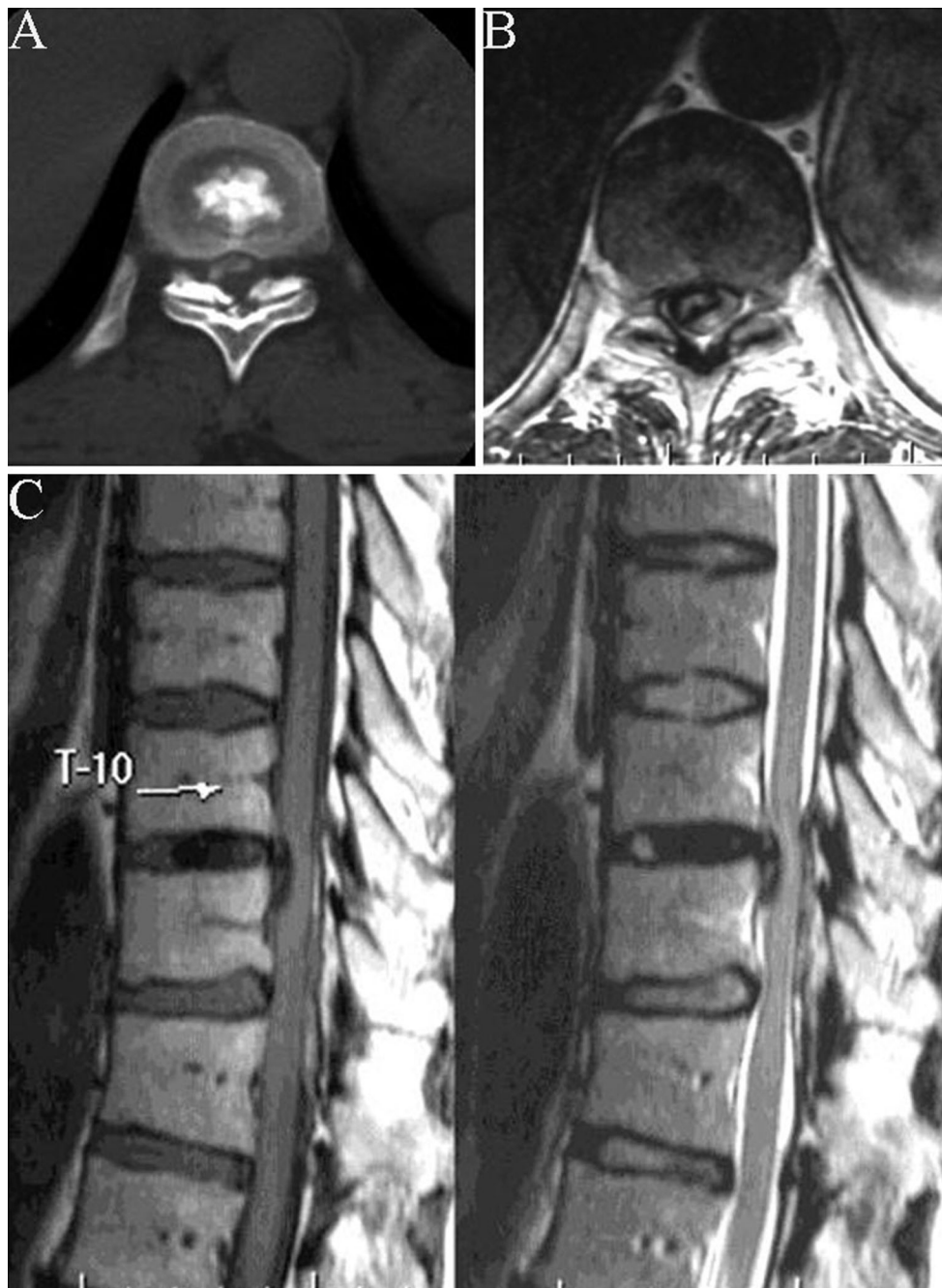
2-year follow-up conventional radiograph. The patient did not reveal any substantial functional change after surgery and during the follow-up period (e.g., muscle force, hyperreflexia, Babinski signs).

## Case 2

A 53-year-old male presented with back pain for 2 months, bilateral lower extremity paraplegia, and bowel or bladder incontinence for 15 days. The patient received conservative treatment at a local hospital before he was admitted to our hospital. Upon admission to our hospital, the patient presented with chief complaints of back pain. Physical examination revealed bilateral lower extremity paresis below the T<sub>10</sub> level, bilateral lower extremity paraplegia (muscle force for zero level), and diffuse hyperreflexia (patellar jerk and Achilles tendon reflex for ++++) with positive Babinski signs. Erythrocyte sedimentation rate (7 mm/h), hemogram (126 mmol/L), calcium (2.2 mmol/L) and C-reactive protein (1.53 mmol/L), creatinine (49.8 μmol/L), and blood urea nitrogen (3.17 mmol/L) were all normal. CT revealed a high-density mass at the T<sub>10–11</sub> disc level (Fig. 4a), and MRI revealed severe spinal cord compression with a hyperintense central core and surrounding hypointense area at the T<sub>10–11</sub> disc level



**Fig. 3** Two-year follow-up reveals intervertebral fusion



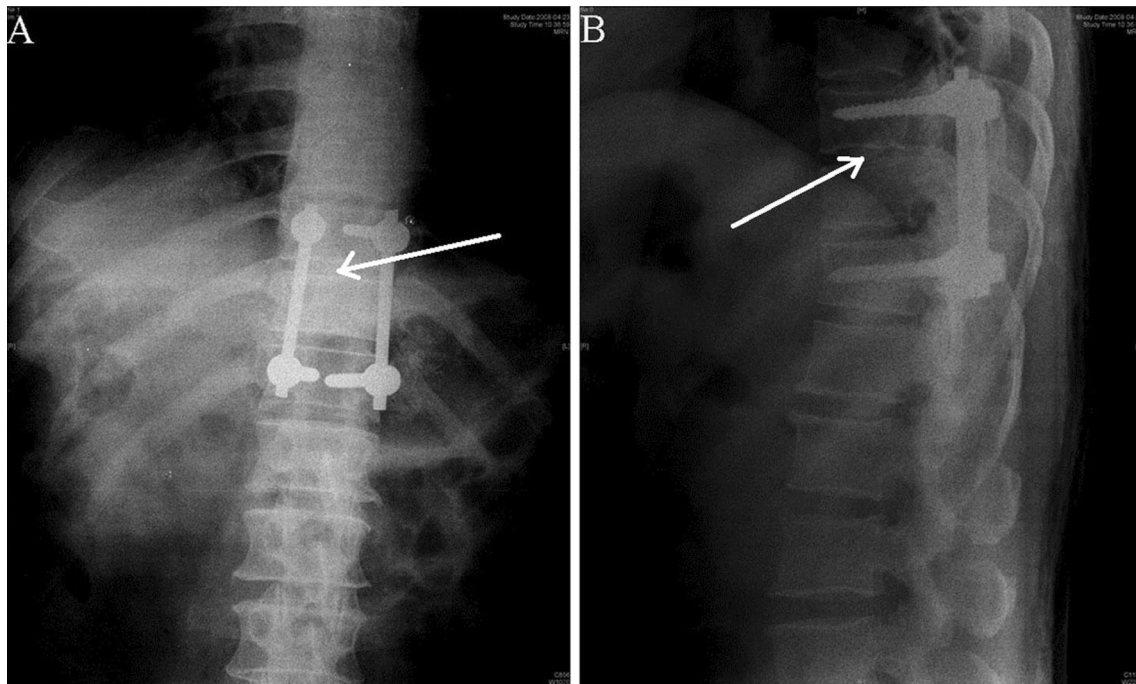
**Fig. 4** CT scan confirms disc calcification and protrusion at the  $T_{10-11}$  level (a). MRI images reveal severe spinal cord compression with a hyperintense central core and surrounding hypointense area, which are directly connected to the calcified intervertebral nucleus pulposus (b, c)

(Fig. 4b, c). The diagnosis was intervertebral disc calcification and protrusion, and the patient underwent discectomy through transversoarthropediclectomy via bilateral posterolateral approach and interbody fusion with instrumentation. Intraoperative findings were similar to “Case 1”, in which the calcified disc was also like a semisolid-toothpaste. Pathological examination revealed calcium deposition. A 6-month follow-up conventional radiograph was obtained (Fig. 5). The patient completely recovered

after 6 months of follow-up (e.g., sensation, muscle force, hyperreflexia, and Babinski signs).

## Discussion

Imaging studies and determining the real hardness of the calcified protruded disc by intraoperative palpation were interesting, and provided good suggestions for the surgical



**Fig. 5** Six-month follow-up reveals the complete removal of calcification and herniation. *Arrows* bone mass shadows

management of future similar cases. In this study, the calcified protruded disc in these two cases appeared to be hard on CT images, and MRI confirmed severe spinal cord compressions with a hyperintense central core and surrounding hypointense area. Surgical intervention through anterior or posterolateral approaches was the only option for these two cases. The structural feature contraindicating a posterolateral approach to a central disc herniation was defined as “ossification”. Therefore, it is difficult to confirm if thoracic herniation is calcified but not ossified, since the posterior approach is very dangerous for an ossified herniated disc. Patients in this study were evaluated by experienced surgeons before surgery. The decision to perform a posterior approach was based on the following preoperative imaging findings: (1) changes in intervertebral disc space height in calcified herniated discs are not obvious; (2) preoperative images of calcified herniated discs display a protruded intervertebral disc with a clear edge (ossified intervertebral disc herniation would show an unclear edge). Intraoperative findings confirmed that the calcified protruded disc was semisolid, and was easily removed via posterolateral approach.

Before surgery, attention should be given to the hardness of the calcified protruded disc, as it is very important for surgical planning and subsequent resections. In some cases, it shows high-signal intensity on T1-weighted MRI [5–8]. Interestingly, we observed that the calcified intervertebral discs in these two cases were semisolid, and had a toothpaste-like consistency [9, 10] by palpation. In clinical

practice, morphological features for differentiating the hardness of calcified discs are obvious in imaging studies. However, real hardness of a calcified disc could not be accurately assessed by signal density on CT or MRI. The clipper-built contour of the calcified protruded disc usually indicates that the mass is soft or semiliquid, rather than a hard bone-like mass. Thus, we recommend that decompression surgery should be carried out as early as possible for patients with early spinal myelopathy or paraplegia due to a calcified protruded disc. In our series, the surgical procedure was smoothly performed beyond expectations, because the calcified disc was semisolid instead of having a hard bone-like mass. Moreover, sporadic calcified disc tissues were well flushed out by continuous irrigation and suction.

The etiology of calcifying tendinitis of the rotator cuff was the crystal deposition of calcium pyrophosphate dihydrate, which is occasionally observed in cervical and lumbar regions, and is rarely observed in the thoracic spine [11, 12]. At present, the exact mechanism of calcium deposits remains unclear. However, the development of this disease was based on calcium deposits. After long periods of stable calcium deposits, a phase of spontaneous liquefaction, inflammatory response, and granuloma formation may occur during the spontaneous resolution of these deposits. Acute pain may occur during this process, and eventually progress to tendinitis, which may inversely aggravate the pain. In this study, the mechanism of the thoracic disc calcification remains unclear. Its mechanism

may be similar to the development of calcifying tendinitis of the rotator cuff. It could be assumed that calcification can develop after long periods of stable calcium deposits in the thoracic intervertebral disc. During this stage, no clinical symptoms can be observed. Thereafter, a series of spontaneous liquification and inflammatory response damaged the fibrous rings, and eventually resulted in thoracic disc herniation and severe neurological symptoms. The two patients in this study did not report any shoulder discomfort; thus, the examination program for calcifying tendinitis of the rotator cuff was not conducted. No calcification or calcium deposits were found on other parts of the body of the two patients. Therefore, this hypothesis remains to be confirmed.

Paolini et al. reported two cases with misleading imaging appearances of protruded lesions [12]. High-density protruded lesions were observed on CT scans, while there was a lack of signal on T1- and T2-weighted MRI sequences. In our cases, the imaging appearance of the protruded lesions was similar to these previous cases. The distinctive finding in our two cases was the relative high-signal intensity of the middle part of the protruded lesions, compared to the marginal part of the protruded lesions. In addition, we observed that the free nucleus pulposus tissue during surgery was like a semisolid-toothpaste with a smooth, lentiform and round shape, which could be completely removed after flushing with wash water. All these findings confirmed intervertebral disc calcification and its liquid appearance, and further supported the above hypothesis. Thus, preoperative qualitative diagnosis of protruded lesions is very important, because it may affect the planning of surgical regimens. However, further studies are warranted.

Spinal canal width in the thoracic vertebrae was extremely minimal. The thoracic spinal cord would account for a large proportion of volumes in the spinal canal. Once anterior or posterior compression occurs, cushion space of the thoracic spinal cord would be very small. Thus, spinal cord compression would progress if decompression surgery is not timely performed, which would inevitably cause spinal cord injury. Therefore, we suggest that decompression surgery should be carried out as early as possible for patients with early spinal myelopathy or paraplegia caused by a calcified protruded disc. The number of the cases in

this study was small, and long-term curative effects need to be followed up.

#### Compliance with ethical standards

**Conflict of interest** The authors declare no conflict of interest with this work.

#### References

- Weinberger A, Myers AR (1978) Intervertebral disc calcification in adults: a review. *Semin Arthritis Rheum* 8:69–75. doi:[10.1016/0049-0172\(78\)90035-5](https://doi.org/10.1016/0049-0172(78)90035-5)
- Nogueira-Barbosa MH, da Silva Herrero CFP, Pasqualini W, Defino HLA (2013) Calcific discitis in an adult patient with intravertebral migration and spontaneous remission. *Skelet Radiol* 42:1161–1164
- Okada Y, Shimizu K, Ido K, Kotani S (1997) Multiple thoracic disc herniations: case report and review of the literature. *Spinal Cord* 35:183–186
- Coscia MF, Strate RW (1993) Calcified thoracic disc herniation with paraparesis. A case report. *Acta Orthop Scand* 64:489–490
- Major NM, Helms CA, Genant HK (1993) Calcification demonstrated as high signal intensity on T1-weighted MR images of the disks of the lumbar spine. *Radiology* 189:494–496. doi:[10.1148/radiology.189.2.8210379](https://doi.org/10.1148/radiology.189.2.8210379)
- Bangert BA, Modic MT, Ross JS, Obuchowski NA, Perl J, Ruggieri PM, Masaryk TJ (1995) Hyperintense disks on T1-weighted MR images: correlation with calcification. *Radiology* 195:437–443. doi:[10.1148/radiology.195.2.7724763](https://doi.org/10.1148/radiology.195.2.7724763)
- Henkelman RM, Watts JF, Kucharczyk W (1991) High signal intensity in MR images of calcified brain tissue. *Radiology* 179:199–206. doi:[10.1148/radiology.179.1.1848714](https://doi.org/10.1148/radiology.179.1.1848714)
- Dell LA, Brown MS, Orrison WW, Eckel CG, Matwiyoff NA (1988) Physiologic intracranial calcification with hyperintensity on MR imaging: case report and experimental model. *AJNR Am J Neuroradiol* 9:1145–1148
- Park SM, Kim ES, Sung DH (2005) Cervical radiculopathy caused by neural foraminal migration of a herniated calcified intervertebral disk in childhood: a case report. *Arch Phys Med Rehabil* 86:2214–2217. doi:[10.1016/j.apmr.2005.06.009](https://doi.org/10.1016/j.apmr.2005.06.009)
- Peck FC Jr (1957) A calcified thoracic intervertebral disk with herniation and spinal cord compression in a child; case report. *J Neurosurg* 14:105–109. doi:[10.3171/jns.1957.14.1.0105](https://doi.org/10.3171/jns.1957.14.1.0105)
- McAllister VL, Sage MR (1976) The radiology of thoracic disc protrusion. *Clin Radiol* 27:291–299
- Paolini S, Ciappetta P, Guiducci A, Principi M, Missori P, Delfini R (2005) Foraminal deposition of calcium pyrophosphate dihydrate crystals in the thoracic spine: possible relationship with disc herniation and implications for surgical planning. Report of two cases. *J Neurosurg Spine* 2:75–78. doi:[10.3171/spi.2005.2.1.0075](https://doi.org/10.3171/spi.2005.2.1.0075)