

# Lavage prior to vertebral augmentation reduces the risk for cement leakage

Sven Hoppe<sup>1</sup> · Tarek Elfiky<sup>2</sup> · Marius Johann Baptist Keel<sup>1</sup> · Emin Aghayev<sup>3</sup> · Timo Michael Ecker<sup>1</sup> · Lorin Michael Benneker<sup>1</sup>

Received: 13 April 2015/Revised: 8 August 2015/Accepted: 9 August 2015/Published online: 15 August 2015  
© Springer-Verlag Berlin Heidelberg 2015

## Abstract

**Purpose** This study aimed at assessing the cement leakage rate and the filling pattern in patients treated with vertebroplasty, kyphoplasty and stentoplasty with and without a newly developed lavage technique.

**Study design** Retrospective clinical case–control study.

**Methods** A newly developed bipedicular lavage technique prior to cement application was applied in 64 patients (45.1 %) with 116 vertebrae, (“lavage” group). A conventional bipedicular cement injection technique was used in 78 patients (54.9 %) with 99 levels (“controls”). The outcome measures were filling patterns and leakage rates.

**Results** The overall leakage rate (venous, cortical defect, intradiscal) was 37.9 % in the lavage and 83.8 % in the control group ( $p < 0.001$ ). Venous leakage (lavage 12.9 % vs. controls 31.3 %;  $p = 0.001$ ) and cortical defect leakage (lavage 17.2 % vs. controls 63.3 %;  $p < 0.001$ ) were significantly lower in the lavage group compared to “controls,” whereas intradiscal leakages were similar in both groups (lavage 12.1 % vs. controls 15.2 %;  $p = 0.51$ ). For venous leakage multivariate logistic regression analysis showed lavage to be the only independent predictor. Lavage was associated with 0.33-times (95 % CI 0.16–0.65;

$p = 0.001$ ) lower likelihood for leakage in compared to controls.

**Conclusions** Vertebral body lavage prior to cement augmentation is a safe technique to reduce cement leakage in a clinical setting and has the potential to prevent pulmonary fat embolism. Moreover, a better filling pattern can be achieved.

**Keywords** Vertebroplasty · Lavage · Leakage · Balloon kyphoplasty · Complication · PMMA

## Introduction

Osteoporotic vertebral compression fracture (VCF) is one of the most common complications of osteoporosis affecting estimated 1.4 million people worldwide annually [1]. Conservative management cannot reverse the kyphotic deformities that cause biomechanical changes in the spinal segment and increase the incidence of adjacent vertebral fractures [1, 2]. Moreover, VCFs result in prolonged hospitalization. The minimally invasive percutaneous vertebral augmentation techniques of vertebroplasty (VP), balloon kyphoplasty (KP) and stentoplasty (SP) comprising the injection of polymethylmethacrylate (PMMA) are effective procedures for immediate postoperative pain alleviation caused by VCF [3]. VP and KP are widely accepted treatments with reported pain relief in approximately 70–100 % [4].

However, augmentation techniques using PMMA must be done with caution. Potential serious complications may occur with the intraosseous injection of cement. The risk of extraosseous cement leakage in various series ranged between 3 and 74 % [5–8], with resultant neurological deficits such as radiculopathy and cord compression

---

S. Hoppe and T. Elfiky have equally contributed to the paper.

✉ Sven Hoppe  
svenhoppe@gmail.com; sven.hoppe@insel.ch

- <sup>1</sup> Department for Orthopedic Surgery, Spine Unit, Inselspital, University Hospital of Bern, 3010 Bern, Switzerland
- <sup>2</sup> Spine Surgery Unit, El-Hadra University Hospital, Alexandria University, Alexandria, Egypt
- <sup>3</sup> Institute for Evaluative Research in Medicine, University of Bern, Stauffacherstrasse 78, 3014 Bern, Switzerland

occurring in 0–3.7 and 0–0.5 %, respectively [5, 6, 8–10]. The risk of pulmonary cement embolism lies between 3.5 and 23 % [11–14]. In addition to unwanted cement leakage also pulmonary fat embolism occurs as a result of the displacement of intraosseous bone marrow by the cement resulting in the occlusion of blood vessels downstream, most notably in the lungs. The acute consequences of fat embolism may be hypotension, cardiac arrest, and, in serious cases, sudden death [15–17]. Bone marrow particles cause microembolization of the arterioles and capillaries of the lungs resulting in an increase in pulmonary arterial pressure, a systemic arterial hypotension, and a drop in heart rate [17, 18]. Moreover, hypotension can be result of cement monomers and vasoactive mediators gaining access to the circulation [19, 20].

To decrease these types of complication the number of augmented vertebrae should be limited to six levels per session or 25–30 cc of PMMA according to Heini et al. [21], knowing that the cement volume is the most important modifiable predictor for pain relief in KP [22]. This cut-off was empirically determined and means a higher risk for pulmonary problems when injecting larger volumes. On the other hand, Aebli et al. demonstrated in an animal study that already smaller volumes of injected PMMA lead to measurable cardiovascular changes as hypotension drop of cardiac output and pulmonary hypertension that may be fatal in older and/or pulmonary impaired patients [20]. They also showed a cumulative increase of fat embolism in lung biopsies in sheep after multiple level augmentations [20].

The cement viscosity issue is also a crucial parameter that is associated with the risk of cement leakage [23, 24]. Injecting PMMA at a low viscosity leads to a scattered, fingerlike, uncontrolled cement distribution pattern and, as a consequence, an increased chance of cement leakage. By the injection of the cement at higher viscosity, a uniform and better-controlled filling pattern can be achieved. During polymerization of commonly used PMMA cements, the viscosity steadily increases. Hence, the cement should be injected at the latest time point possible to have cement that is viscous enough to prevent leakage and extravasation [25–27].

Based on these considerations a lavage technique for vertebroplasty was developed, which enables the surgeon to wash out the intertrabecular bone marrow of the vertebrae before PMMA injection. This leads theoretically to a reduction of fat embolism by reducing the intravertebral resistance and injection forces [28]. In a cadaveric feasibility study Benneker et al. tested the lavage technique in 24 intact vertebral bodies harvested from five osteopenic or osteoporotic human cadaver spines [29]. The study showed a reduction of injection forces that allows the use

of more viscous PMMA cement. This lowers potentially the risk of cement leakage and fat embolization and makes vertebral augmentation safer [29]. It could be shown in a sheep model that lavage of the bone marrow prior to VP prevents cardiovascular complications, reduces injection forces and allows a better control of cement distribution pattern with less leakage [30, 31]. The advantages of lavage technique were not yet assessed in clinical studies.

In our hospital a simplified lavage technique prior to vertebral augmentations using PMMA cement in vertebral fractures is used since 2012.

The objective of this study was to assess radiologically the filling patterns of the cement and the cement leakage rates in patients treated with VP, KP or stentoplasty (SP) with and without lavage.

## Materials and methods

### Patient sample

The local medical ethical committee of the authors' institution approved the study.

The study included 142 consecutive patients with osteoporotic VCF who were treated in the period from January 2012 to August 2014 in our hospital. Osteoporotic VCF was diagnosed primarily on the basis of simple a.-p. and lateral standing X-ray of the spine and confirmed in computed tomography.

Four surgeons were involved in the study, and, overall, 215 levels were augmented in the 142 patients. Two surgeons consequently applied the newly developed lavage technique prior to cement application in 64 patients (45.1 %) with 116 vertebrae (1.8 vertebrae per patient). These were assigned to the interventional "lavage" group. Two other surgeons used a conventional cement injection technique and treated 78 patients (54.9 %) with 99 vertebrae (1.3 vertebrae per patient), who were assigned to "controls".

### Surgical technique

Three types of vertebral augmentation were used: VP, KP and SP. All procedures took place under general anesthesia. The reduction of the fractures was supported by prone patient positioning on a special mattress on the operating table to aggravate the lordosis and promote partial height restoration via ligamentotaxis. A bipedicular approach with the Jamshidi needles under fluoroscopic imaging was used in all patients. Cement preparation was performed according to the manufacturer's manual (Vertecem V+, Synthes, Bettlach, Switzerland), injection of cement was

stopped when either a sufficient filling of the vertebra was achieved (endplate to endplate) or cement leakage was observed.

In the kyphoplasty group a standard kyphoplasty device (SYNFLATE—Vertebral Balloon System, Synthes Bettlach, Switzerland), for the stentoplasty a standard stentoplasty device (VBS—Vertebral Body Stenting System, Synthes, Bettlach, Switzerland) was used according to the manufacturer’s manual. All reviewed cases were done with and bipedicular approach. After reduction of the fracture, cement injection was performed under fluoroscopic imaging as usual.

### Lavage technique

The lavage procedure was performed with two 20 ml standard syringes (Injekt™ Syringe 20 ml LL, B. Braun Medical AG, Sempach, Switzerland) connected to the top of the each Jamshidi needle (Fig. 1). One of the syringes was filled with 10 ml saline solution. By the application of suction to the contralateral syringe, a negative pressure inside the vertebral body was produced. This negative pressure sucked in the saline solution from the filled syringe through the vertebral body. Thus, the intravertebral bone marrow was washed out. After filling the empty syringe with saline-bone-marrow solution the syringe was discarded. Then the lavage procedure was performed the other way around changing the positions of the filled and empty syringes. Two lavages in each direction resulted in a total of four lavages for each vertebral body. Usually after the 3rd passage the aspirated fluid is nearly clear.

After the lavages the augmentation of the vertebral body was performed as usual, aiming for a large cement volume (“endplate-to-endplate” distribution). In the kyphoplasty and the stentoplasty groups lavage was performed prior to balloon dilatation (after creating the working channel, prior to balloon insertion).

### Radiological assessment and outcome measures

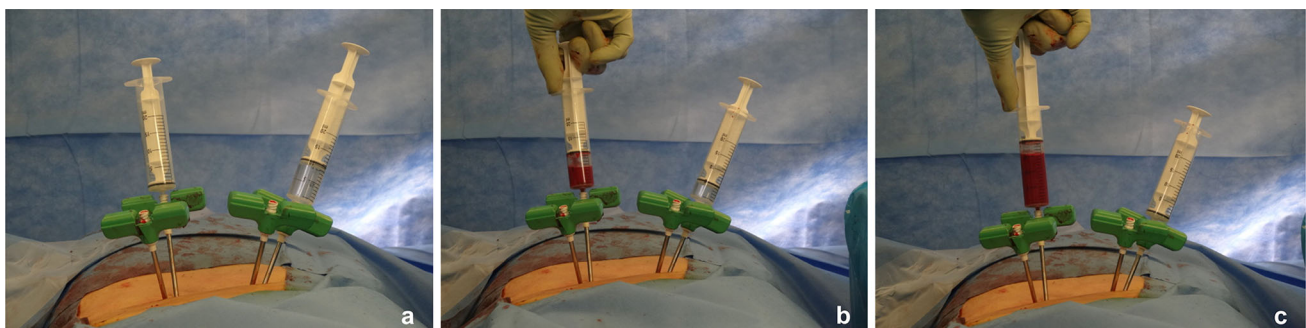
Preoperative a.-p. and lateral X-ray were taken prior to surgery. Postoperative X-ray was performed on the first postoperative day. The X-rays were assessed on the PACS Sectra Workstation in the DICOM format (IDS7, Sectra, Sweden). All fractures were classified according to the AO-Magerl classification [32]. The fracture level and type of augmentation (VP, KP and SP) were assessed.

Cement filling pattern was analyzed on the postoperative X-ray images and classified based on a four-gradient scale into insufficient filling pattern (<25 % of the vertebra), medium filling pattern (25–50 %), sufficient filling pattern (50–75 %) and endplate-to-endplate filling pattern (100 %). Any cement located outside the vertebra was considered leakage and was classified based on their location: via the segmental or basivertebral vein (=venous leakage), through a cortical defect or through the endplate. If the leakage was into the spinal canal or into the intervertebral foramen it was judged as “posterior leakage”. Both cement filling pattern and cement leakage were assessed by an independent evaluator who was blinded to the group assignment.

### Statistical analysis

For the descriptive statistics, means and standard deviations were calculated and minimum and maximum values extracted. The non-parametric Wilcoxon rank-sum test was used for comparison of continuous and the Chi-square test for categorical variables.

A binomial multivariate logistic regression model was built to find out predictors for (1) an overall leakage, (2) for a venous leakage, (3) for cortical defect leakage and (4) for a leakage into intervertebral disc based on all cemented levels. Stepwise selection was used in these models. Furthermore, a multivariate linear regression was calculated to find predictors. Following covariates were



**Fig. 1** Lavage technique: lavage procedure with two 20 ml syringes: **a** attachment of one empty syringe and one filled syringe to the 8 Ga Jamshidi-Biopsy needles located in vertebral pedicles; **b** application

of suction (negative pressure) to the empty syringe; **c** suction in of the intravertebral bone marrow and the saline solution from the contralateral syringe

included in the models: patient age, sex, fracture type, grouped segments (Th1–Th10, Th11–Th12, L1–L5), augmentation technique (KP, ST, VP) and the treatment group (lavage, control).

The significance level was set to 0.05 throughout the study. All statistical analyses were conducted using SAS 9.4 (SAS Institute, Inc., Cary, NC, USA).

## Results

### Patient characteristics

Patient characteristics are shown in Table 1. The distributions of patient characteristics was similar between the groups with the exception of the proportions of the fracture types. Prophylactic augmentation was more common in the lavage group while the fracture pattern A1.2 was more common in the controls ( $p < 0.001$ ) (Table 1). Due to the same number of balloon-assisted procedures (VP and SP) in both groups (25.8 % in the lavage vs. 25.3 % in the non-lavaged group) we did not further split up the groups regarding the augmentation techniques.

### Outcome parameters

#### Leakage rate

There were 44 vertebrae (20 patients) with 49 leakages in the lavage group, and 83 vertebrae (68 patients) with 109

leakages in the control group (vertebra-based  $p < 0.001$ ; Table 2).

The proportion of overall, venous and cortical defect leakages were different in favor of the lavage group ( $p \leq 0.001$ ; Table 2), while the proportion of intradiscal leakages was similar ( $p = 0.51$ ; Table 2). Posterior leakage was very rare ( $n = 5$ ).

#### Overall leakage

The multivariate logistic regression analysis for an overall leakage based on all cemented levels showed lavage and fracture type, but not age, sex and grouped segments, to be independent predictors. Moreover, augmentation technique (VP, KP, SP) could not be shown to be a predicting factor for leakage. A prophylactic cement augmentation was associated with 0.39-times [95 confidence intervals (95 % CI) 0.16–0.99;  $p < 0.001$ ] lower likelihood for an overall leakage in comparison to fracture. Lavage was associated with 0.13-times (95 % CI 0.07–0.27;  $p = 0.005$ ) lower likelihood for an overall leakage in comparison to control.

#### Venous leakage

The multivariate logistic regression analysis for a venous leakage also based on all cemented levels showed lavage to be the only independent predictor. Lavage group was associated with 0.33-times (95 % CI 0.16–0.65;  $p = 0.001$ ) lower likelihood for such a leakage in comparison to control.

**Table 1** Patient characteristics of the treatment groups

Patient characteristics	Lavage	Controls	<i>p</i> value
<i>N</i> patients	64	78	–
<i>N</i> vertebrae	116	99	–
Mean age in years $\pm$ SD	74.3 $\pm$ 11.5	74.9 $\pm$ 11.4	0.76
Age range	42–96	48–92	–
Female (%)	76.6	68	0.26
Fractured vertebrae ( <i>N</i> )	79	89	–
Th1–Th10 (%)	18.1	9.1	0.15
Th11–12 (%)	29.3	30.3	
L1–L5 (%)	52.6	60.6	
No fracture/prophylactic augmentation (%)	<b>33.6</b>	<b>6.1</b>	<b>&lt;0.001</b>
A1.2 (%)	<b>24.1</b>	<b>50.5</b>	
A1.3 (%)	27.6	30.3	
A3.1 (%)	12.1	12.1	
Other (A1.1, A2.1, A2.3)	2.6	1	
KP (%)	17.2	10.1	
SP (%)	8.6	15.2	0.14
VP (%)	74.1	74.8	

Significant differences are marked in bold

SD standard deviation

**Table 2** Outcome measures (filling pattern, leakage rate and extent of leakage) in the groups

Outcomes	Lavage <i>n</i> = 116	Control <i>n</i> = 99	<i>p</i> value
Insufficient filling pattern <25 % (%)	–	<b>1</b>	<b>&lt;0.001</b>
Medium filling pattern 25–50 % (%)	<b>2.7</b>	<b>12.2</b>	
Sufficient filling pattern 50–75 % (%)	<b>64.3</b>	<b>74.5</b>	
Endplate-to-endplate filling pattern 100 % (%)	<b>33</b>	<b>12.2</b>	
Vertebrae with a leakage: overall ( <i>N</i> [%])	<b>44 [37.9]</b>	<b>83 [83.8]</b>	<b>&lt;0.001</b>
Vertebrae with a leakage: venous ( <i>N</i> [%])	<b>15 [12.9]</b>	<b>31 [31.3]</b>	<b>0.001</b>
Vertebrae with a leakage: cortical defect ( <i>N</i> [%])	<b>20 [17.2]</b>	<b>63 [63.6]</b>	<b>&lt;0.001</b>
Vertebrae with a leakage: intradiscal ( <i>N</i> [%])	14 [12.1]	15 [15.2]	0.51
Extent of leakage, overall: <2 mm ( <i>N</i> [%])	27 [61.4]	36 [43.4]	0.1
Extent of leakage, overall: 2–10 mm ( <i>N</i> [%])	14 [31.8]	40 [48.2]	
Extent of leakage, overall: >10 mm ( <i>N</i> [%])	2 [4.6]	7 [8.4]	

Significant differences are marked in bold

### Cortical leakage

The multivariate logistic regression analysis for a cortical leakage revealed fracture type and lavage to be the independent predictors. Lavage group was associated with 0.15-times (95 % CI 0.08–0.30;  $p < 0.001$ ) lower likelihood for cortical leakage in comparison to control.

### Filling pattern

The distributions of cement filling patterns were different between the groups in favor of the lavage group ( $p < 0.001$ ; Table 2). In terms of the extent of leakage the groups were similar ( $p = 0.10$ ; Table 2). No difference in filling pattern could be found between the different augmentation techniques (VP, KP, SP).

## Discussion

The objective of this study was to investigate whether lavage used in PMMA augmentation techniques in the treatment of VCFS has a positive effect on the cement filling pattern and can reduce the risk of cement leakage.

The developed easy and cost-effective lavage technique with two syringes showed to be feasible and reproducibly applicable in the augmentation of osteoporotic and osteopenic fractured and non-fractured vertebral bodies.

So far few experimental and animal studies focused on the effect of bone-marrow removal of the vertebral body prior to PMMA application. It could be shown that (jet)-lavage does not cause cardiovascular reaction in combination with contralateral application of vacuum and can significantly decrease the embolic load in sheep [30]. Similar results, significant reductions of cement leakage, were found by Mohamed et al. [33], using an unipedicular

aspiration technique (without lavage) in a vertebroplasty model.

In the current clinical study we did not investigate the aspirated fluid. The analysis of the relation of fat and blood in the aspirate is actually subject of an ongoing study.

We could show that with the newly developed bipedicular lavage technique a significant reduction of radiological visible cement leakage can be achieved, especially for the potentially dangerous venous leakage, for which lavage was the only independent predictor. Reasons, therefore, may be that by decreasing of the intravertebral resistance the injection of higher viscous cement is possible and the initial path of least resistance is no longer the segmental vein but the vertebral body itself.

For cortical defect leakage fracture type could be shown to be independent predictor additionally to lavage. While other studies found a higher complication and leakage rate in the augmentation of burst fractures [34], in our study population A1.2 fractures (wedge-impaction) showed a higher leakage rate compared to other fracture forms. The cause for this may be iatrogenically higher PMMA insertion pressures in an attempt to achieve endplate-to-endplate filling in this fracture type, in which one endplate is still intact.

It is known that by the use of higher viscous cement a more uniform cement filling with an increased leakage rate is achievable [25]. Moreover, it has been shown that removing bone marrow fat by lavage allows injecting more cement leading to a more homogenous distribution [28]. It might be possible that reduced injection pressures after lavage increase both effects, better filling pattern and less leakage. Our findings support those results, showing that the filling pattern in the lavage group is better in terms of a significant higher rate of endplate-to-endplate fillings in the lavage group, which is favorable [22]. Unfortunately, we did not record the amount of injected cement in detail, but

it can be assumed that the better filling pattern of the lavage group is due to higher cement volumes at lower leakage rates. In addition to the missing recording of cement volumes also no measurement of injection pressures have been made and should be seen as limitations of the study.

The risk of extraosseous cement leakage in various series ranges between 3 and 74 % [5–7, 35] Even so it is hard to compare leakage rates between studies, mainly due to different patient inclusion criteria, methodology (leakage determined by CT, radiographs or intraoperative) as well as cement parameters (type, percentage of filling), in a review of 69 clinical studies Hulme et al. [5] reported an average leakage rate of 41 % for vertebroplasty and of 9 % for kyphoplasty. Compared to this data our lavage group showed a low leakage rate (12.9 %), especially for the potentially life threatening venous leakage.

Interestingly we could not find any difference in leakage rate and cement distribution between vertebroplasty, kyphoplasty and stentoplasty. Higher leakage rates have been reported for single-group cohort vertebroplasty studies compared to kyphoplasty studies [5]. Nevertheless, for kyphoplasty it has been shown [36] that attempting to fill the whole vertebra, rather than just the cavity, results in higher leakage rates similar to rates observed in vertebroplasty (33 %). Our attempt to reach an “endplate-to-endplate” filling pattern in all three different augmentation techniques may contribute to our findings.

We could not find any complications directly associated with the new lavage technique. Theoretically there might be a minimal risk of increased blood loss due to the procedure. As we lavaged four times with a 20-ml syringe the maximum additional blood loss could be 80 ml. Anyway in our patients we did not have problems with postoperative anemia. So far we have not done a qualitative analysis of the aspirate. Previous not-published animal studies suggest the percentage of fat/blood varies largely between 5 and 15 % for the first passage. Actually a prospective study is ongoing investigating this topic specifically.

There are some limitations of the study to be mentioned. Fracture age, which may affect the augmentation process, was not available in all patients and, therefore, could not be integrated into the multiregression analysis. Nevertheless, from our experience it does not affect the lavage process per se. The comparison of two vs. two independent surgeons may be one other limitation potentially causing bias. Anyway, as all surgeons in the department have the same philosophy, used identical cement and cannulas and underwent the same surgical training, we believe it to be valid to compare all the four.

However, in combination with other techniques, which help to prevent cement leakage, like sequential application [4] and use of ultra-high viscous cement, the lavage technique is promising to reduce potentially life threatening cardiopulmonary events.

## Conclusions

Removing intravertebral bone marrow by lavage is inexpensive, safe, feasible and has the potential to reduce fat embolism and PMMA leakage in vertebroplasty or balloon kyphoplasty. Therefore, it may be useful for preventing potentially life threatening complications in patients with impaired cardiopulmonary function. Moreover, a better filling pattern can be achieved.

## Compliance with ethical standards

**Conflict of interest** The authors have no potential conflict of interest.

## References

- Borgstrom F, Zethraeus N, Johnell O et al (2006) Costs and quality of life associated with osteoporosis-related fractures in Sweden. *Osteoporos Int* 17(5):637–650
- Rho YJ, Choe WJ, Chun YI (2012) Risk factors predicting the new symptomatic vertebral compression fractures after percutaneous vertebroplasty or kyphoplasty. *Eur Spine J* 21(5):905–911
- Papanastassiou ID, Phillips FM, Van Meirhaeghe J et al (2012) Comparing effects of kyphoplasty, vertebroplasty, and non-surgical management in a systematic review of randomized and non-randomized controlled studies. *Eur Spine J* 21(9):1826–1843
- Benneker LM, Hoppe S (2013) Percutaneous cement augmentation techniques for osteoporotic spinal fractures. *Eur J Trauma Emerg Surg* 39(5):445–453
- Hulme PA, Krebs J, Ferguson SJ, Berlemann U (2006) Vertebroplasty and kyphoplasty: a systematic review of 69 clinical studies. *Spine* 31(17):1983–2001
- Jensen ME, Evans AJ, Mathis JM, Kallmes DF, Cloft HJ, Dion JE (1997) Percutaneous polymethylmethacrylate vertebroplasty in the treatment of osteoporotic vertebral body compression fractures: technical aspects. *AJNR Am J Neuroradiol* 18(10):1897–1904
- Ryu KS, Park CK, Kim MC, Kang JK (2002) Dose-dependent epidural leakage of polymethylmethacrylate after percutaneous vertebroplasty in patients with osteoporotic vertebral compression fractures. *J Neurosurg* 96(1 Suppl):56–61
- Klazen CA, Lohle PN, de Vries J et al (2010) Vertebroplasty versus conservative treatment in acute osteoporotic vertebral compression fractures (Vertos II): an open-label randomised trial. *Lancet* 376(9746):1085–1092
- Diel P, Reuss W, Aghayev E, Moulin P, Roder C, Group SWR (2010) SWISSspine-a nationwide health technology assessment registry for balloon kyphoplasty: methodology and first results. *The spine journal : official journal of the North American Spine Society*. 10(11):961–971
- Hubschle L, Borgstrom F, Olafsson G et al (2014) Real-life results of balloon kyphoplasty for vertebral compression fractures from the SWISSspine registry. *Spine J* 14(9):2063–2077
- Choe DH, Marom EM, Ahrar K, Truong MT, Madewell JE (2004) Pulmonary embolism of polymethyl methacrylate during percutaneous vertebroplasty and kyphoplasty. *AJR Am J Roentgenol* 183(4):1097–1102
- Kim SY, Seo JB, Do KH, Lee JS, Song KS, Lim TH (2005) Cardiac perforation caused by acrylic cement: a rare complication of percutaneous vertebroplasty. *AJR Am J Roentgenol* 185(5):1245–1247

13. Seo JS, Kim YJ, Choi BW, Kim TH, Choe KO (2005) MDCT of pulmonary embolism after percutaneous vertebroplasty. *AJR Am J Roentgenol* 184(4):1364–1365
14. Duran C, Sirvanci M, Aydogan M, Ozturk E, Ozturk C, Akman C (2007) Pulmonary cement embolism: a complication of percutaneous vertebroplasty. *Acta Radiol* 48(8):854–859
15. Ereth MH, Weber JG, Abel MD et al (1992) Cemented versus noncemented total hip arthroplasty—embolism, hemodynamics, and intrapulmonary shunting. *Mayo Clin Proc* 67(11):1066–1074
16. Monto RR, Garcia J, Callaghan JJ (1990) Fatal fat embolism following total condylar knee arthroplasty. *J Arthroplast* 5(4):291–299
17. Kosova E, Bergmark B, Piazza G (2015) Fat embolism syndrome. *Circulation* 131(3):317–320
18. Pape HC (1999) Pulmonary and systemic fat embolization after medullary canal pressurization: a hemodynamic and histologic investigation in the dog. *J Trauma* 47(1):190
19. Peebles DJ, Ellis RH, Stride SD, Simpson BR (1972) Cardiovascular effects of methylmethacrylate cement. *Br Med J* 1(5796):349–351
20. Aebli N, Krebs J, Davis G, Walton M, Williams MJ, Theis JC (2002) Fat embolism and acute hypotension during vertebroplasty: an experimental study in sheep. *Spine* 27(5):460–466
21. Heini PF, Orlor R (2004) Vertebroplasty in severe osteoporosis. Technique and experience with multi-segment injection. *Der Orthopade* 33(1):22–30
22. Roder C, Boszczyk B, Perler G, Aghayev E, Kulling F, Maestretti G (2013) Cement volume is the most important modifiable predictor for pain relief in BKP: results from SWISSspine, a nationwide registry. *Eur Spine J* 22(10):2241–2248
23. Tome-Bermejo F, Pinera AR, Duran-Alvarez C, Lopez-San Roman B, Mahillo I, Alvarez L (2014) Identification of risk factors for the occurrence of cement leakage during percutaneous vertebroplasty for painful osteoporotic or malignant vertebral fracture. *Spine* 39:E693–E700
24. Hoppe S, Wangler S, Aghayev E, Gantenbein B, Boger A, Benneker LM (2015) Reduction of cement leakage by sequential PMMA application in a vertebroplasty model. *Eur Spine J*. doi:10.1007/s00586-015-3920-3
25. Baroud G, Crookshank M, Bohner M (2006) High-viscosity cement significantly enhances uniformity of cement filling in vertebroplasty: an experimental model and study on cement leakage. *Spine*. 31(22):2562–2568
26. Bohner M, Gasser B, Baroud G, Heini P (2003) Theoretical and experimental model to describe the injection of a polymethylmethacrylate cement into a porous structure. *Biomaterials* 24(16):2721–2730
27. Baroud G, Bohner M, Heini P, Steffen T (2004) Injection biomechanics of bone cements used in vertebroplasty. *Bio-Med Mater Eng* 14(4):487–504
28. Benneker LM, Heini PF, Suhm N, Gisepp A (2008) The effect of pulsed jet lavage in vertebroplasty on injection forces of polymethylmethacrylate bone cement, material distribution, and potential fat embolism: a cadaver study. *Spine*. 33(23):E906–E910
29. Boger A, Benneker LM, Krebs J, Boner V, Heini PF, Gisepp A (2009) The effect of pulsed jet lavage in vertebroplasty on injection forces of PMMA bone cement: an animal study. *Eur Spine J* 18(12):1957–1962
30. Benneker LM, Krebs J, Boner V et al (2010) Cardiovascular changes after PMMA vertebroplasty in sheep: the effect of bone marrow removal using pulsed jet-lavage. *Eur Spine J* 19(11):1913–1920
31. Benneker LM, Gisepp A, Krebs J, Boger A, Heini PF, Boner V (2012) Development of an in vivo experimental model for percutaneous vertebroplasty in sheep. *Vet Comp Orthopaed Traumatol VCOT* 25(3):173–177
32. Magerl F, Aebi M, Gertzbein SD, Harms J, Nazarian S (1994) A comprehensive classification of thoracic and lumbar injuries. *Eur Spine J* 3(4):184–201
33. Mohamed R, Silbermann C, Ahmari A, Bohner M, Becker S, Baroud G (2010) Cement filling control and bone marrow removal in vertebral body augmentation by unipedicular aspiration technique: an experimental study using leakage model. *Spine*. 35(3):353–360
34. Zaryanov AV, Park DK, Khalil JG, Baker KC, Fischgrund JS (2014) Cement augmentation in vertebral burst fractures. *Neurosurg Focus* 37(1):E5
35. Cortet B, Cotten A, Boutry N et al (1999) Percutaneous vertebroplasty in the treatment of osteoporotic vertebral compression fractures: an open prospective study. *J Rheumatol* 26(10):2222–2228
36. Berlemann U, Franz T, Orlor R, Heini PF (2004) Kyphoplasty for treatment of osteoporotic vertebral fractures: a prospective non-randomized study. *Eur Spine J* 13(6):496–501