

Vertebral body fracture following stand-alone lateral lumbar interbody fusion (LLIF): report of two events out of 712 levels

Zachary J. Tempel · Gurpreet S. Gandhoke ·
Bryan D. Bolinger · David O. Okonkwo ·
Adam S. Kanter

Received: 7 January 2015 / Accepted: 26 February 2015 / Published online: 17 March 2015
© Springer-Verlag Berlin Heidelberg 2015

Abstract

Purpose Available studies demonstrate vertebral body fractures as a relatively rare complication following lateral lumbar interbody fusion (LLIF), with most fractures reported in association with lateral plating and vertebral screws. This study reports the occurrence of two vertebral body fractures following stand-alone LLIF in 712 levels fused in 335 patients.

Methods A retrospective review of prospectively collected data was performed on all patients who underwent minimally invasive LLIF over a seven-year period at a single institution. Patients with vertebral body fractures were recorded.

Results Two patients (0.6 %) out of 335 total patients (712 levels) were identified with vertebral body fractures following stand-alone LLIF. Both patients presented with severe back pain and return of symptoms within 2 weeks of the index surgery. Both patients were obese, had impaired bone mineral density and were managed with open posterior segmental fixation.

Conclusions The 0.6 % incidence of vertebral body fractures in our series of fusing 712 levels is in accordance with the incidence rates reported in the literature. Potential risk factors for vertebral body fractures at the index LLIF level included obesity, osteopenia, unrecognized

intraoperative endplate breach, graft subsidence and oversized graft placement.

Keywords Lateral interbody fusion · Graft subsidence · T score · Osteopenia/osteoporosis · Vertebral body fracture

Introduction

The complication profile associated with lateral lumbar interbody fusion (LLIF) has now been comprehensively characterized in the literature [26]. Although the rate of major complications associated with LLIF is relatively low, they can occur resulting in significant morbidity and mortality. There are several known minor complications associated with LLIF that are relatively unique to the procedure. For example, hip flexor weakness and anterior thigh paresthesias or dysesthesias caused by injury to the psoas muscle and genitofemoral nerve, respectively, are unique to the LLIF approach and occur in 15–40 % of patients [1, 5, 10, 17, 19, 21, 23]. Another recognized complication of the LLIF procedure is subsidence of the interbody graft into one or both vertebral bodies, resulting in severe pain, impaired arthrodesis and potentially fracture of the body itself.

Fracture of the vertebral body is an uncommon complication of LLIF. However, these fractures are generally unstable and necessitate a second operation, such as a posterior approach with instrumented fusion for stabilization and symptom relief. LLIF is a good option for older patients or patients with multiple medical morbidities compared to traditional open fusion operations due to the low complication profile and shorter anesthesia time. Therefore, additional surgery subjects these patients to additional risks associated with general anesthesia, blood

Z. J. Tempel and G. S. Gandhoke contributed equally to this manuscript.

Z. J. Tempel (✉) · G. S. Gandhoke · B. D. Bolinger ·
D. O. Okonkwo · A. S. Kanter
Department of Neurological Surgery, University of Pittsburgh
Medical Center, 200 Lothrop Street, Suite B400, Pittsburgh,
PA 15213, USA
e-mail: tempeljz@upmc.edu

loss and a prolonged postoperative recovery. The incidence of vertebral body fractures is difficult to estimate due to a limited number of reported cases. Recent reports address vertebral body fractures following LLIF in patients who also received supplemental lateral plating or pedicle screw fixation [6, 11, 13]. However, vertebral body fractures following stand-alone LLIF have yet to be discussed in the literature. In this report, we present the incidence of vertebral body fractures following stand-alone LLIF in a large series of patients at a single institution over a 7-year period.

Methods

A retrospective review of prospectively collected data was performed on all patients who underwent minimally invasive LLIF at this institution between July of 2008 and June of 2014. This consisted of 712 levels in 335 patients. The patients with vertebral body fractures following stand-alone LLIF were recorded. The patient charts were examined for pertinent demographic and clinical information, including preoperative symptomatology, operative details, body mass index (BMI), *T* score on dual-energy X-ray absorptiometry (DEXA) scans and past medical history. The patients' imaging studies were also reviewed to characterize the indication for surgery and the pattern of vertebral body fracture following LLIF. Indications for surgery included degenerative disc disease with or without foraminal stenosis, adjacent level disease following prior fusion, grade 1 and 2 spondylolisthesis, traumatic fracture, far-lateral disc herniation and scoliosis. The broad categories of degeneration and deformity included 60 and 40 % of the patients, respectively.

Illustrative cases

Patient 1

A 63-year-old female with a past medical history significant for obesity (BMI = 41) and osteopenia (*T* score = -2.1) as well as a 22 pack-year tobacco history presented with severe and progressive mechanical back pain and bilateral lower extremity radicular pain of 12 months duration. She was neurologically intact on physical examination without motor or sensory deficit. Magnetic resonance imaging (MRI) demonstrated a grade I spondylolisthesis of L3 on L4 with facet arthropathy and diffuse disc bulge causing significant bilateral neuroforaminal stenosis (Fig. 1a). No instability was demonstrated on dynamic radiography. Her symptoms remained refractory to 6 months of non-operative management. She subsequently underwent an uncomplicated minimally

invasive transposas LLIF at L3–4. No endplate violation occurred during the surgery (Fig. 1b). A 12 mm × 22 mm × 55 mm, parallel, PEEK interbody graft filled with morselized allograft was inserted into the L3/4 disc space. No supplemental instrumentation was utilized. Postoperative computerized tomography (CT) revealed a well-placed large interbody graft with significant distraction of the disc space and no endplate violation (Fig. 1c). The patient was discharged home on postoperative day one with resolution of her preoperative radicular complaints.

Approximately 2 weeks following surgery, unrelated to trauma, she began to experience back and leg pain again; she remained neurologically intact. CT imaging revealed an L4 burst fracture with interbody graft subsidence (Fig. 1d). She was subsequently taken back to the operating room for posterior decompression and pedicle screw and rod instrumentation (Fig. 1e). The greater degree of subsidence into the L3 vertebral combined with limited screw purchase in the severely comminuted L4 vertebral body warranted a more extensive construct with extension of posterior segmental fusion from L2 to L5.

Patient 2

A 61-year-old female with a past medical history of obesity (BMI of 46), osteopenia (*T* score = -2.4), and human immunodeficiency virus (HIV) presented with several months of severe progressive back and bilateral lower extremity pain. MRI demonstrated a grade 1 spondylolisthesis of L4 on L5 accompanied by a diffuse disc bulge causing severe bilateral neuroforaminal stenosis (Fig. 2a). No instability was noted on dynamic radiography. After failing non-operative management, she underwent an uncomplicated minimally invasive transposas LLIF at L4–5 using a parallel 10 mm × 22 mm × 55 mm PEEK interbody graft filled with morselized allograft without supplemental instrumentation (Fig. 2b). Postoperative CT imaging revealed a well-placed interbody graft at L4–5 with disc space and neuroforaminal expansion without endplate violation (Fig. 2c). She was discharged home on postoperative day two with significant improvement in her preoperative symptoms.

Approximately 10 days following surgery, she began to experience severe low back pain radiating into the buttocks distinctly different than her preoperative symptoms. A short course of oral steroids failed to provide her relief of her symptoms. A CT scan of her lumbar spine demonstrated interbody graft subsidence with a burst fracture of the L5 vertebral body (Fig. 2d). She subsequently underwent a posterior decompression and instrumented fusion from L4 to S1 using a pedicle screw and rod construct (Fig. 2e). The lesser degree of subsidence and the ability to

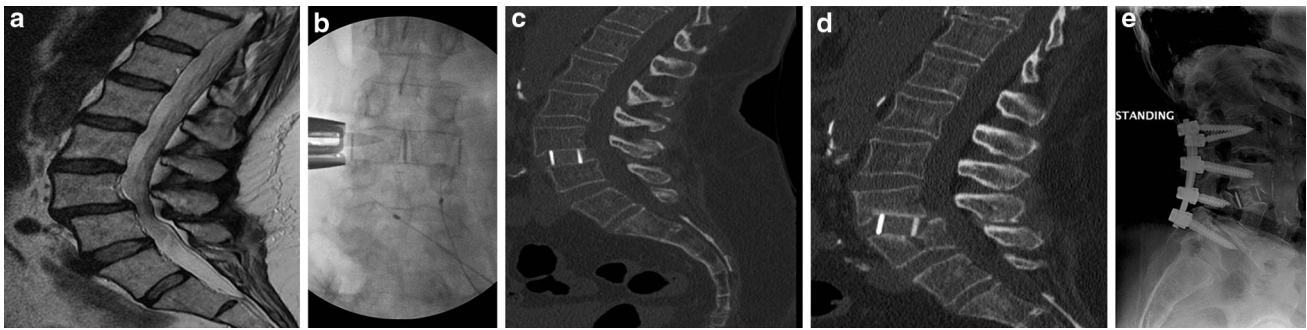


Fig. 1 Preoperative MRI (a) reveals grade I spondylolisthesis with moderate canal stenosis. Intraoperative fluoroscopy (b) demonstrates graft placement with significant disc space distraction and no endplate violation. Postoperative CT imaging (c) reveals good positioning of stand-alone interbody graft within the L3/4 disc space without evidence of endplate violation or graft subsidence; however, the disc

space is much larger than adjacent levels. Delayed CT imaging (d) reveals fracture of the L4 vertebrae with associated graft subsidence into the L3 and L4 bodies. Postoperative radiograph (e) following posterior decompression and pedicle screw and rod placement

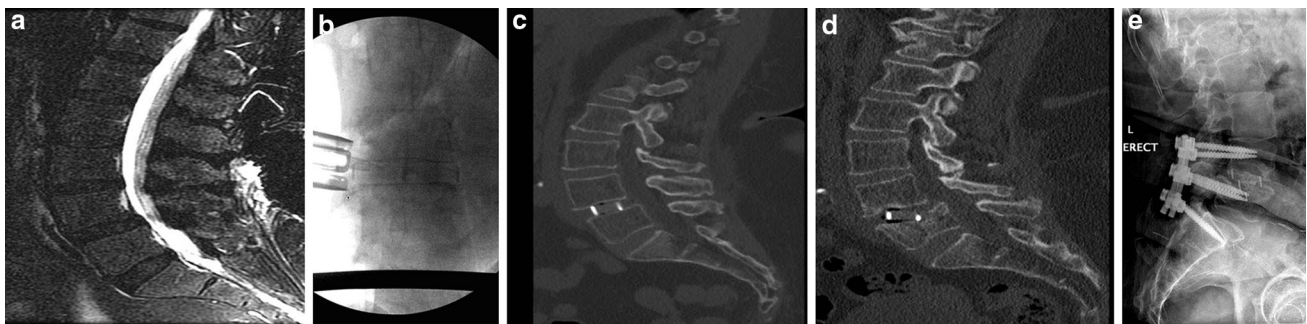


Fig. 2 Preoperative MRI (a) reveals grade I spondylolisthesis with moderate stenosis. Intraoperative fluoroscopy (b) demonstrates appropriate graft placement without obvious endplate violation. Postoperative CT imaging (c) reveals good positioning of stand-alone interbody graft within the L4/5 disc space without evidence of

endplate violation or graft subsidence. Delayed CT imaging (d) reveals fracture of the L5 vertebrae with associated graft subsidence. Postoperative radiograph (e) following posterior decompression and pedicle screw and rod placement from L4 to S1

place longer screws in the fractured vertebra enabled us to limit the fusion to one level above and below the fracture level.

Discussion

The transposas LLIF technique enables an extensive direct discectomy for placement of a wide intervertebral graft without disruption of the anterior or posterior ligaments. An appropriately sized and positioned interbody graft will rest between the apophyseal rings of adjacent vertebrae. This provides increased biomechanical support and allows for distribution of compressive loads over a large surface area [11, 18, 22]. Stability of the motion segment is maintained with preservation of the anterior and posterior tension bands; structures that are routinely violated during anterior and posterior interbody procedures [7, 26].

In our series of 335 patients with 712 levels fused, two patients (0.6 %) experienced a vertebral body fracture at

the index level. Both of these fractures involved the inferior vertebral body of the index level that was fused. This rate of 0.6 % of patients, or 0.3 % of total LLIF levels, is in agreement with previous vertebral fracture reports following lateral interbody fusion; however, this is the first report, which describes this complication following stand-alone LLIF. Rodgers et al. [20] reported a fracture incidence rate of 0.6 % among 600 patients who underwent transposas LLIF. The same group found fracture incidence rates of 1.3 and 0.6 % after comparing 156 obese patients to 157 non-obese patients who underwent LLIF, respectively [19]. Kepler et al. [11] and Dua et al. [6] found a fracture incidence rate of 15.4 % among 13 patients who underwent single-level LLIF with supplemental lateral plating and pedicle screw constructs.

Mechanisms for vertebral body fractures in patients undergoing LLIF are likely multifactorial and related to technique, implant material, graft size, and patient bone quality [2, 9, 25]. Endplate violation during the discectomy, graft insertion, or supplemental hardware placement

may weaken the epiphyseal ring, allowing for cage subsidence and vertebral fracture [6]. Brier-Jones et al. [3] speculate that violation of the epiphyseal ring or subchondral bone by plate-anchoring screws can contribute to the development of coronal vertebral body fractures [3]. Likewise, Kepler et al. [11] and Dua et al. [6] suggest that vertebral fractures occur when compressive forces are unevenly distributed by a subsided cage into the bone surrounding plate-anchoring screws. Other reports suggest the possibility that the interbody graft pivots as the spine transitions between flexion and extension [3]. This magnitude of gross antero-posterior instability has not been proven in biomechanical studies and is unlikely to occur due to the inherent stability of the interbody device as well as the strength of the intact anterior and posterior tension bands [4]. Although bone morphogenic protein (BMP) was not used in any of the patients in our series, it has been reported to cause osteolysis, which can lead to a weakened bone-graft interface and subsequent graft subsidence [8, 14].

The usage of stand-alone lateral cages in patients with low-grade spondylolisthesis has been previously described, and we have also experienced success with this type of approach [15, 16]. Both patients discussed in this report were significantly overweight with additional medical comorbidities and poor bone density, which likely contributed to the development of vertebral body fractures following LLIF. However, there are additional mechanical factors to consider. Further evaluation of the first patient's postoperative CT scan (Fig. 1c) demonstrates that, although the graft appears properly placed without endplate violation, the L3–4 disc space is much wider than the disc spaces at the adjacent levels. Thus, the operative level is likely over distracted due to placement of a graft that is much too large for the disc space. Over distraction of any interspace may induce subsidence or possible fracture because of the increased pressure resulting from stretching of the annulus fibrosus (even after the release of the contralateral annulus). As previously described, the pressure exerted by the cage on the vertebral body directly depends on the surface area of contact between the cage and the endplate. A recent study showed that there exists an inverse correlation between the AP size, but not the length of the cage and the rate of subsidence [12]. Despite the larger AP footprint of the cages used in both of our patients (22 mm), only a perfect placement of the cage in relation to the endplates of the vertebrae will result in the maximum strength to the construct, and any degree of obliquity allows for contact of the cage with the non-apophyseal ring portion of the endplate and predisposition to subsidence and fractures. The increased pressure transmitted through this thin surface explains the anatomy of the coronal fractures in direct extension with the leading edge of the implant that acted as

a bone cutter. It is possible that there was some obliquity in placement of the cage in our patients which may have contributed to the development of the fractures.

A BMI of 41 creates significant axial loading of the interbody graft. As a result, the graft exerts excessive distracting forces on the superior and inferior endplates, which are already compromised by osteopenia, causing a fracture of the inferior L4 vertebral body. Review of the second patient's postoperative imaging demonstrates an appropriately sized interbody graft, with the L4–5 disc spaces of comparable size to the adjacent levels. However, this patient is more obese with more severe osteopenia compared to the first patient. Further, compared to the L3–4 disc space, the axial loading forces on the L4–5 disc space are greater in magnitude. We believe that a combination of factors including over distraction, oblique cage placement and osteopenia contributed to fracture formation. This report adds to the now accumulating evidence of incidence of fractures of vertebral bodies after lateral lumbar interbody fusion, providing food for thought to anticipate, modify technique, and to be prepared to manage this complication [3, 6, 13, 19, 20, 24].

Conclusions

This report highlights two patients with delayed postoperative vertebral body fractures following stand-alone LLIF performed by an experienced surgeon at a single institution. We report a 0.6 % incidence of vertebral body fractures of the index level following LLIF. Factors that may have contributed to these fractures include obesity, osteopenia, unrecognized intraoperative endplate breach and graft subsidence due to oversized graft placement. Continued scrutiny of this powerful procedure with strict complication reporting and evaluation will enable its sustained utilization in a safe and effective manner.

Conflict of interest Dr. Kanter receives royalties from Lanx.

References

1. Anand N, Rosemann R, Khalsa B, Baron EM (2010) Mid-term to long-term clinical and functional outcomes of minimally invasive correction and fusion for adults with scoliosis. *Neurosurg Focus* 28:E6
2. Belkoff SM, Maroney M, Fenton DC, Mathis JM (1999) An in vitro biomechanical evaluation of bone cements used in percutaneous vertebroplasty. *Bone* 25:23S–26S
3. Brier-Jones JE, Palmer DK, Inceoglu S, Cheng WK (2011) Vertebral body fractures after transposas interbody fusion procedures. *Spine J* 11:1068–1072
4. Cappuccino A, Cornwall GB, Turner AW, Fogel GR, Duong HT, Kim KD et al (2010) Biomechanical analysis and review of

- lateral lumbar fusion constructs. *Spine (Phila Pa 1976)* 35:S361–S367
5. Caputo AM, Michael KW, Chapman TM Jr, Massey GM, Howes CR, Isaacs RE et al (2012) Clinical outcomes of extreme lateral interbody fusion in the treatment of adult degenerative scoliosis. *Sci World J* 2012:680643
 6. Dua K, Kepler CK, Huang RC, Marchenko A (2010) Vertebral body fracture after anterolateral instrumentation and interbody fusion in two osteoporotic patients. *Spine J* 10:e11–e15
 7. Helgeson M DA, Stephens FL (2008) Biomechanical importance of the anterior longitudinal ligament in a corpectomy model. *Spine J* 8(suppl):S 141–S 142
 8. Helgeson MD, Lehman RA Jr, Patzkowski JC, Dmitriev AE, Rosner MK, Mack AW (2011) Adjacent vertebral body osteolysis with bone morphogenetic protein use in transforaminal lumbar interbody fusion. *Spine J* 11:507–510
 9. Hou Y, Luo Z (2009) A study on the structural properties of the lumbar endplate: histological structure, the effect of bone density, and spinal level. *Spine (Phila Pa 1976)* 34:E427–E433
 10. Isaacs RE, Hyde J, Goodrich JA, Rodgers WB, Phillips FM (2010) A prospective, nonrandomized, multicenter evaluation of extreme lateral interbody fusion for the treatment of adult degenerative scoliosis: perioperative outcomes and complications. *Spine (Phila Pa 1976)* 35:S322–S330
 11. Kepler CK, Sharma AK, Huang RC (2011) Lateral transposas interbody fusion (LTIF) with plate fixation and unilateral pedicle screws: a preliminary report. *J Spinal Disord Tech* 24:363–367
 12. Le TV, Baaj AA, Dakwar E, Burkett CJ, Murray G, Smith DA et al (2012) Subsidence of polyetheretherketone intervertebral cages in minimally invasive lateral retroperitoneal transposas lumbar interbody fusion. *Spine (Phila Pa 1976)* 37:1268–1273
 13. Le TV, Smith DA, Greenberg MS, Dakwar E, Baaj AA, Uribe JS (2012) Complications of lateral plating in the minimally invasive lateral transposas approach. *J Neurosurg Spine* 16:302–307
 14. Lehman RA Jr (2011) Vertebral body osteolysis after minimal-access transforaminal interbody fusion. *Spine J* 11:581–582
 15. Marchi L, Abdala N, Oliveira L, Amaral R, Coutinho E, Pimenta L (2012) Stand-alone lateral interbody fusion for the treatment of low-grade degenerative spondylolisthesis. *Sci World J* 2012: 456346
 16. Marchi L, Oliveira L, Amaral R, Castro C, Coutinho T, Coutinho E et al (2012) Lateral interbody fusion for treatment of discogenic low back pain: minimally invasive surgical techniques. *Adv Orthop* 2012:282068
 17. Moller DJ, Slimack NP, Acosta FL Jr, Koski TR, Fessler RG, Liu JC (2011) Minimally invasive lateral lumbar interbody fusion and transposas approach-related morbidity. *Neurosurg Focus* 31:E4
 18. Rockoff SD, Sweet E, Bleustein J (1969) The relative contribution of trabecular and cortical bone to the strength of human lumbar vertebrae. *Calcif Tissue Res* 3:163–175
 19. Rodgers WB, Cox CS, Gerber EJ (2010) Early complications of extreme lateral interbody fusion in the obese. *J Spinal Disord Tech* 23:393–397
 20. Rodgers WB, Gerber EJ, Patterson J (2011) Intraoperative and early postoperative complications in extreme lateral interbody fusion: an analysis of 600 cases. *Spine (Phila Pa 1976)* 36:26–32
 21. Sharma AK, Kepler CK, Girardi FP, Cammisa FP, Huang RC, Sama AA (2011) Lateral lumbar interbody fusion: clinical and radiographic outcomes at 1 year: a preliminary report. *J Spinal Disord Tech* 24:242–250
 22. Steffen T, Tsantrizos A, Aebi M (2000) Effect of implant design and endplate preparation on the compressive strength of interbody fusion constructs. *Spine (Phila Pa 1976)* 25:1077–1084
 23. Tempel ZJ, Gandhoke GS, Bonfield CM, Okonkwo DO, Kanter AS (2014) Radiographic and clinical outcomes following combined lateral lumbar interbody fusion and posterior segmental stabilization in patients with adult degenerative scoliosis. *Neurosurg Focus* 36:E11
 24. Tender GC (2014) Caudal vertebral body fractures following lateral interbody fusion in nonosteoporotic patients. *Ochsner J* 14:123–130
 25. Vaidya R, Sethi A, Bartol S, Jacobson M, Coe C, Craig JG (2008) Complications in the use of rhBMP-2 in PEEK cages for interbody spinal fusions. *J Spinal Disord Tech* 21:557–562
 26. Youssef JA, McAfee PC, Patty CA, Raley E, DeBauche S, Shucosky E et al (2010) Minimally invasive surgery: lateral approach interbody fusion: results and review. *Spine (Phila Pa 1976)* 35:S302–S311