

Odontoid process and clival regeneration with Chiari malformation worsening after transoral decompression: an unexpected and previously unreported cause of “accordion phenomenon”

Massimiliano Visocchi · Gianluca Trevisi ·
Domenico Gerardo Iacopino · Gianpiero Tamburrini ·
Massimo Caldarelli · Giuseppe M. V. Barbagallo

Received: 9 July 2014/Revised: 4 December 2014/Accepted: 5 December 2014/Published online: 18 December 2014
© Springer-Verlag Berlin Heidelberg 2014

Abstract

Purpose Transoral odontoidectomy followed by occipito-cervical fixation is a widely used approach to relieve ventral compressions at the craniovertebral junction (CVJ). Despite the large amount of literature on this approach and its complications, no previous reports of odontoid process and clival regeneration following transoral odontoidectomy are present in the English literature.

Methods We report the case of odontoid process and clival regeneration following transoral odontoidectomy.

Results A 7-year-old boy presented with symptoms of brainstem and upper cervical spinal cord compression due to a complex malformation at the CVJ including a basilar invagination with Chiari malformation. A successful transoral microsurgical endoscopic-assisted odontoidectomy extended to the clivus was performed along with occipito cervical instrumentation and fusion. Clinical and radiological resolution of the CVJ compression was evident up to 2 years post-op, when the child had a relapse of some of the presenting symptoms and the follow-up CT and MRI scans showed a quite complete regrowth of the odontoid process, clival partial regeneration and recurrence of pre-operative Chiari malformation.

Conclusions Besides the need of an accurate complete resection of the periosteum, which apparently was incompletely performed in our case, our experience suggests the need of resection of the odontoid down to the dentocentral synchondrosis and an accurate lateral removal of the bone surrounding the anterior tubercle of the Clivus is advised when an anterior CVJ decompression is required in children presenting a still evident synchondrosis at neuro-radiological investigation.

Keywords Basilar invagination · Bone regrowth · Chiari malformation · Clivus · Odontoid process · Transoral odontoidectomy

Introduction

Transoral odontoidectomy is a well described and largely used approach directed to relieve irreducible ventral brain stem compressions at the craniovertebral junction (CVJ). A CVJ instability usually follows odontoid resections and a posterior fixation is generally required, both in the same operative session or after a settling period in a halo vest [1–3]. Recent advances in fixation materials may allow an anterior internal plate fixation [4, 5]. Basilar invagination forms a prominent component of the CVJ anomalies and Chiari malformation is the most common associate due to the small volume of the posterior cranial fossa [6].

We report the case of a 7-year-old boy with a basilar invagination and Chiari malformation who underwent transoral odontoidectomy and posterior fixation with immediate, radiologically confirmed, successful decompression but late quite complete symptomatic regrowth of the odontoid process, clival partial regeneration and recurrence of pre-operative Chiari malformation. No other similar cases of

M. Visocchi (✉) · G. Trevisi · G. Tamburrini · M. Caldarelli
Institute of Neurosurgery, Policlinico Gemelli, Catholic
University School of Medicine, Largo A. Gemelli 8,
00168 Rome, Italy
e-mail: massimiliano.visocchi@rm.unicatt.it

D. G. Iacopino
Institute of Neurosurgery, Policlinico Giaccone, University of
Palermo, Palermo, Italy

G. M. V. Barbagallo
Division of Neurosurgery, Department of Neurosciences,
Policlinico “G.Rodolico” University Hospital, Catania, Italy

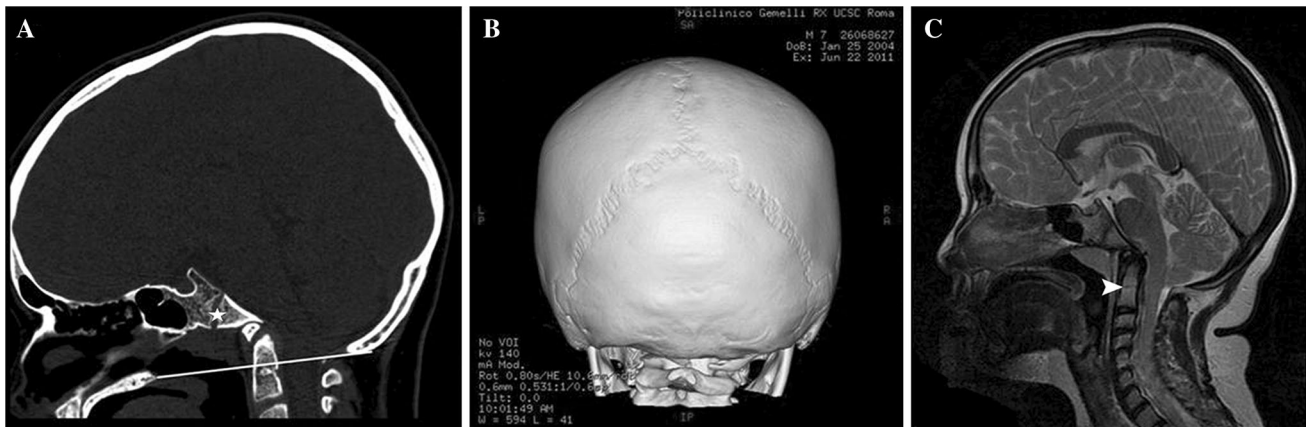


Fig. 1 Preoperative neuroimaging. **a** Sagittal CT showing platybasia and basilar invagination (McGregor's line is showed). **b** 3D CT showing partial assimilation of the anterior arch of the atlas with counterclockwise rotation on C2 and partial aplasia of the posterior

arch. **c** Sagittal T2w MR showing the anterior compression of the brain stem and of the upper cervical spinal cord and the Chiari malformation. Arrow dentocentral synchondrosis. Star sphenoid-occipital synchondrosis

transoral odontoidectomy failure were previously reported in the English literature.

Case report

A 7-year-old boy presented with headache, diplopia, dizziness, episodes of fluid dysphagia, photo- and phonophobia, nuchal rigidity, weakness at the left arm and at lower limbs, paresthesias in left arm, cold dysesthesias in both upper and lower limbs, and pain at mastication. Brain and cervical spine MRI and CT scans showed a complex malformation at the CVJ: platybasia, basilar invagination, partial assimilation of the anterior arch of the atlas with counterclockwise rotation on C2, partial aplasia of the posterior arch of the atlas (bifidus) and Chiari malformation with compression of the brain stem and of the upper cervical spinal cord (Fig. 1). Brainstem auditory-evoked potentials were normal, while SEPs showed an abnormal central conduction pattern at lower limbs. Thus, a transoral microsurgical endoscopic-assisted decompression was performed according to our previous experiences; although the feeling of the surgeon was that the entire periosteum was removed along with the odontoid “more solito”, postoperative MR showed some findings consistent with possible residual periosteum (Fig. 2b) [7, 8].

After 7 days in Halo Vest, the child underwent an occipito-cervical posterior fixation. The perioperative period was uneventful and the child had a rapid resolution of the preoperative symptoms. Early postoperative neuroimaging showed a satisfactory global decompression of the CVJ (Fig. 2). These clinical and radiological findings were stable at 3, 6 and 12 months follow-up (Fig. 3). Surprisingly at 2 years follow-up headache and sensory-motor deficits at

lower limbs relapsed; neuroradiological investigations (CT and MR) showed a quite complete regeneration of the odontoid process along with a partial regrowth of the inferior portion of the clivus and recurrence of Chiari malformation, with a symptomatic compression of the brainstem and upper cervical spinal cord (Fig. 4). The patient was, therefore, scheduled for a redo surgery consisting of a further decompression with a more homogeneous caudal resection of the odontoid down to the dentocentral synchondrosis and an accurate lateral removal of the bone surrounding the anterior tubercle of the Clivus and complete removal of the periosteum. The parents refused a new operation. The clinical status was stabilised and unchanged up to date.

Discussion

Transoral odontoidectomy is a worldwide diffused surgical procedure and large case series of both adult and paediatric population harbouring basilar invagination have been reported in the last decades. This approach provides access to midline pathologies at the lower clivus, anterior arch of C1, odontoid process of C2, down to the C3 vertebral body in some patients [9–11]. A number of technical variations including “extended approaches”, endoscopic assisted or pure endoscopic transoral and transnasal approaches have been described to extend the surgical domain of the approach up to the Clivus [8, 9, 12–17]. Classically, complications related to the transoral surgical odontoidectomy are immediate (CSF leakage, carotid or vertebral artery injuries, soft tissues oedema and cranial nerve injuries) and late (infections, wound dehiscence, CSF leak and meningitis, velopalatine incompetence, nasal speech, dysphagia and regurgitation of liquids and CVJ instability) [9, 17–20].

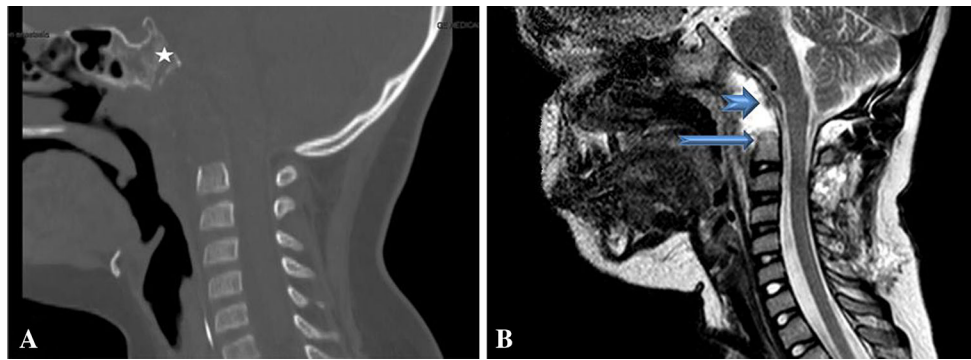


Fig. 2 Early postoperative neuroimaging. **a** Sagittal *midline* CT showing an extensive bone removal (inferior and middle third of the Clivus, anterior arch of the atlas and all the odontoid) at the anterior aspect of the CVJ with some middle third of the Clivus, the sphenoccipital synchondrosis (*star*). **b** Sagittal paramedian T2w MR

showing an optimal decompression of the neural structures and the dentocentral synchondrosis left intact (*thin arrow*). Note the imaging consistent with residual periosteum recognisable on the anterior aspect of the tectorial membrane (*thick arrow*)

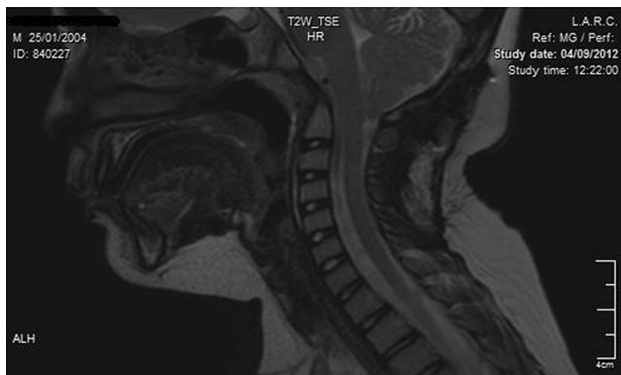


Fig. 3 1-year follow-up. Sagittal T2w MR showing a stable decompression of the anterior CVJ. Note that the resected bone edges have a more rounded aspect when compared with early postoperative imaging and Chiari malformation is lightly worsening

arch of the Atlas, the odontoid and the medial aspect of the middle and inferior third of the clivus (Fig. 2a).

So far spontaneous odontoid process regrowth after transoral odontoidectomy has never been reported in the English literature as possible complication or evenience procedure related. In our case, the bone regrowth caused a renewed compression of the brain stem/upper cervical cord, surprisingly associated with the worsening of the preoperative Chiari malformation, improved soon after the operation, with a recurrence of some of the preoperative symptoms.

Bone regeneration at the foramen magnum has been previously reported after suboccipital craniectomies with or without C1 laminectomy in Chiari malformations [22–25, 32].

Complete spontaneous bone regeneration has been occasionally described in other craniofacial bones such as in mandible after partial mandibulectomy even in elderly patients [26–30].

Several conditions have been suggested to possibly influence this rare bone regeneration: young age; infections/inflammations; the development of new bone from intact periosteum or its fragments and from regenerated juvenile periosteum under the influence of a local environment which is permissive to osteogenesis due to the presence of growth factors as the VEGF; post-surgical immobilisation or even continuous functional stresses on the regenerating area [26–29, 31]. However, the mandible, as well as the majority of the skull and facial bones such as maxilla, premaxilla, zygoma, frontal parietal, vomer, palatine, and nasal bones, develops by intramembranous ossification [32], while the bony cranial base develops by endochondral ossification [33].

At spinal level some degree of bone regeneration has been observed after lumbar laminectomies for several degenerative conditions [34, 35].

In 1998, Goel classified basilar invagination in two groups:

Group 1: the angle of the clivus and posterior cranial fossa volume are unaffected in presence of atlantoaxial dislocation.

Group 2: the assembly of the odontoid process the anterior arch of the atlas and the clivus is migrated superiorly in unison, resulting in reduction of posterior cranial fossa volume without atlantoaxial dislocation [6].

In 2009, we published our experience on the “always posterior strategy”; such a philosophy avoid transoral surgery as first step in view of a possible CVJ decompression by simple surgical manoeuvres during posterior fixation; nevertheless in the absence of CVJ dislocation it was not indicated in this case [21].

Since our patient was harbouring, Group 2 irreducible basilar invagination transoral decompression was performed and, by the simple transoral approach without extended variants, it was possible to remove the anterior

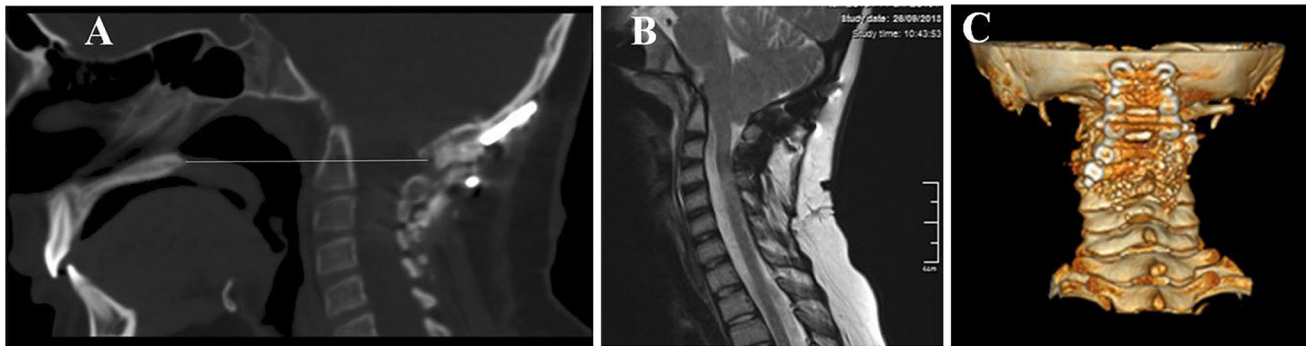


Fig. 4 2-year follow-up. **a** Sagittal CT scan showing the posterior construct with bone fusion, the spontaneous odontoid process regeneration with relapsing basilar invagination (note the McGregor's

line) and the inferior clival regeneration. **b** Sagittal T2w MRI showing the compressive effect of CVJ on the neural structures. **c** Posterior 3D reconstruction showing a good craniocervical bone bridging

The Axis embryologically develops from four bones separated by synchondrotical articulations consisting of four ossification centres: two in the neural arches bilaterally (neurocentral synchondrosis), one in the vertebral body (dentocentral synchondrosis) and one in the odontoid process (apicodental synchondrosis) [36]. These ossification centres fuse between 3 and 7 years of age, but rarely they can remain open into adolescence [36–38]. In our case, the odontoid resection did not include the dentocentral synchondrosis, which is generally well below the superior articulating facets that constitutes the anatomical base of the odontoid process growth (Fig. 2). The ossification potential of this growing centre in a 7-year-old boy could explain the unusual odontoid regrowth associated with the Chiari worsening as the consequence of posterior cranial fossa impingement. Similarly, the development of the clivus, whose anterior tubercle develops from the hypocentrum of the fourth occipital sclerotome (proatlas), is determined by sutural growth at the level of the spheno-occipital synchondrosis and, laterally, at the level of the petro-occipital and spheno-petrosal junctions [39]. The spheno-occipital synchondrosis closes between 11 and 17 years of age, this process generally happens in girls before than in boys [40, 41]. Again, in the case here presented the spheno-occipital synchondrosis was not included in the bony resection and a quote of clival regrowth could be noticed at 2 years radiological follow-up (Fig. 4).

Moreover the inferior Clivus resection, clearly evident in the early midline CT reconstructions, was not enough laterally extended to the anterior tubercle of the Clivus, suggesting a possible lateral to medial reossification. We defined the phenomenon described as an “accordion” phenomenon. Beside the need of an accurate complete resection of the periosteum, our experience suggests to aim at a more homogeneous caudal resection of the odontoid down to the dentocentral synchondrosis and an accurate lateral removal of the bone surrounding the anterior tubercle of the Clivus when an anterior CVJ decompression

is required in children presenting a still evident synchondrosis at neuroradiological investigation.

Acknowledgments No funding was obtained for the present paper.

Conflict of interest None of the authors has any potential conflict of interest.

References

- Dickman CA, Locantro J, Fessler RG (1992) The influence of transoral odontoid resection on stability of the craniovertebral junction. *J Neurosurg* 77:525–530. doi:10.3171/jns.1992.77.4.0525
- Crockard HA, Calder I, Ransford AO (1990) One-stage transoral decompression and posterior fixation in rheumatoid atlanto-axial subluxation. *J Bone Joint Surg Br* 72:682–685
- Dickman CA, Crawford NR, Brantley AG, Sonntag VK (1995) Biomechanical effects of transoral odontoidectomy. *Neurosurgery* 36:1146–1152 (discussion 1152–1143)
- Ai F, Yin Q, Wang Z, Xia H, Chang Y, Wu Z, Liu J (2006) Applied anatomy of transoral atlantoaxial reduction plate internal fixation. *Spine (Phila Pa 1976)* 31:128–132 (00007632-200601150-00003)
- Wang X, Fan CY, Liu ZH (2010) The single transoral approach for Os odontoidemum with irreducible atlantoaxial dislocation. *Eur Spine J* 19(Suppl 2):S91–S95. doi:10.1007/s00586-009-1088-4
- Goel A, Bhatjiwale M, Desai K (1998) Basilar invagination: a study based on 190 surgically treated patients. *J Neurosurg* 88:962–968. doi:10.3171/jns.1998.88.6.0962
- Visocchi M, Della Pepa GM, Doglietto F, Esposito G, La Rocca G, Massimi L (2011) Video-assisted microsurgical transoral approach to the craniovertebral junction: personal experience in childhood. *Childs Nerv Syst* 27:825–831. doi:10.1007/s00381-010-1386-5
- Visocchi M, Doglietto F, Della Pepa GM, Esposito G, La Rocca G, Di Rocco C, Maira G, Fernandez E (2011) Endoscope-assisted microsurgical transoral approach to the anterior craniovertebral junction compressive pathologies. *Eur Spine J* 20:1518–1525. doi:10.1007/s00586-011-1769-7
- Hsu W, Wolinsky JP, Gokaslan ZL, Sciubba DM (2010) Transoral approaches to the cervical spine. *Neurosurgery* 66:119–125. doi:10.1227/01.NEU.0000365748.00721.0B
- Fang HSOG (1962) Direct anterior approach to the upper cervical spine. *J Bone Joint Surg Am* 44:1588–1604

11. Greenberg AD, Scoville WB, Davey LM (1968) Transoral decompression of atlanto-axial dislocation due to odontoid hypoplasia. Report of two cases. *J Neurosurg* 28:266–269. doi:[10.3171/jns.1968.28.3.0266](https://doi.org/10.3171/jns.1968.28.3.0266)
12. Kassam AB, Snyderman C, Gardner P, Carrau R, Spiro R (2005) The expanded endonasal approach: a fully endoscopic transnasal approach and resection of the odontoid process: technical case report. *Neurosurgery* 57:E213 discussion E213
13. Qiuhan Z, Feng K, Bo Y, Hongchuan G, Mingchu L, Ge C, Feng L (2013) Transoral endoscopic odontoidectomy to decompress the cervicomedullary junction. *Spine(Phila Pa 1976)* 38:E901–E906. doi:[10.1097/BRS.0b013e3182941735](https://doi.org/10.1097/BRS.0b013e3182941735)
14. Youssef AS, Sloan AE (2010) Extended transoral approaches: surgical technique and analysis. *Neurosurgery* 66:126–134. doi:[10.1227/01.NEU.0000366117.04095.EC](https://doi.org/10.1227/01.NEU.0000366117.04095.EC)
15. Patel AJ, Boatey J, Muns J, Bollo RJ, Whitehead WE, Giannoni CM, Jea A (2012) Endoscopic endonasal odontoidectomy in a child with chronic type 3 atlantoaxial rotatory fixation: case report and literature review. *Childs Nerv Syst* 28:1971–1975. doi:[10.1007/s00381-012-1818-5](https://doi.org/10.1007/s00381-012-1818-5)
16. Frempong-Boadu AK, Faunce WA, Fessler RG (2002) Endoscopically assisted transoral-transpharyngeal approach to the craniovertebral junction. *Neurosurgery* 51:S60–S66
17. Menezes AH (2008) Surgical approaches: postoperative care and complications “transoral-transpalatopharyngeal approach to the craniocervical junction”. *Childs Nerv Syst* 24:1187–1193. doi:[10.1007/s00381-008-0599-3](https://doi.org/10.1007/s00381-008-0599-3)
18. Naderi S, Pamir MN (2001) Further cranial settling of the upper cervical spine following odontoidectomy. Report of two cases. *J Neurosurg* 95:246–249
19. Goel A (2005) Progressive basilar invagination after transoral odontoidectomy: treatment by atlantoaxial facet distraction and craniovertebral realignment. *Spine (Phila Pa 1976)* 30:E551–E555 (00007632-200509150-00025 [pii])
20. Tuite GF, Veres R, Crockard HA, Sell D (1996) Pediatric transoral surgery: indications, complications, and long-term outcome. *J Neurosurg* 84:573–583. doi:[10.3171/jns.1996.84.4.0573](https://doi.org/10.3171/jns.1996.84.4.0573)
21. Visocchi M, Pietrini D, Tufo T, Fernandez E, Di Rocco C (2009) Pre-operative irreducible C1–C2 dislocations: intra-operative reduction and posterior fixation. The “always posterior strategy”. *Acta Neurochir (Wien)* 151:551–559. doi:[10.1007/s00701-009-0271-z](https://doi.org/10.1007/s00701-009-0271-z) (discussion 560)
22. Yoshifuji K, Imaizumi T, Iihoshi S, Miyata K, Toyama K (2005) Chiari malformation (type 1) with regeneration of removed C1 lamina after foramen magnum decompression: a case report. *No Shinkei Geka* 33:257–260
23. Rahme R, Koussa S, Samaha E (2009) C1 arch regeneration, tight cisterna magna, and cervical syringomyelia following foramen magnum surgery. *Surg Neurol (discussion 85-86)* 72:83–85. doi:[10.1016/j.surneu.2008.01.041](https://doi.org/10.1016/j.surneu.2008.01.041) (S0090-3019(08)00056-6 [pii])
24. Hudgins RJ, Boydston WR (1995) Bone regrowth and recurrence of symptoms following decompression in the infant with Chiari II malformation. *Pediatr Neurosurg* 23:323–327
25. Aoki N, Oikawa A, Sakai T (1995) Spontaneous regeneration of the foramen magnum after decompressive suboccipital craniectomy in Chiari malformation: case report. *Neurosurgery* 37:340–342
26. Adekeye EO (1977) Rapid bone regeneration subsequent to subtotal mandibulectomy. Report of an unusual case. *Oral Surg Oral Med Oral Pathol* 44:521–526
27. Kisner WH (1980) Spontaneous posttraumatic mandibular regeneration. *Plast Reconstr Surg* 66:442–447
28. Shuker S (1985) Spontaneous regeneration of the mandible in a child. A sequel to partial avulsion as a result of a war injury. *J Maxillofac Surg* 13:70–73
29. de Villa GH, Chen CT, Chen YR (2003) Spontaneous bone regeneration of the mandible in an elderly patient: a case report and review of the literature. *Chang Gung Med J* 26:363–369
30. Abdulai AE (2012) Complete spontaneous bone regeneration following partial mandibulectomy. *Ghana Med J* 46:174–177
31. Street J, Winter D, Wang JH, Wakai A, McGuinness A, Redmond HP (2000) Is human fracture hematoma inherently angiogenic? *Clin Orthop Relat Res* 378:224–237
32. Lee SK, Kim YS, Oh HS, Yang KH, Kim EC, Chi JG (2001) Prenatal development of the human mandible. *Anat Rec* 263:314–325
33. Muller F, O’Rahilly R (1980) The human chondrocranium at the end of the embryonic period, proper, with particular reference to the nervous system. *Am J Anat* 159:33–58. doi:[10.1002/aja.1001590105](https://doi.org/10.1002/aja.1001590105)
34. Postacchini F, Cinotti G (1992) Bone regrowth after surgical decompression for lumbar spinal stenosis. *J Bone Joint Surg Br* 74:862–869
35. Chen Q, Baba H, Kamitani K, Furusawa N, Imura S (1994) Postoperative bone re-growth in lumbar spinal stenosis. A multivariate analysis of 48 patients. *Spine (Phila Pa 1976)* 19:2144–2149
36. Cokluk C, Aydin K, Rakunt C, Iyigun O, Onder A (2006) The borders of the odontoid process of C2 in adults and in children including the estimation of odontoid/body ratio. *Eur Spine J* 15:278–282. doi:[10.1007/s00586-005-0946-y](https://doi.org/10.1007/s00586-005-0946-y)
37. Bailey DK (1952) The normal cervical spine in infants and children. *Radiology* 59:712–719. doi:[10.1148/59.5.712](https://doi.org/10.1148/59.5.712)
38. Fassett DR, McCall T, Brockmeyer DL (2006) Odontoid synchondrosis fractures in children. *Neurosurg Focus* 20:E7
39. Bjork A (1955) Cranial base development. *Am J Orthod* 41:198–225
40. Shirley NR, Jantz RL (2011) Spheno-occipital synchondrosis fusion in modern Americans. *J Forensic Sci* 56:580–585. doi:[10.1111/j.1556-4029.2011.01705.x](https://doi.org/10.1111/j.1556-4029.2011.01705.x)
41. Bassed RB, Briggs C, Drummer OH (2010) Analysis of time of closure of the spheno-occipital synchondrosis using computed tomography. *Forensic Sci Int* 200:161–164. doi:[10.1016/j.foresci.2010.04.009](https://doi.org/10.1016/j.foresci.2010.04.009)