

Drug fever caused by propofol in the intensive care unit

Tomoaki Yatabe¹ · Koichi Yamashita¹ · Masataka Yokoyama¹

Received: 10 February 2015 / Accepted: 12 March 2015 / Published online: 24 March 2015
© Japanese Society of Anesthesiologists 2015

Abstract Few studies have reported that fever is caused by intravenous sedative drugs even though these agents are widely used. We present a case of propofol-induced drug fever. A 57-year-old woman underwent hepatic segmentectomy. Although she was diagnosed with type I glycogen storage disease when in her twenties, her liver function was normal. As the operative hemorrhage was high, the patient was transferred to the intensive care unit (ICU). Her temperature at ICU admission was 35.8 °C, and sedation with propofol and dexmedetomidine was initiated. Two hours after admission to the ICU, the patient had a fever of 38–39.5 °C. Remittent fever persisted until day 5 after surgery. Because of her persistent fever, pneumonia was suspected and antibiotics were initiated on day 4 after surgery. As the fever persisted after the initiation of antibiotics, drug fever was suspected. On day 5 after surgery, propofol infusion was discontinued and the patient was extubated. Her temperature of 37.7 °C at the discontinuation of propofol infusion, and rapidly decreased to 36.1 °C in the following 3 h. Propofol-induced drug fever must be considered in cases of fever of unknown origin when patients receive propofol and appear inappropriately well for the degree of fever that they have.

Keywords Drug fever · Remittent fever · Propofol · Dexmedetomidine · Type I glycogen storage disease

Introduction

In critically ill patients, fever is a common symptom, and the incidence of fever in the intensive care unit (ICU) is 26–70 % [1]. A previous study reported that 50 % of fever in the ICU is the result of an infection and the remaining half has causes other than infection [2]. Drug fever is well known as one cause of non-infection-induced fever. The drugs most commonly implicated in the ICU include antibiotics, anticonvulsants, and anti-arrhythmics [1]. On the other hand, few studies have reported that fever is caused by intravenous sedative drugs even though these agents are widely used. However, propofol-induced drug fever has not been reported previously. We present here a case of propofol-induced drug fever.

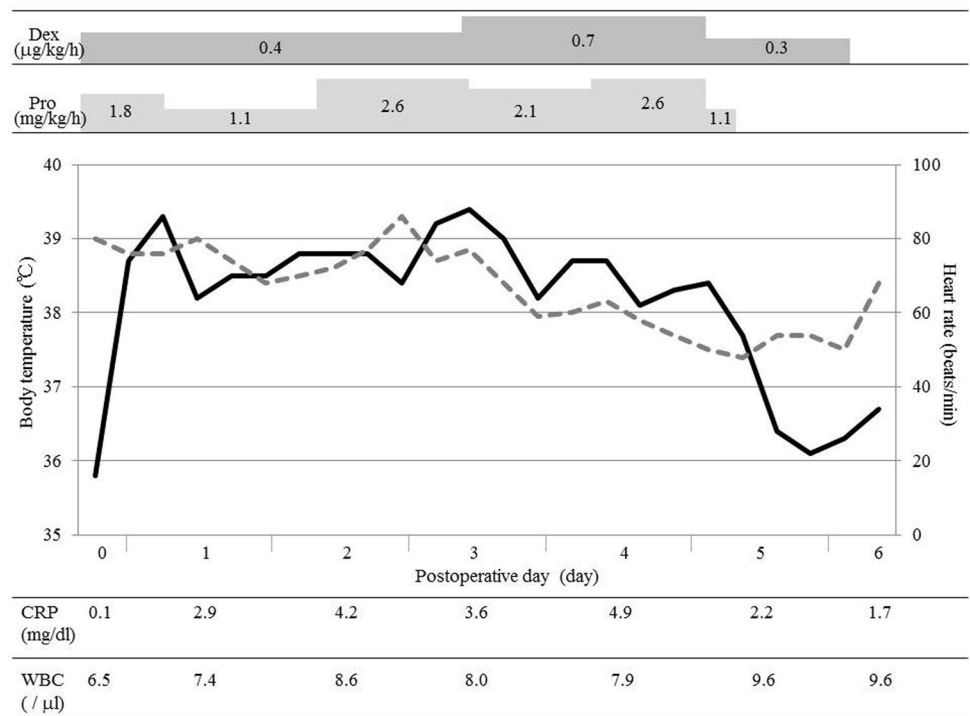
Case report

A 57-year-old woman was diagnosed with type I glycogen storage disease in her twenties. When she was 36 years old, she underwent lateral segmentectomy of the liver for hepatocellular adenoma. A few months ago, mass lesions were detected in the segments (S) 1 and 7 of the liver. Therefore, hepatic segmentectomy (S1) and subsegmentectomy (S8) were planned. During the preoperative examination, total bilirubin level, albumin level, and prothrombin time (as percentage) were found to be 0.3 mg/dl, 4.2 g/dl, and 103.4 %, respectively. The patient had no ascites, her liver damage was grade A, and the indocyanine green retention rate at 15 min was 8.6 %. Anesthesia was induced with propofol (1 % propofol injection “Maruishi”; Maruishi Pharmaceutical, Osaka, Japan, 100 mg), rocuronium (40 mg), and fentanyl (100 µg), and was maintained with sevoflurane, epidural anesthesia, and remifentanyl. A

✉ Tomoaki Yatabe
yatabe@kochi-u.ac.jp

¹ Department of Anesthesiology and Intensive Care Medicine, Kochi Medical School, Kohasu, Oko-cho, Nankoku, Kochi 783-8505, Japan

Fig. 1 Alternation of body temperature, heart rate, C-reactive protein levels, and white blood cell counts. *Black line* indicates body temperature, *gray broken line* indicates heart rate. *Dex* dexmedetomidine, *Pro* propofol, *CRP* C-reactive protein, *WBC* white blood cell counts



prophylactic antibiotic (cefazolin) was used only during surgery.

As the operative hemorrhage was high (1,730 ml), the patient was transferred to the ICU under intubation. Her temperature at ICU admission was 35.8 °C, and sedation with propofol (1 % diprivan injection; AstraZeneca, Osaka, Japan, 1.8 mg/kg/h) and dexmedetomidine (0.4 μg/kg/h) was initiated. Two hours after admission to the ICU, the patient had a fever (temperature 38–39.5 °C) (Fig. 1). Fourteen hours after ICU admission, the patient had an elevated temperature of 39.3 °C and her white blood cell count and C-reactive protein level were approximately 7,400/μl and 2.9 mg/dl, respectively. Extubation was not performed because of persistent fever, and propofol (1.1–2.6 mg/kg/h) and dexmedetomidine (0.4–0.7 μg/kg/h) were adjusted according to the degree of sedation. Analgesia was managed with epidural anesthesia until day 4 of admission. Remittent fever persisted until day 5 after surgery. During this period, her white blood cell counts and C-reactive protein levels ranged from 8,600 to 9,600/μl and from 2.2 to 4.2 mg/dl, respectively. However, her temperature increased to 39.5 °C on day 3 after surgery, and although two sets of blood cultures were collected, both were negative. Her pulse was 76 beats/min at this time. A sputum culture was performed. Gram staining revealed the presence of pneumococcus on day 5 after surgery. Although chest radiography detected pleural effusion, no signs of pneumonia were observed. Although pleural fluid drainage was performed, it was clear and yellow. Then, the pleural fluid culture was

negative. However, owing to the persistent fever, pneumonia was suspected and tazobactam sodium/piperacillin sodium was initiated. On day 4 after surgery, the patient’s procalcitonin level was 0.996 ng/ml. As the fever persisted after the initiation of antibiotics, drug fever was suspected. On day 5 after surgery, propofol infusion was discontinued and the patient was extubated. Her temperature was 37.7 °C at the time of discontinuation of propofol infusion, and it rapidly decreased to 36.1 °C in the following 3 h. Although dexmedetomidine was continued until day 6 after surgery, the patient showed no further signs of fever. Based on the results for the sensitivity of the sputum culture, the antibiotics were switched to oral potassium clavulanate/amoxicillin. On the same day, the patient had a temperature of 36.7 °C and was transferred to the general ward. On day 17 after surgery, she exhibited no signs of complication and was discharged.

Discussion

Propofol and dexmedetomidine are widely used because they are recommended for sedation in the ICU [3]. A literature search of PubMed and Ovid MEDLINE revealed that propofol-induced drug fever has not been reported previously. There are no clear diagnostic guidelines for drug fever, which tends to be a diagnosis of exclusion [4] and is characterized by antipyresis after discontinuation of the suspected drug [4, 5]. Our patient was diagnosed with drug

Table 1 All drugs used for this patient

	POD 0	POD 1	POD 2	POD 3	POD 4	POD 5	POD 6
Propofol	[Redacted]						
Dexmedetomidine	[Redacted]						
Levobupivacaine	[Redacted]						
Cefazolin	[Redacted]						
Tazobactam/Piperacillin				[Redacted]			
Potassium Canrenoate	[Redacted]						
Hydrocortisone	[Redacted]						
Dopamine	[Redacted]						
Total parental nutrition	[Redacted]						

POD postoperative day

fever because we observed a rapid reduction in temperature after the discontinuation of propofol. In the previous report regarding dexmedetomidine-induced drug fever, the patient's fever was alleviated within 1 h of the completion of administration [5]. Dexmedetomidine could not have been a causative agent in our case because it was administered continuously after extubation. Although hydrocortisone was used as routine postoperative management at 7 AM on day 5, extubation was subsequently performed 7 h after the bolus infusion. We did not suspect the other drugs, because the timing of the discontinuation and the reduction of the patient's fever were not identical (Table 1).

In patients with drug fever, relative bradycardia is present [4]. In addition, the patient often appears inappropriately well for the degree of fever that they have [4]. Our patient had a pulse rate of approximately 75 beats/min, although her maximum temperature was 39.5 °C. Although we might have diagnosed drug fever earlier if we had understood the significance of these symptoms, dexmedetomidine and propofol both decrease heart rate. Therefore, we think that it is difficult to recognize drug fever based on relative bradycardia alone in sedative patients.

Based on their effects on the temperature regulatory center, idiosyncratic drug reaction, allergic reaction, and related drug administration are all considered causes of drug fever [4, 5]. In our patient, although the propofol used for anesthesia induction was not the same as the propofol used for sedation, the fever might have developed after the initiation of sedation consequent to sensitization during anesthesia induction. In addition, her fever may have been related to her glycogen storage disease as propofol

Table 2 Alternation of the laboratory data

	POD 0	POD 1	POD 3	POD 5	POD 6
ALT (U/l)	646	589	1316	454	329
AST (U/l)	2405	2394	3395	288	154
CK (U/l)	236	692	375	139	89
Crn (mg/dl)	0.34	0.58	0.46	0.37	0.27
BUN (mg/dl)	14	26	29	30	31
BE (mmol/l)	7.1	10.3	8.1	3.2	6.1
Lactate (mmol/l)	12.0	5.5	4.0	4.8	3.8
Glucose (mg/dl)	141	147	223	194	224

POD postoperative day

is metabolized in the liver. However, there have been only two previous reports about a relationship between propofol and glycogen storage disease; arrhythmia and pancreatitis occurred in each report [6, 7]. Malignant hyperthermia and hyperthermia have also been reported in some types of glycogen disease when the patients were under general anesthesia [8, 9]. However, the laboratory data in our case did not reveal any serious metabolic disorders, such as malignant hyperthermia or liver failure (Table 2). Nevertheless, as we could not obtain the details regarding her previous perioperative data from the lateral segmentectomy (when she was 36 years old), any possible relationship remains unclear.

Because a diagnosis of drug fever requires the exclusion of other potential diagnoses, we had to consider other factors. First, we had to exclude infection. Given that pneumococcus was detected in her sputum, it is possible that

her fever might have been caused by pneumonia. However, pneumonia was not detected after chest radiography, and her fever did not decrease in the days after initiation of antibiotics. In addition, blood and pleural fluid cultures were both negative and her surgical wound was clear. Although remittent fever might be a sign of catheter-related bloodstream infection, we used the same central venous catheter until 12 days after surgery. In addition, we considered the possibility that contaminated propofol induced sepsis with high fever, although we excluded this possibility because of her good general condition, negative blood culture, and procalcitonin levels. Second, the influence of surgery: some type of infection might improve on day 5 after surgery as the natural course of ICU treatment. In fact, plasma interleukin-6 level was 9.1 pg/ml (normal range is <4.0 pg/ml) at 7 AM on day 5, although we suspected fever caused by a cytokine storm. However, we also excluded this possibility, as her temperature rapidly decreased after discontinuation of the propofol. Finally, a humidifier in the ventilator circuit might have caused heat retention, as we used a heated humidifier (set at 37.0 °C; MR850 Heated Humidifier, Fisher & Paykel Healthcare Auckland, New Zealand). However, a previous randomized study of patients during spinal surgery reported that body temperature did not reach 37.0 °C in the patients who received a heated humidifier, although it did maintain their body temperature [10]. Although that finding may not generalize to our case, as we did not treat the patient in an operating suite, we excluded the possible influence of the heated humidifier, as the patient's fever was higher than the heat retention in this case. Therefore, we conclude that there was a high possibility of a drug fever in the present case.

Although the prognosis of drug fever after discontinuation is good, it can cause prolonged hospitalization and increase healthcare costs [4, 11]. In fact, our patient needed longer mechanical ventilation.

In conclusion, propofol-induced drug fever must be considered in cases of fever of unknown origin when patients receive propofol and appear inappropriately well for the degree of fever that they have.

Acknowledgments We obtained informed consent from the patient for a case report.

References

1. Rehman T, Deboisblanc BP. Persistent fever in the ICU. *Chest*. 2014;145:158–65.
2. Circiumaru B, Baldock G, Cohen J. A prospective study of fever in the intensive care unit. *Intensive Care Med*. 1999;25:668–73.
3. Barr J, Fraser GL, Puntillo K, Ely EW, Gélinas C, Dasta JF, Davidson JE, Devlin JW, Kress JP, Joffe AM, Coursin DB, Herr DL, Tung A, Robinson BR, Fontaine DK, Ramsay MA, Riker RR, Sessler CN, Pun B, Skrobik Y, Jaeschke R. Clinical practice guidelines for the management of pain, agitation, and delirium in adult patients in the intensive care unit. *Crit Care Med*. 2013;41:263–306.
4. Patel RA, Gallagher JC. Drug fever. *Pharmacotherapy*. 2010;30:57–69.
5. Okabe T, Takeda S, Akada S, Hongo T, Sakamoto A. Postoperative intensive care unit drug fever caused by dexmedetomidine. *Anesth Analg*. 2009;108:1589–91.
6. Bustamante SE, Appachi E. Acute pancreatitis after anesthesia with propofol in a child with glycogen storage disease type IA. *Paediatr Anaesth*. 2006;16:680–3.
7. Wang LY, Ross AK, Li JS, Dearnley SM, Mackey JF, Worden M, Corzo D, Morgan C, Kishnani PS. Cardiac arrhythmias following anesthesia induction in infantile-onset Pompe disease: a case series. *Paediatr Anaesth*. 2007;17:738–48.
8. Bollig G, Mohr S, Raeder J. McArdle's disease and anaesthesia: case reports. Review of potential problems and association with malignant hyperthermia. *Acta Anaesthesiol Scand*. 2005;49:1077–83.
9. Edelstein G, Hirshman CA. Hyperthermia and ketoacidosis during anesthesia in a child with glycogen-storage disease. *Anesthesiology*. 1980;52:90–2.
10. Lee HK, Jang YH, Choi KW, Lee JH. The effect of electrically heated humidifier on the body temperature and blood loss in spinal surgery under general anesthesia. *Korean J Anesthesiol*. 2011;61:112–6.
11. Vodovar D, LeBeller C, Mégarbane B, Lillo-Le-Louet A, Hanslik T. Drug fever: a descriptive cohort study from the French national pharmacovigilance database. *Drug Saf*. 2012;35:759–67.