

# Effect of adding cervical facet joint injections in a multimodal treatment program for long-standing cervical myofascial pain syndrome with referral pain patterns of cervical facet joint syndrome

Sung-Chun Park · Kyung-Hoon Kim

Received: 12 September 2010 / Accepted: 19 April 2012 / Published online: 31 May 2012  
© Japanese Society of Anesthesiologists 2012

## Abstract

**Purpose** Cervical facet joint (CFJ) syndrome is a common disorder observed in chronic pain of the cervical region, especially in long-standing myofascial pain syndrome (MPS). This study aimed to investigate the effects of therapeutic CFJ injections on patients with long-standing cervical MPS with referral pain patterns of CFJ syndrome.

**Methods** Four hundred patients presented with long-standing cervical MPS with referral pain patterns of CFJ syndrome over a period of 6 months. A randomized clinical trial was performed wherein 200 patients (group 1) received therapeutic CFJ injections at bilateral C5/C6 and C6/C7 after diagnostic, controlled double-blind blocks. The same cointerventions, such as medication and a home exercise program, were simultaneously applied to patients in group 1 and the noninjection group (group N). Cervical range of motion (CROM), mean reduction of numeric rate scale (NRS) for pain, and comorbid tension-type headache were compared between groups during the 1-year follow-up period. Treatment duration and symptom-free periods were compared according to age group.

**Results** Group 1 showed increased CROM, increased mean NRS pain reduction, and decreased incidence of combined tension-type headache compared with group N during the follow-up. Younger patients in group 1 required a shorter treatment cycle and experienced a longer symptom-free period.

**Conclusion** Addition of therapeutic CFJ injections to a multimodal treatment program is a useful therapeutic modality for patients, especially young patients, suffering from long-standing MPS with referral pain of CFJ syndrome.

**Keywords** Cervical pain · Intra-articular injections · Myofascial pain syndrome · Referred pain · Zygapophyseal joint

## Introduction

Myofascial pain syndrome (MPS) is characterized by regional or widespread myalgia with muscle trigger points in one or more muscles, taut bands, referred pain, sensory changes, and local twitch response [1]. Common cervical myofascial trigger points are located at the trapezius, splenius capitis or cervicis, levator scapulae, anterior and medial scalene, and infraspinatus muscles [2]. Long-standing cervical MPS may lead to postural static mechanical stress on the cervical facet joints (CFJ), especially on the supraspinous and infraspinous with the interscapular area, which is where the referral pain patterns of CFJ C5/C6 and C6/C7 occur [3].

It is difficult to treat long-standing cervical MPS with referral pain patterns of CFJ syndrome using trigger-point injection, physiotherapy, and pharmacological treatment without any intervention on the facet joint lesions. The known prevalence of facet joint pain in patients with chronic cervical spine pain is 55 % [4], but the false-positive rate of the single diagnostic block varies from 27 to 63 % [5]. Macroscopic inspection of the cartilaginous surface of the facet joints indicates that the prevalence of CFJ degeneration is probably high, with a tendency to increase in severity with age [6].

S.-C. Park · K.-H. Kim (✉)  
Department of Anesthesia and Pain Medicine,  
School of Medicine, Pusan National University,  
Bumeuri, Mulgeumup, Yangsan,  
Kyungsangnamdo 626-770, Korea  
e-mail: pain@pusan.ac.kr

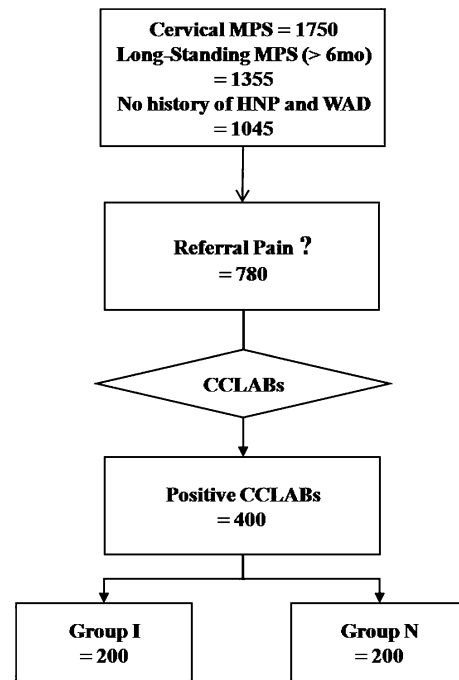
This prospective randomized controlled study was performed to investigate the effects of therapeutic CFJ injections on C5/C6 and C6/C7 in a multimodal treatment program of patients with long-standing cervical MPS with referral pain patterns of CFJ syndrome, which was diagnosed by using controlled comparative local anesthetic blocks according to age groups.

## Materials and methods

This study was conducted at a pain clinic at Pusan National University in Korea. The recruitment period lasted from March 2002 to February 2008. The protocol was approved by the Policy of the Ethical Committee at Pusan National University Hospital Institutional Review Board. Eligible patients were informed about the study procedure and agreed to participate. MPS was defined as cervical myalgia with more than three of the following five symptoms: trigger points in one or more muscles of the trapezius, splenius capitis or cervicis, levator scapulae, anterior and medial scalene, and infraspinatus muscles; taut bands; referred pain; sensory changes; and local twitch response [1, 2]. Among 1,750 occurrences of cervical MPS, 1,355 had symptom duration of >6 months. Exclusion criteria were: (1) history of radiating pain in the shoulder and upper extremities, (2) cervical radiculopathy on electrodiagnostic examination, (3) herniated nucleus pulposus and spinal stenosis on magnetic resonance imaging (MRI) and computed tomography (CT), and (4) previous neck trauma from traffic accident or fall to exclude herniated nucleus pulposus, spinal stenosis, and whiplash-associated disorders, leaving 1,045 patients. Of these 1,045 patients, 780 presented suspicious supraspinous and infraspinous with interscapular-area referred pain patterns of CFJ syndrome [3], of whom 400 tested positive for controlled comparative local anesthetic blocks using 0.3 ml of 1 % lidocaine and 0.25 % bupivacaine on their first and second visits, respectively [7]. Of the 400 patients, 200 were randomly assigned to group 1 and received therapeutic CFJ injections on the bilateral C5/C6 and C6/C7; group N comprised patients who had not received therapeutic CFJ injections (Fig. 1).

For a diagnostic result to be considered positive using controlled comparative local anesthetic blocks, pain relief must last for at least 2 h with lidocaine and with bupivacaine at least 3 h or more longer than lidocaine-induced pain relief. The intensity of pain relief must reach a minimum value of 80 %. Any other response was considered negative. Patients with lidocaine-positive results were further tested with bupivacaine on a separate occasion, usually 1 week after the first visit [8].

Therapeutic CFJ injections were administered via a posterior approach after 3 weeks of controlled comparative

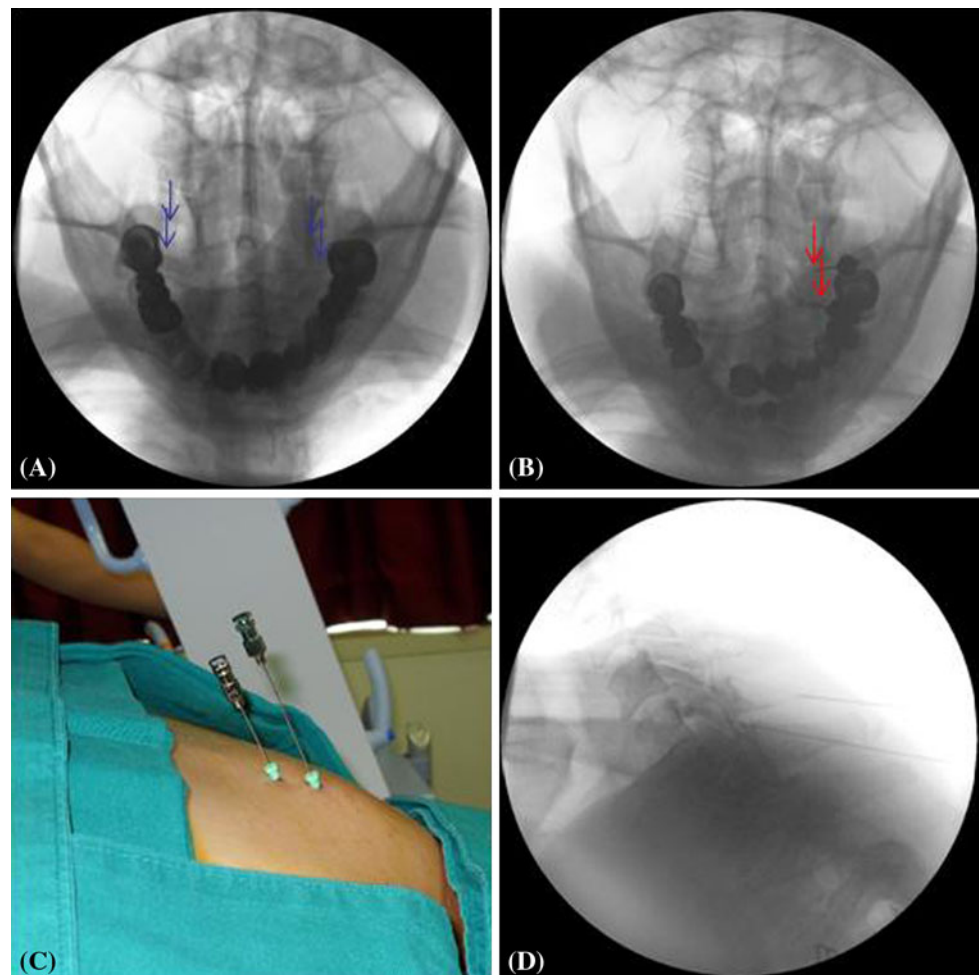


**Fig. 1** Patient flow. MPS myofascial pain syndrome, HNP herniated nucleus pulposus, WAD whiplash-associated disorder, CCLABs controlled comparative local anesthetic blocks. Group 1 cervical facet joint injection group. Group N noninjection group

local anesthetic blocks with both lidocaine and bupivacaine. Patients had to lie in the prone position with a pillow. The injections were performed with a 22-gauge 10-cm spinal needle under intermittent fluoroscopic visualization. After inserting the first needle, 0.3 ml of iopamidol contrast medium (Pamiray<sup>®</sup> 300, Dongkook Pharm., Seoul, Korea) was injected to confirm the joint space by intermittent anteroposterior and lateral fluoroscopic visualization. Therapeutic CFJ injections were administered to each joint of the bilateral C5/C6 and C6/C7 using a mixture of 0.5 ml of 1 % lidocaine, 5 mg of triamcinolone (Rheudonolone<sup>®</sup>, Kukje Pharm., Ansan, Korea), and 187.5 IU of hyaluronidase (Hlase<sup>®</sup>, Kuhnil Pharm., Chunan, Korea) (Fig. 2) [9].

Both groups were prescribed identical medication and a self-supervised home program comprising self-myofascial-release exercises to alleviate trigger points, which was performed 20 times a day from the first visit. Patients were trained to lift their hands, place them on a table at the height of their anterior superior iliac spine, then, in a squatting position, hold the posture for 5 s with a neutral neck position, for 10 s with neck extension, and for 10 s with neck flexion (Fig. 3). If they had not performed the exercises between every visit, they were to do so before they could return home. A mixture of 10 mg of codeine-containing weak opioid, 250 mg of acetaminophen, and 200 mg of ibuprofen (Mypol<sup>®</sup>, Sungwon Adcock Pharm.,

**Fig. 2** Therapeutic cervical facet joint injections at the bilateral C5/C6 and C6/C7. **a** Among the four targeted joints, the one best viewed under fluoroscopic guidance was injected first, and the order followed the direction of the arrows. **b** The tip of the upper needle is withdrawn from the muscle after injection in the left C5/C6 facet joint, and the tip of lower needle is placed on the left C6/C7 facet joint to guide its angle and depth on the anteroposterior fluoroscopic view. **c** The upper needle is withdrawn from the joint, in comparison with the lower needle. **d** The same situation is shown on the lateral fluoroscopic view



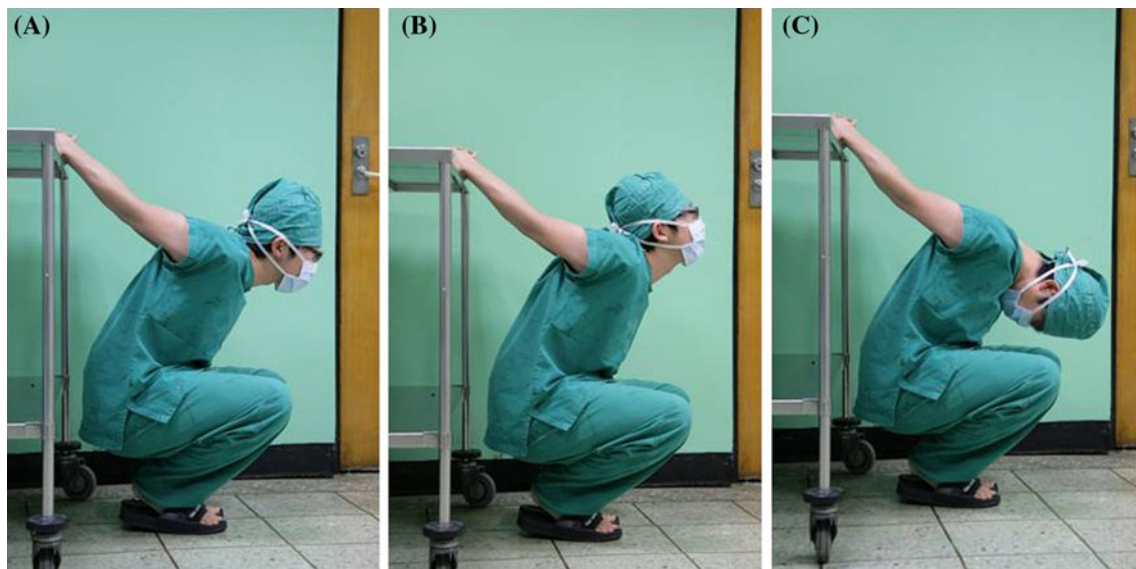
Kimpo, Korea) with 1 mg of tizanidine (Sirdalud<sup>®</sup>, Novartis Pharm., Sasayama, Japan) three times daily was prescribed as a muscle relaxant.

At their first visit, patients were advised to attend the pain clinic for evaluation of their cervical range of motion (CROM), numeric rating scale (NRS; from 0 to 10, with 0 indicating no pain and 10 indicating the worst pain imaginable), and comorbid tension-type headache. The first diagnostic block with lidocaine was performed at the first visit. If the first block was positive, the second block with bupivacaine was performed 1 week later at the second visit. If the second block was positive, therapeutic CFJ injections were performed at the third visit. Patients were subsequently advised to return to the clinic on a monthly basis for 1 year after receiving therapeutic CFJ injections. At the first and second posttherapeutic CFJ injection visits, 1 ml of 1 % lidocaine was injected to the remaining trigger points. At the third posttherapeutic CFJ injection visit, it was recommended to inject 50 IU of botulinum toxin type A (Botox<sup>®</sup>, Allergan Pharm. Inc., Westport, Ireland) to the remaining trigger points on each trapezius muscle if the patients consented. CROM, which

included flexion, extension, right/left flexion, and right/left rotation, NRS, and comorbid tension-type headache were evaluated before administering the therapeutic CFJ injections after 1 week, 4 weeks, and the monthly follow-up period (Fig. 4).

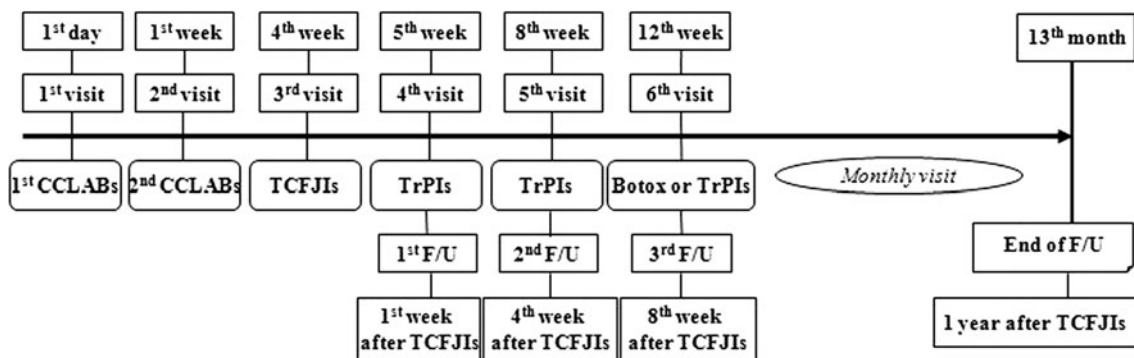
Criteria for subjective successful treatment were a mean reduction in NRS scores  $>4/10$  or those  $<3/10$  and absence of comorbid tension-type headache since the last visit. In addition, the criterion for objective successful treatment was  $>90\%$  recovery of all CROM. If criteria for the subjective and objective successful treatments were fulfilled, monthly follow-up visits were stopped, and the patients were recommended to visit after 3 months, 6 months, and 1 year of treatment. Treatment duration and the symptom-free period were also evaluated according to age group (young:  $<45$  years; middle: between 45 and 64 years; elderly:  $>64$  years) for both intergroup and intragroup comparisons.

Statistical analysis was performed using the SPSS ver. 12.0 for Windows software (SPSS Inc., Chicago, IL, USA). Values were calculated as mean  $\pm$  standard deviation (SD). Demographic characteristics, including age



**Fig. 3** Home program of self-myofascial-release exercises to alleviate trigger points. Patients stood with their feet shoulder-width apart, clasped their hands behind their backs, and pulled down toward the floor. They then lifted up their hands and put them on a table at the

height of their anterior superior iliac spine; then, in a squatting position, they held the posture for **a** 5 s with neutral neck position, **b** for 10 s with neck extension, and **c** 10 s with neck flexion



**Fig. 4** Follow-up visit schedule and additional interventions for long-standing cervical myofascial pain syndromes with referral pain from the C5/C6 and C6/C7 facet joint. *CCLABs* controlled comparative

local anesthetic blocks, *TCFJIs* therapeutic cervical facet joint injections, *TrPIs* trigger point injections

and sex, were analyzed using the Student *t* test and the chi-square test in the intergroup comparison. Changes in CROM and NRS before and after treatment were used as repeated measures using the analysis of variance (ANOVA) test and corrected using the Bonferroni adjustment method in the intragroup comparison. Fisher’s exact test was used to test the differences in the proportions of comorbid tension-type headache between groups 1 and N before and after treatment. Treatment duration and symptom-free period were evaluated using Student’s *t* test in the intergroup comparison. Age group comparison in the intragroup for treatment duration and symptom-free period was obtained using the ANOVA test with multiple comparisons, with Bonferroni correction in the intragroup comparison.

**Results**

Because 94 patients (group 1 45; group N 49) were lost to follow-up during the first year, 155 patients remained in group 1 and 151 patients in group N. Patient’s demographic characteristics are shown in Table 1. No significant differences were found in mean age, age distribution, sex ratio, symptom duration, and comorbid tension-type headache between groups (Table 1).

Group 1 showed increased CROM, a marked reduction in NRS, and a decreased incidence of combined tension-type headache compared with group N at the 1-week, 3-month, 6-month, and 1-year follow-up ( $p < 0.05$ ) (Fig. 5). Group 1 also showed a decreased number of visits compared with group N across all age groups. The young

**Table 1** Patient's demographic characteristics

	Group 1 (n = 155)	Group N (n = 151)
Age (years)	55.2 ± 20.6	53.5 ± 19.5
Age groups (%)		
Young	35 (22.6)	37 (24.5)
Middle	77 (49.7)	76 (50.3)
Elderly	43 (27.7)	38 (25.1)
Male/female (male proportion, %)	46/109 (30.0)	54/97 (35.8)
Symptom durations (%)		
6 months–1 year	26 (16.7)	32 (21.2)
1 year–2 years	19 (12.3)	19 (12.6)
>2 years	110 (70.9)	100 (66.2)
Comorbid tension-type headache (%)	95 (61.2)	90 (59.6)

No significant differences noted among groups when comparing mean age, age distribution, sex ratio, symptom duration, and comorbid tension-type headache

*Group 1* patients who received therapeutic cervical facet joint injections at bilateral C5/C6 and C6/C7 after controlled comparative local anesthetic blocks, *group N* patients who received conservative treatment only for cervical myofascial pain syndrome after controlled comparative local anesthetic blocks, *Young* <45 years, *Middle* 45–64 years, *elderly* ≥65 years

age group in group 1 showed a markedly decreased number of visits compared with other age groups and a longer duration of symptom-free period across all age groups over the 1-year study period. They also showed a markedly longer symptom-free period after treatment compared with other age groups till the end of the study (Table 2).

Thirteen patients (seven in group 1 and six in group N) were injected with 10 ml of 1 % lidocaine solution with 100 IU botulinum toxin A for chronic tension-type headache with myofascial trigger points on both upper trapezius muscles. There were no adverse events reported during the study.

## Discussion

Therapeutic CFJ injections largely improved CROM, markedly reduced NRS and decreasing the incidence of combined tension-type headache compared with conservative treatments alone during the 1-year follow-up. They also decreased the number of visits and allowed a longer symptom-free period in all age groups, especially the young age group. Long-standing MPS and comorbid CFJ syndrome need to be treated simultaneously.

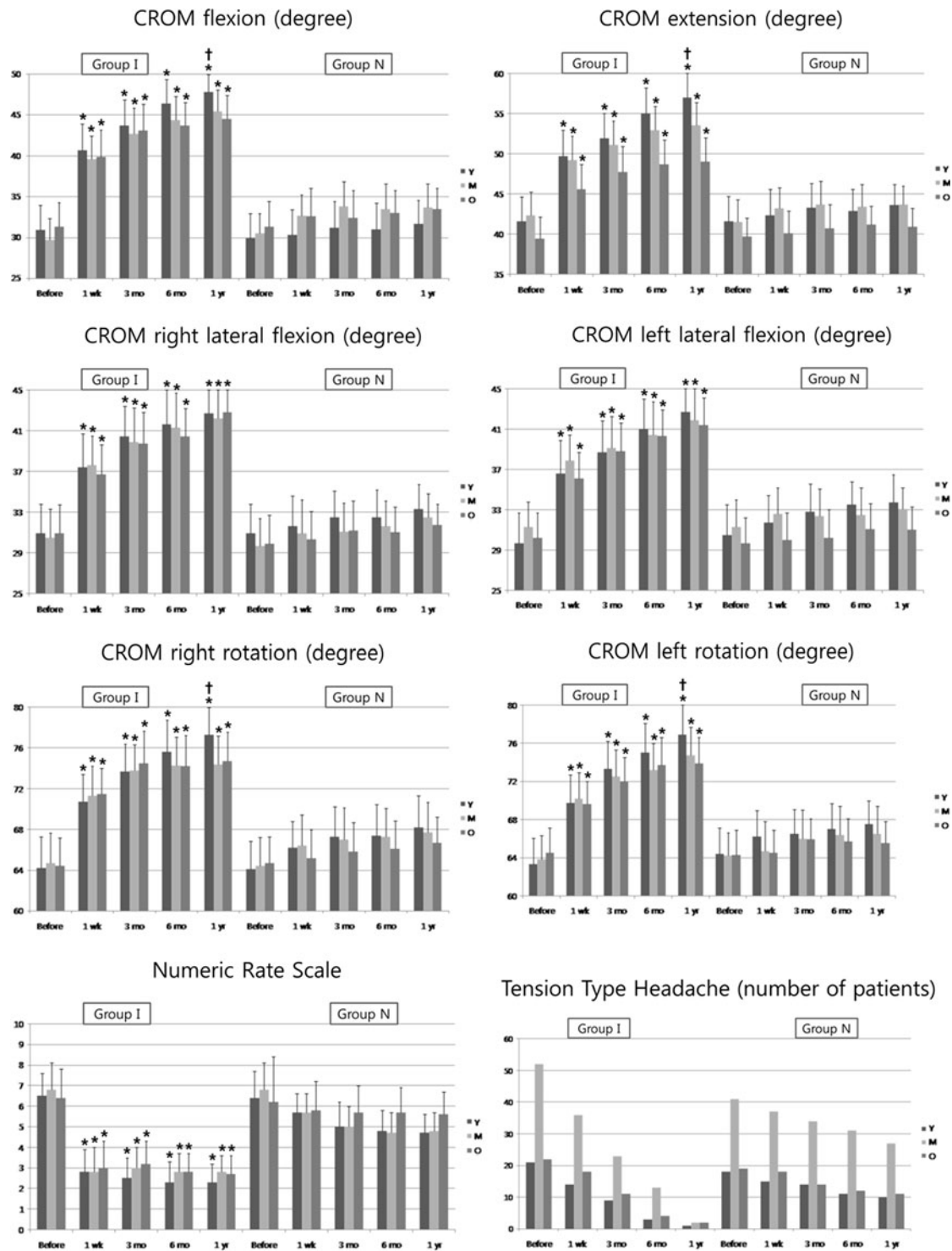
Muscle-related nociceptive stimulation of the peripheral and central nervous systems results in hypersensitivity. Both mechanical and systemic medical disorders cause

muscle stress. Mechanical problems can be structural or postural. Static (postural) or acute (trauma) muscle overload occurs in mechanical disorders, which results in physical and biochemical changes such as hypoxia, ischemia, and neuromuscular junction dysfunction [1]. Incorrect posture and spinal curvature for long periods alter the line of weight transmission, thereby increasing weight bearing and degenerative deformity of the CFJs.

Pathological changes attributed to facet joint degeneration can be articular cartilage thinning, sclerosis of the subchondral bone, osteophyte formation, or hypertrophy. Macroscopic inspection of the cartilaginous surface of the facet joints indicates that the prevalence of CFJ degeneration in individuals >50 years of age is probably high, with a tendency to increase in severity with age [6]. These results show that the young age group experiences fewer pathological changes in CFJs owing to a shorter history of bad cervical curvature. In order to provide hospital treatments with maximum therapeutic effects, patients are strongly advised to follow a home program of self-myofascial-release exercises to alleviate trigger points by maintaining correct alignment of the head, neck, and spine.

Deep somatic pain originates from ligaments, tendons, bones, blood vessels, fasciae, and muscles. It is difficult to differentiate the origin of pain from the muscle and/or fasciae (myotome) or the bones and/or joints (sclerotome). Depending on the pain source, referral pain corresponds with segmental innervation, representing the patterns of myotome or sclerotome rather than that of dermatome. It is difficult to differentiate between the possible origins of referral pain in cases of long-standing cervical MPS with comorbid CFJ syndrome. Typical referral pain patterns of CFJs in the C5/C6 and C6/C7 are distributed in the supraspinous and infraspinous regions with the interscapular area [3, 10], similar to the distribution of trigger points on the middle and lower trapezius. Referral pain patterns from the trigger points on the middle and lower trapezius may obscure those from the CFJs. If a dull, aching pain and limited CROM remains, then it is important to differentiate between pain from the latent trigger points and referral pain from the joints after treatment of the active trigger points.

The question remains, however: “What came first: the chicken or the egg”? The ultimate treatment goal for patients with long-standing MPS and comorbid referral pain patterns of CFJ syndrome is to remove the referred pain originating from the facet joints and muscle fasciae, thereby, recovering near-normal CROM and normal cervical curvature immediately, and to prevent the development of coexisting tension-type headache. Therapeutic CFJ injections could be a useful method for breaking the vicious cycle of pain caused by long-standing MPS with CFJ syndrome. It is also helpful to prescribe medications such as analgesics and muscle relaxants to break the cycle.



**Fig. 5** Changes in cervical range of motion, numeric rating scale, and tension-type headache during the 1-year follow-up period. *Group I* patients who received therapeutic cervical facet joint injections at bilateral C5/C6 and C6/C7 after diagnostic, controlled, double-blind blocks. *Group N* patients who received conservative treatments only for cervical myofascial pain syndrome after diagnostic, controlled, double-blind blocks. *CROM* cervical range of motion (normal range), *F* flexion (50°), *E* extension (60°), *RLF* right lateral flexion (45°), *LLF* left lateral flexion (45°), *RR* right rotation (80°), *LR* left rotation (80°), *Y* young age

group, *M* middle age group, *O* elderly age group, *numeric rating scale (NRS)* 0 being no pain at all and 10 being the worst pain imaginable, *TTH* number of patients with comorbid tension-type headache since last visit. *Asterisks* group I showed increased CROM, a marked reduction in NRS, and a decreased incidence of comorbid TTH compared with group N at 1-week, 3-month, 6-month, and 1-year follow-up ( $p < 0.05$ ). *Dagger symbols* young age group compared with other age groups in group I showed increased cervical flexion, extension, and right and left rotation at 1-year follow-up

**Table 2** Treatment duration and symptom-free period till the end of study according to age group

	Group 1	<i>P</i> value of intragroup 1	Group N	<i>P</i> value of intragroup N	<i>P</i> value of intergroup
Treatment duration (number of visits for treatment)					
Young	2.8 ± 0.7 <sup>a,b</sup>	–	6.6 ± 1.8	–	0.00
Middle	5.4 ± 2.3 <sup>a</sup>	0.02	7.9 ± 2.3	0.31	0.03
Elderly	6.1 ± 2.5 <sup>a</sup>	0.00	8.9 ± 2.9	0.28	0.04
Symptom-free period after treatment till the end of study (months)					
Young	10.2 ± 1.1 <sup>a,b</sup>	–	5.5 ± 2.1	–	0.00
Middle	6.5 ± 2.8 <sup>a</sup>	0.02	4.2 ± 1.3	0.41	0.04
Elderly	5.9 ± 2.9 <sup>a</sup>	0.00	3.1 ± 2.5	0.34	0.04

*Group 1* patients who received therapeutic cervical facet joint injections at bilateral C5/C6 and C6/C7 after controlled comparative local anesthetic blocks, *group N* patients who received conservative treatment only for cervical myofascial pain syndrome after controlled comparative local anesthetic blocks, *Young* <45 years, *Middle* 45–64 years, *Elderly* ≥65 years

<sup>a</sup> Group 1 showed a decreased number of visits and an increased symptom-free period compared with group N across all age groups

<sup>b</sup> The young age group in group 1 showed a decreased number of visits and an increased symptom-free period compared with other age groups in group 1

A decrease in the incidence of comorbid episodic and chronic tension-type headache was noted in group 1 after therapeutic CFJ injections. The effect of botulinum toxin A solution in the treatment of chronic tension-type headache with cervical myofascial trigger points lasted until the 3-month follow-up period, which was similar to the duration noted in a previous study [11]. It was difficult to evaluate the efficacy of botulinum toxin A because only 13 patients (six in group 1 and seven in group N) were injected depending on their economic status.

The known prevalence rate of facet joint pain in patients with chronic cervical spine pain is 55 % [4]. However, the false-positive rate of the single diagnostic block varies from 27 to 63 % [5]. The positive controlled comparative local anesthetic blocks suggest that the source of pain was the medial branch of the posterior ramus. However, pain reduction due to the controlled comparative local anesthetic blocks did not indicate that the facet joint was the sole source of pain. Although the facet joint is the sole source of pain according to the controlled comparative local anesthetic blocks, the therapeutic medial branch block does not warrant complete treatment of facet joint pathology. The presence of substance P and calcitonin gene-related peptide-reactive nerve fibers in the facet joint and capsule could be another source of pain in the pathological changes attributed to facet joint degeneration [12]. Thus, it is difficult to predict the long-term outcomes from the therapeutic medial branch blocks after using controlled comparative local anesthetic blocks and ignoring both facet joint pathology and pain mediators. If therapeutic medial branch ablations are considered as a treatment option, controlled comparative local anesthetic blocks are a choice for treatment. They are, however, not a necessary and sufficient condition for therapeutic medial branch blocks. A

certain degree of pain reduction may arise from blocking nerve conduction by injecting local anesthetics on the medial branch of the ramus, but the overall effect of adding steroids and hyaluronidase cannot be estimated. This study is limited with respect to predicting the effect of therapeutic CFJ injections from controlled comparative local anesthetic blocks. Future studies need to focus on comparisons between the efficacy of facet joint injections and medial branch blocks.

In conclusion, patients with long-standing MPS with referral pain patterns of CFJ syndrome should be diagnosed and treated according to the origin of their pain. Therapeutic CFJ injections showed increased CROM, increased mean reduction in NRS, and decreased incidence of combined tension-type headache for long-standing MPS with referral pain patterns of CFJ syndrome across all age groups. The young age group that received therapeutic CFJ injections required a shorter treatment course and experienced a longer symptom-free period during the 1-year follow-up period.

## References

- Gerwin RD. Classification, epidemiology, and natural history of myofascial pain syndrome. *Curr Pain Headache Rep.* 2001;5: 412–20.
- Jaeger B. Overview of head and neck region. In: Travell JG, Simons DG, editors. *Myofascial pain and dysfunction. The trigger point manual.* 2nd ed. Baltimore: Williams & Wilkins; 1999. p. 237–77.
- Dwyer A, Aprill C, Bogduk N. Cervical zygapophyseal joint pain patterns. I: a study in normal volunteers. *Spine.* 1990;15:453–7.
- Manchikanti L, Boswell MV, Singh V, Pampati V, Damron KS, Beyer CD. Prevalence of facet joint pain in chronic spinal pain of

- cervical, thoracic, and lumbar regions. *BMC Musculoskeletal Disord.* 2004;5:15.
5. Falco FJ, Erhart S, Wargo BW, Bryce DA, Atluri S, Datta S, Hayek SM. Systematic review of diagnostic utility and therapeutic effectiveness of cervical facet joint interventions. *Pain Phys.* 2009;12:323–44.
  6. Kettler A, Werner K, Wilke HJ. Morphological changes of cervical facet joints in elderly individuals. *Eur Spine J.* 2007;16:987–92.
  7. Merskey H, Bogduk N. Classification of chronic pain. Descriptions of chronic pain syndromes and definitions of pain terms. Prepared by the International Association for the Study of Pain, Subcommittee on Taxonomy. *Pain.* 1986;3:S1–226.
  8. Manchikanti L, Singh V, Falco FJ, Cash KM, Fellows B. Cervical medial branch blocks for chronic cervical facet joint pain: a randomized, double-blind, controlled trial with one-year follow-up. *Spine.* 2008;33:1813–20.
  9. Kim KH, Choi SH, Kim TK, Shin SW, Kim CH, Kim JI. Cervical facet joint injections in the neck and shoulder pain. *J Korean Med Sci.* 2005;20:659–62.
  10. Fukui S, Ohseto K, Shiotani M, Ohno K, Karasawa H, Naganuma Y, Yuda Y. Referred pain distribution of the cervical zygapophyseal joints and cervical dorsal rami. *Pain.* 1996;68:79–83.
  11. Harden RN, Cottrill J, Gagnon CM, Smitherman TA, Weiland SR, Tann B, Joseph P, Lee TS, Houle TT. Botulinum toxin a in the treatment of chronic tension-type headache with cervical myofascial trigger points: a randomized, double-blind, placebo-controlled pilot study. *Headache.* 2009;49:732–43.
  12. Kallakuri S, Singh A, Chen C, Cavanaugh JM. Demonstration of substance P, calcitonin gene-related peptide, and protein gene product 9.5 containing nerve fibers in human cervical facet joint capsules. *Spine.* 2004;29:1182–6.