

Skin-traction method prevents the collapse of the internal jugular vein caused by an ultrasound probe in real-time ultrasound-assisted guidance

HIROSHI SASANO, MASATO MORITA, TAKAFUMI AZAMI, SHOJI ITO, NOBUKO SASANO, RINA KATO, HIROYUKI HIRATE, HIROAKI ITO, AKINORI TAKEUCHI, and KAZUYA SOBUE

Department of Anesthesiology and Medical Crisis Management, Nagoya City University Graduate School of Medical Sciences, 1 Kawasumi, Mizuho-cho, Mizuho-ku, Nagoya 467-8622, Japan

Abstract

Purpose. Real-time ultrasound-assisted guidance for catheterization of the internal jugular vein (IJV) is known to be useful, especially for a small-sized vein, which is difficult to catheterize. However, one of the problems with real-time ultrasound-assisted guidance is that the ultrasound probe itself can collapse the vein. We have developed a novel “skin-traction method (STM)”, in which the puncture point of the skin over the IJV is stretched upwards with several pieces of surgical tape in the cephalad and caudal directions with the aim being to facilitate catheterization of the IJV. We examined whether this method increased the compressive force required to collapse the IJV.

Methods. In ten volunteers, the compressive force required to collapse the right IJV, and the cross-sectional area and anteroposterior and transverse diameters of the IJV were measured with ultrasound imaging in the supine position (SP) with or without the STM or in the Trendelenburg position of 10° head-down (TP) without the STM.

Results. The compressive force to required to collapse the vein was increased significantly with the STM, while the cross-sectional area and anteroposterior diameter of the vein in the SP with STM were similar to those in the TP without the STM.

Conclusion. With the STM, not only the cross-sectional area but also the compressive force required to collapse the IJV increased. Thus, the STM may facilitate real-time ultrasound-assisted guidance for catheterization of the IJV by maintaining the cross-sectional area of the vein during the guidance.

Key words Skin-traction method · Internal jugular vein · Compressive force

Introduction

Real-time ultrasound-assisted guidance for catheterization of the internal jugular vein (IJV) is known to be

useful, especially for a small-sized vein [1,2], which is difficult to catheterize. One of the problems with real-time guidance is that the ultrasound probe itself can collapse the vein, and meticulous handling of the probe is thus needed for successful puncture [3].

We have developed a novel “skin-traction method (STM)”, in which the puncture point of the skin over the IJV is stretched upwards with several pieces of surgical tape in the cephalad and caudal directions with aim of facilitating catheterization of the IJV. We previously reported that the cross-sectional area and anteroposterior diameter of the IJV increased with the STM [4]. We have observed that the collapse of the IJV by external forces, produced with the ultrasound probe or advancement of the needle, is prevented with the STM, and thus we speculated that the STM may facilitate real-time ultrasound-assisted guidance, not only by enlarging the vein size but also by preventing the vein from collapsing during catheterization.

The purpose of this study was to examine how the STM increased the compressive force required to be produced by the ultrasound probe to collapse the IJV in real-time guidance.

Subjects, materials, and methods

Ten healthy male volunteers were enrolled in this study. The research protocol was reviewed and approved by the Ethics Committee of our university, and informed consent was obtained from each subject. The subjects' mean age was 36.2 years (range, 26–49 years). Body weight ranged from 62 to 82 kg, with a mean weight of 71.4 kg. Height ranged from 169 to 180 cm, with a mean height of 174 cm.

The subjects had no previous history of IJV catheterization or diseases of the neck. In each subject, the head was rotated about 30° to the left while keeping the neck flat. A head ring was set under each subject's head, and

Address correspondence to: H. Sasano

Received: August 7, 2008 / Accepted: October 1, 2008

the head was positioned so as to retain the angle made by two lines—that between the center of the clavicle and the assumptive puncture point, and that between the mandibular angle and the assumptive puncture point. The angle was about 135° , which makes it easy to lift up the skin around the assumptive puncture point with the STM. Then the skin over the right IJV (RIJV) was stretched with several pieces of 5-cm-wide surgical tape (Transpore surgical tape; 3M Health Care, St. Paul, MN, USA; or NICHIBAN H50; NICHIBAN, Tokyo, Japan) in the cephalad and caudal directions. The skin cephalic to the RIJV was stretched cephalad, while the skin caudal to the RIJV was stretched caudal. Three or four pieces of tape were used in each direction. The other ends of the tape were firmly stuck to the metal edge of the operating table. The stretch with the STM was confirmed by both a circle drawn on the skin over the RIJV stretched around 1.5 times in the cephalad and caudal directions, and the skin lifted upward (Fig. 1).

In three conditions, the supine position without the STM (SP), the Trendelenburg position of 10° head-down without the STM (TP), and the supine position with the STM (SP with STM), the compressive force required to collapse the RIJV was measured as follows. Subjects were given the three conditions in random order. While manual compressive force was applied with the head of a spring-type pressure gauge (Force gauge KM 1; Imoto Seisakusho, Kyoto, Japan) placed perpendicularly on the skin surface at the assumptive puncture point, collapse of the RIJV under the force gauge was observed on two-dimensional ultrasound imaging (iLOOK25; SonoSite, Bothell, WA, USA) obtained with an ultrasound probe placed at the cephalad side of the force gauge (Fig. 2). The assumptive puncture point was the lesser supraclavicular fossa at the level of the cricoid cartilage. The head of the force gauge used to press the skin is a round shape 1 cm in diameter. Measurements were repeated three times for

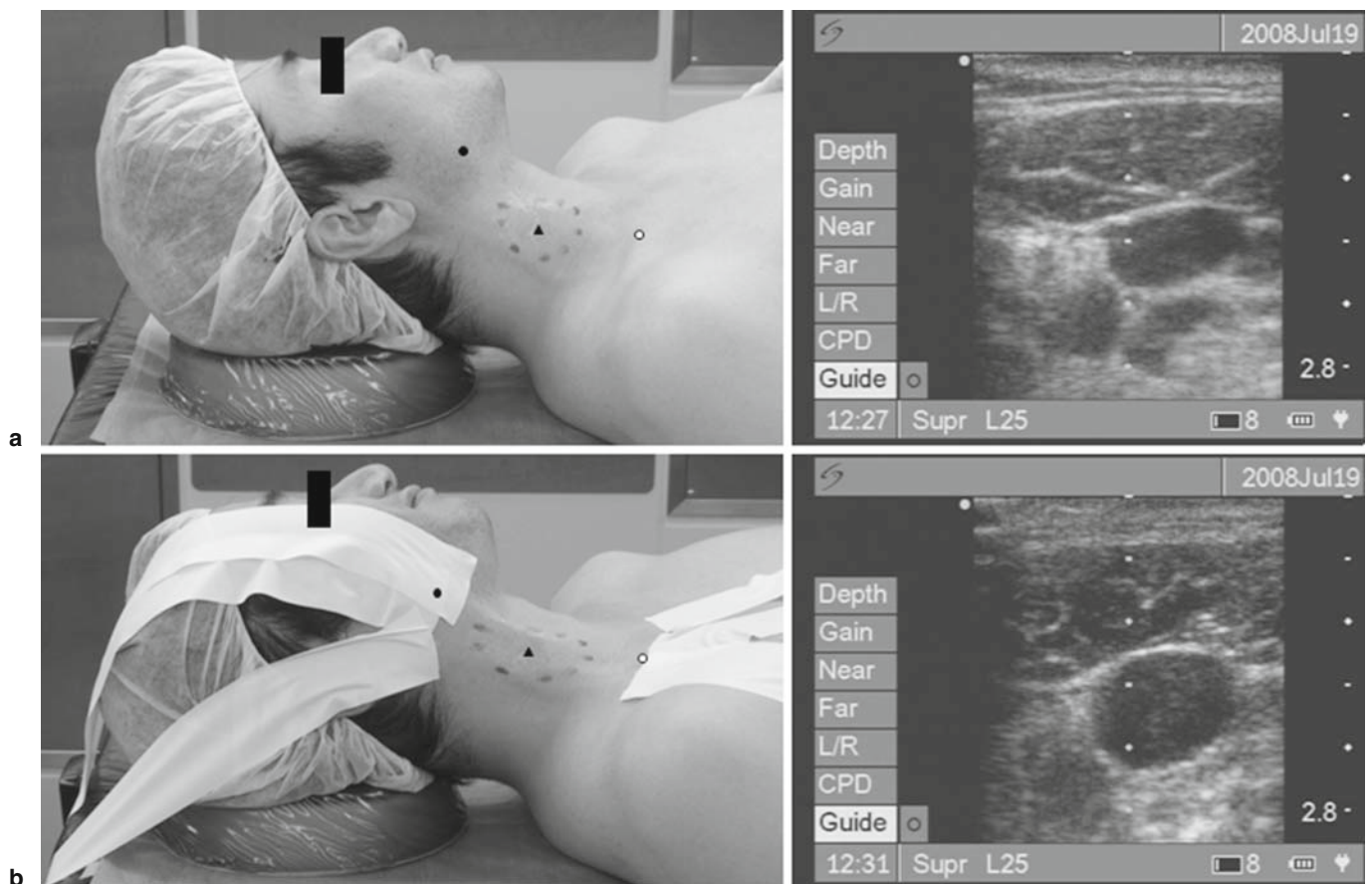


Fig. 1a,b. Differences in the surface of the neck and cross-sectional area of the right interior jugular vein (RIJV) without (a) and with (b) the skin-traction method (STM). The skin over the RIJV is stretched upward, and the assumptive puncture point (black triangle) is lifted up by the STM (b left). The

angle made by two lines—that between the center of the clavicle (open circle) and the puncture point, and that between the mandibular angle (black dot) and the puncture point—was kept at about 135° without the STM. L/R, Left/right flip; CPD, color power doppler; Supr, superficial

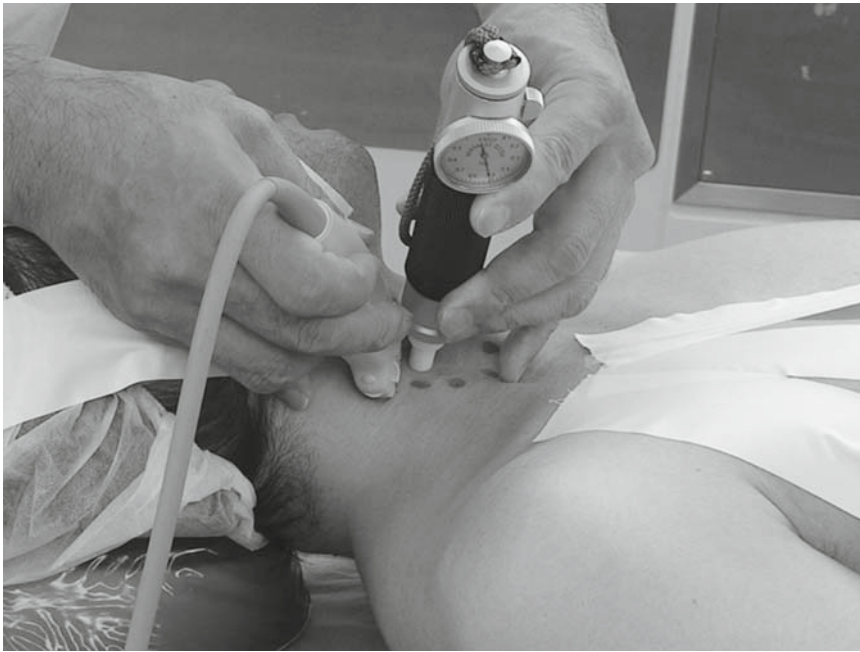

Fig. 2. Measurement of the compressive force required to collapse the right internal jugular vein (RIJV). While manual compression was applied with the head of a spring-type force gauge placed perpendicularly on the skin surface at the assumptive puncture point, collapse of the RIJV under the force gauge was observed in an ultrasound image obtained with an ultrasound probe placed at the cephalad side of the force gauge

Table 1. The compressive force required to collapse the right internal jugular vein (RIJV) and anatomical measurements of the RIJV in three conditions

	SP	TP	SP with the STM
Compressive force required to collapse RIJV (N)	0.11 ± 0.03	0.15 ± 0.03	0.51 ± 0.12*****
Cross-sectional area of the RIJV (cm ²)	0.82 ± 0.33	1.19 ± 0.43**	1.23 ± 0.46**
Anteroposterior diameter of the RIJV (cm)	0.84 ± 0.17	1.04 ± 0.21**	1.17 ± 0.22**
Transverse diameter of the RIJV (cm)	1.25 ± 0.25	1.47 ± 0.31*	1.43 ± 0.24*

* $P < 0.05$ (vs SP); ** $P < 0.01$ (vs SP); *** $P < 0.01$ (vs TP)

TP, Trendelenburg position of 10° head-down; SP, supine position; SP with the STM, supine position with the skin-traction method

each condition, and the average value for each condition was calculated.

The cross-sectional areas and anteroposterior and transverse diameters of the RIJV at the assumptive puncture point were also measured. A ultrasound probe (L25/10-5 MHz; Sonosite) was placed perpendicularly on the skin surface of the neck in order to observe the cross-sectional image of the RIJV. The images were recorded on a videotape recorder and transferred to a computer, where the recorded images of the RIJV at the endexpiratory phase of spontaneous respiration were measured using ImageJ (Image Processing and Analysis in Java) version 1.34 (<http://rsb.info.nih.gov/ij/>) [5].

One-way repeated-measures analysis of variance (ANOVA), followed by multiple comparisons with the Bonferroni correction, was used to evaluate the effects of the STM or position on variables. Data values are presented as means ± SD. A P value of less than 0.05 was considered to indicate significance.

Results

With the STM, the compressive force required to collapse the RIJV increased from 0.11 ± 0.03 N to 0.51 ± 0.12 N (4.5 times; $P < 0.01$) in the SP, while the force did not increase in the TP without the STM. The cross-sectional area, anteroposterior diameter, and transverse diameter of the RIJV in the SP with the STM and in the TP without the STM were greater than that in the SP without the STM ($P < 0.01$, $P < 0.01$, and $P < 0.05$, respectively; Table 1).

Discussion

In this study, we showed that the compressive force required to collapse the internal jugular vein (IJV) with the STM was increased 4.5 times in the supine position (SP), while the force without the STM did not increase in the TP. On the other hand, the cross-sectional area,

anteroposterior diameter, and transverse diameter of the IJV with the STM in the SP were greater than that without the STM in the SP, and similar to that without the STM in the TP.

Many reports and guides have demonstrated the usefulness of ultrasound imaging for guidance in IJV catheterization [6–10]. Recently, real-time ultrasound-assisted guidance for catheterization of the IJV has been found to be useful, especially for the difficult case of a small-sized vein [1,2]. One of the problems with real-time ultrasound-assisted guidance is that the vein can be collapsed unintentionally by the ultrasound probe itself. Striking a balance between fine contact of the probe on the skin for clear ultrasonography and preventing the vein from being collapsed by the probe demands meticulous handling of the probe [3].

Previously we reported that an STM [4], in which the puncture point of the skin over the IJV is stretched upwards with several pieces of surgical tape in the cephalad and caudal directions, had the advantage of enlarging the cross-sectional area of the IJV. The result of increasing the cross-sectional area and diameter of the IJV with the STM in the present study is the same as that reported by us previously. An increase in the compressive force required to collapse the RIJV by the ultrasound probe, which was mimicked by the force gauge in the present study, may be another advantage of the STM. The increased compressive force may maintain the cross-sectional area of the vein during real-time ultrasound-assisted guidance even without meticulous handling of the ultrasound probe, and thus may facilitate IJV catheterization in real-time guidance.

In real-time guidance, advancing the needle has also been observed to collapse the vein [11]. Because the mechanism of increasing the compressive force required to collapse the IJV and to increase the cross-sectional area and anteroposterior diameter of the IJV with the STM seems to involve lifting the skin over the IJV and then stretching the IJV mainly in an anteroposterior direction, logically, the STM should also be effective for preventing the vein from collapsing by the advancing of the needle. Having several advantages produced by extravascular negative force to enlarge the IJV, the STM may be a tool that allows the operator to use the real-time guidance easily. Further study is needed before an appropriate conclusion can be reached.

Several reports have shown the effect of neck extension on the diameter of the IJV. Armstrong et al. [12] demonstrated a marked reduction in the diameter of the IJV when a bolster was placed under the shoulders, and Parry [13] showed that a small pillow or head ring placed under the head enlarged the diameter of the IJV. These reports seem to indicate that a flat position of the neck enlarges the diameter of the IJV, while overextension of the neck reduces it. We consider that the flat position

of the neck is useful even with the STM, and thus we prevented overextension of the neck by placing a head ring under the head while the skin over the IJV was stretched with the STM.

The mechanism underlying our finding that both the compressive force required to collapse the IJV and the cross-sectional area of the vein increased in the SP with the STM, while only the cross-sectional area of the vein increased in the TP without the STM is explained as follows: with the STM, the compressive force on the skin surface at the assumptive puncture point does not compress the IJV directly but spreads on the clavicle or the mandibular bone, which the tape of the STM is attached to, while in the TP without the STM, the compressive force almost directly compresses the IJV via unstretched skin. Thus, the compressive force with the STM is not as effective in collapsing the IJV as that without the STM. In other words, the skin that is stretched and lifted up with the STM works as an impact absorber to prevent the IJV from collapsing by compressive force.

One of the limitations of our study is that we used healthy volunteers rather than subjects of greater interest, such as hypovolemic patients or pediatric patients. In these patients of greater interest, however, the STM, logically, could have a similar effect on the compressive force. Further study on this is also needed.

In conclusion, the increases in the compressive force required to collapse the RIJV with the STM may maintain the cross-sectional area of the vein during real-time ultrasound-assisted guidance and thus facilitate IJV catheterization.

References

1. Hosokawa K, Shime N, Kato Y, Hashimoto S. A Randomized trial of ultrasound image-based skin surface marking versus real-time ultrasound-guided internal jugular vein catheterization in infants. *Anesthesiology*. 2007;107:720–4.
2. Milling TJ Jr, Rose J, Briggs WM, Birkhahn R, Gaeta TJ, Bove JJ, Melniker LA. Randomized, controlled clinical trial of point-of-care limited ultrasonography assistance of central venous cannulation: the Third Sonography Outcomes Assessment Program (SOAP-3) Trial. *Crit Care Med*. 2005;33:1764–9.
3. Ganesh A, Jobes DR. Ultrasound-guided catheterization of the internal jugular vein. *Anesthesiology*. 2008;108:1155–7.
4. Morita M, Sasano H, Azami T, Sasano N, Katsuya H. The skin-traction method increases the cross-sectional area of the internal jugular vein by increasing its anteroposterior diameter. *J Anesth*. 2007;21:467–71.
5. Image J. Image processing and analysis in Java. <http://rsb.info.nih.gov/ij/>
6. Gordon AC, Saliken JC, Johns D, Owen R, Gray RR. US-guided puncture of the internal jugular vein: complications and anatomic considerations. *J Vasc Interv Radiol*. 1998;9:333–8.
7. Alderson, PJ, Burrows FA, Stemp LI, Holtby HM. Use of ultrasound to evaluate internal jugular vein anatomy and to facilitate central venous cannulation in paediatric patients. *Br J Anaesth*. 1993;70:145–8.

8. Hayashi Y, Uchida O, Takaki O, Ohnishi Y, Nakajima T, Kataoka H, Kuro M. Internal jugular vein catheterization in infants undergoing cardiovascular surgery: an analysis of the factors influencing successful catheterization. *Anesth Analg*. 1992;74:688–93.
9. Ultrasound guidance of central vein catheterization. Making health care safer: a critical analysis of patient safety practices. In: Rothschild JM, editor. Evidence report/technology assessment, no. 43. Rockville, MD: Agency for Healthcare Research and Quality, publication no. 01-E058. 2001. p. 245–53.
10. Guidance on the use of ultrasound locating devices for placing central venous catheters. National Institute for Clinical Excellence. Technology appraisal no. 49. Issue date: September 2002. http://www.nice.org.uk/nicemedia/pdf/Ultrasound_49_GUIDANCE.pdf (accessed July 2008).
11. Mallory DL, Shawker T, Evans RG, McGee WT, Brenner M, Parker M, Morrison G, Mohler P, Veremakis C, Parrillo JE. Effects of clinical maneuvers on sonographically determined internal jugular vein size during venous cannulation. *Crit Care Med*. 1990;18:1269–73.
12. Armstrong PJ, Sutherland R, Scott DH. The effect of position and different manoeuvres on internal jugular vein diameter size. *Acta Anaesthesiol Scand*. 1994;38:229–31.
13. Parry G. Trendelenburg position, head elevation and a midline position optimize right internal jugular vein diameter. *Can J Anaesth*. 2004;51:379–81.