

Erratum to: Clinical effectiveness of bipolar radiofrequency ablation for small liver cancers

Yukio Osaki · Kenji Ikeda · Namiki Izumi ·
Satoyoshi Yamashita · Hiromitsu Kumada ·
Shinji Hatta · Kiwamu Okita

Published online: 31 August 2013
© Springer Japan 2013

Erratum to: J Gastroenterol (2013) 48:874–883
DOI 10.1007/s00535-012-0685-x

Please note that there are errors in this article:

The first sentence in the legend for Fig. 2 appeared incorrectly. The sentence should read as follows:

Fig. 2 Differences in the electrical flow routes of **a** the bipolar (CelonPOWER System) and **b** the monopolar radiofrequency ablation (RFA) systems.

In Fig. 4, in the next-to-last step on the right side of the flowchart, the correct number of weeks in the follow-up period should be 24, not 20. The correct figure should be shown as follows:

The online version of the original article can be found under
doi:[10.1007/s00535-012-0685-x](https://doi.org/10.1007/s00535-012-0685-x).

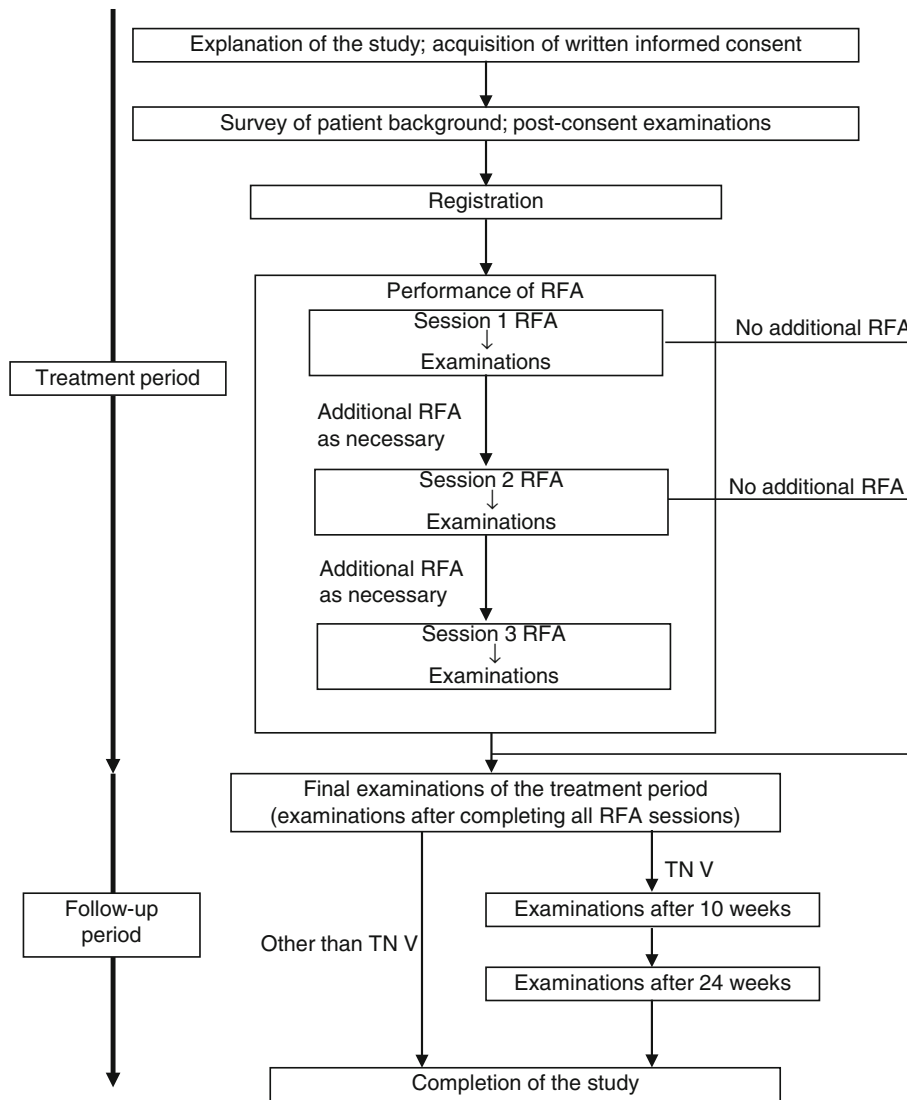
Y. Osaki
Department of Gastroenterology and Hepatology,
Osaka Red Cross Hospital, Osaka, Japan

K. Ikeda · H. Kumada
Department of Hepatology, Toranomon Hospital, Tokyo, Japan

N. Izumi
Division of Gastroenterology and Hepatology,
Musashino Red Cross Hospital, Tokyo, Japan

S. Yamashita · K. Okita (✉)
Department of Hepatology, Center for Liver Disease,
Social Insurance Alliance Shimonoseki Kohsei Hospital,
Kami-Shinchi Cho 3-3-8, Shimonoseki,
Yamaguchi 750-0061, Japan
e-mail: k.okita@kousei-h.jp; k.okita@www.kousei-h.jp

S. Hatta
Olympus Medical Systems Corp, Tokyo, Japan



In addition, in the legend for Table 3, the symbol “>” was incorrect; it should have been “≥”. The correct legend should be shown as follows:

Table 3 Frequently observed adverse effects (5 % or more) (adverse reactions at an incidence of ≥ 5 % in the overall study period).