

Basic knowledge of interest

History of pancreaticojejunostomy in pancreaticoduodenectomy: development of a more reliable anastomosis technique

AKIRA KAKITA, MUNEKI YOSHIDA, and TSUYOSHI TAKAHASHI

Department of Surgery, Kitasato University School of Medicine, 1-15-1 Kitasato, Sagamihara, Kanagawa 228-8520, Japan

Abstract The history of pancreaticojejunostomy in pancreaticoduodenectomy is described. Many types of operations have been devised in search of a more reliable method of anastomosis. To perform a safe and reliable pancreaticoenteric anastomosis it is necessary to understand the organ characteristics of the pancreas. We investigated factors required for a reliable pancreaticojejunostomy and devised a new surgical technique that meets those requirements. We introduce the theoretical substantiation and clinical usefulness of our new surgical technique while reviewing the history of pancreaticojejunostomy after pancreaticoduodenectomy. The unique aspect of our method is approximation of the pancreas stump and jejunal wall by six to eight interrupted sutures. It is speculated that too many sutures and tying too tight in the anastomosis may cause ischemia and necrosis of the pancreatic stump by restricting the tissue blood flow. Our method allows us not only to reduce the number of sutures, but also to avoid some of the complicated manipulations done in any other existing methods. The newly devised pancreaticojejunostomy is an excellent surgical technique with anastomotic failure seen in only two patients and no deaths out of 162 consecutive patients.

Key words Pancreatic carcinoma · Pancreaticoduodenectomy · Pancreaticojejunostomy · Approximation of the pancreas and jejunum

Introduction

About 57 years have passed since Cattell and Whipple,¹ in 1943, introduced a pancreaticoenteric anastomosis for reconstruction in pancreaticoduodenectomy. The history of pancreatic surgery, in particular, pancreaticojejunostomy, has always involved a struggle against complications.² Among the complications of the pancreaticojejunostomy, anastomotic failure is some-

times fatal. To prevent this failure, many types of operations have been devised in the search for a more reliable method of anastomosis. With improvements in surgical materials and postoperative management, pancreaticojejunostomy has recently come to be performed more reliably than before. In reality, however, it can be performed only by extremely skilled hands in most centers, and a certain fixed rate of complications is considered unavoidable (Table 1).³⁻⁷ As such, further improvements in the type of operation are still needed.

We investigated factors required for a reliable pancreaticojejunostomy and devised a new surgical technique that meets these requirements.⁸ We have been using this technique, which can be performed very reliably with few complications, in clinical practice since 1990. In this article, we introduce the theoretical underpinning and clinical usefulness of our new surgical technique, while looking back on the history of pancreaticojejunostomy after pancreaticoduodenectomy. We also review the background and characteristics of the main types of pancreaticojejunostomies currently in common use.

History of pancreaticojejunostomy in pancreaticoduodenectomy

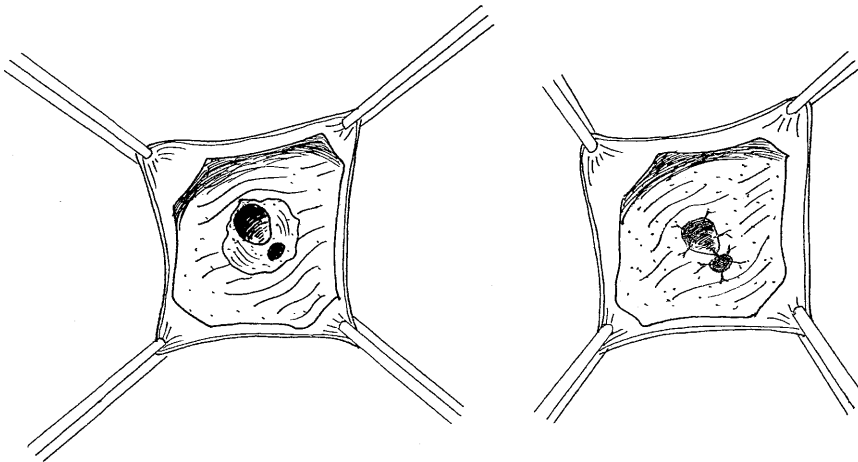
Attempts to partially excise the pancreas and duodenum were started about 102 years ago. It is Codivilla (1898) who has been credited by many authors as the pioneer of that procedure.⁹ For patients with carcinoma of the head of the pancreas, he performed partial resection of the head of the pancreas, pylorus ring, and duodenum. The common bile duct was dissected at the upper margin of the pancreas and the stump was sutured. Cholecystojejunostomy and gastrojejunostomy were performed for reconstruction, but the cut surface of the pancreas was closed only by suture, and pancreaticoenteric anastomosis was not performed.

Offprint requests to: A. Kakita

Received: July 14, 2000 / Accepted: December 22, 2000

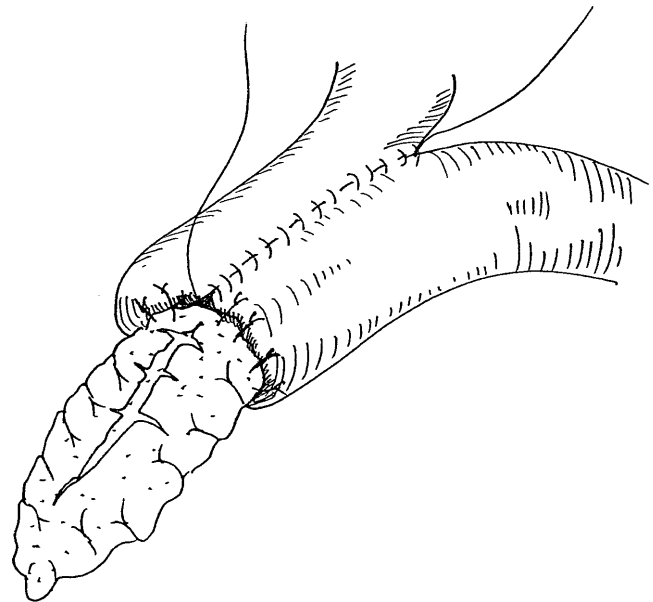
Table 1. Pancreatic anastomotic leak in pancreaticoduodenectomy reported in recent years

Author	Incidence (%)	No. of patients	Country (Year)
Cullen et al. ³	17.6	66/375	United States (1994)
Howard ⁴	3.3	5/152	United States (1997)
Chew and Attiyeh ⁵	3.4	1/29	United States (1997)
Yeo et al. ⁶	14.0	91/650	United States (1997)
Carrabetta et al. ⁷	22.1	33/149	Italy (1998)

**Fig. 1.** Transduodenal cautery excision of carcinoma of the ampulla by Halsted (1899).¹⁰ The common bile duct and pancreatic duct were reimplanted into the posterior wall of the duodenum

In 1899, Halsted¹⁰ excised periampullary pancreatic tissues transduodenally, with partial resection of the duodenal wall, in a 60-year-old woman with carcinoma of the ampulla. The common bile duct and the pancreatic duct were reimplanted into the posterior wall of the duodenum (Fig. 1). The patient survived for 7 months after surgery without any major postoperative complications. Since the performance of this successful surgery by Halsted, transduodenal resection of the pancreas for carcinoma of the ampulla has been performed by many surgeons,¹¹ including Riedel (1899), Mayo (1900), Mayo-Robson (1900),¹² Czerny (1901), and Koerte (1904). However, pancreaticoduodenectomy for carcinoma of the head of the pancreas, as performed by Codivilla,¹³ was not widely used.

In 1907, Desjardins¹⁴ performed a complete pancreaticoduodenectomy in a human cadaver. The head of the pancreas and second portion of the duodenum were resected, and the raised jejunum was anastomosed with the common bile duct and the pancreatic duct. He devised a technique in which the Button of Boari was used to bridge the pancreatic duct and the jejunal wall in the anastomosis of the pancreatic duct and the jejunum. In 1909, Coffey¹⁵ conducted a study in human cadavers and dogs, and advocated a technique for pancreaticoenteric anastomosis in which a jejunal loop was made and the pancreatic stump was implanted into the jejunal loop (Fig. 2).

**Fig. 2.** Coffey's (1909)¹⁵ pancreaticojejunostomy. A jejunal loop was made and the pancreatic stump was implanted into the jejunal loop

Despite such basic research on pancreaticoenteric anastomosis, pancreaticoenteric anastomosis was not applied immediately to clinical practice. In 1912, Kausch¹⁶ performed a partial pancreaticoduodenectomy, utilizing a two-stage operation, in a 49-year-old

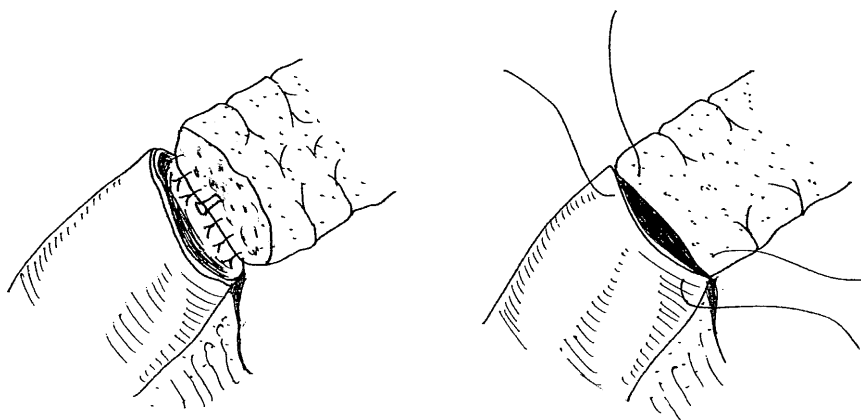


Fig. 3. End-to-end pancreaticojejunostomy by Child (1941).²⁰ The pancreatic stump is invaginated into the jejunal stump

man with carcinoma of the ampulla of Vater, and implanted the pancreatic stump into the duodenal stump. In the partial pancreaticoduodenectomies reported thereafter by Hirschel (1914)¹⁷ and Tenani (1922),¹⁸ however, the cut surface of the pancreas was closed with sutures, and pancreaticoenteric anastomosis was not employed.

In 1935, Whipple, Parsons, and Mullins¹⁹ reported the results of their three patients with a pancreaticoduodenectomy.¹⁹ This operation consisted of resection of the second and third portions of the duodenum, along with a wedge of pancreatic tissue surrounding the tumor. Their first patient had carcinoma of the ampulla of Vater with obstructive jaundice, and underwent a two-stage operation. Cholecystojejunostomy and gastrojejunostomy were performed as the first operation, and, 2 weeks later, pancreaticoduodenectomy was performed as the second operation. The cut surface of the pancreas was then closed with sutures. No pancreaticoenteric anastomosis was performed, the reasons given being that: (1) when the pancreas is anastomosed with the intestinal tract, pancreatic enzyme is activated, which is sure to cause an anastomotic failure; (2) one can live without pancreatic juice; and (3) even when an anastomosis is made, it is obstructed sooner or later.

In 1943, however, Cattell¹ stated that pancreaticoenteric anastomosis was indispensable, maintaining that the leakage of pancreatic juice accounted for many postoperative complications and deaths in patients with pancreaticoduodenectomy. That is, he proposed that the leakage should be prevented by performing pancreaticoenteric anastomosis, because ligation of the main pancreatic duct caused pancreatic juice to leak from the cut surface of the pancreas. For prevention of the leakage of pancreatic juice, Child,²⁰ in 1941, had already attempted to invaginate the pancreatic stump into the jejunal stump (Fig. 3). Cattell¹ recommended a direct anastomosis of the pancreatic duct and the jejunum in patients in whom the main pancreatic duct had a sufficient diameter. If the pancreatic duct was

small in diameter, he recommended the use of a “necrosing suture”, whereby the pancreatic duct was ligated and the cut surface of the pancreas was covered with the jejunal wall (Fig. 4).

In 1946, Whipple²¹ also introduced pancreaticojejunostomy, and completed the one-stage reconstruction that is, today, called Whipple’s method. The pancreaticojejunostomy then used was a method in which a short rubber tube inserted into the pancreatic duct was placed into the jejunal wall, fixing the pancreatic parenchyma to the jejunum by ligation. This is almost the same as the pancreaticojejunostomy, using a tube, reported by Varco²² in 1945 (Fig. 5), and it may correspond to the tube pancreaticojejunostomy and pancreatic juice drainage by a pancreatic tube as used today. Many types of operations have been devised since that time, although most of them are variations of the ideas of Whipple, Child, and Cattell.

Pancreaticojejunostomies currently in use and their characteristics

Pancreaticoenteric anastomoses currently in wide use employ combinations of various surgical techniques, depending on the site of anastomosis, the direction of anastomosis, and method of suturing. Generally, however, the types of pancreaticoenteric anastomoses can be divided into the end-to-end anastomosis (so-called invaginating end-to-end pancreaticojejunostomy) and the end-to-side anastomosis, when viewed from the direction of the anastomosis of the pancreas and intestinal tract.

The methods of suturing used in most types of operation are the one-layer suture, in which the pancreatic parenchyma and the intestinal wall are sutured around the cut surface of the pancreas; or the two-layer suture, in which the pancreas and the intestinal wall are sutured a second time to cover the one-layer-suture. These types of operation are all widely recognized, but it is

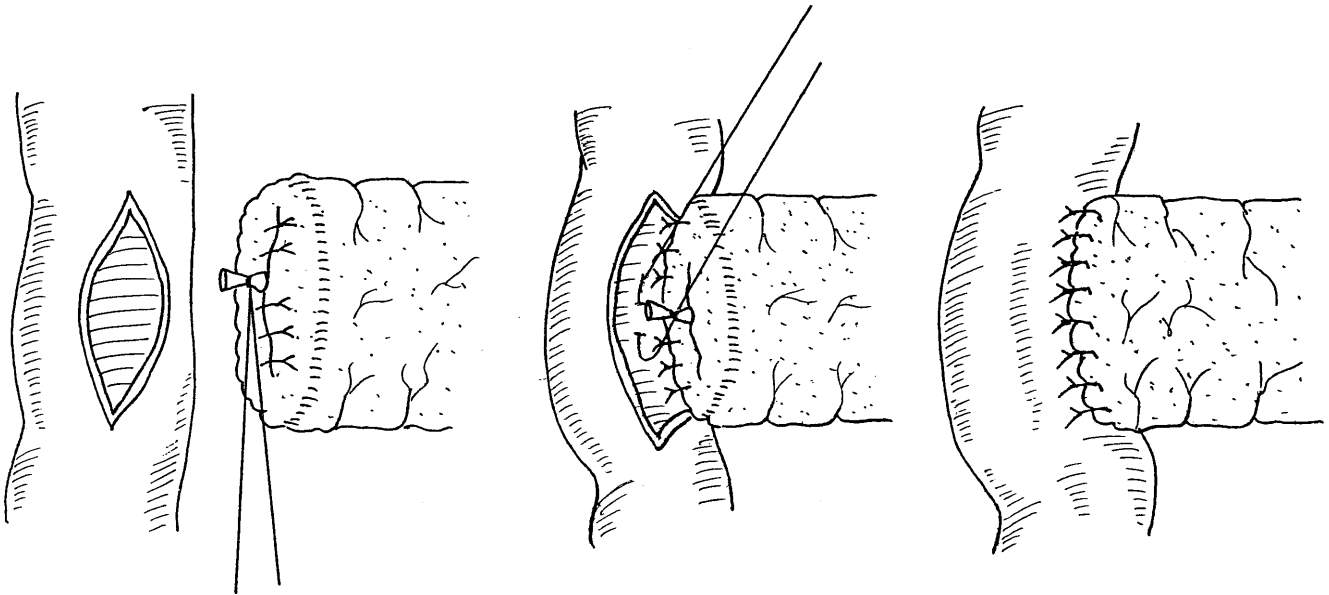


Fig. 4. In patients in whom the pancreatic duct was small in diameter, Cattell (1943)¹ recommended the use of a “necrosing suture”. The pancreatic duct was ligated and the cut surface of the pancreas was covered with the jejunal wall

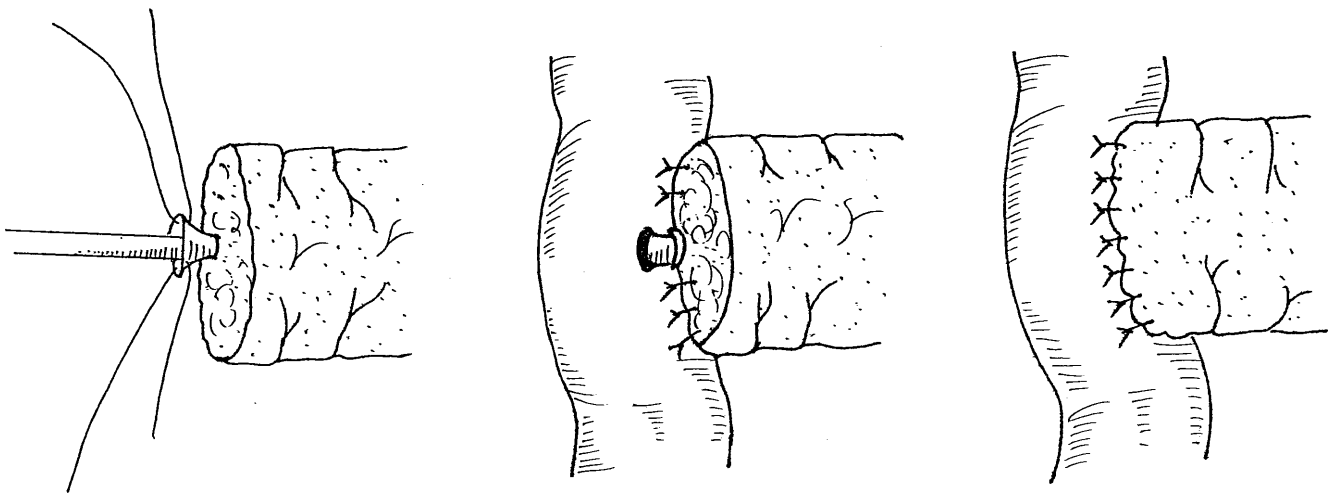


Fig. 5. Varco (1945)²³ implanted the pancreatic duct into the jejunal wall, using a two-hole catheter

necessary to understand the advantages and disadvantages of each type of operation.

Invaginating end-to-end pancreaticojejunostomy is based on the type of operation used by Child.²⁰ This is a method whereby the pancreatic stump is introduced into the open end of the jejunum. As an advantage of this method, pancreatic juice from the main pancreatic duct and pancreatic stump is drained completely into the intestinal tract. On the other hand, the method is time-consuming, and sometimes disturbs the blood flow in the pancreatic stump, because the anterior and posterior walls of the pancreas are densely sutured in a circle. Once the anastomosis is broken, the contents of the

intestinal tract leak into the abdominal cavity, and this may sometimes cause serious problems.

In contrast, the end-to-side anastomosis is the one that was used by Cattell,²³ Cattell and Pyrtek,²⁴ and Whipple,²¹ in which the cut surface of the pancreas is covered with the wall of the small intestine to prevent the leakage of pancreatic juice. It is fundamentally different from the invaginating end-to-end pancreaticojejunostomy used by Child.²⁰ In an anastomosis between the pancreatic stump and the intestinal wall, the anterior and posterior walls of the pancreas are often sutured in a circular manner in two layers. However, the method is as time-consuming as the invaginating end-

to-end pancreaticojejunostomy, and is likely to reduce the blood flow at the cut surface of the pancreas. Moreover, it is possible that a dead space could be made between the cut surface of the pancreas and the intestinal wall, with retention of effusions from the cut surface of the pancreatic stump, leading to postoperative pancreatitis and breakdown of the pancreaticoenteric anastomosis.

In regard to the long-term patency of the pancreatic duct, Greene et al.,²⁵ in animal experiments, compared the patency rates in the invaginating end-to-end pancreaticojejunostomy with those in the end-to-side pancreaticojejunostomy with duct-to-mucosa anastomosis. They reported that, 8 weeks after surgery, the pancreatic duct had closed completely in half of the animals with the invaginating end-to-end pancreaticojejunostomy, whereas it was patent in all the animals with the duct-to-mucosa anastomosis of the end-to-side pancreaticojejunostomy. Thus, they recommended the end-to-side pancreaticojejunostomy combined with the duct-to-mucosa anastomosis.

Characteristics of the pancreas as an organ, and ideal conditions for pancreaticoenteric anastomosis

In devising a more reliable pancreaticoenteric anastomosis and in performing the operation, it is important to fully understand the characteristics of the pancreas as an organ. Yonekawa²⁶ performed pancreaticoenteric anastomoses by different methods in dogs, and experimentally studied approximation of the pancreatic stump and intestinal wall, as well as the characteristics of the pancreas. He found that: (1) the animals with complete drainage of pancreatic juice by a pancreatic tube had a lower incidence of anastomotic failure, (2) poor approximation between the pancreatic stump and the intestinal wall caused retention of effusions, and (3) when the pancreatic stump was clamped with forceps or contracted with sutures, this caused impaired circulation in the stump.

The normal pancreatic parenchyma is soft and fragile,²⁷ and if ligated tightly, the pancreas sometimes tears or the blood flow at the pancreatic stump is reduced. If the cut surface of the pancreas is treated inadequately and ductules are exposed, leakage of pancreatic juice occurs readily in such areas. Furthermore, pancreatic juice has a potent proteolytic action. Reduced blood flow in the pancreatic stump causes autolysis, and, with the leakage of pancreatic juice, disintegration of the surrounding organs occurs, which is likely to result in serious problems.²⁸

On the basis of these findings, we defined four necessary conditions for an ideal pancreaticoenteric anastomosis: (1) maintaining the blood flow in the

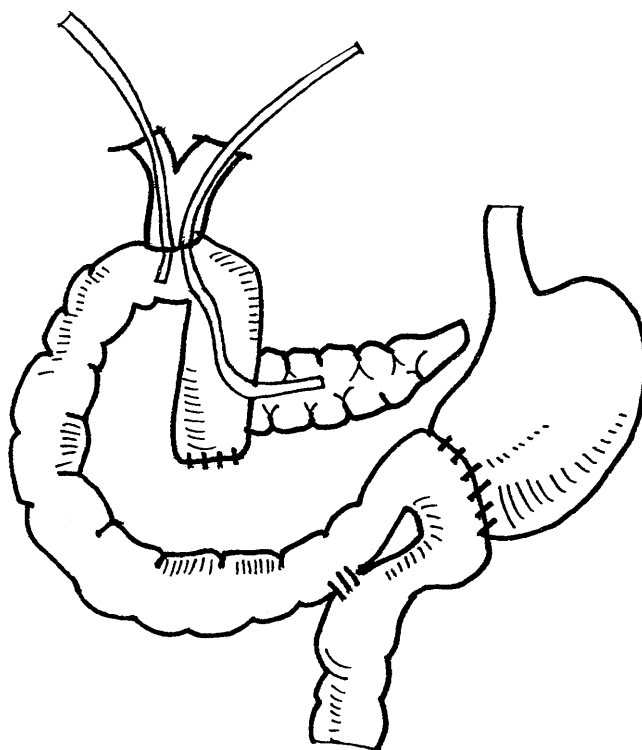


Fig. 6. Reconstruction in pancreaticoduodenectomy is basically done according to a modification of the method described by Child.²⁰ A pancreatic drainage tube is guided outside the body transhepatically via the choledochojejunal anastomosis. A retrograde transhepatic biliary drainage tube is, likewise, guided outside the body transhepatically

pancreatic stump, (2) ensuring fixation of the intestinal tract and the cut surface of the pancreas, (3) ensuring complete coverage of the cut surface of the pancreas, and (4) ensuring complete drainage of pancreatic juice.

Surgical technique of our new pancreaticojejunostomy

Reconstruction in pancreaticoduodenectomy is done according to a modification of the method described by Child²⁰ (Fig. 6). A pancreatic drainage tube inserted into the pancreatic duct is guided outside the body transhepatically via the choledochojejunal anastomosis. For drainage of bile, a retrograde transhepatic biliary drainage (RTBD) tube is, likewise, guided outside the body transhepatically.

We devised a pancreaticojejunostomy of our own that meets the above-mentioned conditions.⁸ The outline of the procedure for our pancreaticojejunal anastomosis is as follows: (1) insertion of a pancreatic tube, (2) fixation of the pancreatic duct and jejunal mucosa with sutures, and (3) approximation of the pancreas and the jejunal wall with penetrating sutures. This method is far simpler to perform than other existing methods.

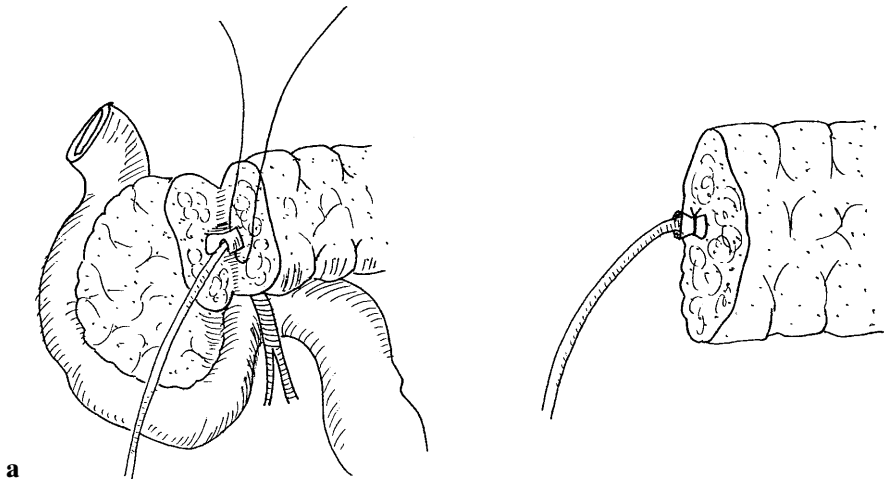


Fig. 7a,b. A more reliable technique for pancreaticoduodenectomy. **a** The first step begins with the isolation of the parenchymal duct by generously dividing the pancreatic parenchyma. **b** A pancreatic drainage tube is inserted through the incision into the pancreatic duct and tied firmly

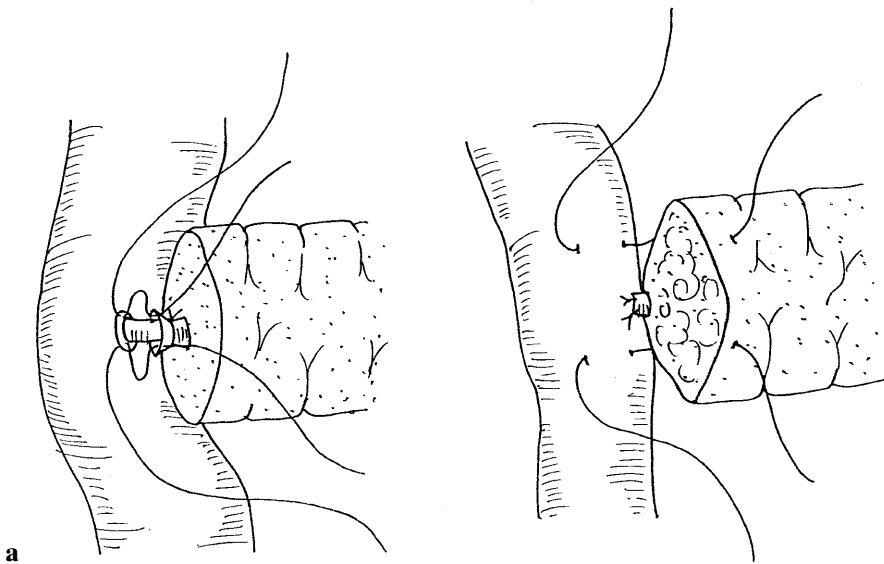


Fig. 8a,b. A more reliable technique of pancreaticoduodenectomy. **a** Direct anastomosis between the jejunal wall and the pancreatic duct is achieved with a monofilament suture. **b** Approximation of the pancreas stump and jejunal wall. The sutures are inserted onto the anterior wall of the pancreas, and are introduced straight through the pancreatic parenchyma to the posterior wall. The sutures then lift the seromuscular layer of the jejunum in the posterior-to-anterior direction

Insertion of drainage tube into the main duct of the pancreas

In dissecting the pancreas, the parenchymal tissue of the pancreas is carefully divided, little-by-little, using the back of a scalpel, until the main pancreatic duct becomes visible. The main pancreatic duct is then isolated at a sufficient distance. After a small incision is made, a commercially available drainage tube is inserted into the pancreatic duct (Fig. 7a). Then the pancreatic duct is circumferentially ligated with an absorbable tie for fixation of the pancreatic tube (Fig. 7b). The cut surface of the pancreas is not closed with sutures. Any bleeding is controlled with either electrocautery or sutures.

Fixation of pancreatic duct and jejunal mucosa with sutures

The pancreas is anastomosed to the side wall of the raised jejunum. First, a pancreatic drainage tube is

placed into the jejunal wall. Then the pancreatic duct and the jejunal mucosa are fixed with absorbable 5-0 sutures (Fig. 8a). Three to four needles are placed between the end of the pancreatic duct and the mucosa of the jejunum. The purpose of this suture is to secure the pancreatic duct being placed into the jejunal wall.

Approximation of the pancreatic stump and jejunal wall with sutures

This step is the unique aspect of this method. The stump of the pancreas and the jejunal wall are usually approximated in one layer with six to eight interrupted sutures (3-0 nonabsorbable monofilament suture). The sutures are inserted onto the anterior wall approximately 5 mm distal to the cut edge of the pancreas, and are introduced straight through the pancreatic parenchyma to the posterior wall. The sutures then lift the seromuscular layer of the jejunum, in the posterior-to-anterior

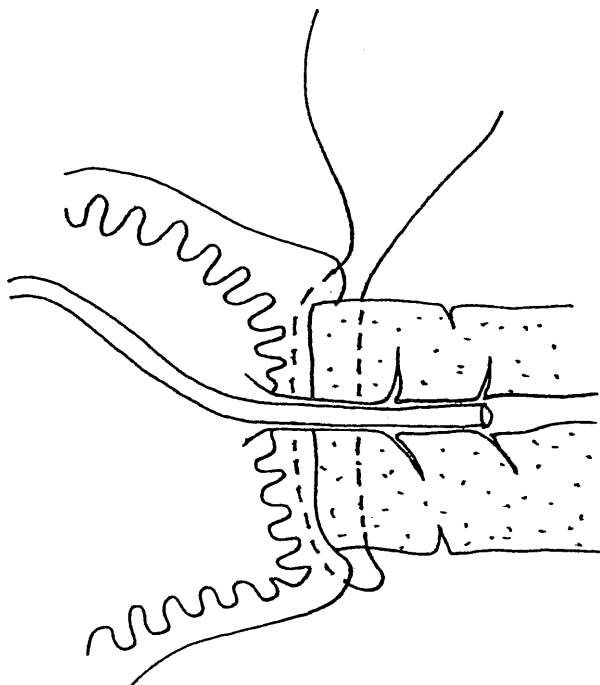


Fig. 9. A longitudinal section through the pancreatic duct shows that the jejunal wall fully covers the cut surface of the pancreas; thus, leaving no dead space between the wall and the pancreas

direction, widely enough to cover the cut surface of the pancreas (Fig. 8b). Care should be taken that the jejunal wall completely covers the edge of the cut surface of the pancreas (Fig. 9).

It is speculated that the use of too many sutures and tying them too tightly in the anastomosis may cause ischemia and necrosis of the pancreatic stump by restricting the tissue blood flow, thus leading to eventual anastomotic failure. Care should therefore be taken not to ligate the pancreaticojejunal anastomosis too tightly. Our method allows us not only to reduce the number of sutures but also to avoid some of the complicated manipulations done in any other existing methods.

Clinical observations

At our department, we have performed this new pancreaticojejunostomy in 162 consecutive patients (127 with a malignant neoplasm, and 35 with benign disease.) from 1990 to the present. Because this procedure is so simple technically, it could be mastered within a short time by any surgeon. Furthermore, it is applicable to any condition of the pancreas, from normal to chronic inflammation.

In regard to early postoperative complications, delayed gastric emptying was observed in 42 (25.9%) patients, and 5 (3.0%) patients developed marginal ulcer

after the operation. Of these 5 patients, 1 patient with ulceration on the jejunal side of the duodenojejunal anastomosis and with giant gastric ulcer required total gastrectomy.

Intra-abdominal bleeding and pancreatic fistula were also observed, in five (3.0%) and two (1.2%) patients, respectively. One patient with bleeding from the middle colic artery died of multiple organ failure after massive bleeding. Two of the four patients with bleeding from the gastroduodenal artery stump or hepatic artery survived selective embolization of the common hepatic artery. The remaining two patients died of uncontrollable bleeding and hepatic failure.

Pancreatic fistula was defined as high amylase content (more than 5000 units/l) in the fluid collected from the drain placed at the site of the pancreaticoenteric anastomosis, and/or anastomotic breakdown demonstrated radiographically. In two patients (1.2%), the drainage fluid from the peripancreatic drain showed an amylase level of more than 5000 units/l. However, no evident leakage of the pancreaticoenteric anastomosis was found radiographically, nor were there any deaths caused by complications of the pancreaticoenteric anastomosis. No serious complications related to the pancreaticoenteric anastomosis have been encountered to date.

It is likely that, in these two patients with pancreatic fistula, the cut surface of the pancreas was not sufficiently covered with the wall of the jejunum, leading to the leakage of a small amount of pancreatic juice from the ductules at the stump. Alternatively, it is possible that the blood flow in the pancreatic stump may have been restricted because of too-tight ligations, resulting in necrosis of the pancreatic tissues and the ensuing leakage of pancreatic juice. We emphasize again that covering the pancreas stump sufficiently with the intestinal wall, handling the pancreas gently and protectively, and not ligating the pancreaticojejunal anastomosis too tightly are the keys to a successful pancreaticojejunostomy.

One hundred and four patients were followed-up for more than 1 year after surgery. The median postoperative follow-up was 28 months. Pancreatic duct patency was confirmed in 44 patients by magnetic resonance cholangiopancreatography. Of the remaining 60 patients, 10 patients had dilatation of the distal pancreatic duct, with a marked decline in pancreatic exocrine and endocrine functions, while the other 50 patients have preserved these pancreatic functions.

Summary

We here describe the history of pancreaticojejunostomy in pancreaticoduodenectomy along with a newly de-

vised anastomotic technique by us. To perform a safe and reliable pancreatoenteric anastomosis, it is necessary to understand the characteristics of the pancreas as an organ. The newly devised pancreaticojejunostomy is an excellent surgical technique, with anastomotic failure seen in only 2 and no deaths of 162 consecutive patients.

References

- Cattell RB (1943) Resection of the pancreas, discussion of special problems. *Surg Clin North Am* 23:753–766
- Howard JM (1996) Historical aspects and the future of pancreatoduodenectomy. *J Hepatobiliary Pancreat Surg* 3:149–153
- Cullen JJ, Sarr MG, Ilstrup DM (1994) Pancreatic anastomotic leak after pancreaticoduodenectomy: incidence, significance, and management. *Am J Surg* 168:295–298
- Howard JM (1997) Pancreatojejunostomy: leakage is a preventable complication of the Whipple resection. *J Am Coll Surg* 184:454–457
- Chew DK, Attiyeh FF (1997) Experience with the Whipple procedure (pancreaticoduodenectomy) in a university-affiliated community hospital. *Am J Surg* 174:312–315
- Yeo CJ, Cameron JL, Sohn TA, Lilemoe KD, Pitt HA, Talamimi MA, Hruban RH, Ord SE, Sauter PK, Coleman J, Zahurak ML, Grochow LB, Abrams RA (1997) Six hundred fifty consecutive pancreaticoduodenectomies in the 1990s: pathology, complications, and outcomes. *Ann Surg* 226:248–257
- Carrabetta S, De Cian F, Mondini G, Bocchio MM, D'Ambra L, Spirito C, Lazzari I, Griffanti Bartoli F, Civalleri D (1998) Pancreatic cancer. Analysis of 149 cases in our 17-year experience. *Chir Ital* 19:265–270
- Kakita A, Takahashi T, Yoshida M, Furuta K (1996) A simpler and more reliable technique of pancreatojejunal anastomosis. *Surg Today* 26:532–535
- Whipple AO (1960) A historical sketch of the pancreas. In: Howard JM, Jordan GL Jr (eds) *Surgical disease of the pancreas*. JB Lippincott, Philadelphia, pp 1–8
- Halsted WS (1899) Contributions to the surgery of the bile passages, especially of the common bile duct. *Boston Med Surg J* 141:645–654
- Hunt VC (1941) Surgical management of carcinoma of the ampulla of Vater and of the periampullary portion of the duodenum. *Ann Surg* 114:570–602
- Mayo-Robson A (1900) La chirurgie du pancreas. XIII Internat. Congress of Med. (Paris), Section 10, Chirurgie generale, pp 140–159
- Peters JH, Carey LC (1991) Historical review of pancreaticoduodenectomy. *Am J Surg* 161:219–225
- Desjardins A (1907) Technique de la pancreatectomie. *J Rev Chir* 35:945–973
- Coffey RC (1909) Pancreato-enterostomy and pancreatectomy. A preliminary report. *Ann Surg* 50:1238–1264
- Kaush W (1912) Das Karzinom der Papilla Duodeni und seine radikale Entfernung. *Beitr klin Chir* 78:439–486
- Hirschel G (1914) Die Resektion des Duodenum mit der Papilla wegen Karzinoms. *Munch Med Wsch* 61:1728–1729
- Tenani O (1922) Contributo alla chirurgia della papilla del Vater. *Policlinico* 29:291–333
- Whipple AO, Parsons WB, Mullins CR (1935) Treatment of carcinoma of the ampulla of Vater. *Ann Surg* 102:763–779
- Child CG III (1941) Carcinoma of duodenum: one-stage radical pancreaticoduodenectomy preserving the external pancreatic secretion, case report. *Ann Surg* 118:838–842
- Whipple AO (1946) Observations on radical surgery for lesions of the pancreas. *Surg Gynecol Obstet* 82:623–631
- Varco RL (1945) A method of implanting the pancreatic duct into the jejunum in the Whipple operation for carcinoma of the pancreas. *Surgery* 32:569–573
- Cattell RB (1948) A technique for pancreaticoduodenal resection. *Surg Clin North Am* 28:753–766
- Cattell RB, Pyrttek LJ (1949) An appraisal of pancreatoduodenal resection: a follow up study of 61 cases. *Ann Surg* 129:840–849
- Greene BS, Loubeau JM, Peoples JB, Elliott DW (1991) Are pancreatoenteric anastomoses improved by duct-to-mucosa sutures? *Am J Surg* 161:45–50
- Yonekawa M (1981) A study on the healing process of pancreatico-enterostomy (in Japanese with English abstract). *Nippon Geka Gakkai Zasshi (Jpn J Surgery)* 82:1255–1267
- Matsumoto Y, Fujii H, Miura K, Inoue S, Sekikawa T, Aoyama H, Ohnishi N, Sakai K, Suda K (1992) Successful pancreatojejunal anastomosis for pancreatoduodenectomy. *Surg Gynecol Obstet* 175:555–562
- Goldsmith HS, Ghosh BC, Huvos AG (1971) Ligation versus implantation of the pancreatic duct after pancreaticoduodenectomy. *Surg Gynecol Obstet* 132:87–92