

Single-access transumbilical laparoscopic splenectomy using curved reusable instruments

Giovanni Dapri · Dominique Bron · Jacques Himpens · Lorenzo Casali · Pietro Carnevali · Pavlos Koustas · Guy-Bernard Cadière

Received: 11 December 2010 / Accepted: 10 March 2011 / Published online: 22 April 2011
© Springer Science+Business Media, LLC 2011

Abstract

Background The authors report a single-access transumbilical laparoscopic splenectomy (SATLS) performed with curved reusable instruments.

Methods A 23-year-old female consulted for steroid-resistant idiopathic thrombocytopenic purpura and clinical evidence of secondary Cushing syndrome. Preoperative workup showed a normal-sized spleen and thrombocytopenia. The umbilicus was incised and a purse-string suture was applied. A reusable 11-mm trocar was inserted for a 10-mm, 30° angled scope. Curved reusable instruments (Karl Storz-Endoskope, Tuttlingen, Germany) were advanced without trocars transumbilically. After opening the splenicocolic and gastrosplenic ligaments, the main splenic artery and vein were dissected off at the level of the hilum, clipped with 5-mm clips introduced transumbilically, and sectioned. Posterior splenic attachments were freed at the hilum cranially and caudally. The spleen was finally retrieved transumbilically in a plastic bag.

Results Addition of supplementary trocars or incisions was not necessary. Operative time was 180 min and final umbilical scar 16 mm. The patient was discharged on postoperative day 3, and after 6 months she was doing well.

Conclusions SATLS was feasible and safe to be performed using curved reusable instruments. The curves of the instruments permitted the surgeon to work in an ergonomic position, without the instruments clashing thanks to the obtained triangulation. Since only reusable instruments were used, the cost of SATLS remained similar to that of standard laparoscopy.

Keywords Single access · Single port · Single incision · Laparoscopy · Splenectomy · Idiopathic thrombocytopenic purpura

This paper was a video presentation at the Annual Meeting of the Society of American Gastrointestinal Endoscopic Surgeons (SAGES), San Antonio, TX, March 30–April 2, 2011.

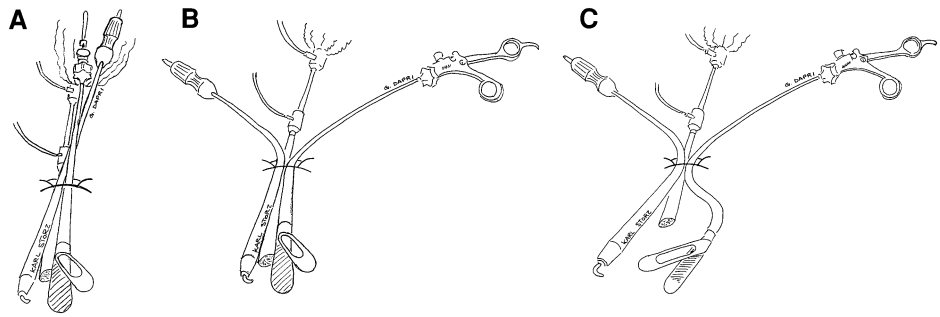
Electronic supplementary material The online version of this article (doi:10.1007/s00464-011-1678-1) contains supplementary material, which is available to authorized users.

G. Dapri (✉) · J. Himpens · L. Casali · P. Carnevali · P. Koustas · G.-B. Cadière
Department of Gastrointestinal Surgery, European School of Laparoscopic Surgery, Saint-Pierre University Hospital, 322 rue Haute, 1000 Brussels, Belgium
e-mail: giovanni@dapri.net

D. Bron
Department of Clinical and Experimental Hematology, Institut Jules Bordet, Brussels, Belgium

In recent years transumbilical single-access laparoscopy (SAL) has gained interest in the different surgical specialities because it offers the patient better cosmetic results since only an umbilical incision was used to access the abdominal cavity [1]. Advanced laparoscopic procedures like splenectomy have been proven to be feasible through SAL [2]. This procedure can be performed using straight classic instruments [3–5], but since only one incision is used, a working triangulation cannot be obtained (Fig. 1A) and there is conflict between the instruments' tips and the surgeon's hands. From this situation came the idea to develop some curved instruments in order to establish a working triangulation outside the abdomen (Fig. 1B) as well as inside (Fig. 1C), maintaining one of the rules of laparoscopy which is the optical system at the bisector of the working triangulation [6]. Another option is the use of articulating instruments [2, 7–9].

Fig. 1 The concept of the curved instruments is based on the creation by **A** the straight classic instruments of the triangulation angle both **B** outside and **C** inside the abdominal cavity



Here we report on a single-access transumbilical laparoscopic splenectomy (SATLS) using curved reusable instruments, performed on a 23-year-old female with a body mass index (BMI) of 35.7 kg/m². The patient consulted for steroid-resistant idiopathic thrombocytopenic purpura and clinical evidence of secondary Cushing syndrome. At the preoperative workup, the spleen appeared normal (15 cm) and the thrombocytopenia was confirmed.

Surgical technique

The patient was placed in a semilateral position with only the right arm alongside the body and the legs abducted. The surgeon stood between the patient's legs and the camera assistant stood to the patient's right. The umbilicus was incised and the peritoneal cavity was entered using the Hasson technique. A purse-string suture using 1 polydioxane (PDS) was placed in the umbilical fascia at 2, 4, 6, 8, 10, and 12 o'clock positions, respectively. An 11-mm nondisposable trocar was inserted inside the purse-string suture. A 10-mm, 30° angled, nonflexible, standard-length scope (Karl Storz-Endoskope, Tuttlingen, Germany) was used. Curved reusable instruments (Karl Storz-Endoskope) were inserted into the abdomen through the umbilicus without trocars. The curved grasping forceps III (Fig. 2A) was advanced through a separate opening, 5 mm outside the purse-string suture at 1 o'clock through the umbilical fascia. Other instruments such as the curved coagulating hook (Fig. 2B), curved scissors (Fig. 2C), curved bipolar scissors (Fig. 2D), curved suction device, and 5-mm straight-clip applier (Weck Hem-o-lok, Teleflex Medical, Belgium) were introduced on the opposite side of the grasper, alongside the 11-mm trocar and inside the purse-string suture (Fig. 3). The suture was adjusted to maintain a tight seal around the 5-mm tools and the 11-mm trocar, and opened only when necessary. The splenocolic ligament was opened, followed by opening the gastrosplenic ligament. As per standard practice, the short gastric vessels were sectioned by the curved coagulating hook and curved bipolar scissors. Because of the curves of the instruments, a working triangulation was established inside (Fig. 4A) and

outside (Fig. 4B) the abdomen. The main splenic artery was dissected and isolated from the main splenic vein at the level of the splenic hilum. The latter vessels were sectioned separately between 5-mm clips. The superior and inferior splenic lobes were dissected from the peritoneal attachments at the hilum cranially and caudally. A plastic bag was introduced in the cavity through the 11-mm trocar to gather the specimen. Once in the plastic bag, the specimen was morcellated at the umbilicus, taking care not to tear the bag. The abdominal cavity was checked for bleeding and the instruments were removed under visual control. The umbilical fascia, including the separate opening for the grasper, was closed using absorbable sutures.

Results

In this procedure additional supplementary trocars or incisions were not necessary. Total operative time was 180 min and partial laparoscopic time (time between the beginning of pneumoperitoneum and removal of the instruments and trocar) was 160 min. The final umbilical scar appeared to be 16 mm. The patient was discharged on postoperative day 3, and after 6 months she was doing well.

Discussion

In the technique of SATLS described here, only a classic reusable 11-mm trocar was used with the curved instruments inserted without trocars transumbilically. A trick to maintain pneumoperitoneum during the entire laparoscopy was to insert the curved grasping forceps III through a separate opening in the umbilical fascia because the grasper was kept in the surgeon's nondominant hand (left) and was never changed during the entire SATLS. The other curved instruments, kept in the surgeon's dominant hand (right), were continuously changed during the procedure, hence the placement of the purse-string suture in the umbilical fascia. The latter helped maintain the pneumoperitoneum and was opened only to change the tools in the

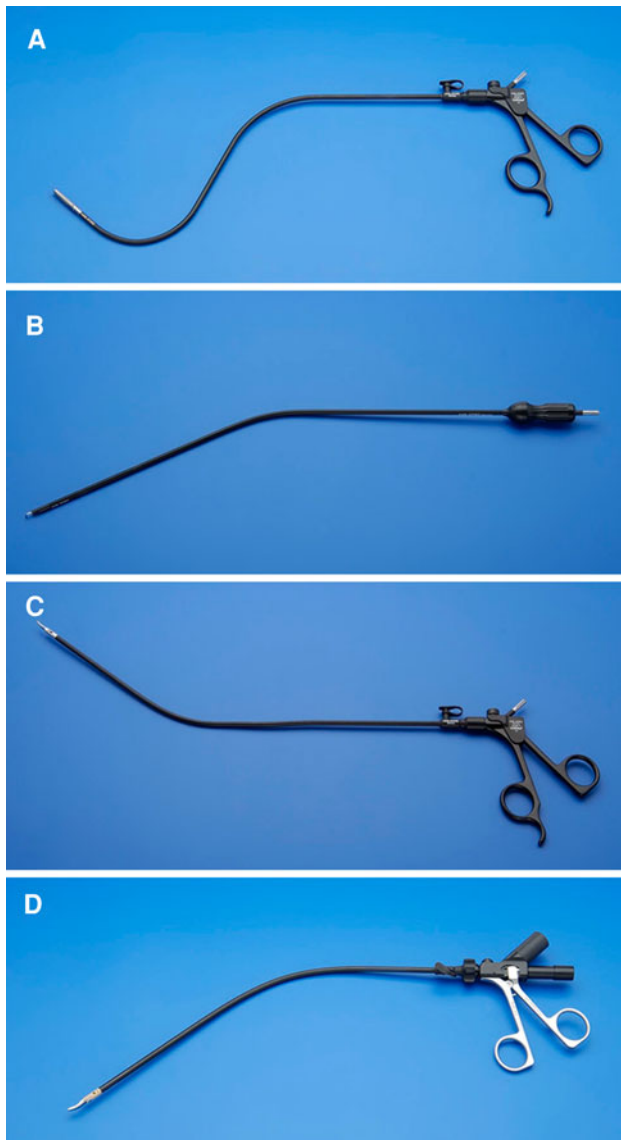


Fig. 2 DAPRI curved reusable instruments. **A** Grasping forceps III. **B** Coagulating hook. **C** Scissors. **D** Bipolar scissors (courtesy of Karl Storz-Endoskope, Tuttlingen, Germany)

surgeon's dominant hand or to evacuate the smoke created during the dissection. In order to avoid suture breakdown, a thick and sliding stitch like 1 PDS was used.

The quality of the image during this SATLS technique was the same as for classic laparoscopy because unlike other SAL [2, 4, 5, 7–9], a 5-mm scope was not used. Furthermore, because only reusable material was used, the cost of SATLS remained similar to that of classic laparoscopy.

All the curved instruments have to be inserted transumbilically following the curves, maintaining a 45° angle with respect to the abdominal wall. The curved grasping forceps III has two main curves, one at the umbilicus to

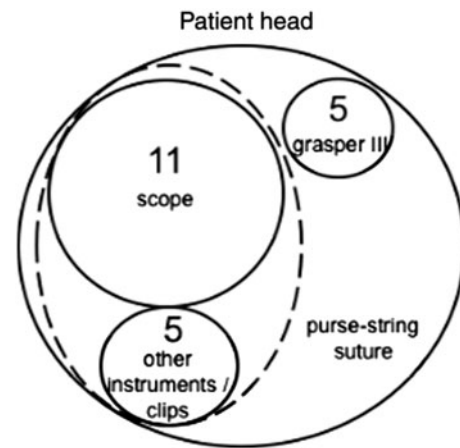


Fig. 3 Placement of the curved instruments, scope, and purse-string suture through the umbilicus

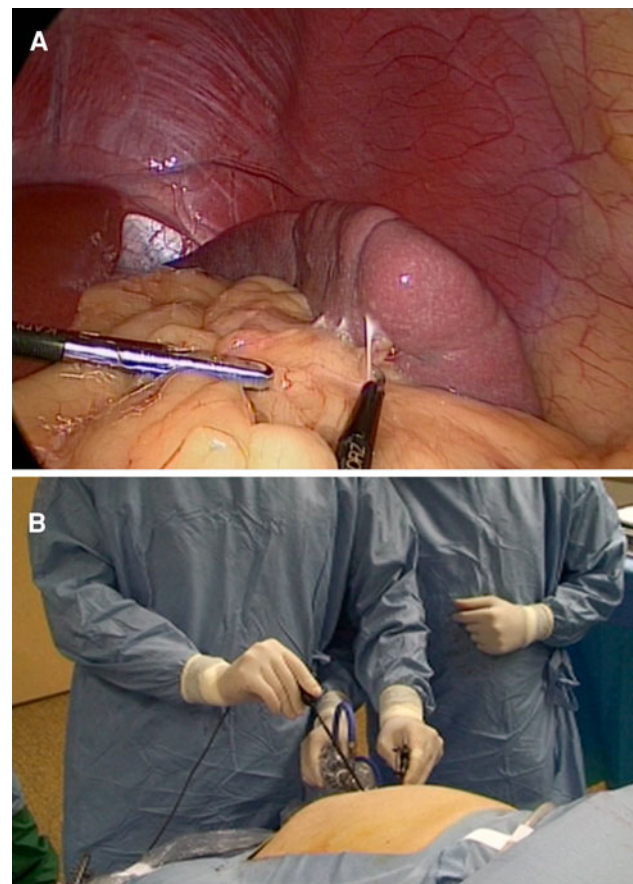


Fig. 4 Opening of the splenocolic ligament thanks to **A** the internal working triangulation and **B** the surgeon's ergonomics

avoid the conflict between the surgeon's hands and the scope outside the abdomen, and another one between the umbilicus and the instruments' tips establishing a working triangulation inside the abdomen. The curved coagulating hook, the curved scissors, and the curved bipolar scissors

are similar in shape and have only one curve to avoid the collision between the surgeon's and the assistant's hands outside the abdomen. Obviously, there is a learning curve before the instruments can be manipulated safely. This procedure with the curved instruments was quite similar to SATLS performed with articulating instruments, where coordination between the surgeon and the camera assistant is necessary [2]. Because of the curved shape of the instruments, the surgeon was able to work very ergonomically, with flexed arms similar to classic laparoscopy, since there was no clashing of the instruments' tips or crossing of the surgeon's hands, as frequently observed in SALS [10].

The selection of patients for SATLS remains an important challenge, as for SAL [1, 11]. Obviously, patients for whom an intact spleen for histological examination is necessary or who have splenomegaly (diameter > 20–25 cm) cannot undergo this procedure. We proposed SATLS in a patient with a normal-sized spleen, trying to reproduce the gold standard of laparoscopic splenectomy in normal or slightly enlarged spleens [11].

A limit of the transumbilical technique described here is that the curves are fixed and were chosen with the most common patient sizes in mind; hence, this technique is not meant for very tall or very short patients. Furthermore, patients with high BMI are poor candidates for SATLS because the transumbilical approach becomes quite impossible and the operative time longer. An option for the latter case remains SAL performed through a different incision of the umbilicus, e.g., in the left subcostal region [11].

Sometimes when the procedure becomes unexpectedly difficult or too long, one or more additional trocars have to be inserted, as in a classic laparoscopy [11]. Conversion to open surgery remains another option [9], as it was for a standard laparoscopic splenectomy.

Our operative time was longer than 110–150 min [2], 84 min [5], 120 min [9], or 60–150 min [11]. In our technique, a certain amount time was required to gain access to the abdominal cavity and to close the umbilical fascia at the end of the procedure. This procedure time can be reduced after the surgeon's learning curve, as it was the case for classic laparoscopic splenectomy [12].

Finally, in the technique described here, the umbilical incision length remained similar to the incision used in classic laparoscopy for a 12-mm trocar because only one reusable 11-mm trocar was inserted in the umbilicus and the curved tools were advanced without trocars. Moreover, since the main vessels were sectioned at the splenic hilum between 5-mm clips, as in classic laparoscopic splenectomy [12], and not by a linear stapler [2, 4, 5, 7, 9, 13], no enlargement of the incision was required.

Conclusions

SATLS was feasible and safe to be performed using curved reusable instruments. The curves of the instruments permitted surgeon to work ergonomically without the instruments clashing. The cost of the procedure remained similar to standard laparoscopy.

Disclosures Giovanni Dapri is a consultant for Karl Storz-Endoskope (Tuttlingen, Germany). Dominique Bron, Jacques Himpens, Lorenzo Casali, Pietro Carnevali, Pavlos Koustas, and Guy-Bernard Cadière have no conflicts of interest or financial ties to disclose.

References

- Gill IS, Advincula AP, Aron M, Cadeddu J, Canes D, Curcillo PG II, Desai MM, Evanko JC, Falcone T, Fazio V, Gettman M, Gumbs AA, Haber GP, Kaouk JH, Kim F, King SA, Ponsky J, Remzi F, Rivas H, Rosemurgy A, Ross S, Schauer P, Sotelo R, Speranza J, Sweeney J, Teixeira J (2010) Consensus statement of the consortium for laparoendoscopic single-site surgery. *Surg Endosc* 24:762–768
- Barbaros U, Dincag A (2009) Single incision laparoscopic splenectomy: the first two cases. *J Gastrointest Surg* 13: 1520–1523
- Tam YH, Lee KH, Chan KW, Sihoe JD, Cheung ST, Pang KK (2010) Technical report on the initial cases of single-incision laparoscopic combined cholecystectomy and splenectomy in children, using conventional instruments. *Surg Innov* 17: 264–268
- Rottman SJ, Podolsky ER, Kim E, Kern J, Curcillo PG II (2010) Single port access (SPA) splenectomy. *JLS* 14:48–52
- Hansen EN, Muensterer OJ (2010) Single incision laparoscopic splenectomy in a 5-year-old with hereditary spherocytosis. *JLS* 14:286–288
- Hanna GB, Drew T, Clinch P, Hunter B, Cuschieri A (1998) Computer-controlled endoscopic performance assessment system. *Surg Endosc* 12:997–1000
- Dutta S (2009) Early experience with single incision laparoscopic surgery: eliminating the scar from abdominal operations. *J Pediatr Surg* 44:1741–1745
- Ponsky TA, Diluciano J, Chwals W, Parry R, Boulanger S (2009) Early experience with single-port laparoscopic surgery in children. *J Laparoendosc Adv Surg Tech* 19:551–553
- Malladi P, Hungness E, Nagle A (2009) Single access laparoscopic splenectomy. *JLS* 13:601–604
- Romanelli JR, Earle DB (2009) Single-port laparoscopic surgery: an overview. *Surg Endosc* 23:1419–1427
- Targarona EM, Pallares JL, Balague C, Luppi CR, Marinello F, Hernandez P, Martinez C, Trias M (2010) Single incision approach for splenic diseases: a preliminary report on a series of 8 cases. *Surg Endosc* 24:2236–2240
- Kang CM, Lee JG, Kim KS, Choi JS, Lee WJ, Kim BR (2006) What we learned from the experience of laparoscopic splenectomy in patients with idiopathic thrombocytopenic purpura (ITP)—single surgeon experiences. *Surg Laparosc Endosc Percutan Tech* 16:151–155
- Targarona EM, Balague C, Martinez C, Pallares L, Estalella L, Trias M (2009) Single-port access: a feasible alternative to conventional laparoscopic splenectomy. *Surg Innov* 16:348–352