



Ileocecal duplication in children: a single-center experience of 115 cases

Jiayu Yan¹ · Waiun Lei¹ · Jun Yan¹ · Cailin Ding¹ · Tingting Liu² · Yajun Chen¹

Received: 10 April 2022 / Revised: 1 September 2022 / Accepted: 6 September 2022 / Published online: 12 September 2022
© The Author(s), under exclusive licence to Springer-Verlag GmbH Germany, part of Springer Nature 2022

Abstract

To evaluate the clinical features, surgical management, and prognosis of ileocecal duplication in children. A total of 115 patients diagnosed with ileocecal duplication at Beijing Children's Hospital between January 2010 and June 2021 were retrospectively reviewed. Ileocecal duplications were divided into ileal intraluminal ($n=41$), ileal extraluminal ($n=24$), ileocecal valve ($n=11$), cecal intraluminal ($n=18$), and cecal extraluminal ($n=3$) types according to their locations. Median age at diagnosis was 9.5 (0.1–169.2) months. Intussusception was only observed preoperatively in patients with the ileal intraluminal (8/41), ileocecal valve (4/11), and cecal intraluminal (7/18) types ($P=0.004$). Ileocecal resection and ileocolostomy and cyst excision without ileocecal resection were performed in 41 (35.7%) and 74 (64.3%) patients, respectively. The proportions of cyst excision without ileocecal resection performed in patients with different types were 78.0% (32/41), 91.7% (22/24), 27.3% (3/11), 27.8% (5/18), and 100.0% (3/3) ($P<0.001$). Time of oral intake ($P=0.003$) and hospital stay after surgery ($P<0.001$) were significantly shorter in patients undergoing cyst excision without ileocecal resection. There were no significant differences in the complications, growth, and stool frequency (older than 4 years) between patients undergoing different surgical procedures. Regarding the stool consistency (older than 4 years), there was a lower proportion of dry stool in patients undergoing cyst excision ($P=0.008$).

Conclusions: Ileocecal duplications at specific locations are prone to intussusception and can influence the surgical procedure choice. At mid-term follow-up, the children's growth and defecation patterns do not seem to be affected by ileocecal resection.

What is Known:

- How to address ileocecal duplication has always been challenging in clinical management.
- Children who have an ileocecal resection can develop some early postoperative complications.

What is New:

- Ileocecal duplications at specific locations are prone to intussusception and can influence the surgical procedure choice.
- Children's growth and defecation patterns do not seem to be affected by ileocecal resection.

Keywords Children · Ileocecal duplication · Location · Surgical procedure · Ileocecal resection · Prognosis

Communicated by Peter de Winter

Jiayu Yan and Waiun Lei contributed equally as co-first authors.

✉ Yajun Chen
chenyajunmd@126.com

¹ Department of General Surgery, Beijing Children's Hospital, Capital Medical University, National Center for Children's Health, Beijing, China

² Department of Emergency Surgery, Beijing Children's Hospital, Capital Medical University, National Center for Children's Health, Beijing, China

Introduction

Enteric duplication, an uncommon congenital malformation with an incidence of 1.0–2.2 per 10,000 live births, has various clinical presentations according to the location and appearance of the lesion that requires surgical resection [1–3]. Duplication lesions may occur at any level of the gastrointestinal tract but most commonly in the small intestine [4]. Ileocecal duplication accounts for approximately 20.0% of patients with an enteric duplication [5].

Ileocecal duplications are almost cystic and located in the ileocecal region near the ileocecal valve, and these patients can develop severe complications such as intestinal

obstruction and intussusception [6–8]. Due to the complex structure of the ileocecal region, the heterogeneous morphology of ileocecal duplication, and the importance of the ileocecal valve, how to address ileocecal duplication has always been challenging in clinical management [9]. Cyst excision without ileocecal resection has been gradually considered a feasible surgical procedure, first reported by Catalano et al. in 2014 [6, 10]. However, few studies have focused on the specific location of the lesions in ileocecal duplications and their impact on the choice of surgical procedures. In addition, the existing studies on ileocecal duplication could not definitively determine the effect of ileocecal resection on children's growth and defecation because of the small sample size and lack of control groups. Therefore, we performed this retrospective study of 115 cases to analyze the characteristics of ileocecal duplications in different locations, compare the outcomes between patients undergoing different surgical procedures, and provide evidence for clinical management.

Materials and methods

Patients

After being approved by the Ethics Committee of Beijing Children's Hospital (approval number: 2021-E-246-R), we conducted a retrospective study of all patients diagnosed with enteric duplication who underwent surgery in our center, Beijing Children's Hospital, Children's National Medical Center, China, from January 2010 to June 2021. Patients with a duplication cyst at the ileocecal region were included in this study. Patients who underwent surgery at other hospitals before admission were excluded. All diagnoses were confirmed by postoperative histopathology with well-defined muscular and mucosal layers.

Study design

Two pediatric surgeons reviewed the electronic medical records (Jiayu Yan and Waiun Lei). The preoperative patient characteristics, surgical details, pathological data, perioperative clinical data, and postoperative outcomes were analyzed. The preoperative patient characteristics included age, sex, prenatal diagnosis, accompanying malformations, presenting symptoms, abdominal complications, preoperative examination findings, and preoperative diagnosis. The surgical details and pathological data were extracted by reading the surgical records and postoperative pathological results, including the specific location of the lesion, surgical procedure, and lesion characteristics.

The ileocecal duplications were divided into ileal intraluminal, ileal extraluminal, ileocecal valve, cecal intraluminal, and cecal extraluminal types according to their specific locations

of the lesion (Fig. 1). We divided the patients into two groups according to the surgical procedures, including one group of patients who underwent ileocecal resection and ileocolostomy and another group who underwent cyst excision without ileocecal resection. The perioperative clinical data and postoperative outcomes were compared between the two groups.

The perioperative clinical data included the operation time, blood loss, time of defecation, time of oral intake, and hospital stay after surgery. Telephone interviews were performed in January 2022 (more than 6 months after surgery) to ask the patients' parents about the child's postoperative complications, height, and weight; additionally, the defecation patterns were assessed, including the stool frequency and stool consistency when the patients were older than 4 years old. Postoperative complications included adhesive intestinal obstruction, abdominal infection, anastomotic leakage, and anastomotic stricture. Regarding their growth, the patients were divided into two categories according to their height-for-age or BMI in normal children of the same age and sex [11]. For the height-for-age, $\geq 90\%$ indicated normal growth, and $< 90\%$ indicated stunting. For the BMI, $\geq -1SD$ indicated normal growth, and $< -1SD$ indicated underweight. The stool consistency in each patient was evaluated by the parents using modified Bristol Stool Form Scale [12].

Data analysis

Categorical variables were analyzed with the χ^2 test, Fisher's exact test, or Spearman correlation analysis. Continuous variables with a normal distribution are presented as the means \pm standard deviations (SDs) and were analyzed with Student's *t* test. Continuous variables with nonnormal distribution are presented as the medians and ranges and were analyzed with the Mann–Whitney or Kruskal–Wallis test. $P < 0.05$ (2-sided) was considered significant. The statistical calculations were performed using a software program (IBM SPSS Package, version 26; IBM Corporation).

Results

Study population

A total of 115 patients were included in this study, with a median age of 9.5 (0.1–169.2) months during our hospital visit (Table 1). In 72.2% of the patients, ileocecal duplication was diagnosed before 2 years of age (Fig. 2). Accompanying congenital malformations were found in 7 (6.1%) patients, including 2 patients with congenital heart diseases, 2 patients with indirect inguinal hernias, 1 patient with hypospadias, 1 patient with Meckel's diverticulum, and 1 patient with Klinefelter syndrome.

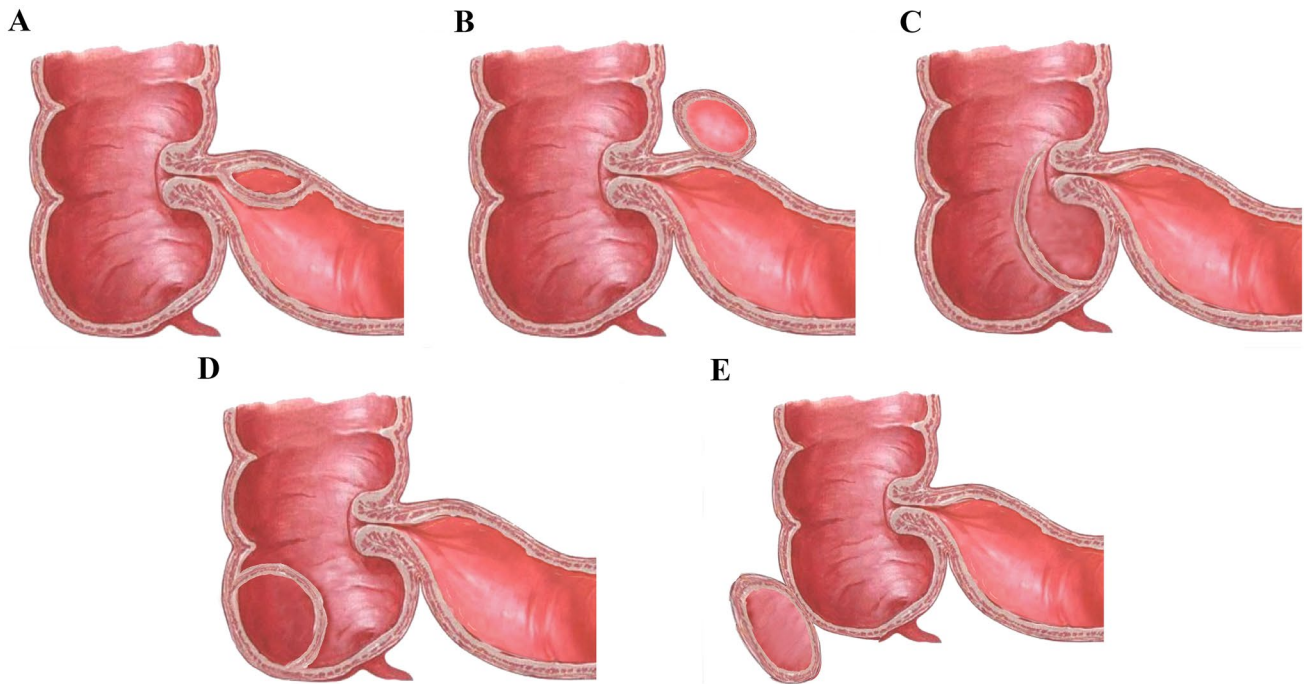


Fig. 1 Schematic diagram of specific classification of ileocecal duplication. **A** Ileal intraluminal type. **B** Ileal extraluminal type. **C** Ileocecal valve type. **D** Cecal intraluminal type. **E** Cecal extraluminal type

Patients with different types of ileocecal duplication

In addition to 18 patients whose surgical records could not determine the exact location of the lesions, the characteristics of the other 97 patients with different types of ileocecal duplication are presented in Table 2, including 41 with the ileal intraluminal type, 24 with the ileal extraluminal type, 11 with the ileocecal valve type, 3 with the cecal extraluminal type, and 18 with the cecal intraluminal type. Intussusception was only observed preoperatively in the ileal intraluminal (8/41), ileocecal valve (4/11), and cecal intraluminal (7/18) types ($P=0.004$).

The proportions of cyst excision without ileocecal resection performed in patients with different types were 78.0% (32/41), 91.7% (22/24), 27.3% (3/11), 27.8% (5/18), and 100.0% (3/3) ($P<0.001$). There was no significant difference in the length of the excised cyst ($P=0.415$) or the proportion of ectopic mucosa ($P=0.427$) among the patients with the different types. Ileocecal duplication adjacent to the ileocecal valve had a higher probability of communicating with the native lumen ($P=0.017$).

Patients undergoing different surgical procedures

Ileocecal resection and ileocolostomy and cyst excision without ileocecal resection were performed in 41 (35.7%) and 74 (64.3%) patients, respectively (Table 3). After comparing the perioperative clinical data between the patients undergoing the two different surgical procedures, we found

that the median age of the patients undergoing ileocecal resection and ileocolostomy was younger than that of the patients undergoing cyst excision without ileocecal resection ($P<0.001$). The operative time ($P=0.599$), blood loss during surgery ($P=0.859$), and defecation time after surgery ($P=0.879$) did not significantly differ between the 2 groups. The time of oral intake ($P=0.003$) and hospital stay after surgery ($P<0.001$) were significantly shorter in the patients undergoing cyst excision without ileocecal resection.

Thirty patients undergoing ileocecal resection and ileocolostomy and 63 patients undergoing cyst excision without ileocecal resection were followed up, with a median time of 8.4 (0.6–10.8) and 3.9 (0.7–11.6) years, respectively ($P<0.001$). The results showed no significant difference in the postoperative complications and growth between the 2 groups (Table 4). The postoperative complications included 2 patients with adhesive intestinal obstruction and 1 patient with septicemia in the group undergoing ileocecal resection and ileocolostomy, and 1 patient with intestinal perforation in the group undergoing cyst excision without ileocecal resection. The defecation patterns were assessed in 27 (90.0%) patients undergoing ileocecal resection and ileocolostomy and in 45 (71.4%) patients undergoing cyst excision without ileocecal resection. No significant difference between the 2 groups was noted in terms of stool frequency ($P>0.999$), while there was a lower proportion of patients with dry stool in the patients undergoing cyst excision without ileocecal resection ($P=0.008$).

Table 1 Clinical characteristics of the study population

Features	<i>n</i> = 115
Age (months) (median (range))	9.5 (0.1–169.2)
Sex (<i>n</i> (%))	
Male	60 (52.2)
Female	55 (47.8)
Prenatal diagnosis (<i>n</i> (%))	27 (23.5)
Gestational age (weeks) (mean ± SD)	25.4 ± 5.8
Accompanying malformations (<i>n</i> (%))	7 (6.1)
Admission (<i>n</i> (%))	
Outpatient	69 (60.0)
Emergency	46 (40.0)
Presenting symptoms (<i>n</i> (%))	
Vomiting	59 (51.3)
Abdominal pain (including intermittent crying)	48 (41.7)
Abdominal distension	36 (31.3)
Abdominal mass	24 (20.9)
Bloody stool	23 (20.0)
Constipation	19 (16.5)
Diarrhea	11 (9.6)
Fever	5 (4.3)
Incidental finding	2 (1.7)
Abdominal complications (<i>n</i> (%))	
Intussusception	24 (20.9)
Intestinal obstruction	22 (19.1)
Preoperative diagnostic tests (<i>n</i> (%))	
Ultrasound	115 (100.0)
Abdominal X-ray	29 (25.2)
Computed tomography	2 (1.7)
Barium enema	1 (0.9)
Magnetic resonance imaging	1 (0.9)
Preoperative diagnosis (<i>n</i> (%))	
Enteric duplication	107 (93.0)
Intussusception	4 (3.4)
Appendicitis	2 (1.7)
Intestinal obstruction	1 (0.9)
Mesenteric cyst	1 (0.9)

Discussion

We provided a more specific classification of ileocecal duplications and found that ileocecal duplications at specific locations were prone to intussusception and influenced the choice of surgical procedure. Moreover, our findings also demonstrate that ileocecal resection did not seem to affect children's growth and defecation patterns at mid-term follow-up.

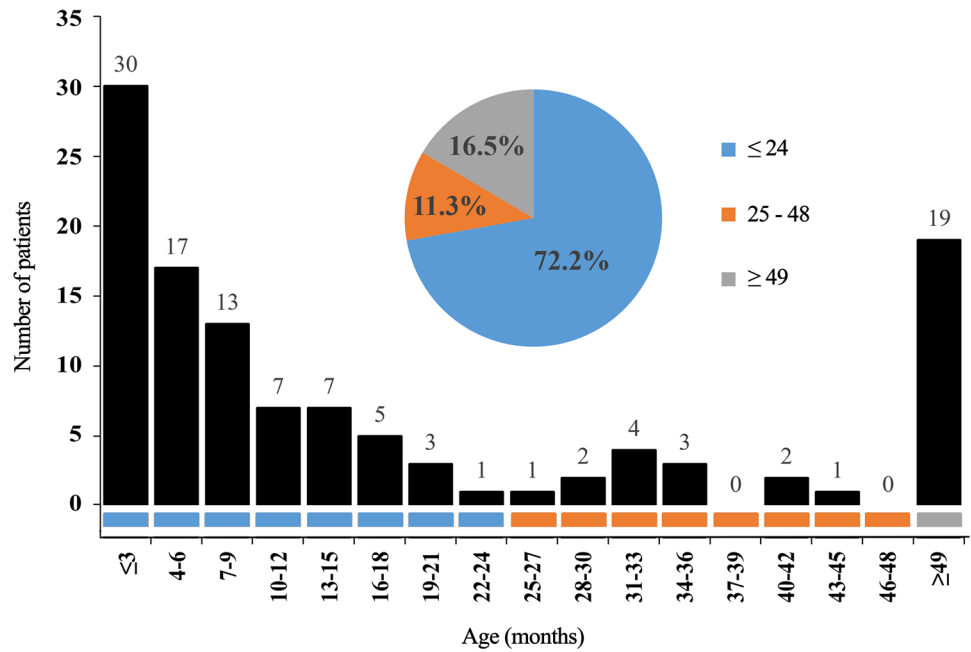
Ileocecal duplication is a particular entity, a rare enteric duplication that usually presents symptoms or complications in infancy and childhood [13, 14]. It could be distinguished from ileum duplication and includes cecal duplication and

cases of duplication at the ileocecal junction because all of these cases are located in the ileocecal region, have the same blood supply (the ileocolic artery), and can present with the same symptoms and complications [15]. Some previous studies on other diseases have demonstrated that resection of the ileocecal region has adverse effects [16, 17]. However, the available literature on ileocecal duplication is sparse and mainly consists of case reports. No controlled study about the different surgical procedures for ileocecal duplication has been reported.

A review of our data shows that similar to other types of enteric duplication, except for the prenatal ultrasonography findings, vomiting, abdominal pain, and abdominal distension were the main symptoms in ileocecal duplication; however, the rates of complications in ileocecal duplication, including intussusception and intestinal obstruction, were significantly higher than the rate in the other types [2, 5, 15]. Moreover, we noted that intussusception occurred only in ileocecal duplications at specific locations, including ileal intraluminal, ileocecal valve, and cecal intraluminal types. Two possible reasons can explain this phenomenon. First, according to the classification diagram (Fig. 1A, C, D), the lesion in the above three types can act as a pathologic lead point for intussusception [18, 19]. In contrast, the other two types cannot. Second, in the ileocecal valve and cecal intraluminal types, bowel thickening may also show the typical target signs of intussusception on ultrasound, which is not a true intussusception [14, 20]. For intestinal obstructions, space-occupying cystic lesions and the compression effects resulting from mucus secretion and accumulation may be the basic pathogenesis, affecting the normal process of food passing through the ileocecal valve [21]. Similar to a previous study, abdominal ultrasound was performed for all of the patients in our study and had high accuracy for a preoperative diagnosis [10, 22]. Whenever there is a cystic lesion in the right lower abdomen on ultrasound in a case of intussusception or intestinal obstruction in a child, the first differential diagnosis should be enteric duplication, including ileum duplication, which is the most common, or ileocecal duplication [23, 24].

Notably, the location of the cystic lesions in ileocecal duplication will affect the choice of the surgical procedure; the proportions of patients who had cyst excision without ileocecal resection performed in the ileal extraluminal, ileal intraluminal, and cecal extraluminal types were 91.7%, 78.0%, and 100.0%, respectively, which were significantly higher than those in the patients with the ileocecal valve and cecal intraluminal types. In addition, the choice of surgical procedure also depends on the surgeon's experience and any complications that develop, such as intestinal necrosis [25]. In our study, 40% of the patients were admitted to our center as an emergency, suggesting that the condition of these children was severe, and the

Fig. 2 Age distribution of patients diagnosed with ileocecal duplication



patients required surgery as soon as possible. When the children’s conditions are complicated with intussusception for a long time, intestinal necrosis may occur, further leading to shock or even death [26]. Some surgeons preferred the relatively simple ileocecal resection and ileocolostomy to prevent complications, such as delayed intestinal perforation [27].

With the improvement in the perioperative management and surgical techniques, especially when considering that

ileocecal duplication is a benign congenital malformation, an increasing number of studies have described excision of duplication cysts to preserve the ileocecal region with laparoscopy or laparoscopic assistance [6, 9, 10]. Comparing the perioperative clinical data between the patients undergoing the two different surgical procedures in our center in the past 12 years, we noted that although repair of the bowel or ileocecal valve was sometimes needed during the cyst excision, compared with the traditional ileocecal

Table 2 Characteristics of patients with different types of ileocecal duplication

	Ileal intraluminal (n=41)	Ileal extraluminal (n=24)	Ileocecal valve (n=11)	Cecal intraluminal (n=18)	Cecal extraluminal (n=3)	P value	Total (n=115)*
Abdominal complications (n (%))							
Intussusception	8 (19.5)	0 (0.0)	4 (36.4)	7 (38.9)	0 (0.0)	0.004	24 (20.9)
Intestinal obstruction	6 (14.6)	3 (12.5)	1 (9.1)	7 (38.9)	0 (0.0)	0.176	22 (19.1)
Surgical procedures (n (%))							
Ileocecal resection and ileocolostomy	9 (22.0)	2 (8.3)	8 (72.7)	13 (72.2)	0 (0.0)		41 (35.7)
Cyst excision without ileocecal resection	32 (78.0)	22 (91.7)	3 (27.3)	5 (27.8)	3 (100.0)	<0.001	74 (64.3)
Duplication characteristics							
Length of the cyst (cm) (median (range))	3.0 (0.5–7.0)	3.0 (1.0–5.0)	3.0 (2.0–7.0)	3.3 (2.0–6.0)	3.0 (1.5–3.5)	0.415	3.0 (0.5–7.0)
Connection with the native lumen (n (%))	0 (0.0)	1 (4.2)	3 (27.3)	1 (5.6)	0 (0.0)	0.017	6 (5.2)
Ectopic gastrointestinal mucosa (n (%))	15 (36.6)	5 (20.8)	4 (36.4)	3 (16.7)	1 (33.3)**	0.427	30 (26.1)

*The specific types of 18 patients could not be determined by operative recordings and postoperative pathological results

**Duodenal mucosa

Table 3 Perioperative clinical data of the patients according to the procedure types

Characteristics (median (range))	Ileocecal resection and ileocolostomy (<i>n</i> = 41)	Cyst excision without ileocecal resection (<i>n</i> = 74)	<i>P</i> value
Age at the time of surgical procedure (months)	5.4 (0.1–147.4)	13.9 (0.2–169.2)	<0.001
Operation time (min)	110 (60–315)	105 (45–200)	0.599
Blood loss (mL)	2 (1–10)	2 (0–10)	0.859
Defecation (days)	3 (1–6)	2 (1–6)	0.879
Oral intake time (days)	5 (2–9)	4 (1–9)	0.003
Hospital stay (days)	8 (5–18)	7 (3–19)	<0.001

resection and ileocolostomy procedures, these procedures did not significantly increase the operative time or blood loss. Furthermore, these patients recovered more quickly after surgery, manifested by an earlier oral intake and a shorter hospital stay. This technique retains the important function of the ileocecal valve in childhood and is consistent with the concept of enhanced recovery after surgery [28]. We also observed that the median age of the patients undergoing ileocecal resection and ileocolostomy was significantly younger than those undergoing cyst excision. This observation implies that younger children with ileocecal duplication tend to have more severe complications, such as dehydration, and the surgical procedures for these patients tend to be more conservative, even including

an ileostomy [8, 24]. However, considering that only a small number of patients (1.6%) undergoing cyst excision without ileocecal resection had postoperative complications in our study and recent findings in other studies, we recommend that cyst excision without ileocecal resection is a safe and feasible option for ileocecal duplication, except for patients with severe complications, including dehydration, intestinal perforation, and a prolonged intussusception [6, 10].

Furthermore, in our study, ileocecal resection did not increase the incidence of postoperative complications or affect the growth of children with ileocecal duplication. At the same time, in contrast to previous literature, a high proportion of the patients did not have postoperative diarrhea

Table 4 Postoperative outcomes of the patients according to the procedure types

Characteristics	Ileocecal resection and ileocolostomy (<i>n</i> = 30)	Cyst excision without ileocecal resection (<i>n</i> = 63)	<i>P</i> value
Follow-up age (years) (median (range))	9.4 (1.3–20.6)	7.1 (1.0–24.1)	0.004
Follow-up time (years) (median (range))	8.4 (0.6–10.8)	3.9 (0.7–11.6)	<0.001
Complications (<i>n</i> (%))	3 (10.0)	1 (1.6)	0.097
Growth (<i>n</i> (%))	27 (90.0)	57 (90.5)	—
Height-for-age (<i>n</i> (%))			>0.999
(I) Normal ($\geq 90\%$)	27 (100.0)	56 (98.2)	
(II) Stunting ($< 90\%$)	0 (0.0)	1 (1.8)	
BMI (<i>n</i> (%))			>0.999
(I) Normal (≥ -1 SD)	26 (96.3)	54 (94.7)	
(II) Underweight (< -1 SD)	1 (3.7)	3 (5.3)	
Defecation* (<i>n</i> (%))	27 (90.0)	45 (71.4)	—
Follow-up age (years) (median (range))	9.6 (5.4–20.6)	8.2 (4.0–24.1)	0.054
Stool frequency (<i>n</i> (%))			>0.999
(I) Every other day to twice a day	24 (88.9)	39 (86.7)	
(II) More often	0 (0.0)	0 (0.0)	
(III) Less often	3 (11.1)	6 (13.3)	
Stool consistency** (<i>n</i> (%))			0.008
(I) 1–2	14 (51.9)	9 (20.0)	
(II) 3	13 (48.1)	36 (80.0)	
(III) 4–5	0 (0.0)	0 (0.0)	

*The defecation patterns were evaluated in patients who aged older than 4 years

**Stool consistency was evaluated by modified Bristol Stool Form Scale

[29]. The patients undergoing ileocecal resection and ileocolostomy had a higher incidence of dry stool with a median follow-up time of 8.4 (0.6–10.8) years. This finding might be related to the fact that ileocecal resection without an extensive ileal resection did not affect bile acid absorption [16, 30]. Moreover, we hypothesized that an ileocecal valve resection could lead to colon bacterial overgrowth and colonization of the ileum, thereby increasing the ability of the digestive tract to absorb water, resulting in dry stool at mid-term follow-up [17, 31].

This study was a retrospective analysis of a single institution and still had limitations. First, the primary limitation was the retrospective nature of the design. Consistency in the choice of surgical procedures for ileocecal duplication cannot be guaranteed in our study due to the different surgeons and some emergency surgical treatments, which may lead to errors in the results. In addition, the short-term postoperative defecation patterns in the patients undergoing ileocecal resection and ileocolostomy could not be acquired. Second, our study did not compare the follow-up results with normal children, so it was impossible to know whether ileocecal resection affects the patients' long-term postoperative defecation, which is the focus of our future study. Finally, even though we clearly described the definitions of the stool characteristics for each scale within the modified Bristol Stool Form Scale to the children's parents through telephone interviews, there were still some errors.

Acknowledgements We thank Yueping Zeng for assisting in retrieving the hospital/medial record numbers for the electronic patient records needed for data collection. Jiayu Yan thanks his parents for always accompanying him to grow up.

Authors' contributions JY and YC conception and design of the work. JY and WL conducted data collection and performed data analysis. JY, WL, JY, CD, and TL contributed to the data interpretation. JY, WL, and YC assisted in drafting the manuscript. All authors critically revised the manuscript and read and approved the final manuscript for submission.

Declarations

Ethics approval The study received approval by the Ethics Committee of Beijing Children's Hospital (approval number: 2021-E-246-R).

Consent to participate N/A.

Consent for publication N/A.

Conflict of interest The authors declare no competing interests.

References

- Mayer JP, Bettolli M (2014) Alimentary tract duplications in newborns and children: diagnostic aspects and the role of laparoscopic treatment. *World J Gastroenterol* 20:14263–14271. <https://doi.org/10.3748/wjg.v20.i39.14263>
- Kim SH, Cho YH, Kim HY (2020) Alimentary tract duplication in pediatric patients: its distinct clinical features and managements. *Pediatr Gastroenterol Hepatol Nutr* 23:423–429. <https://doi.org/10.5223/pghn.2020.23.5.423>
- Jezioreczak PM, Warner BW (2018) Enteric duplication. *Clin Colon Rectal Surg* 31:127–131. <https://doi.org/10.1055/s-0037-1609028>
- Stringer MD, Spitz L, Abel R, Kiely E, Drake DP, Agrawal M, Stark Y, Brereton RJ (1995) Management of alimentary tract duplication in children. *Br J Surg* 82:74–78. <https://doi.org/10.1002/bjs.1800820126>
- Sujka JA, Sobrino J, Benedict LA, Alemayehu H, Peter SS, Hendrickson R (2018) Enteric duplication in children. *Pediatr Surg Int* 34:1329–1332. <https://doi.org/10.1007/s00383-018-4362-x>
- Catalano P, Di Pace MR, Caruso AM, De Grazia E, Cimador M (2014) Ileocecal duplication cysts: is the loss of the valve always necessary? *J Pediatr Surg* 49:1049–1051. <https://doi.org/10.1016/j.jpedsurg.2013.12.026>
- Radhakrishna V, Rijhwani A, Jadhav B (2018) Cecal duplication: a mimicker of intussusception: a case report and review. *Ann Med Surg (Lond)* 31:17–19. <https://doi.org/10.1016/j.amsu.2018.05.010>
- Pai NG, Prabhu S, Prabhakar P, Kumar V (2020) Duplication cyst with midgut volvulus in a neonate: an unusual presentation. *BMJ Case Rep* 13:e235526. <https://doi.org/10.1136/bcr-2020-235526>
- Górecki W, Bogusz B, Zając A, Sołtysiak P (2015) Laparoscopic and laparoscopy-assisted resection of enteric duplication cysts in children. *J Laparoendosc Adv Surg Tech A* 25:838–840. <https://doi.org/10.1089/lap.2015.0103>
- Chen J, Wang J, Gu Z, Huang S, Zhu J, Wu B, Zhu Z, Cai P, Sun C (2020) Laparoscopic resection of ileocaecal duplication in children (report of 15 cases). *J Minim Access Surg* 16:372–375. https://doi.org/10.4103/jmas.JMAS_120_19
- World Health Organization (2009) WHO child growth standards and the identification of severe acute malnutrition in infants and children: a joint statement by the World Health Organization and the United Nations Children's Fund. Geneva
- Wegh CAM, Hermes GDA, Schoterman MHC, Vaughan EE, Smidt H, Belzer C, Benninga MA (2021) The Modified Bristol Stool Form Scale: a reliable and valid tool to score stool consistency in Dutch (Non) toilet-trained toddlers. *J Pediatr Gastroenterol Nutr* 73:210–216. <https://doi.org/10.1097/MPG.0000000000003186>
- Keum SW, Hwang MW, Na JI, Yu ST, Oh YK (2009) Intestinal obstruction caused by a duplication cyst of the cecum in a neonate. *Korean J Pediatr* 270:527–533. <https://doi.org/10.3345/kjp.2009.52.2.261>
- Verma S, Bawa M, Rao KL, Sodhi KS (2013) Caecal duplication cyst mimicking intussusception. *BMJ Case Rep* 2013:bcr2012008056. <https://doi.org/10.1136/bcr-2012-008056>
- Stern LE, Warner BW (2000) Gastrointestinal duplications. *Semin Pediatr Surg* 9:135–140. <https://doi.org/10.1053/spsu.2000.7565>
- Diederer K, de Ridder L, van Rheenen P, Wolters VM, Mearin ML, de Meij TG, van Wering H, Oomen MW, de Jong JR, Sloots CE, Benninga MA, Kindermann A (2019) Quality of life and colorectal function in Crohn's disease patients that underwent ileocecal resection during childhood. *Eur J Pediatr* 178:1413–1421. <https://doi.org/10.1007/s00431-019-03427-3>
- Shafik AA, Ahmed IA, Shafik A, Wahdan M, Asaad S, El Neizamy E (2011) Ileocecal junction: anatomic, histologic, radiologic and endoscopic studies with special reference to its antireflux mechanism. *Surg Radiol Anat* 33:249–256. <https://doi.org/10.1007/s00276-010-0762-x>
- Lai M, Coakley BA, Webber EM, Goldman RD (2018) Intussusception with cecal cyst as lead point in a child. *Pediatr Emerg Care* 34:e134–135. <https://doi.org/10.1097/PEC.0000000000000893>
- Al-Shaibi MA, Raniga SB, Asghar ANM, Al Tubi IS (2019) Caecal duplication cyst leading to intussusception in an adult. *BMJ Case Rep* 12:e230567. <https://doi.org/10.1136/bcr-2019-230567>

20. Karakus SC, Ozokutan BH, Ceylan H (2014) Diseases mimicking intussusception: diagnostic dilemma. *Pediatr Int* 56:768–771. <https://doi.org/10.1136/bcr-2019-230567>
21. Yan J, Yan J, Ding C, Guo J, Peng Y (2021) Chen Y (2021) Clinical features of colorectal duplication in children: a study of 25 cases. *J Pediatr Surg* S0022–3468(21):00657–00666. <https://doi.org/10.1136/bcr-2019-230567>
22. Pracros JP, Tran-Minh VA, Wright C (1985) Ultrasound in diagnosis of intussusception. *Lancet* 28:733–734. <https://doi.org/10.1136/bcr-2019-230567>
23. Renu Kumar T, Satya Srinivas B (2014) Cecal duplication cyst presenting as a recurrent intestinal obstruction. *Indian J Pediatr* 81:516–518. <https://doi.org/10.1136/bcr-2019-230567>
24. Tawil KA, Crankson S, Emam S, Eldemerdash A, Sabbagh F, Laimoun BA (2005) Cecal duplication cyst: a cause of intestinal obstruction in a newborn infant. *Am J Perinatol* 22:49–52. <https://doi.org/10.1136/bcr-2019-230567>
25. Temiz A, Oğuzkurt P, Ezer SS, İnce E, Gezer HÖ, Hiçsönmez A (2013) Different clinical presentations, diagnostic difficulties, and management of cecal duplication. *J Pediatr Surg* 48:550–554. <https://doi.org/10.1136/bcr-2019-230567>
26. Bogdanović M, Blagojević M, Kuzmanović J, Ječmenica D, Alempijević Đ (2019) Fatal intussusception in infancy: forensic implications. *Forensic Sci Med Pathol* 15:284–287. <https://doi.org/10.1136/bcr-2019-230567>
27. Fisher JG, Sparks EA, Turner CG, Klein JD, Pennington E, Khan FA, Zurakowski D, Durkin ET, Fauza DO, Modi BP (2015) Operative indications in recurrent ileocolic intussusception. *J Pediatr Surg* 50:126–130. <https://doi.org/10.1016/j.jpedsurg.2014.10.012>
28. Ljungqvist O, Scott M, Fearon KC (2017) Enhanced recovery after surgery: a review. *JAMA Surg* 152:292–298. <https://doi.org/10.1001/jamasurg.2016.4952>
29. Iwanaka T, Hashizume K, Kawarasaki H, Tanaka K, Kanamori Y, Utsuki T, Obana K, Uno K, Sugiyama M, Tsuchida Y (1993) Ileocecal resection in neonates and infants: a follow-up study. *J Pediatr Surg* 28:110–112. [https://doi.org/10.1016/s0022-3468\(05\)80367-7](https://doi.org/10.1016/s0022-3468(05)80367-7)
30. Ho KJ, Bondi JL (1977) Cholesterol metabolism in patients with resection of ileum and proximal colon. *Am J Clin Nutr* 30:151–159. <https://doi.org/10.1093/ajcn/30.2.151>
31. Malbert CH (2005) The ileocolonic sphincter. *Neurogastroenterol Motil* 17:41–49. <https://doi.org/10.1111/j.1365-2982.2005.00657.x>

Publisher's Note Springer Nature remains neutral with regard to jurisdictional claims in published maps and institutional affiliations.

Springer Nature or its licensor holds exclusive rights to this article under a publishing agreement with the author(s) or other rightsholder(s); author self-archiving of the accepted manuscript version of this article is solely governed by the terms of such publishing agreement and applicable law.