



Clinical presentations and surgical outcomes of intraocular foreign body presenting to an ocular trauma unit

Rodrigo Anguita^{1,2} · René Moya^{1,3} · Victor Saez¹ · Gaurav Bhardwaj^{2,4} · Alejandro Salinas¹ · Rudolf Kobus¹ · Cristóbal Nazar⁵ · Rodolfo Manriquez¹ · David G. Charteris²

Received: 7 May 2020 / Revised: 9 July 2020 / Accepted: 23 July 2020 / Published online: 30 July 2020
© Springer-Verlag GmbH Germany, part of Springer Nature 2020

Abstract

Objectives To describe, evaluate, and identify the characteristics, prognostic factors, and visual outcomes in patients with intraocular foreign body (IOFB) in a Latin American population.

Methods A retrospective, observational case-series of patients with a diagnosis of IOFB. Variables analyzed included age, gender, initial and final best correct visual acuity (BCVA), ocular trauma score, intraocular pressure, mechanism of injury, material and number of IOFB, zone of injury, timing of primary repair and IOFB removal, complications, and follow up.

Results Sixty-one patients with IOFB were identified of which 97% were male with a mean age of 37.9 years (SD 2.16). The most common IOFB location was intravitreal (43%). IOFBs were metallic in 78%, vegetal in 3%, and other materials in 11%. Primary repair and secondary IOFB removal were performed at a mean timepoint of 3 days and 5 days, respectively. Systemic and topical antibiotics were administered to all patients. The initial BCVA was 1.62 logMAR and the final was 0.6 logMAR, which was statistically significant (Pearson's chi-squared test, *p* value 0.01). No cases of endophthalmitis were seen.

Conclusion IOFB removal can be delayed when there are no signs of infection or evidence of retinal detachment, without an increased risk of endophthalmitis and a negative impact on visual outcomes. Use of topical and systemic antibiotics appear sufficient to prevent endophthalmitis in these cases.

Keywords Intraocular foreign body · Latin America · Ocular trauma · Retina · Vitreoretinal surgery · Traumatic endophthalmitis · Traumatic retinal detachment · Antibiotics

Introduction

Intraocular foreign body (IOFB) is a serious ophthalmic emergency which can result in blindness. IOFBs account for 16–41% of open globe injuries, and may affect visual function severely [1–3]. Young men are the most commonly affected group, usually accounting for over 90% of cases [2, 4] notably in work-related injuries without adequate protective measures. In 1993, Thompson and co-workers reported that only 6% of those who suffered IOFB were wearing protective eyewear [5]. Hammering is the most common mechanism of injury, reported to account for 43% [2]. Treatment is surgical and

the main objective is to achieve an effective repair of ocular anatomy, remove the IOFB, and minimize complications, in particular endophthalmitis.

There is currently no published data on the outcomes of IOFB in a Latin American population. In this study, we analyzed the presenting features and clinical outcomes of patients with IOFB who were seen at Ocular Trauma Unit (UTO), the Chilean National referral center of ocular trauma. We aimed to report the mechanism of injury, surgical approach, and outcomes with a specific focus on assessing whether antibiotic prophylaxis and deferred IOFB removal resulted in a significant incidence of endophthalmitis.

✉ Rodrigo Anguita
rodrigoanguita@gmail.com

¹ Hospital Del Salvador, Universidad de Chile, Santiago, Chile

² Moorfields Eye Hospital NHS Foundation Trust, London, UK

³ Centro de la visión, Clínica las Condes, Santiago, Chile

⁴ Faculty of Medicine and Health, Sydney Medical School, Discipline of Ophthalmology and Eye Health and Save Sight Institute, The University of Sydney, Sydney, Australia

⁵ Hospital De La Florida, Santiago, Chile

Methods

A retrospective observational case-series of patients with a diagnosis of IOFB was collected from clinical records of patients presenting with IOFB at UTO, Hospital Del Salvador, Santiago, Chile (Chilean National Referral Centre of ocular trauma) presenting between January 2015 and December 2017. The UTO had 34,087 outpatient attendances with diagnosis of ocular trauma during this period. Ocular trauma was recorded according to the recommendations of the United States Eye Injury Registry and the International Society of Ocular Trauma Birmingham Eye Trauma Terminology (BETT) [6]. The ocular trauma score (OTS) was applied in all cases [7]. Variables analyzed included age, gender, initial and final best correct visual acuity (BCVA), OTS, intraocular pressure (IOP), mechanisms of injury, material and number of IOFB, zone of injury (according to the Ocular Trauma Classification Group: zone I: cornea, including corneoscleral limbus, zone II: corneoscleral limbus to a point 5 mm posterior into the sclera and zone III: posterior to the anterior 5 mm of the sclera) [8], timing of primary repair and IOFB removal, use of systemic antibiotics and intravitreal antibiotics (IVA), complications, and follow up.

All IOFBs were diagnosed and confirmed by ultrasound and/or computed axial tomography. The data was recorded into a database (Excel®). All statistical analyses were performed using GraphPad Prism version 6.01. Variables were analyzed using Spearman correlation coefficient and Mann–Whitney *U* test. A *p* value of < 0.05 was considered statistically significant for all tests. The research protocol was approved by the Hospital Del Salvador Ethics Committee and fulfilled the Declaration of Helsinki.

Results

Demographic features

A total of 61 eyes of 61 patients with a diagnosis of IOFB were analyzed (Table 1). The average age at diagnosis was 37.9 (SD 2.16, range 8–85 years) and 59 patients were males (97%). Hammering was the most common mechanism accounting for 57% (35 eyes); followed by use of machining tools with missiles of glass and stone in 34% (21 eyes); explosions 5% (3 eyes); and vegetal trauma 3% (2 eyes).

Clinical features

At presentation, 7% of patients had OTS 1, 13% OTS 2, 41% OTS 3; 10% OTS 4; and 30% OTS 5. With respect to the zone of injury, 40 patients (66%) had trauma in Zone I; 16 patients (26%) in Zone II and 5 patients (8%) in Zone III. Ocular findings at admission are detailed in Table 2. Sixty of 61

patients (98%) had a single IOFB with one patient presenting with three IOFBs. The material of the IOFB was metallic magnetic in 46 (75%), metallic non-magnetic in 2 (3%), vegetal in (3%), and others (glass, stone, among others) in 11 (18%). The most common location of IOFB was intravitreal in 26 eyes (43%), followed by retinal in 22 eyes (36%), 8 in the anterior chamber (13%), and 5 intralenticular (8%).

Treatment

With respect to the treatment, the timing of primary repair was a mean of $3 \pm$ days (SD 0.5 range 0–17) following the injury. IOFB was removed during the primary repair (open globe rupture repair and vitrectomy) in 35 cases (57%); in 26 patients (42%), extraction of the IOFB was deferred due to lack of vitreoretinal expertise or a severely compromised view. The average timing for IOFB removal was 5 days (SD 5.2 range 0–22). In one patient, the IOFB was removed 270 days later. In this case, the primary repair was performed in his local hospital, and no IOFB was diagnosed until the patient presented with siderosis. This patient was excluded from the analysis.

Systemic antibiotic was administered to all patients immediately at the time of diagnosis and again before surgical repair, as a part of endophthalmitis prophylaxis. This consisted of moxifloxacin 400 mg once a day PO for 5 days in 60/61 (98%) patients. One patient, an 8-year-old child, was treated with cefazolin 75 mg/kg/day and clindamycin 15 mg/kg/day. Intravitreal antibiotics (IVA) were injected in 5 patients (8%) according to surgeon preference, at the moment of the primary repair. Therefore, the majority of patients in our study have not had IVA as a part of the treatment. Topical moxifloxacin was administered to all patients after the primary repair.

Twenty-three-gauge vitrectomy (Alcon Constellation® system) was utilized in all cases of intravitreal and retinal IOFB (48 eyes) and one case of intralenticular IOFB. Gas endotamponade (C3F8 and SF6) and silicone oil were each used in 10 cases. Those eyes without significant retinal damage were filled with air in 20 cases (41%) and balanced salt solution (BSS) in 9 cases (18%).

Complications (Table 3)

The most common complication was retinal detachment in 13% (8 cases), followed by glaucoma in 11% (7 cases), phthisis in 7% (4 cases), and cystoid macular edema (CMO) in 5% (3 cases). One case each of postoperative cataract, epiretinal membrane (ERM), macular scar, and corneal ulcer were recorded. No patients with traumatic endophthalmitis (TE) or sympathetic ophthalmia were observed during the period of follow up (mean $163 \pm$ 19 days). No complications were seen in 36 eyes.

Key messages

- Intraocular foreign body is a serious ophthalmic emergency which can result in blindness. The working-age population group is the most affected. This has to be managed by vitreoretinal surgeons with experience in ocular trauma in order to achieve an effective repair of ocular anatomy, remove the IOFB, and minimise complications.
- The series emphasizes the success of the prompt use of systemic and topical antibiotics in preventing endophthalmitis.
- The IOFB removal can be delayed, when there are no signs of infection, high risk features such as vegetal IOFB, or evidence of retinal detachment, without an increase of risk of endophthalmitis and a negative impact on visual outcomes

With respect to the number of reoperations, 29 patients underwent one additional surgery, 4 patients needed two surgeries, and 1 patient had three procedures. Types of surgery included secondary intraocular lens (IOL) implantation which was performed in 25 patients (41%) and pars plana vitrectomy (PPV) which was performed in 15 patients (25%). The main indication for PPV was retinal detachment (8 eyes) and removal of silicone oil (ROSO) (7 eyes). In 6 patients, secondary IOL implantation and PPV were performed at the same time. Twenty-seven (44%) patients did not undergo any reoperation.

Visual outcomes and follow up

The initial mean BCVA was 1.62 logMAR (0.25 ± 0.04 decimal), and the final mean BCVA had improved significantly to 0.6 logMAR (0.58 ± 0.10 decimal) (Wilcoxon rank-sum test, p value < 0.0001). At presentation, 5 patients had no light perception (NLP) and 28 patients had a BCVA between light perception (LP) and counting finger (CF). At the end of follow up, 35 patients had a final BCVA 0.3 logMAR (20/40) or better and 6 had vision of NLP.

In regard to ocular trauma score, patients with OTS 3 or better had significantly better final visual acuity (LogMar 0.37 ± 0.48) than the group of patients with OTS 2 or less (LogMar 1.68 ± 1.10) (Mann Whitney test, p value < 0.0001). The BCVA was not affected by time interval to primary repair of globe rupture (Spearman correlation coefficient, p value = 0.26), and there was no correlation between final BCVA and time of extraction of IOFB (Spearman

correlation coefficient, p value = 0.8). In terms of zone of injury, there were no statistically significant differences between zone of injury and final BCVA (Fig. 1) (Spearman correlation coefficient p value = 0.8). Finally, the correlation between final BCVA and location of IOFB was not statically significant (Fig. 2.) (Kruskar-Wallis p value = 0.2 with Dunn's multiple comparison test). The mean duration of follow up was 163 ± 19 days.

Discussion

Ocular trauma is a relevant cause of blindness in Chile. Currently there is no accurate data in the Chilean population regarding the presenting features and surgical outcomes of

Table 1 Demographic and clinical features and visual outcomes

Features	Results
Age (Mean, SD, range)	37.9 ± 2.16 (8–85)
Gender (% , number)	Male 97% (59) Female 3% (2)
Eye (% , number)	Right 56% (34) Left 44% (27)
Visual acuity at presentation (Snellen) (decimal) (mean, SD)	1.62 logMAR and (0.25 ± 0.04 decimal)
Final visual acuity (Snellen) (decimal) (mean, SD)	0.6 logMAR (0.58 ± 0.10 decimal)

Table 2 Ocular findings at presentation

Ocular findings	Percentage % (number)
Traumatic cataract	36% (22)
Vitreous hemorrhage	34% (21)
Retinal tears	20% (12)
Capsular rupture	18% (11)
Hyphema	18% (11)
Retinal detachment	11% (7)
Choroidal detachment	10% (6)
Subluxation crystalline lens	3% (2)
Vein occlusions	2% (1)
Macular lesions	2% (1)
Siderosis	2% (1)
Zone of injury	Zone I 66% (40) Zone II 26% (16) Zone III 8% (5)
IOFB location	Intravitreal 43% (26) Retinal (partially penetrated/ perforated the retina) 36% (22) Anterior chamber 13% (8) IntracrySTALLINE 8.19% (5)

IOFB. The reported incidence of IOFB in cases of open globe injury varies from 16 to 41% [1–3]. In our study, most cases took place in work environments and patients did not wear eye protection, even though there are regulatory policies for work safety consistent with previous studies in which only 0.8 to 6% of patients wore eye protection [4, 9]. In our series, 97% of patients were working-age men, which is also in agreement with previous data [2, 9, 10]. Hammering was the main mechanism of trauma, accounting for 57%. In previous reports, this mechanism varies from 35 to 83% [10, 11].

The OTS is considered a good predictor of final visual acuity [7]—this was also observed in our study. Those patients with OTS 2 or more had significantly better final BCVA. Most of our patients had trauma in Zone I (65%), compared with Zone II (26%) and finally Zone III (8%), which is similar to previous reported studies [10]. The most common reported clinical features at presentation include traumatic cataract (43–73%), vitreous hemorrhage (33–57%), and retinal detachment (5–23%) [2, 10]. We demonstrate similar clinical findings: traumatic cataract (36%), vitreous hemorrhage (34%), and retinal detachment in 11%. A literature review by Kuhn et al. showed that multiple IOFBs can be seen in 8–25% of eyes [12], although we document multiple IOFBs in only one of 61 cases in our series.

In IOFB cases, initial visual acuity is a well-recognized predictive factor [10, 13–15], which correlates with final visual results. This reflects the level of damage in intraocular tissues at the initial injury, which is difficult to adequately repair, depending on retinal or optic nerve involvement. In

our study, the BCVA was not affected by time interval to primary repair of globe rupture, which has previously been described by Guven et al. [16] and Zhang et al. [10]. Previous work [10, 17–21] has suggested that visual acuity is not affected by timing of IOFB removal. Colyer et al. [21] evaluated IOFB in military conflicts showed that timing of vitrectomy did not correlate with visual outcome with a median time to IOFB removal of 21 days (mean 38 days; range 2–661 days). On the other hand, Chaudhry [22] showed that a delay in the IOFB removal for 48 h or more was a predictor of poor visual acuity and a delay was also associated with an increased risk of endophthalmitis, an association which was not observed in our study and other previous reports [10, 21].

Williams and colleagues [19] did not find that the zone of injury was an independent prognostic factor in poor outcomes; however, as in other reports, they described that large wounds may be associated with poor visual results [19, 20]. In our analysis, there were no statistically significant differences between zone of injury and final BCVA. Conversely, significant differences have been reported between anterior and posterior location of the wound, the latter having worse visual results [23]. The size of the wound was not systematically evaluated in our study.

The location of IOFB is another relevant prognostic factor in previous publications. Although it has been reported that IOFBs in the posterior segment are related to poor visual outcomes [20, 24], this was not observed in our study. We believe that we did not find differences in visual outcomes according to zone of injury because the majority of our patients had trauma in zone 1 and the location of IOFB was intravitreal. We hypothesize that energy is dissipated during penetration of the IOFB and may be absorbed by the cornea, iris, and lens. In our study, 36% of IOFB were located in the retina and 43% were in the vitreous. Although it is documented in a previous report that intravitreal IOFB can come to rest in the vitreous after rebounding off the retina [25], this did not seem to be the case in our series.

Another visual predictive factor which has been widely studied is post-traumatic endophthalmitis [22, 26]. The

Table 3 Complications after extraction of IOFB

Complications	% (number)
Retinal detachment	13% (8)
Glaucoma	11% (7)
Phthisis	7% (4)
Cystoid macular edema	5% (3)
Cataract	2% (1)
Epiretinal membrane	2% (1)
Corneal ulcer	2% (1)
Macular scar	2% (1)

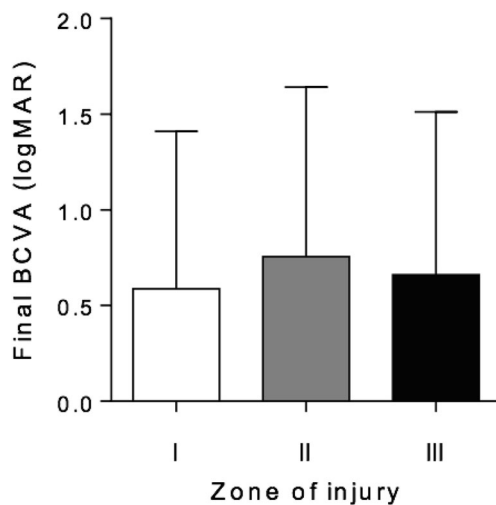


Fig. 1 Bar chart showing final BCVA in the different zone of injury. No statistically significant differences were observed

percentage of endophthalmitis previously reported varies from 0 [9, 21, 27] to 17% [10]. In our study, we did not see any cases of endophthalmitis. We believe that the absence of endophthalmitis in our cases is likely due to two factors. First of all, the material of IOFB being mostly metallic with only 2 vegetal IOFB and finally due to routine use and excellent intravitreal penetration of systemic moxifloxacin, which was used in all of our patients. Only 5 patients with IOFB included in this study had documentation of intravitreal antibiotics. Several studies have shown excellent intravitreal concentrations and broad-spectrum coverage with moxifloxacin after systemic administration [28–30]. Colyer et al. [21] highlighted the potential role of topical and systemic fluoroquinolone agents (primarily gatifloxacin, moxifloxacin, or levofloxacin)

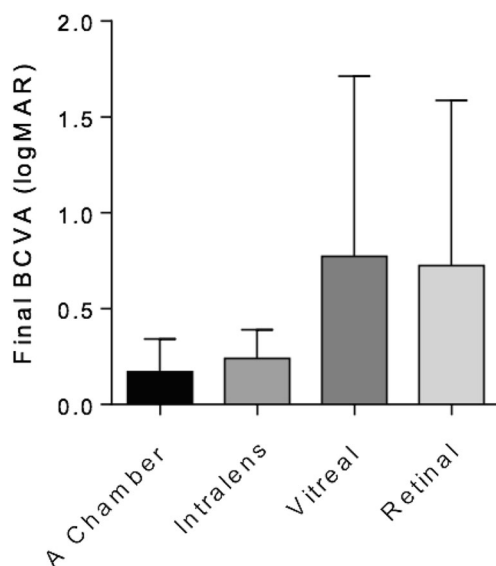


Fig. 2 Bar chart shows the final BCVA in the different location of IOFB; despite there is a trend of worse visual acuity in IOFB located on the posterior segment, this was not statistically significant

in preventing traumatic endophthalmitis. Our study had similar results to Colyer's study which had no cases of endophthalmitis in 79 eyes with penetrating ocular injury and delayed removal of IOFB (median time to IOFB removal was 21 days and mean of 38 days, with a range of 2–661 days). All patients in their series were treated with systemic and topical newer-generation fluoroquinolones [21]. The main difference with our study is median removal time of IOFB, being 5 days (range 0–22) in our series. We excluded one patient who had a delayed presentation of IOFB 270 days following the injury, as our study series aimed to assess acute presentations of IOFB.

Finally, 6 eyes (10%) had a final vision of NLP; however within this group, 4 eyes (6.55%) had initial vision of NPL. As previously reported, 8 to 33% of eyes achieve a final VA of NLP [31, 32]. Other reports described 25% of eyes with final VA of 20/200 [13, 33]. In our series, 21% of eyes had a final VA of 20/200 or worse and 57% achieved a final VA of 20/40 or better. These results concur with previous research which showed a range of 17 to 71% of eyes with final visual outcome of 20/40 or better [9, 10, 13].

Conclusion

This is the first report of the management and outcomes of IOFB in a Latin American population, allowing us to compare with series documented elsewhere in differing settings. The series emphasizes the success of the prompt use of systemic and topical antibiotics in preventing endophthalmitis. This allows the patient to be transferred to an ocular trauma center and be managed by vitreoretinal surgeons with experience in ocular trauma, obtaining better surgical results. The IOFB removal can be delayed, when there are no signs of infection, high-risk features such as vegetal IOFB, or evidence of retinal detachment, without an increase of risk of endophthalmitis and a negative impact on visual outcomes. The retrospective nature of our study requires caution in the interpretation and applicability of its results, and future controlled clinical trials could further elucidate these hypotheses.

Acknowledgments Professor David G Charteris—The research was supported by the NIHR Biomedical Research Centre at Moorfields Eye Hospital NHS Foundation Trust and UCL Institute of Ophthalmology and the NIHR Moorfields Clinical Research Facility. The views expressed are those of the author(s) and not necessarily those of the NHS, the NIHR, or the Department of Health.

Compliance with ethical standards

Conflict of interest All authors certify that they have no affiliations with or involvement in any organization or entity with any financial interest (such as honoraria; educational grants; participation in speakers' bureaus;

membership, employment, consultancies, stock ownership, or other equity interest; and expert testimony or patent-licensing arrangements), or nonfinancial interest (such as personal or professional relationships, affiliations, knowledge, or beliefs) in the subject matter or materials discussed in this manuscript.

Ethical approval This article does not contain any studies with human participants or animals performed by any of the authors.

References

1. Yeh S, Colyer M, Weichel E (2008) Current trends in the management of intraocular foreign bodies. *Curr Opin Ophthalmol* 19(3): 225–233
2. Liu C, Tong J, Li P, Li K (2016) Epidemiology and clinical outcome of intraocular foreign bodies in Hong Kong: a 13-year review. *Int Ophthalmol* 37(1):55–61
3. Patel S, Langer P, Zarbin M, Bhagat N (2012) Diagnostic value of clinical examination and radiographic imaging in identification of intraocular foreign bodies in open globe injury. *Eur J Ophthalmol* 22(2):259–268
4. Imrie F, Cox A, Foot B, MacEwen C (2007) Surveillance of intraocular foreign bodies in the UK. *Eye* 22(9):1141–1147
5. Thompson J, Parver L, Enger C, Mieler W, Liggett P (1993) Infectious endophthalmitis after penetrating injuries with retained intraocular foreign bodies. *Ophthalmology* 100(10):1468–1474
6. Kuhn F, Morris R, Witherspoon C, Heimann K, Jeffers J, Treister G (1996) A standardized classification of ocular trauma. *Graefes Arch Clin Exp Ophthalmol* 234(6):399–403
7. Kuhn F, Maisiak R, Mann L, Mester V, Morris R, Witherspoon C (2002) The ocular trauma score (OTS). *Ophthalmol Clin N Am* 15(2):163–165
8. Pieramici D, Sternberg P, Aaberg T, Bridges W, Capone A, Cardillo J et al (1997) A system for classifying mechanical injuries of the eye (globe). *Am J Ophthalmol* 123(6):820–831
9. Greven C, Engelbrecht N, Slusher M, Nagy S (2000) Intraocular foreign bodies. *Ophthalmology* 107(3):608–612
10. Zhang Y, Zhang M, Jiang C, Qiu H (2011) Intraocular foreign bodies in China: clinical characteristics, prognostic factors, and visual outcomes in 1421 eyes. *Am J Ophthalmol* 152(1):66–73.e1
11. Wickham L, Xing W, Bunce C, Sullivan P (2006) Outcomes of surgery for posterior segment intraocular foreign bodies—a retrospective review of 17 years of clinical experience. *Graefes Arch Clin Exp Ophthalmol* 244(12):1620–1626
12. Kuhn F, Pieramici DJ (2002) Intraocular foreign bodies. In: Ferenc K, Pieramici D (eds) *Ocular trauma: principles and practice*. Thieme, New York, pp 235–263
13. Chiquet C, Zech J, Gain P, Adeleine P, Trepsat C (1998) Visual outcome and prognostic factors after magnetic extraction of posterior segment foreign bodies in 40 cases. *Br J Ophthalmol* 82(7): 801–806
14. El-Asrar A, Al-Amro S, Khan N, Kangave D (2000) Visual outcome and prognostic factors after vitrectomy for posterior segment foreign bodies. *Eur J Ophthalmol* 10(4):304–311
15. Mansouri M, Faghihi H, Hajizadeh F, Rasoulnejad S, Rajabi M, Tabatabaey A et al (2009) Epidemiology of open-globe injuries in Iran. *Retina* 29(8):1141–1149
16. Guven S, Durukan A, Erdurman C, Kucukcivciloglu M (2018) Prognostic factors for open-globe injuries: variables for poor visual outcome. *Eye* 33(3):392–397
17. Ehlers J, Kunimoto D, Ittoop S, Maguire J, Ho A, Regillo C (2008) Metallic intraocular foreign bodies: characteristics, interventions, and prognostic factors for visual outcome and globe survival. *Am J Ophthalmol* 146(3):427–433.e2
18. de Souza S, Howcroft MJ (1999) Management of posterior segment intraocular foreign bodies: 14 years' experience. *Can J Ophthalmol* 34:23–29
19. Williams D, Mieler W, Abrams G, Lewis H (1988) Results and prognostic factors in penetrating ocular injuries with retained intraocular foreign bodies. *Ophthalmology* 95(7):911–916
20. Wani V, Al-Ajmi M, Thalib L, Azad R, Abul M, Al-Ghanim M, Sabti K (2003) Vitrectomy for posterior segment intraocular foreign bodies. *Retina* 23(5):654–660
21. Colyer M, Weber E, Weichel E, Dick J, Bower K, Ward T, Haller J (2007) De-layed intraocular foreign body removal without endophthalmitis during operations Iraqi freedom and enduring freedom. *Ophthalmology* 114(8):1439–1447
22. Chaudhry I, Shamsi F, Al-Harathi E, Al-Theeb A, Elzaridi E, Riley F (2007) Incidence and visual outcome of endophthalmitis associated with intraocular foreign bodies. *Graefes Arch Clin Exp Ophthalmol* 246(2):181–186
23. Punnonen E, Laatikainen L (1989) Prognosis of perforating eye injuries with intraocular foreign bodies. *Acta Ophthalmol* 67(5): 483–491
24. Hadden O, Wilson J (1990) The management of intraocular foreign bodies. *Aust N Z J Ophthalmol* 18(3):343–351
25. Lit E, Young L (2002) Anterior and posterior segment intraocular foreign bodies. *Int Ophthalmol Clin* 42(3):107–120
26. Lieb D, Scott I, Flynn H, Miller D, Feuer W (2003) Open globe injuries with positive intraocular cultures. *Ophthalmology* 110(8): 1560–1566
27. Mieler W, Ellis M, Williams D, Han D (1990) Retained intraocular foreign bodies and endophthalmitis. *Ophthalmology* 97(11):1532–1538
28. Lott M, Fuller J, Hancock H, Singh J, Singh H, Mcgwin G, Marcus D (2008) Vitreal penetration of oral moxifloxacin in humans. *Retina* 28(3):473–476
29. Hariprasad S (2006) Vitreous and aqueous penetration of orally administered moxifloxacin in humans. *Arch Ophthalmol* 124(2): 178
30. Ahmed S, Kuruvilla O, Yee D, Aggarwal H, Li Y, Edwards P et al (2014) Intraocular penetration of systemic antibiotics in eyes with penetrating ocular injury. *J Ocul Pharmacol Ther* 30(10):823–830
31. Kuhn F, Mester V, Morris R (2002) Intraocular foreign bodies. In: Kuhn F, Pieramici DJ (eds) *Ocular Trauma: Principles and Practice*. Thieme Medical Publishers Inc, New York, Stuttgart, pp 236–257
32. Yang C, Lu C, Lee F, Hsu W, Lee Y, Lee S (2010) Treatment and outcome of traumatic endophthalmitis in open globe injury with retained intraocular foreign body. *Ophthalmologica* 224(2):79–85
33. Kuhn F, Morris R, Witherspoon C, Mann L (2006) Epidemiology of blinding trauma in the United States eye injury registry. *Ophthalmic Epidemiol* 13(3):209–216

Publisher's note Springer Nature remains neutral with regard to jurisdictional claims in published maps and institutional affiliations.