



Prevalence of intronic repeat expansions in *RFC1* in Dutch patients with CANVAS and adult-onset ataxia

Fatemeh Ghorbani¹ · Jelkje de Boer-Bergsma¹ · Corien C. Verschuuren-Bemelmans^{1,7} · Maartje Pennings² · Eddy N. de Boer¹ · Berry Kremer^{3,7} · Els K. Vanhoutte⁴ · Jeroen J. de Vries^{3,7} · Raymond van de Berg⁵ · Erik-Jan Kamsteeg² · Cleo C. van Diemen¹ · Helga Westers¹ · Bart P. van de Warrenburg⁶ · Dineke S. Verbeek^{1,7}

Received: 5 May 2022 / Revised: 7 July 2022 / Accepted: 7 July 2022 / Published online: 21 July 2022
© The Author(s) 2022

Abstract

Recently, an intronic biallelic (AAGGG)_n repeat expansion in *RFC1* was shown to be a cause of CANVAS and adult-onset ataxia in multiple populations. As the prevalence of the *RFC1* repeat expansion in Dutch cases was unknown, we retrospectively tested 9 putative CANVAS cases and two independent cohorts (A and B) of 395 and 222 adult-onset ataxia cases, respectively, using the previously published protocol and, for the first time optical genome mapping to determine the size of the expanded *RFC1* repeat. We identified the biallelic (AAGGG)_n repeat expansion in 5/9 (55%) putative CANVAS patients and in 10/617 (1.6%; cohorts A + B) adult-onset ataxia patients. In addition to the AAGGG repeat motif, we observed a putative GAAGG repeat motif in the repeat expansion with unknown significance in two adult-onset ataxia patients. All the expanded (AAGGG)_n repeats identified were in the range of 800–1299 repeat units. The intronic biallelic *RFC1* repeat expansion thus explains a number of the Dutch adult-onset ataxia cases that display the main clinical features of CANVAS, and particularly when ataxia is combined with neuropathy. The yield of screening for *RFC1* expansions in unselected cohorts is relatively low. To increase the current diagnostic yield in ataxia patients, we suggest adding *RFC1* screening to the genetic diagnostic workflow by using advanced techniques that attain long fragments.

Keywords CANVAS · Adult-onset ataxia · Repeat expansion · *RFC1* · Optical genome mapping

Introduction

The cerebellar ataxias are a group of genetically heterogeneous neurodegenerative disorders, characterized by atrophy of the cerebellum that leads to the inability to control balance

and coordination [1]. Even though there are many known cerebellar ataxia-causing genes and variations, some adult patients with adult-onset cerebellar ataxia remain genetically undiagnosed [2], and studies to identify the genetic cause are ongoing. It has also been shown that patients can experience a range of clinical symptoms, from pure cerebellar ataxia to more complex clinical phenotypes including for example

Cleo C. van Diemen, Helga Westers and Bart P. van de Warrenburg have contributed equally to this work.

✉ Dineke S. Verbeek
d.s.verbeek@umcg.nl

- ¹ Department of Genetics, HPC CB50, University Medical Center Groningen, University of Groningen, P.O. Box 30001, 9700 RB Groningen, The Netherlands
- ² Department of Human Genetics, Radboud University Medical Center, Nijmegen, The Netherlands
- ³ Department of Neurology, University Medical Center Groningen, University of Groningen, Groningen, The Netherlands
- ⁴ Department of Clinical Genetics, Maastricht University Medical Center, Maastricht, The Netherlands

- ⁵ Department of Otorhinolaryngology and Head and Neck Surgery, School for Mental Health and Neuroscience, Maastricht University Medical Center, Maastricht, The Netherlands
- ⁶ Department of Neurology, Donders Institute for Brain, Cognition, and Behaviour, Radboud University Medical Center, Nijmegen, The Netherlands
- ⁷ Expertise Center Movement Disorders Groningen, University Medical Center Groningen, Groningen, The Netherlands

peripheral neuropathy [3]. One example here is CANVAS, a syndrome of adult-onset, slowly progressive ataxia associated with bilateral vestibulopathy, neuropathy, chronic cough, and autonomic dysfunction [4]. Recently, Cortese et al. reported a biallelic intronic repeat expansion in the gene encoding the replication factor C subunit 1 (*RFC1*) as a cause of CANVAS. They identified four different repeat motifs at the *RFC1* locus: the (AAAAG)₁₁, (AAAAG)_n and (AAAGG)_n repeats, which are considered benign, and the pathogenic (AAGGG)_n repeat that causes CANVAS when it occurs in a biallelic state. Interestingly, the biallelic (AAGGG)_n repeat expansion also explained quite a number of late-onset ataxia cases. Thus, this expansion can also be considered as a novel cause of late-onset ataxia.

Following these results, various studies have screened regional CANVAS and adult-onset ataxia cohorts for the biallelic (AAGGG)_n repeat expansion [5–15] (Supplementary Table 1). In all these studies, the frequency of the biallelic (AAGGG)_n repeat expansion was higher in CANVAS cohorts compared to late-onset ataxia cohorts. Additionally, novel mono-allelic repeat motifs such as (AAGAG)_n and (AGAGG)_n were identified in combination with the mono-allelic (AAGGG)_n repeat [5]. Moreover, novel biallelic (ACAGG)_n repeats were also found at the *RFC1* locus [7], but whether these previously unreported repeat motifs are the cause of the disease remains to be investigated.

In this study, we aimed to study the prevalence of the biallelic (AAGGG)_n repeat expansion in nine cases with clinically putative CANVAS and two cohorts of combined 617 adult-onset ataxia cases from the Netherlands. To determine if the patients carry the biallelic (AAGGG)_n repeat expansion, we performed *RFC1*-flanking PCR, repeat primed PCR (RP-PCR), long-range PCR for Sanger sequencing and optical genome mapping to measure the size of the repeat expansion.

Material and methods

Patient selection and characterization

Nine patients were clinically suspected of having CANVAS with the presence of adult-onset cerebellar ataxia (age at onset > 25 years), and either sensory axonal neuropathy or vestibulopathy. These nine cases were previously collected as a small series from 2015 to 2020 via the Departments of Neurology and Genetics of the University Medical Center Groningen (UMCG), the Netherlands and the ENT Department of Maastricht University Medical Center, the Netherlands.

We also included two independent cohorts of cases who were not preselected for particular clinical features related to CANVAS or *RFC1*-disease other than the presence of

adult-onset ataxia. The first cohort (A) comprised of 395 adult-onset ataxia patients, excluding those with current age < 25 years, who were referred to the Department of Genetics of the UMCG for cerebellar ataxia molecular diagnostics from years 1997 to 2017. These cases remained negative after screening for repeat expansions in the SCA1, 2, 3, 6, 7 and 17 genes and conventional variants in known dominant late-onset ataxia (SCA) genes. The second cohort (B) comprised of 222 ataxia patients with a negative dominant family history and excluding those with current age < 30 years, who had been referred to the diagnostic lab of the Human Genetics department of the Radboud University Medical Center for cerebellar ataxia diagnosis between years 2012–2018. These patients remained genetically undiagnosed after testing for either combined SCA1, 2, 3, 6, 7, and 17 analysis or for exome sequencing. The clinical and paraclinical information for patients in cohorts A and B, carrying (AAGGG)_n *RFC1* repeat expansions, was retrospectively collected from the patient reports. Unfortunately, the required information on all *RFC1*-related disease elements was not available and/or not retrievable for all cases, as these in part concerned diagnostic requests from other centers, making it difficult to access patient reports. In most of the cases in cohorts A and B with *RFC1* repeat expansions and bilateral vestibular impairment the history and/or neurologic investigation have been suggestive for vestibulopathy, without specifications on the type of vestibulopathy and how this was established. MRI scans were available for all *RFC1*-positive cases of the putative CANVAS series and for eight *RFC1*-positive cases from the adult-onset ataxia cohorts. The total number of cases who underwent an MRI scan remains unknown. For this study, no additional informed consent was requested as the test is in line with the original request for diagnostic testing.

Flanking PCR, RP-PCR, long-range PCR and Sanger sequencing

Flanking PCR was performed on the *RFC1* repeat region to identify cases with non-amplifiable products. To prevent false positives, PCR products of the *DCHS1* gene (cohort A) or the *AMELX/Y* genes (cohort B) were simultaneously generated within the same tube/well to serve as an internal control. Supplementary Table 2 lists the primers used for the amplification of the *RFC1*, *DCHS1* and *AMELX/Y* loci.

RP-PCR was performed as described by Cortese et al. [4] on the genomic DNA of patients who showed a PCR product for *DCHS1* or *AMELX/Y* but not *RFC1*. The primers used for the RP-PCR specifically targeted three different repeat sequences: I. expanded benign allele (AAAAG)_{15–200}, II. expanded benign allele (AAAGG)_{40–1000} and III. expanded pathogenic allele (AAGGG)_{400–1000}. The primers, PCR conditions and program used for the RP-PCR can be found in

Supplementary Tables 3–5. An ABI 3730xl Genetic Analyzer (Applied Biosystems, Waltham, Massachusetts, USA) was used to analyze the RP-PCR fragment lengths. The resulting data was analyzed using Genemapper software v5 (Applied Biosystems). Based on the RP-PCR, samples that seemed biallelic for the (AAGGG)_n repeat expansion were subjected to long-range PCR using the Phusion Flash High-Fidelity PCR Master Mix (Thermo Fisher Scientific, Waltham, Massachusetts, USA). For primers, PCR conditions and program see Supplementary Tables 2, 6 and 7, respectively. Sanger sequencing was performed on the PCR products to analyze the sequence motif of the repeats. The start of the repeat motif is based on a consensus reference sequence preceding the repeat motif. Figure 1 shows the complete workflow.

Optical genome mapping

Optical genome mapping (Bionano Genomics, San Diego, CA, USA) was used to determine the size of the repeat expansion in *RFC1*. Fresh EDTA blood samples were drawn from patients and immediately frozen at -80°C . The DNA isolation, labelling and optical mapping procedure was performed by the Bionano Services Lab (Clermont-Ferrand, France). For each sample, a minimum of 650 μl frozen blood was used to purify ultra-high molecular weight gDNA, following the Bionano Prep SP Frozen Human Blood DNA Isolation Protocol (Bionano Genomics). DNA molecules were labelled using the Direct Label and Stain DNA Labelling Kit (Bionano Genomics). Labelled gDNA samples were loaded on Saphyr chips using the Saphyr System User Guide, following the manufacturer's instructions (Bionano Genomics). The Saphyr chips were run to reach a minimum yield of 310 Gbp for de novo assembly. The de novo assembly and Variant Annotation Pipeline were executed on Bionano Solve software V3.7. Reporting and direct visualization of structural variants were performed on Bionano Access V1.7. The effective coverage of the assembly was about 50 \times , and

no filtering was used. The Bionano Solve software V3.7 was used to determine the size of the repeat. While the DLE-1 enzyme does not directly label the individual repeats, the software estimates repeat lengths based on the interval between labels flanking the repeats. The minimum resolution for sizing the repeat expansions is 500 bp, which corresponds to 100 repeats for the AAGGG motif. The *RFC1* intronic AAGGG repeat size (chr4:39350045-39350103 (hg19)) was manually reviewed in the Bionano Access V1.7 genome browser.

Results

To study the prevalence of the biallelic (AAGGG)_n *RFC1* repeat expansion in putative CANVAS and adult-onset ataxia patients from the Netherlands, we used the workflow illustrated in Fig. 1. Eight (89%) putative CANVAS patients as well as 59 (14.9%) and 33 (14.9%) adult-onset ataxia patients from cohorts A and B, respectively, did not have an amplifiable *RFC1* product (data not shown) and were suspected of carrying a biallelic *RFC1* expansion, but with a yet unknown sequence motif. In those cases, we performed RP-PCR to define the nature of the repeat expansions (I, II or III, as described in Materials and Methods). The RP-PCR analysis revealed five putative CANVAS and twelve adult-onset ataxia cases (cohorts A and B) to be suspected carriers of the biallelic expanded (AAGGG)_n repeat (III) (Fig. 1). The other patients with a non-amplifiable *RFC1* allele and a negative RP-PCR for the (AAGGG)_n repeat expansion carried the expanded benign allele (AAAAG)_{15–200} or (AAAGG)_{40–1000}. However, studies have shown that even with a positive RP-PCR for the (AAGGG)_n repeat expansion, other sequence motifs might also be present at this locus [5]. Thus, follow-up needed to be performed with Sanger sequencing of the first and last 150 base pairs of the repeat to confirm the sequence of the motif. Sanger sequencing confirmed the presence of

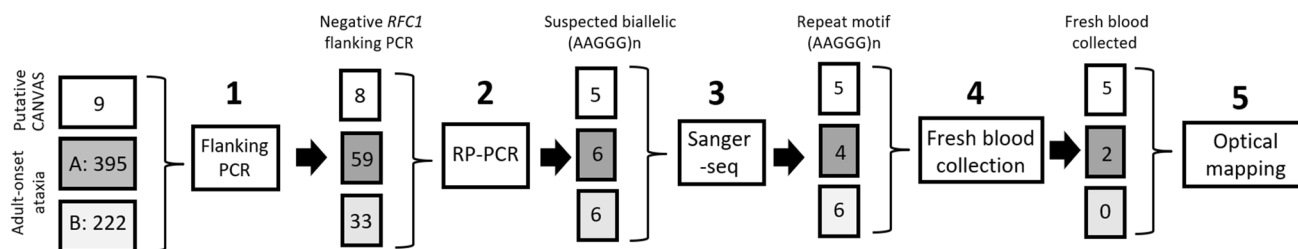


Fig. 1 Diagram showing the workflow and the number of patients from each cohort at the start of the study to identify patients with *RFC1* (AAGGG)_n expanded alleles. The study started with 3 cohorts including a putative CANVAS cohort consisting of nine cases, and cohorts A and B with 395 and 222 adult-onset ataxia cases, respectively. The subsequent steps included: (1) *RFC1*-flanking PCR

to identify cases with a non-amplifiable *RFC1* region, (2) repeat primed-PCR (RP-PCR) to identify patients suspected of carrying biallelic (AAGGG)_n expansions, (3) Sanger sequencing (Sanger-Seq) to read the repeat motifs and (4) collect fresh blood and (5) optical genome mapping to determine the size of the repeat expansion

the AAGGG motif on both expanded *RFC1* alleles in all putative CANVAS patients, while the AAGGG motif was detected in both expanded alleles in ten adult-onset ataxia patients (Fig. 1). Two patients (patients 10 and 11) from adult-onset ataxia cohort A carried a putative mono-allelic (GAAGG)_n repeat in combination with the mono-allelic (AAGGG)_n repeat (Table 1).

To determine the length of the expanded *RFC1* repeats, we performed optical genome mapping (Bionano Genomics) for five putative CANVAS cases and two adult-onset ataxia cases from cohort A (Fig. 1 and Table 1). Optical genome mapping confirmed the presence of expanded *RFC1* alleles in all 7 cases. Overall, the *RFC1* repeat size ranged from 800 to 1299 AAGGG repeats (Table 1). Notably, six cases showed expanded biallelic (AAGGG)_n alleles of similar size, but this may reflect a technical limitation of the optical genome mapping technology.

Clinical features of patients with expanded *RFC1* repeats

To assess the presence of the main clinical features of CANVAS in the 17 patients with expanded (AAGGG)_n repeats, we retrospectively collected the clinical data, but unfortunately not for every patient all the required information was available (Table 1).

Two of the cases (numbers 1 and 3) from our historically collected, putative CANVAS cohort did not present with overt bilateral vestibulopathy, in addition to cerebellar ataxia and neuropathy, and as such did not fulfill all the required diagnostic criteria of CANVAS [7]. Likewise, two adult-onset ataxia cases (numbers 6 and 17) had cerebellar ataxia with neuropathy and bilateral vestibular impairment but were not previously labelled as CANVAS. For the remaining cases, mostly presented with a slowly progressive cerebellar syndrome and a sensory axonal neuropathy. However, two cases (numbers 7 and 10) presented with a sensorimotor axonal neuropathy. Cough was reported in some cases and cerebellar atrophy on MRI was quite prevalently seen. The unifying clinical picture linked to *RFC1* repeat expansions in our study is an adult-onset slowly progressive cerebellar ataxia combined with a mostly sensory neuropathy, as well as bilateral vestibular impairment in some cases.

Discussion

This is the first study to examine the *RFC1* intronic repeat region in a historically collected putative Dutch CANVAS and two adult-onset ataxia cohorts and use optical genome mapping (Bionano Genomics) to determine the size of the expanded *RFC1* repeat length. We found the previously reported biallelic (AAGGG)_n repeat expansion in five of

the nine putative CANVAS patients (55%) and in 10 of the 617 adult-onset ataxia patients (1.6%, cohorts A + B). Five patients with biallelic (AAGGG)_n repeat expansions were retrospectively clinically diagnosed with full-blown CANVAS based on the presence of cerebellar ataxia, bilateral vestibulopathy, and sensory neuropathy, with the note that data on vestibular investigations were not available for many cases with an expanded *RFC1* repeat. Therefore, the number of cases with CANVAS diagnosis could be actually higher. This retrospective study also included genetic diagnostic requests from other centers which has led to missing detailed phenotypic data. Consequently, two cases from the small, historic series of putative CANVAS patients did not fulfil all diagnostic criteria for CANVAS, and two CANVAS diagnoses were not labelled as such in the adult-onset ataxia cohorts. Additionally, two patients with an expanded *RFC1* repeat presented with a sensorimotor neuropathy that was also recently described by others who reported *RFC1* repeat expansions as the cause of sensorimotor neuropathy in 3/138 cases [13]. In contrast, a large study by Curro et al., identified *RFC1* repeat expansions only in sensory neuropathy cases and not in their cohort of 100 cases with sensorimotor neuropathy [14]. Nevertheless, our work and that of others showed that the clinical spectrum associated with *RFC1* repeat expansions is broader than previously reported and patients may present with a mixed sensorimotor axonal neuropathy.

The biallelic (AAGGG)_n expansion was the repeat configuration found in all putative CANVAS patients and in most adult-onset ataxia cases. However, in 2 of the 12 adult-onset ataxia cases with a suspected biallelic (AAGGG)_n repeat expansion, we also observed a putative mono-allelic (GAAGG)_n repeat expansion in combination with the mono-allelic expanded (AAGGG)_n repeat. The size of the (AAGGG)_n repeat expansion ranged from 4 to 7 kb corresponding to 800–1299 pentanucleotide repeats, consistent with the previously reported repeat range.

Our diagnostic yield (55%) for the biallelic (AAGGG)_n repeat expansion in the small series of putative CANVAS patients is quite similar to that reported in previous studies, where biallelic (AAGGG)_n repeat expansions were reported to lead to a genetic diagnosis in 68 to 100% of patients suspected to have CANVAS [4, 11]. In contrast, in our two adult-onset ataxia cohorts, the prevalence of the biallelic (AAGGG)_n repeat expansion in *RFC1* is in the lower range of previously reported yields (1.6% vs 0–22%) [4, 9, 15]. The variability in diagnostic yield reported for adult/late-onset ataxia is likely due to the different genetic backgrounds of the cohorts, which range from European to Asian, North and South America, and possibly to the differing inclusion criteria between the studied cohorts. Additionally, our adult-onset ataxia cohorts were not preselected on any clinical feature other than cerebellar ataxia. Also, one of our cohorts

Table 1 Clinical features of patients with expanded *RFC1* alleles

| Cohort | Number | Sex | AaO | F/S | Repeat sequence | Repeat size (bp) | Number of repeats | Progression ataxia | Clinical signs of neuropathy | Nerve conduction studies abnormal | MRI scan | Cerebellar syndrome | Dysautonomia | Bilateral vestibular impairment | Cough | Full-blown CANVAS | |
|--|--------|-----|-----|-----|------------------------------------|------------------|-------------------|--------------------|------------------------------|-----------------------------------|-------------------------|---------------------|--------------|---------------------------------|-------|-------------------|-----|
| Historically collected putative CANVAS | 1 | M | 30 | F | AAGGG (biallelic) | 6498/5880 | 1299/1176 | Slowly | Yes | Yes (S) | Mild cerebellar atrophy | Yes | - | - | Yes | - | |
| | 2 | F | 64 | F | AAGGG (biallelic) | 4003/4003 | 800/800 | Slowly | Yes | Yes (S) | Mild cerebellar atrophy | Yes | - | Yes | - | Yes | |
| | 3 | F | 65 | F | AAGGG (biallelic) | 4820/4820 | 964/964 | Slowly | Yes | No | Mild cerebellar atrophy | Yes | No | No | No | No | |
| | 4 | F | >50 | F | AAGGG (biallelic) | 4087/4087 | 817/817 | Slowly | Yes | - | No major abnormalities | Yes | Yes | Yes | Yes | Yes | Yes |
| | 5 | F | >60 | F | AAGGG (biallelic) | 4281/4281 | 856/856 | Slowly | Yes | - | Mild cerebellar atrophy | Yes | No | Yes | - | - | Yes |
| Adult-onset ataxia cohort A | 6 | F | 47 | S | AAGGG (biallelic) | 4750/4750 | 950/950 | Slowly | Yes | Yes (S) | No major abnormalities | Yes | No | Yes | Yes | Yes | Yes |
| | 7 | M | 55 | S | AAGGG (biallelic) | 4451/4451 | 890/890 | Slowly | Yes | Yes (S/M) | No major abnormalities | Yes | - | No | Yes | Yes | No |
| | 8 | M | 70 | F | AAGGG (biallelic) | - | - | Slowly | Yes | Yes (S) | Mild cerebellar atrophy | Yes | - | - | - | - | - |
| | 9 | M | 60 | F | AAGGG (biallelic) | - | - | Slowly | - | - | - | Yes | - | - | - | - | - |
| | 10 | M | 45 | S | Allele 1: AAGGG Allele 2: GAAGG | - | - | Slowly | Yes | Yes (S/M) | Mild cerebellar atrophy | Yes | No | No | - | - | No |
| | 11 | F | - | - | Allele 1: AAGGG Allele 2: GAAGG | - | - | - | - | - | - | Yes | - | - | - | - | - |

Table 1 (continued)

| Cohort | Number | Sex | AaO | F/S | Repeat sequence | Repeat size (bp) | Number of repeats | Progression ataxia | Clinical signs of neuropathy | Nerve conduction studies | MRI scan | Cerebellar syndrome | Dysautonomia | Bilateral vestibular impairment | Cough | Full-blown CANVAS |
|-----------------------------|--------|-----|-----|-----|-------------------|------------------|-------------------|--------------------|------------------------------|--------------------------|---------------------------------|---------------------|--------------|---------------------------------|-------|-------------------|
| Adult-onset ataxia cohort B | 12 | F | 43 | S | AAGGG (biallelic) | – | – | Slowly | Yes | Yes (S) | No major abnormalities | Yes | No | – | – | – |
| | 13 | M | 53 | F | AAGGG (biallelic) | – | – | Slowly | Yes | – | Cerebellar atrophy | Yes | No | – | Yes | – |
| | 14 | M | 48 | S | AAGGG (biallelic) | – | – | Slowly | Yes | Yes (S) | Cerebellar atrophy | Yes | No | – | Yes | – |
| | 15 | F | – | – | AAGGG (biallelic) | – | – | – | Yes | – | – | – | – | – | – | – |
| | 16 | M | – | – | AAGGG (biallelic) | – | – | – | Yes | – | – | – | – | – | – | – |
| | 17 | M | 63 | F | AAGGG (biallelic) | – | – | Slowly | Yes | – | Cerebral and cerebellar atrophy | Yes | Yes | Yes | – | Yes |

No fresh blood samples could be obtained for patients 8–17 to determine the size of the repeat with the optical mapping technique

– unknown/data not available, AaO: age at onset, F: familial, S: sporadic, (S): Sensory, (M): Motor

(A) was not preselected for solely sporadic cases, which may have led to a lower diagnostic yield (0.5%) compared to a reported cohort preselected for sporadic cases [4, 15]; still, the yield in cohort B, in which dominant cases had been excluded, was only slightly higher (2.7%).

In all studies, including ours, that have examined both (putative) CANVAS and adult-onset ataxia cases for the biallelic (AAGGG)_n repeat expansion in *RFC1*, the frequency of the biallelic (AAGGG)_n repeat expansion is higher in CANVAS cases than in adult-onset ataxia patients. This could be due to the different clinical manifestations of the patients from the CANVAS cohort and the adult-onset ataxia cohorts. For example, despite the fact that data on the complete clinical features of CANVAS were not available for all the patients enrolled in our study, most of the putative CANVAS patients had clinically full-blown CANVAS, whereas documented typical CANVAS was less prevalent in the adult-onset ataxia patients. The identification of biallelic (AAGGG)_n *RFC1* expansions in our adult-onset ataxia cohort clearly indicates the need to screen adult-onset ataxia patients for expanded *RFC1* repeats when no other genetic cause is found in other known ataxia genes, and particularly when adult-onset ataxia is combined with sensory neuropathy.

Additionally, we identified a putative mono-allelic (GAAGG)_n repeat expansion in combination with a mono-allelic (AAGGG)_n repeat expansion in two patients. Marker analysis did not show any familial relationship between these two patients (data not shown). Although, the presence of the same motifs in two independent referrals may increase the likelihood that this repeat motif is pathogenic, we should further investigate the configuration of the *RFC1* repeat in the general population and additional adult-onset ataxia cases to be able to make a conclusion. Additionally, this (GAAGG)_n repeat motif may be the result of the insert of a single nucleotide G preceding the original classical repeat motif AAGGG and if this is considered, the repeat motif can be read as a pathogenic (AAGGG)_n repeat expansion. In all, our results together with the other previously reported repeat motifs ((AAGAG)_n/(AGAGG)_n and (ACAGG)_n repeat expansions [5, 7]) indicate that this repeat region can be variable and that novel disease-causing repeat configurations may be revealed over time.

In this work, we successfully used optical genome mapping [16] to replace the labor intensive and time-consuming Southern blot, which has been the “gold” standard for sizing repeat expansions up to now [17]. The number of AAGGG units found with this technique in our patients (800–1299) is consistent with the previously reported size of *RFC1* repeat units (> 400) (Supplementary Table 1). The value of optical genome mapping in sizing repeat expansions in human clinical applications has already been proven by others [18], but this technique has not yet been used for the sizing

of expanded *RFC1* repeats. Furthermore, a recent study reported the use of long-read sequencing (Oxford Nanopore Technologies, Oxford, UK) to simultaneously identify, size and read the motif of the *RFC1* repeat [19]. We speculate that this technology will very likely replace the current diagnostic workflow for repeat expansion disorders in the future [20].

In conclusion, we here confirm that the *RFC1* repeat expansion explains a number of adult-onset ataxia cases who present with (incomplete) key clinical features of CANVAS. Additionally, the repeat has a dynamic nature and can have different configurations, even with a positive RP-PCR for the (AAGGG)_n repeat motif, and thus patients with a “positive” RP-PCR should be followed up with Sanger sequencing. To improve the current diagnostic practice, patients with genetically unexplained, slowly progressive adult-onset ataxia and sensory or sensorimotor axonal neuropathy should be screened for the presence of (AAGGG)_n repeat expansions in the *RFC1* gene.

Supplementary Information The online version contains supplementary material available at <https://doi.org/10.1007/s00415-022-11275-9>.

Acknowledgements We sincerely thank all the patients for their participation in this study. We thank Kate Mc Intyre for proofreading the manuscript.

Author contributions FG, EJK, BvdW, CD, HW and DV designed the work. JB-B and MP performed the experiments. FG, EB, MP and EJK analyzed the data. DV, CD and HW supervised the study. CV-B, BK, JV, RB, and BvdW collected and clinically assessed the patients. FG took the lead in writing the manuscript. EJK, BvdW, DV, CD and HW revised the work for intellectual content. All authors provided critical feedback and helped shape the research, analysis and manuscript.

Funding Rosalind Franklin Fellowship by University Medical Center of Groningen (DSV), PhD grant by the GSMS of the University of Groningen (FG).

Declarations

Conflicts of interest The authors report no conflict of interest.

Open Access This article is licensed under a Creative Commons Attribution 4.0 International License, which permits use, sharing, adaptation, distribution and reproduction in any medium or format, as long as you give appropriate credit to the original author(s) and the source, provide a link to the Creative Commons licence, and indicate if changes were made. The images or other third party material in this article are included in the article's Creative Commons licence, unless indicated otherwise in a credit line to the material. If material is not included in the article's Creative Commons licence and your intended use is not permitted by statutory regulation or exceeds the permitted use, you will need to obtain permission directly from the copyright holder. To view a copy of this licence, visit <http://creativecommons.org/licenses/by/4.0/>.

References

- Jayadev S, Bird TD (2013) Hereditary ataxias: overview. *Genet Med* 15(9):673–683. <https://doi.org/10.1038/gim.2013.28>
- de Silva RN, Vallortigara J, Greenfield J, Hunt B, Giunti P, Hadjivassiliou M (2019) Diagnosis and management of progressive ataxia in adults. *Pract Neurol* 19(3):196–207. <https://doi.org/10.1136/practneurol-2018-002096>
- Lindsay, K. W., Bone, I., & Fuller, G. (2010). *Neurology and neurosurgery illustrated e-book*. Elsevier Health Sciences.
- Cortese A, Simone R, Sullivan R, Vandrovцова J, Tariq H, Yau WY et al (2019) Biallelic expansion of an intronic repeat in RFC1 is a common cause of late-onset ataxia. *Nat Genet* 51(4):649–658. <https://doi.org/10.1038/s41588-019-0372-4>
- Akçimen F, Ross JP, Bourassa CV, Liao C, Rochefort D, Gama MTD et al (2019) Investigation of the RFC1 repeat expansion in a Canadian and a Brazilian ataxia cohort: identification of novel conformations. *Front Genet*. <https://doi.org/10.3389/fgene.2019.01219>
- Beecroft SJ, Cortese A, Sullivan R, Yau WY, Dyer Z, Wu TY et al (2020) A Māori specific RFC1 pathogenic repeat configuration in CANVAS, likely due to a founder allele. *Brain* 143(9):2673–2680. <https://doi.org/10.1093/brain/awaa203>
- Tsuchiya M, Nan H, Koh K, Ichinose Y, Gao L, Shimozono K et al (2020) RFC1 repeat expansion in Japanese patients with late-onset cerebellar ataxia. *J Hum Genet* 65(12):1143–1147. <https://doi.org/10.1038/s10038-020-0807-x>
- Syriani DA, Wong D, Andani S, De Gusmao CM, Mao Y, San-youra M et al (2020) Prevalence of RFC1-mediated spinocerebellar ataxia in a North American ataxia cohort. *Neuro Genet*. <https://doi.org/10.1212/NXG.0000000000000440>
- Fan Y, Zhang S, Yang J, Mao CY, Yang ZH, Hu ZW et al (2020) No biallelic intronic AAGGG repeat expansion in RFC1 was found in patients with late-onset ataxia and MSA. *Parkinsonism Relat Disord* 73:1–2. <https://doi.org/10.1016/j.parkreldis.2020.02.017>
- Cortese A, Tozza S, Yau WY, Rossi S, Beecroft SJ, Jaunmuktane Z et al (2020) Cerebellar ataxia, neuropathy, vestibular areflexia syndrome due to RFC1 repeat expansion. *Brain* 143(2):480–490. <https://doi.org/10.1093/brain/awz418>
- Traschütz A, Cortese A, Reich S, Dominik N, Faber J, Jacobi H et al (2021) Natural history, phenotypic spectrum, and discriminative features of multisystemic RFC1 disease. *Neurology* 96(9):e1369–e1382. <https://doi.org/10.1212/WNL.00000000000011528>
- Costales M, Casanueva R, Suárez V, Asensi JM, Cifuentes GA, Diñeiro M et al (2021) CANVAS: a new genetic entity in the otorhinolaryngologist's differential diagnosis. *Otolaryngol Head Neck Surg*. <https://doi.org/10.1177/01945998211008398>
- Tagliapietra M, Cardellini D, Ferrarini M, Testi S, Ferrari S, Monaco S et al (2021) RFC1 AAGGG repeat expansion masquerading as Chronic Idiopathic Axonal Polyneuropathy. *J Neurol* 268(11):4280–4290. <https://doi.org/10.1007/s00415-021-10552-3>
- Currò R, Salvalaggio A, Tozza S, Gemelli C, Dominik N, GalassiDeforie V et al (2021) RFC1 expansions are a common cause of idiopathic sensory neuropathy. *Brain* 144(5):1542–1550. <https://doi.org/10.1093/brain/awab072>
- Montaut S, Diedhiou N, Fahrer P, Marelli C, Lhermitte B, Robelin L et al (2021) Biallelic RFC1-expansion in a French multicentric sporadic ataxia cohort. *J Neurol* 268(9):3337–3343. <https://doi.org/10.1007/s00415-021-10499-5>
- Yuan Y, Chung CYL, Chan TF (2020) Advances in optical mapping for genomic research. *Comput Struct Biotechnol J* 18:2051–2062. <https://doi.org/10.1016/j.csbj.2020.07.018>
- Dominik N, GalassiDeforie V, Cortese A, Houlden H (2021) CANVAS: a late onset ataxia due to biallelic intronic AAGGG expansions. *J Neurol* 268(3):1119–1126. <https://doi.org/10.1007/s00415-020-10183-0>
- Iqbal MA, Broeckel U, Levy B, Skinner S, Sahajpal NS, Rodriguez V et al (2021) Multi-site technical performance and concordance of optical genome mapping: constitutional postnatal study for SV, CNV, and repeat array analysis. *medRxiv*. <https://doi.org/10.1101/2021.12.27.21268432>
- Nakamura H, Mitsuhashi S, Miyatake S, Katoh K, Frith MC, Asano T et al (2020) Long-read sequencing identifies the pathogenic nucleotide repeat expansion in RFC1 in a Japanese case of CANVAS. *J Hum Genet* 65(5):475–480. <https://doi.org/10.1038/s10038-020-0733-y>
- Stevanovski I, Chintalaphani SR, Gamaarachchi H, Ferguson JM, Pineda SS, Scriba CK et al (2021) Comprehensive genetic diagnosis of tandem repeat expansion disorders with programmable targeted nanopore sequencing. *medRxiv*. <https://doi.org/10.1126/sciadv.abm5386>