

An unusual case of acquired pedophilic behavior following compression of orbitofrontal cortex and hypothalamus by a *Clivus Chordoma*

Giuseppe Sartori¹ · Cristina Scarpazza^{1,2} · Sara Codognotto¹ · Pietro Pietrini^{3,4}

Received: 5 February 2016/Revised: 16 April 2016/Accepted: 22 April 2016/Published online: 9 May 2016
© Springer-Verlag Berlin Heidelberg 2016

Dear Sirs,

Structural brain alterations rarely lead to changes in sexual orientation. Acquired pedophilia has been reported following lesions in the frontal and temporal lobes in males [1]. Here we report a case in which onset of paedophilia was the striking symptom of a *Clivus Chordoma*, a rare, slow-growing neoplasm originating from the bone in the skull base [2], that compressed the hypothalamus and the orbitofrontal cortex (OFC).

A 64-year-old male pediatrician was caught while enacting sexually inappropriate behavior towards a female child in a kindergarten doctor's office. Paedophilic urges were carried out in a disorganized and risky manner (e.g., leaving the office door wide open). Upon arrest, the pediatrician appeared not to realize the severity of the moral and social disvalue of his behavior nor its legal implications. History was negative for relevant medical,

neurological or psychiatric disorders, including abnormal (sexual) behavior. He had been married for over 40 years, had two children and was a highly respected pediatrician. On neurological and psychiatric examinations, conducted while he was at house arrest, he showed asymmetrical brisk motor reflexes, along with symptoms and signs suggestive of optic chiasm compression (tunnel vision and diplopia) and frontal lobe dysfunction, including pathological crying, dis-inhibition, easy irritability, childish and obsessive-compulsive behaviors, and impairments in emotion attribution, moral reasoning and abstract thinking. According to his wife, easy frustration and irritability had slowly begun about 2 years earlier, followed by subtle behavioral dis-inhibition. For instance, while traveling with his wife, the patient would steal postcards from exhibitors in museum shops. One night, he was surfing adult pornography on the web, completely worrisome of being caught by his wife. Neuropsychological testing revealed impairments in emotion attribution, moral reasoning and abstract thinking. MRI scan examination revealed the presence of a 4 × 3 cm *Clivus Chordoma* (Fig. 1) that displaced the pituitary gland and compressed the OFC, the optic chiasm and the hypothalamus. All the behavioral, neurological and neuropsychological abnormalities, including paedophilic urges, receded following surgical resection of the tumor (Table S1 and S2 in Supplementary Information for neuropsychological evaluations).

This is the first case of pedophilia emerging as a consequence of an intracranial bone tumor that affected OFC and hypothalamus concomitantly. Indeed, because of its dimensions and location, the tumor could well account for all the observed symptoms and signs. Optic chiasm compression explained the diplopia and the tunnel vision; alteration of hypothalamus functioning resulted in abnormal sexual drives [3] and the OFC compression accounts

G. Sartori and C. Scarpazza equally contributed to the work.

Electronic supplementary material The online version of this article (doi:10.1007/s00415-016-8143-y) contains supplementary material, which is available to authorized users.

✉ Giuseppe Sartori
giuseppe.sartori@unipd.it

¹ Department of General Psychology, University of Padua, Via Venezia n 8, 35131 Padua, PD, Italy

² Department of Psychosis Studies, King's College Health Partners, King's College London, De Crespigny Park, London SE5 8AF, UK

³ Laboratory of Clinical Biochemistry and Molecular Biology, University of Pisa, Pisa, Italy

⁴ Clinical Psychology Branch, Pisa University Hospital, Pisa, Italy

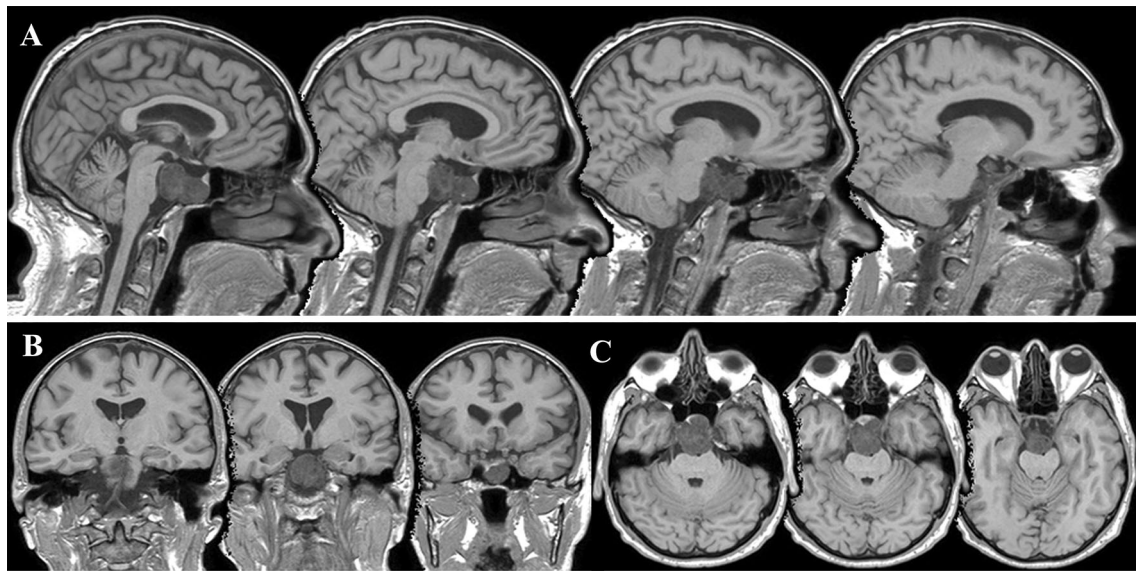


Fig. 1 Patient's structural MRI scan exam in the sagittal (a), coronal (b) and axial (c) projections

for the impairment in emotional recognition, moral reasoning [4] and impulse inhibition [5]. The *restitutio ad integrum* after neurosurgery proved the causal link between the *Clivus Chordoma* and the whole clinical picture, including pedophilic behavior. This interpretation is in line with the neurophenomenological model of sexual arousal [1], which considers the hypothalamus to be involved in the motivational and neuroendocrine components, and the OFC in the inhibitory component of the behavioral expression of sexual arousal. However, patients with frontal lobe lesions who have inhibitory deficits frequently have inappropriate release of sexual behavior (which usually is not manifested as a change in sexual orientation), but they do not necessarily engage in sexually deviant acts. We suggest that in this patient, the concomitant alteration of both hypothalamus, which caused the alteration of sexual orientation, and OFC, which caused the dis-inhibition, lead to the overt expression of deviant sexual urges, while the alteration of one of these structures alone would not have caused the emergence of a paedophilic disorder.

This case may have social and forensic implications: paedophilia is among the most hideous behaviors condemned by society. Identification of brain alterations that

may potentially cause paedophilic behaviors may question the individual legal responsibility.

Compliance with ethical standards

Conflicts of interest All the authors declare that no conflict of interest exists.

Ethical standards The patient described provided written informed consent.

References

1. Mohnke S, Muller S, Amelung T, Kruger TH, Ponseti J, Schiffer B, Walter M, Beier KM, Walter H (2009) Brain alterations in paedophilia: a critical review. *Prog Neurobiol* 122:1–23
2. Harbour JW, Lawton MT, Criscuolo GR, Holliday MJ, Mattox DE, Long DM (1991) Clivus Chordoma: a report of 12 recent cases and review of the literature. *Skull Base Surg* 1(4):200–206
3. Brunetti M, Babiloni C, Ferretti A (2008) Hypothalamus, sexual arousal and psychosexual identity in human males: a functional magnetic resonance imaging study. *Eur J Neurosci* 27(11):2291–2297
4. Fumagalli M, Priori A (2012) Functional and clinical neuroanatomy of morality. *Brain* 135:2006–2021
5. Bari A, Robbins TW (2013) Inhibition and impulsivity: behavioral and neural basis of response control. *Prog Neurobiol* 108:44–79