

# Anesthesia for Advanced Bronchoscopic Procedures: State-of-the-Art Review

Basavana G. Goudra<sup>1,5</sup> · Preet Mohinder Singh<sup>2</sup> · Anuradha Borle<sup>2</sup> ·  
Nahla Farid<sup>3</sup> · Kassem Harris<sup>4</sup>

Received: 13 February 2015 / Accepted: 17 April 2015 / Published online: 29 April 2015  
© Springer Science+Business Media New York 2015

**Abstract** The bronchoscopic procedures have seen a remarkable increase in both numbers and complexity. Although many anesthesia providers have kept pace with the challenge, the practice is varied and frequently sub-optimal. Shared airway during bronchoscopy poses unique challenges. The available reviews have tried to address this lacuna; however, these have frequently dealt with the technical aspects of bronchoscopy than anesthetic challenges. The present review provides evidence-based management insights into anesthesia for bronchoscopy—both flexible and rigid. A systematic approach toward pre-procedural evaluation and risk stratification is presented. The possible anatomical and physiological factors that can influence the outcomes are discussed. Pharmacological principles guiding sedation levels and appropriate selection

of sedatives form the crux of safe anesthetic management. The newer and safer drugs that can have potential role in anesthesia for bronchoscopy in the near future are discussed. Ventilatory strategies during bronchoscopy for prevention of hypoxia and hypercarbia are emphasized.

**Keywords** Anesthesia for bronchoscopy · Sedation for bronchoscopy · Sedation for interventional pulmonology · Sedatives for bronchoscopy · Ventilation during bronchoscopy

## Background

The benefits of technological advancements in fiber optics, ultrasound, and fluoroscopy are nowhere more evident than in pulmonary medicine. Since the first invention of flexible fiberoptic bronchoscope in 1968, the bronchoscopic interventional procedures have grown in both numbers and complexity. Many of these procedures have specific anesthesia requirements for a successful completion. The degree of noxious stimulation caused by the insertion and manipulation of a bronchoscope (both flexible and rigid) is often similar to a surgical incision. Providing appropriate degree of anesthesia to meet the procedural needs and yet allow a safe and rapid recovery is a unique challenge limited mainly to “interventional pulmonary suite”. With the increase in caseloads, most of the tertiary centers are now opting for a dedicated state-of-the-art pulmonary suites with dedicated anesthesia teams.

As providers are more concerned with patient satisfaction than ever before, the outcomes are not only adjudged by therapeutic end points but also by patients’ overall experience. Evaluations based on patient satisfaction after bronchoscopy clearly indicate that utilization of anesthesia/deep sedation services for endoscopic procedures improves

---

✉ Basavana G. Goudra  
BasavanaGouda.Goudra@uphs.upenn.edu

Preet Mohinder Singh  
Preetrajpal@gmail.com

Anuradha Borle  
Andromeda85@gmail.com

<sup>1</sup> Department of Anesthesiology and Critical Care Medicine, Hospital of the University of Pennsylvania, Philadelphia, PA, USA

<sup>2</sup> Department of Anesthesia, All India Institute of Medical Sciences, New Delhi, India

<sup>3</sup> Russels Hall Hospital, Dudley, West Midlands DY1 2HQ, UK

<sup>4</sup> Department of Medicine, University of Pennsylvania Hospital, Philadelphia, PA, USA

<sup>5</sup> Perelman School of Medicine, University of Pennsylvania, Philadelphia, PA, USA

acceptability [1]. Many therapeutic and diagnostic procedures require undivided attention of the bronchoscopist and an immobile patient. An anesthesia provider who understands the intricacies of this environment would be an invaluable member of the team. Invention of new intravenous agents coupled with modern delivery systems has benefited all concerned. With this in mind, it is appropriate to have a good understanding of the anesthetic aspects of this evolving field. It is hoped that readers can use the knowledge as the basis of their clinical practice.

### The Debate: to Sedate or Not to Sedate

Trials conducted during the early phase of fiberoptic bronchoscopy did not show any additional benefits for use of sedation during these procedures [2]. The outcomes were primarily measured in terms of adverse events during the procedure and results comparing sedation versus no sedation were equivocal. It led to the belief that sedation was an unnecessary burden that adds to potential costs and might jeopardize patient safety. However, studies comparing sedation with placebo did not substantiate the above findings and presently, sedation is well accepted [3]. With accumulating experience and further trials, it is now accepted that using sedation during these procedures improves patient satisfaction and increases the procedural success [4, 5]. As a result, the utilization of sedation during these procedures increased from 51 % in 1991 to 73 % in 2003 [6, 7]. In addition to satisfaction, studies have reported reduced cough and laryngospasm in sedated patients [8]. Other potential benefits include shortening of the procedure duration which has an economic advantage [9, 10]. The British Thoracic Society guidelines on diagnostic flexible bronchoscopy now recommend offering sedation to all patients undergoing bronchoscopy unless a specific contraindication to sedation exists [11]. The evolving trends with regard to quality of sedation favor the use of propofol-based sedation for bronchoscopy [12]. As per ASA (American Society of Anesthesiologists) and Royal College of Anesthesiologists' (Great Britain) directive, propofol-based sedation by non-anesthesiologist mandates expertise in airway skills.

### Sedation and Topical Anesthesia

Patients presenting for bronchoscopy might have limited cardio-pulmonary reserve, with even minimal sedation producing apnea and rapid oxygen desaturation. Many present for relatively non-stimulating procedures like inspection of tracheobronchial tree. This subset of patients

may be suitable for topical anesthesia along with appropriate doses of anxiolytics. Topical anesthesia prior to procedure suppresses cough and diminishes the need for sedatives. Experience exists with the use of cocaine (4 %), tetracaine (1 %), benzocaine (20 %), and most extensively with Lidocaine (1–10 %). Caution is advised while using benzocaine and tetracaine as reports of methemoglobinemia exist when higher doses were used for bronchoscopy [13]. Lidocaine is the agent of choice and has been delivered using multiple methods including nebulization, “spray as you go”, and transtracheal injections. Studies suggest that doses of up to 8.4 mg/kg mg can be safely used for anesthetizing airways prior to bronchoscopy [11]. Transtracheal/transcricoid local anesthetic airway injections can be effective in the hands of skilled practitioners for specific indications. Optimal level of topical anesthesia can be achieved, thereby increasing the patient acceptability and safety [14].

Although topical anesthesia is effective in blunting sensory response to bronchoscope insertion, it will not alleviate patient anxiety, enhance patient co-operation, or mitigate patient's movement. These elements are desirable during bronchoscopy and thus may necessitate the use of additional sedation, unless specific contraindications exist.

### Role of General Anesthesia in Bronchoscopy

Alleviation of perioperative stress, reducing coughing, providing amnesia without compromising airway patency and maintaining adequate oxygenation are primary goals [15]. Patient's anxiety, cultural differences, and pulmonologist training might influence the choice of anesthesia technique. A unique feature pertinent to anesthetic management of bronchoscopic procedures is impracticality of the use of inhalational anesthetics. Provision of an airtight breathing system, monitoring gases, and operating room pollution are some of the obvious drawbacks. Although reports of using inhaled nitrous oxide exist [16] and some anesthesia practitioners continue to use modern inhalational agents, their use in the setting of bronchoscopy is largely historical. TIVA (total intravenous anesthesia) with or without skeletal muscle relaxant is the preferred anesthetic technique.

Bronchoscopic procedures commonly conducted under general anesthesia are listed in Table 1; however, it is not an all-inclusive list. Anesthesia services might be requested due to severe co-morbidity and not necessarily due to complexity of the procedure. In such a scenario, the anesthesia provider should not hesitate to use local blocks with short-acting benzodiazepine sedation than deep propofol sedation.

**Table 1** Indications of sedation/anesthesia during bronchoscopy

Common indications requiring sedation/anesthesia for bronchoscopy	
Transbronchial needle aspiration (EBUS–TBNA)	Bronchial Thermoplasty
Endobronchial valve placement	Endoscopic high dose rate brachytherapy
Stent placement	Argon plasma coagulation therapy
Laser therapy	Electrocautery
Electromagnetic navigational bronchoscopy (ENB)	Balloon dilation
Fiducial Implantation	Rigid bronchoscopy
Bronchoscopic Lung Volume Reduction (BLVR)	Curvilinear EBUS

## The Anatomy, Physiology, and the Physics

An understanding of anatomy, physiology, and physics as it applies to bronchoscopic procedures is both important and relevant.

Anatomically, upper airways are conduits for transfer of gases from outside to the alveoli. The normal diameter of trachea is 1.8 cm (anterio-posterior) that amounts to a surface area of 170 mm<sup>2</sup>. Depending on the bronchoscope used, this area could be reduced to 1/3rd [17]. Unlike pathologies that narrow the tracheal diameter circumferentially (e.g., laryngotracheobronchitis), wherein the resistance to airflow increases to the 4th power of the radius, reduction of the circumference with scope insertion does not increase the resistance to a similar degree. In fact, airflow decreases by a factor  $R^2 - r^2$  (where  $R$  is the diameter of trachea and  $r$  is the diameter of bronchoscope). As a result, positive pressure ventilation is not unduly affected. However, laryngospasm (common during these procedures and usually partial) can add significant resistance, requiring deepening of anesthesia or muscle relaxant.

Intraluminal lesions or extraluminal lesions causing significant tracheobronchial compression are rare (Fig. 1). An effort should be made to understand the pathology and its influence on the bronchial anatomy. A discussion with the pulmonologist is helpful for better understanding. Rarely tracheomalacia is encountered and the anesthesia provider may find it impossible to ventilate with scope in situ. Any scan showing tracheobronchial anatomy should be examined before the procedure [18].

Blood flow to bronchial tree is mainly from bronchial vessels that are direct branches of thoracic aorta. Life-threatening bleeding during bronchoscopy is rare and conditions like tuberculosis-induced erosion might increase the risk. Laser coagulation is sometimes employed for the treatment of AV malformations. As the blood from bronchial vein drains directly to the left heart, use of high pressure during ventilation in such cases can rarely lead to air embolism followed by cerebrovascular events [19].

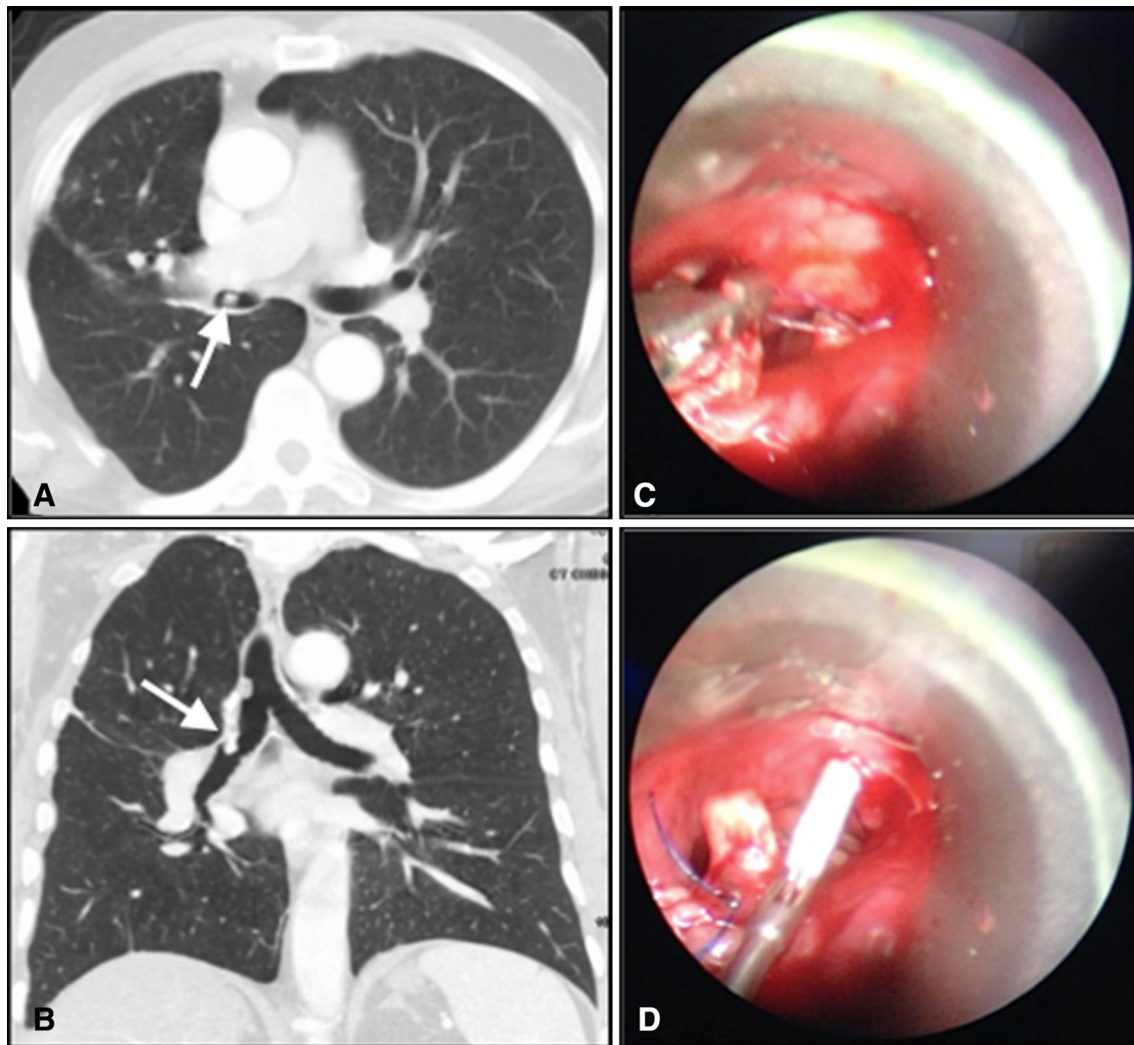
Lastly sensory innervation to larynx is from internal and recurrent laryngeal nerves. Although mechanisms of

laryngospasm are poorly understood and rare during the course of routine anesthesia, they are extremely common during bronchoscopy. Stimulation of larynx and trachea (many times in relatively lightly anesthetized patient) can lead to violent coughing and laryngospasm. Fortunately, laryngospasm during bronchoscopy can be visually confirmed and treatment instituted early [20]. Prolonged procedures especially with rigid bronchoscopes can also lead to laryngeal edema with attendant intra-procedural airway obstruction or significant reduction in tracheal diameter after the procedure. An examination of the false vocal cords and the surrounding structures while the bronchoscopist withdraws the scope can help in their timely diagnosis and management [21].

## Preoperative Evaluation and Preparation

Performing preoperative evaluation as per the standard ASA guidelines is essential and can help predicting possible intra-procedural complications. Symptoms and signs related to either primary pathology (e.g., lung cancer) or metastasis might influence the choice of anesthetic. Smokers are likely to have other manifestations of lung injury like chronic obstructive pulmonary disease (COPD). As discussed, a review of CT and MRI scan for any airway narrowing due to tumor invasion is important. Pulmonary hypertension and severe obstructive (and restrictive) lung disease might necessitate home oxygen and these patients have poor tolerance to even brief periods of apnea at induction. COPD patients may also have metabolic compensation (due to chronic carbon dioxide retention) and this should be considered, both during intraoperative ventilation and emergence [22].

A review of pulmonary function tests might facilitate a quick assessment of airway compromise. They can also help predict apnea tolerance (which may be unavoidable during the procedure). Presence of stridor prior to procedure must alert the likelihood of narrowing of the upper airway. Luminal narrowing due to tracheal/bronchial intraluminal tumor or extraluminal compression not only makes the procedure difficult but can lead to ventilatory



**Fig. 1** a, b Computed tomography images showing right mainstem partial obstruction at the anastomosis site of right upper lobe sleeve resection (arrows). c, d Rigid bronchoscopy images showing

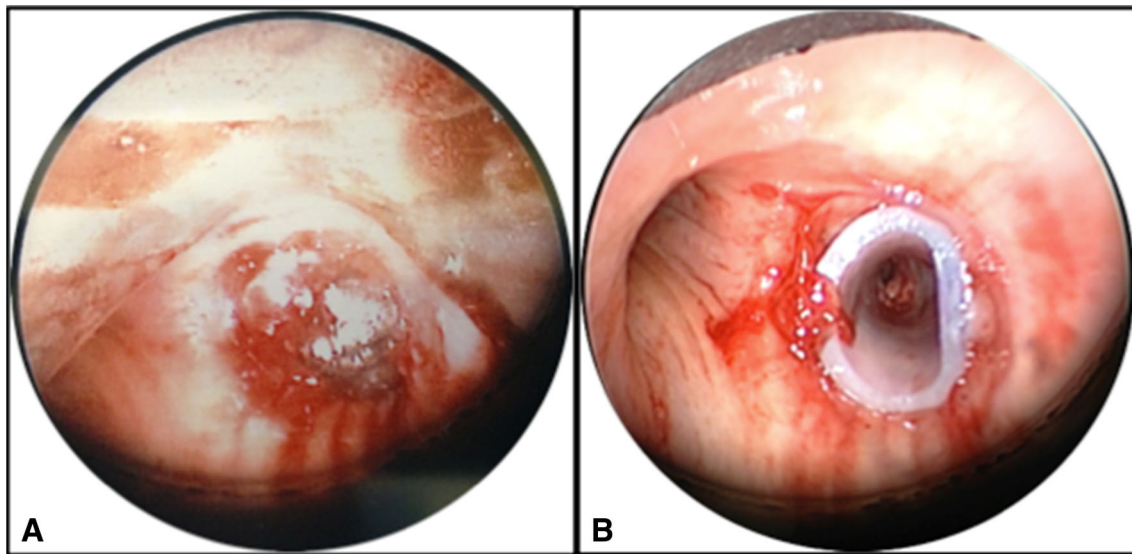
resection of endobronchial sutures and surrounding granulation tissue using rigid forceps and scissors

difficulties (Fig. 1a, b). Patients with transplanted lungs (single and double) are presenting increasingly for bronchoscopy. Presence of granulation tissue at the site of anastomosis can cause bronchial obstruction (Fig. 1c, d). Tracheal and bronchial obstruction can be caused by malignant tumors (Fig. 2). Special attention must be paid to dental assessment, as the possibility of loose tooth or dental prosthesis aspiration during probe insertion exists. This is more likely to happen during rigid bronchoscopy (Fig. 3). A review of chart to identify the extent of the lesion, its effect on surrounding structures, and reports related to chemotherapy can give useful information. The findings at the preoperative evaluation will help planning the anesthesia technique, drugs, and the degree of supervision/involvement needed [23]. Presence of a bronchoesophageal fistula (Fig. 4), tracheoesophageal fistula, and tracheal

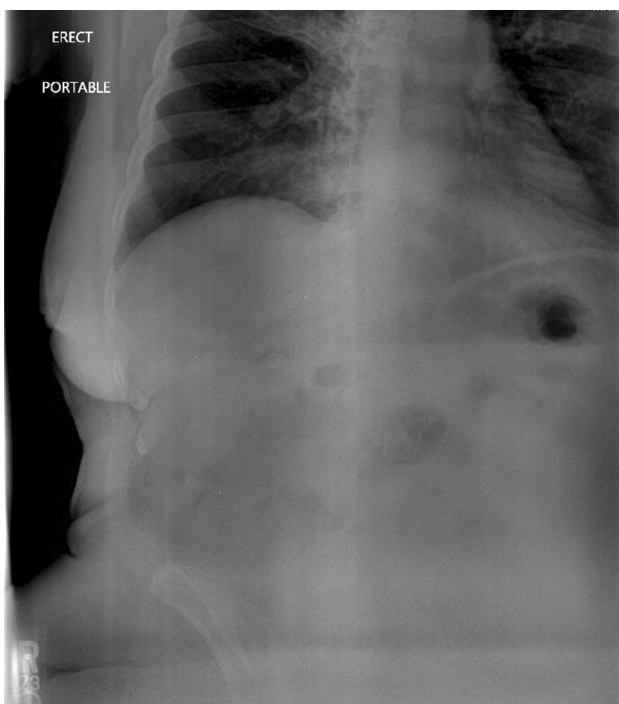
compression from an invading esophageal malignant tumor might require setting up of a jet ventilator [24]. Presence of severe subglottic stenosis might prompt the anesthesiologist to the need of a smaller endotracheal tube as well as the need for a jet ventilator (Figs. 5, 6).

### Premedication

The anticholinergic agents, atropine and glycopyrrolate, cause bronchodilatation and inhibit secretions in the nasopharynx/oropharynx and bronchi allowing better examination of the tracheobronchial tree as well as protection against vasovagal reaction and bronchospasm. These benefits occur when given through the IV or IM route prior to bronchoscopy; however, this improvement is not sustained



**Fig. 2** **a** Rigid bronchoscopic view showing complete obstruction of the right mainstem bronchus by the tumor. **b** A silicone stent was placed after tumor debulking and ablation



**Fig. 3** Radiopaque density, measuring about  $10 \times 6$  mm overlying upper lumbar spine, probably in distal stomach. The patient reported with a missing tooth after a rigid bronchoscopy

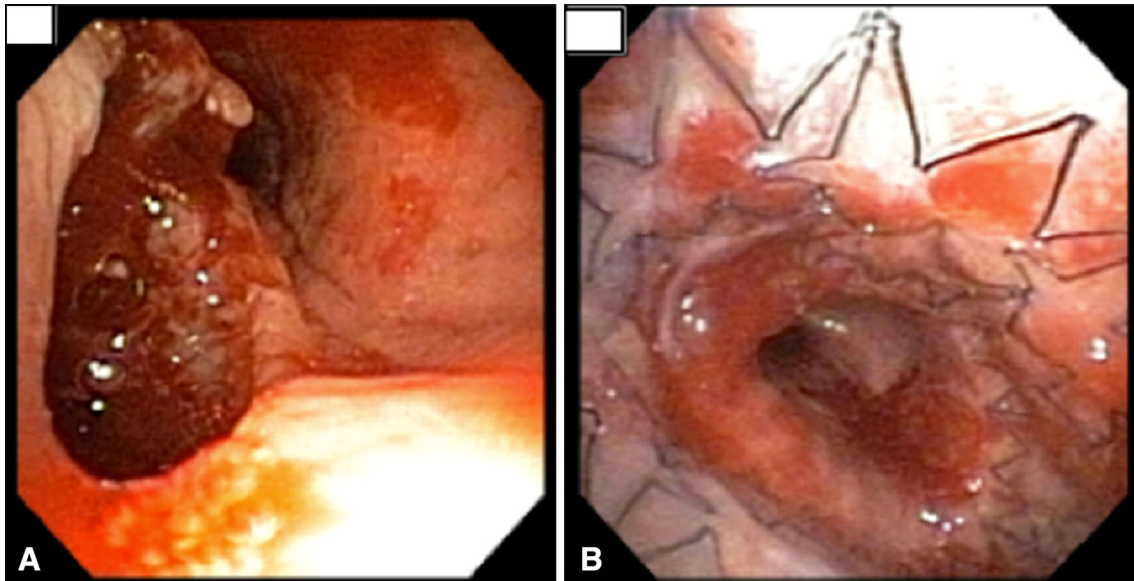
through the post-bronchoscopy period [25, 26]. Moreover, recent American College of Chest Physicians consensus Statement discourages the administration of anticholinergic agents, as they do not produce a clinically meaningful improvement [27]. Patients may typically benefit from pre-procedure bronchodilator therapy with beta-2 agonist

nebulization. It is also recommended to use steam inhalation/nebulization prior to procedure. This may not only help in clearing the secretions but would also improve the bronchoscopic view by assisting in removing secretions that can obscure the view.

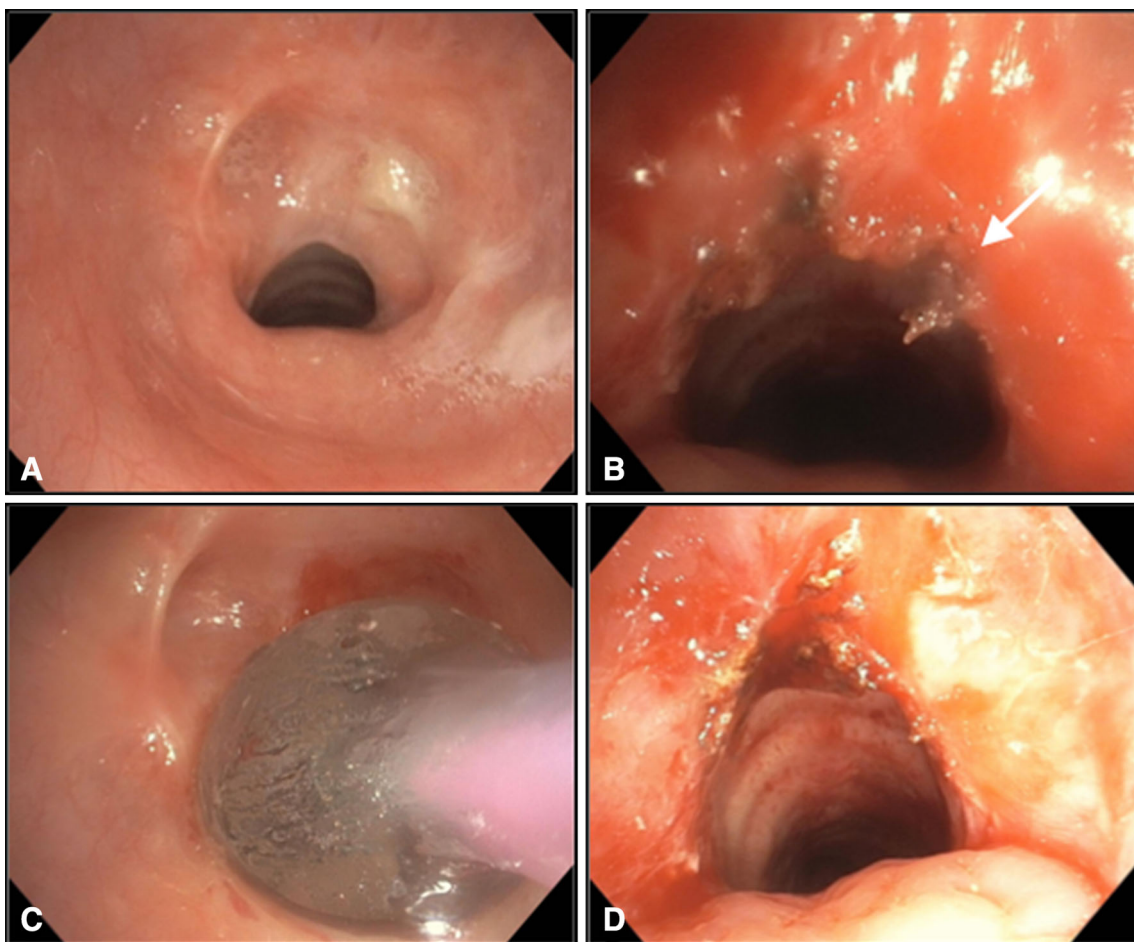
The use of anxiolytics and sedatives should be considered only for very anxious patients with vigilant care and monitoring because the pulmonary status of many patients is poor and these drugs can cause respiratory depression. Additionally, supplemental oxygen should be administered before premedication as a safety measure.

### Monitoring

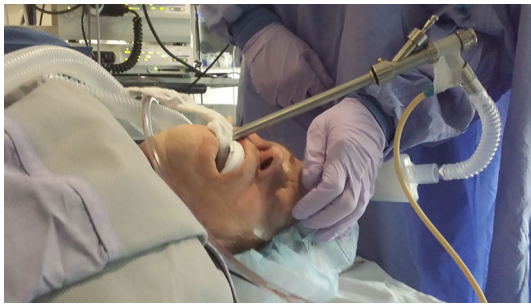Standard monitoring is mandatory while using either monitored anesthesia care sedation or general anesthesia. Monitoring the depth of anesthesia might facilitate appropriate titration of the intravenous drugs and avoid delayed emergence [28]. Additionally, resuscitation equipment for airway emergencies (nasal and oral airways, anesthesia masks, laryngoscope, endotracheal tubes, intubating stylets, self-inflating bag-valve-mask and suction) and cardiac emergencies (defibrillator) must be always available in the bronchoscopy suite. In moribund patients with severe respiratory compromise, transcutaneous carbon dioxide monitor is helpful [29]. Hemodynamically unstable patients may be poor candidates for conventional monitoring and may benefit from frequent ABG (arterial blood gas) monitoring. In such patients, consideration should be given to using an arterial line, which will be useful in monitoring adequacy of respiration and hemodynamics simultaneously.



**Fig. 4** **a** Bronchoscopic view showing left mainstem large bronchoesophageal fistula. **b** Placement of self-expanded covered metallic stent in the left mainstem to cover the fistula



**Fig. 5** **a** Bronchoscopic view of idiopathic subglottic stenosis at the level of first tracheal ring. **b** Needle-knife electrocautery cuts of the stenosis wall (*arrow*). **c** Balloon dilation of the subglottic stenosis. **d** Subglottic stenosis post dilation



**Fig. 6** Saline-soaked throat pack being introduced to provide a seal around the rigid bronchoscope

## Anesthesia/Sedation Agents

The basic pharmacological principles guiding the use of various drugs for sedation during bronchoscopy are summed up in Table 2.

### Remifentanyl

Remifentanyl is gaining popularity as a safe analgesic adjuvant during general anesthesia for advanced bronchoscopic procedures. However, the drug is still not easily available in many countries and relatively expensive in countries where it is available.

It is an ultra-short-acting opioid with a rapid onset time of less than minute and unique pharmacokinetic properties. Its pharmacodynamic properties are similar to other commonly used short-acting opioids. It is a mu receptor agonist with profound analgesic properties. Remifentanyl attenuates the haemodynamic response to bronchoscopic procedures [30] and is ideal for managing the fluctuating periods of high and low stimulation during most advanced bronchoscopic procedures. Pharmacokinetically, however, unlike all other opioids, remifentanyl (due to the presence of ester moiety at the active site) is metabolized by esterases. Due to rapid elimination, its context-sensitive half-time is short, about 2–4 min, and fixed.

To be clinically useful, remifentanyl should be administered as a small slow bolus followed by an infusion [31]. When the drug was first introduced into clinical practice in late 90 s, there were case reports of intense bradycardia and brief periods of sinus pause. It is important to administer it as a small bolus (1–3 mcg per kg) infused over a period of at least 2 min. Bradycardia and hypotension especially in young and beta-blocked patients can be prevented by judicious use of vasopressors like ephedrine. The maintenance infusion for surgical procedures is normally around 1–2 mg per kg per min. However, for bronchoscopies, the dose is significantly higher and may vary up to 5 mg per kg per min. At these doses, respiratory center is inhibited and responses to laryngeal and

**Table 2** Pharmacological principles guiding the use of sedatives during bronchoscopy

Pharmacology of agents used in bronchoscopy		Propofol	Dexmedetomidine	Midazolam	Fentanyl	Alfentanil	Diazepam	Fospropofol	Remimazolam
Agent	Remifentanyl	Propofol	Dexmedetomidine	Midazolam	Fentanyl	Alfentanil	Diazepam	Fospropofol	Remimazolam
Mechanism/class	Opioid	GABA agonist	Allopathic-2 agonist	Benzodiazepine	Opioid	Opioid	Benzodiazepine	GABA agonist	Benzodiazepine derivative
Onset	<30 s	30 s	10 min	30–60 s	<60 s	Immediate	60 s	4–13 min	Immediate
Peak action	1.5 min	1.5 min	15–20 min	5–10 min	3.6 min	1.4 min	2–3 min	12 min	3 min
Duration of action	3–4 min	3–5 min	2.5–3.5 h	2 h	1–1.5 h	1–1.5 h	1–3 h	17–28 min	6 min
Metabolism	Organ independent	Hepatic	Hepatic	Hepatic	Hepatic	Hepatic	Hepatic	Hepatic	Organ independent
Elimination half-life	1–20 min	3–12 h	2–2.5 h	2–3.5 h	3–4 h	1 h	20–48 h	45 min	0.76–1.08 h
Adverse effects	Chest wall rigidity, bradycardia, respiratory depression	Respiratory depression, hypotension	Hypotension, bradycardia	Respiratory depression, hypotension	Respiratory depression	Chest wall rigidity, respiratory depression	Respiratory depression, phlebitis	Hypotension, pruritus	Not enough studies yet

tracheal stimulation are suppressed. During the procedure, depending on the patient's response, either small boluses (2 mic per king per min over 60 s) or increase in the rate of infusions might be helpful. In the majority, a requirement of muscle relaxant may be completely avoided. However, there are some situations wherein supplemental boluses of remifentanyl and Propofol are not sufficient or hemodynamically unfriendly. This is especially true in rigid bronchoscopies, obese patients, and in patients with an irritable airway (smoker, bronchial asthma). In such cases, administration of skeletal short–intermediate-acting muscle relaxant is helpful and sometimes essential [32].

Remifentanyl is demonstrated not only to reduce the incidence of coughing and laryngospasm, it also increases the bronchoscopist's satisfaction [33]. It is not recommended to stop the remifentanyl infusion or even reduce the rate until the bronchoscope is withdrawn at the end of the procedure. Unlike procedures involving a surgical incision, the intensity of stimulation in bronchoscopies is sustained and severe for the whole procedure. Given the short and context insensitive half-life of remifentanyl, reduction of the plasma concentrations by half (e.g., from 8 to 4 nanogram per cc) can occur in 2–3 min. This might trigger coughing and rapid desaturation.

### Propofol

Propofol is the most commonly used hypnotic as a part of total intravenous anesthesia technique ensuring continuous delivery of anesthesia and avoiding operating room pollution. It facilitates the inhibitory effect of gamma aminobutyric acid and results in decreased the sympathetic outflow and stress response [34]. In combination with remifentanyl in doses suggested above, the main role of Propofol is to provide a hypnotic base. Advised infusion rates are 80–120 mic per kg per min. It is inadvisable to taper off the Propofol infusion rate rapidly especially after short durations of infusion. However, after prolonged procedures, a small reduction in the infusion rate is needed as the context-sensitive half-life is prolonged and this may eventually lead to delayed awakening. An EEG-based depth of anesthesia monitor (BIS or SEDline) might help in titration to the required hypnotic level. Small boluses (30–50 mg for an average sized adult) just prior to scope introduction and during the procedure (reintroduction or change to rigid scope) are helpful in preventing an unwanted hemodynamic response or laryngospasm. It is known to decrease the incidence of coughing and also depresses the ciliary function [35]. Propofol in subhypnotic doses is also effective in preventing laryngospasm on tracheal extubation in children [36] and in volunteers when examined by videoradiography [35–37].

### Dexmedetomidine

Dexmedetomidine has unique pharmacodynamic properties (unlike remifentanyl that has unique pharmacokinetic properties). It is a selective alpha 2 agonist. Its action is similar to clonidine; however, it is 6–8 times more selective to alpha 2A type receptors. It is presently FDA approved only for sedation in intensive care patients; however, as an off-label use, it can be considered for patients undergoing bronchoscopy by virtue of its capability to maintain spontaneous breathing despite deep sedation.

Dexmedetomidine is unique in that it has properties unlike any other commonly used anesthetic drugs. Almost all studies agree on its ability to maintain spontaneous ventilation with almost no assistance required apart from occasional minor airway maneuvers like chin lift [38]. Despite above desirable properties, dexmedetomidine is still not in popular use among bronchoscopy suites mainly because of limited available evidence. The following are possible limitations (extrapolated from non-bronchoscopy-based studies) of using dexmedetomidine during bronchoscopy: [39–41].

1. The optimal loading dose is unknown and evidence indicates that a bolus of 1 mg per kg over 6–10 min followed by 0.5–0. mcg per kg per h seems to be reasonable. However, it is important to remember that supplements of midazolam in increments of 0.5–1 mg are necessary for completion of procedure.
2. As can be expected from its pharmacokinetics, the drug has a prolonged induction time and even more prolonged recovery time. Most diagnostic bronchoscopies will not take more than 10 min, which questions the role of this drug in this setting altogether.
3. It is frequently noted that dexmedetomidine has excellent hemodynamic profile. It suppresses intubation response and maintains heart rate and blood pressure, but it can also cause severe bradycardia and hypotension, which caused the cessation of at least one study.
4. Even if a simple diagnostic bronchoscopy can be done with reasonable success, it might be difficult to carry out complicated therapeutic and advanced endoscopic procedures with dexmedetomidine even with the addition of midazolam and fentanyl.

In our opinion, dexmedetomidine might be useful for simple diagnostic bronchoscopy in experienced hands. Use of midazolam and short-acting opioid is essential to achieve higher success rates.

### Remimazolam (CNS 7056)

A major drawback of propofol (in the context of total intravenous anesthesia) is prolonged and relatively



unpredictable context-sensitive half-life. A hypnotic that combines properties of remifentanyl (metabolism) and propofol would be ideal. Although such a hypnotic is not yet available, a benzodiazepine is undergoing clinical trials. It is a midazolam with an ester moiety introduced to allow metabolism by esterase. As a result, it is metabolized in plasma and tissues rapidly without dependence on any specific organ. The patients are likely to wake up rapidly, even after a prolonged infusion.

Remimazolam like midazolam acts on the benzodiazepine part of GABA receptors [42]. The drug is currently touted as a replacement for propofol in gastrointestinal (GI) endoscopy. In a phase IIa clinical trial on patients undergoing upper GI endoscopy, its onset of action was similar to that of midazolam and recovery was slightly shorter. The second study (results presented at European society of intravenous anesthesia annual meeting June 10th 2011) involved 160 patients scheduled to undergo colonoscopy. Based on the findings of this study, it is likely to play a significant role in the future of endoscopy sedation and anesthesia. Remimazolam is also likely to be part of future total intravenous anesthesia due to its predictable recovery (not shorter recovery), unlike propofol [43]. The combined infusion of remimazolam and propofol might reduce propofol dose significantly, especially after prolonged procedures. Reduction of total dose of propofol would not only help faster recovery, it can also reduce lipid load and the incidence of propofol infusion syndrome.

### Choice of Airway

Invention of laryngeal mask airway (LMA) has been one of the most significant anesthesia landmarks during the last century. The benefits of this invention have not been felt as much in any area of anesthesia practice as in bronchoscopy. It allows use of larger diameter conduit (compared to endotracheal tube), thereby reducing the airway resistance [44]. This may not be a significant factor when controlled ventilation is used as is universal in these procedures. However, it allows unprecedented view and flexibility for bronchoscopist especially during therapeutic interventions. Instillation of few milliliters of lidocaine before introducing the bronchoscope helps in blunting the response. It is easy to see the position of mask in relation to the laryngeal inlet while the bronchoscope is being introduced and this should be noted by the anesthesia provider. It is not uncommon to notice a folded LMA or the tip inserted too far. If necessary, position of the LMA should be readjusted at this time.

However, there are some situations where LMA is unsuitable and it does not guarantee protection against aspiration. Patients with significant resistance (airway or chest

wall) may have unacceptable leaks at pressures needed to achieve sufficient tidal volumes [45]. Morbid obesity and restrictive lung diseases are some of the examples [46]. Anatomical variations especially at the laryngopharynx can lead to difficulty in positioning. Patients with short and thick neck can be challenging. Use of skeletal muscle relaxants can lower the chest wall resistance and help reduce inspiratory pressures required to achieve satisfactory tidal volumes. A large endotracheal tube is used when LMA is contraindicated or unsuccessful. Tracheomalacia is another condition where LMA is not preferable, although reports of successful use of LMA do exist in this situation [47].

Newer airway devices are being developed and might benefit patients undergoing procedures of mild–moderate stimulation [48, 49].

### Endotracheal Tube

Endotracheal tube is the definitive airway device which provides a secure airway and is of importance especially in patients with gastro–esophageal reflux disease, hiatus hernia, post-esophagectomy with stomach pull through, and/or when EBUS scope is required to be inserted via esophagus to obtain biopsies. There are wide ranges of bronchoscopy adaptors with diaphragms to decrease the air leak. Nevertheless, high fresh gas flows are often required to deliver adequate ventilation and compensate for the leaks. Generally, larger endotracheal tubes are used to allow free movement for the bronchoscope and adequate ventilation without developing high airway pressures as a result of sharing the airway with the pulmonologist.

### Ventilation Strategies

Ensuring adequate spontaneous ventilation under anesthesia through a narrowed airway (due to presence of bronchoscope) is usually not a practical option. The depth of anesthesia required to suppress coughing in response to noxious stimulation causes significant respiratory depression. Presence of bronchoscope further narrows the available airway. Given these limitations, spontaneous ventilation can be applied for short procedures [50] performed under conscious sedation, when the patient can maintain his spontaneous ventilation, but vigilant monitoring is still required [51]. This leaves the ventilation choices essentially between controlled ventilation and jet ventilation. An experienced hand (compressing the bag) might be more useful than any other mechanical mode of ventilation.

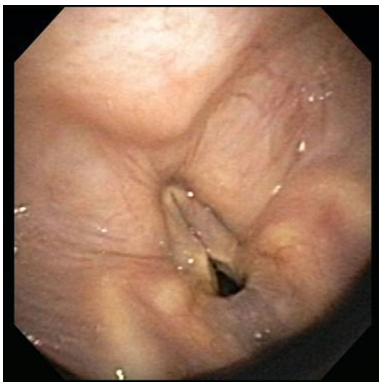
Air leaks are inevitable due to high pressures needed to deliver adequate tidal volume to the lungs. As a result, pressure control ventilation is preferable to ensure adequate

volumes. Wherever an LMA is being used, it must be realized that peak pressures may be limited to around 30 cm of water (leak pressure for LMA). If sufficient expired volumes cannot be delivered leading to either unacceptably high end tidal carbon dioxide or oxygen desaturation, manual controlled ventilation with high fresh gas flows may be effective. If none of the above measures are effective, skeletal muscle paralysis might be considered. Withdrawal of the bronchoscope and brief periods of mask ventilation is another option. Endotracheal intubation might be the best option in some circumstances and the decision needs to be made in good time to prevent any severe desaturation.

Advanced procedures such as balloon dilatation of the stenotic segment can lead to brief periods of airway obstruction (Fig. 5). Tracheal dilatation causes complete obstruction and a non-observant anesthesiologist might panic. An ongoing communication is essential. Airway pressures will rise and ventilation will be impossible. It is essential to be prepared for this period and ventilate patients with 100 % oxygen prior to attempted balloon dilation. The mode of ventilator needs to be switched to spontaneous during dilation followed by resumption of controlled ventilation.

## Complications

The potential complications associated with bronchoscopic procedures include hypoxemia, hypercarbia, [52] cough, laryngospasm, (Fig. 7) major bleeding, [53] pneumothorax, tension pneumothorax, [54] endobronchial fire, [55] injury to glottic structures, loss of airway, tracheal rupture, [56] pulmonary barotrauma, and cerebral or cardiac air emboli [19]. The incidence of such complications depends upon the skill of the pulmonologist and ventilatory strategies used during the procedures. A careful vigilant monitoring




**Fig. 7** Partial laryngospasm is not uncommon during and at the end of a bronchoscopic procedure

can help in prevention, diagnosis, and management. An underestimated complication is “airway fire” related to laser procedures during advanced bronchoscopy. Analogous to some Ear-nose & throat (ENT) surgeries, such incidents have been reported in patients undergoing advanced pulmonary procedures [57]. Silicone stents used during some advanced procedures pose a particular risk as they supply fuel to the fire [58]. It is suggested that standard precautions implemented to prevent fires during ENT surgery must be adhered to during bronchoscopic procedures warranting the use of laser. Limiting inhaled oxygen concentration to <40 % is advisable [59]. Flammable material should be kept away from the operating field. Whether performed via rigid or flexible bronchoscopy, continuous suction should be applied. Apart from continuously clearing inflammable tissue particles, it prevents accumulation of inhaled anesthetics (gaseous anesthesia is being delivered). However, inhalational anesthesia is not advisable during advanced bronchoscopic procedures. Often laser-based pulmonary procedures are performed to relieve central airway obstructions and highest degree of caution is advised where silicone stents (flammable material) are present in the airway.

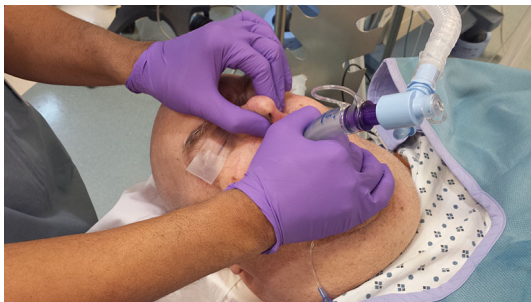## Jet Ventilation

Most anesthesiologists would consider high-frequency jet ventilation as standard, whenever rigid bronchoscope is used [60, 61]. However, there is no evidence to support the practice. Administration of skeletal muscle relaxant facilitates jet ventilation.

Mechanical jet ventilator devices allows the control of driving pressure, inspiratory time, frequency of respiration, fraction of inspired oxygen, humidification of inspired oxygen, and alarm system to protect against barotrauma. Typical settings during a rigid bronchoscope under general anesthesia are displayed in Fig. 8. High fresh gas flow is needed to compensate for the leak around the rigid bronchoscope [62]. Mouth guards can be used to protect the lips and teeth. Occasionally saline-soaked packs are inserted inside the mouth to decrease fresh gas leak. These must be recorded on application and removal at the end of the procedure to avoid any post-operative airway obstruction (Fig. 6) [63]. Rarely jet ventilation is ineffective or equipment malfunction might prevent its use while the procedure is in progress. Using both hands to form an airtight seal around the mouth and asking an assistant to deliver manual positive pressure ventilation is effective. However, one should be always prepared to remove the endoscope (rigid or flexible) and institute positive pressure ventilation with a tight-sealing face mask.



**Fig. 8** Typical Jet Ventilator settings during rigid bronchoscopy



**Fig. 9** Applying hand around the laryngeal mask airway with occlusion of the nose to prevent an air leak, while an assistant ventilates the patient with hand is a useful technique to treat partial laryngospasm during the emergence period

Experience with the use of jet ventilation in patients with lung pathology is presently limited. Physiologically, the mean airway pressures remain high during jet ventilation [64]. In patients with pulmonary hypertension, such increased airway pressure can lead to further fall in pulmonary blood flow, making them poor candidates for jet ventilation. Presently available literature discusses the use of jet ventilation in neonates with pulmonary hypertension and use in adult population is limited [65]. On the contrary, in patients with decreased lung compliance or lowered diffusion capacity (Interstitial lung disease), jet ventilation may improve the oxygenation. Higher mean airway pressures are known to step up the oxygenation by recruiting unventilated lung zones. This rationale is analogous to the successful use of high-frequency ventilation in acute respiratory distress syndrome (ARDS). During these procedures, one must, however, be prepared to allow some degree of hypercapnia, as effective alveolar minute volume may be reduced [66].

Barotrauma (pneumothorax, pneumomediastinum, subcutaneous emphysema) is an uncommon but severe complication associated with the use of jet ventilation [67]. It has a reported incidence of more than 10 %, when used as an emergency measure. Presence of airway narrowing increases the risk of barotrauma. Keeping the airway open at all times including an open pop-off valve of the breathing

system and a preference for supraglottic jet ventilation might reduce the risk of barotrauma.

## Emergence

Emergence from anesthesia is a particularly tricky period of the procedure. Unlike many surgical procedures (that involve skin closure), the transition during bronchoscopy is from a period of intense stimulation to its complete absence. The period of skin closure period is utilized by the anesthesiologists to lighten the anesthetic depth and facilitate rapid emergence. Such a luxury does not exist with most advanced bronchoscopic procedures.

The patients can pass through a phase of upper airway obstruction during the emergence process. The ventilatory volumes can fall accompanied by increasing airway pressures. Severe hypoxemia can ensue. Reduction of the minute volume to increase the blood carbon dioxide tension commonly practiced by anesthesia providers can worsen the situation. It does not serve any useful purpose and can increase the patient's restlessness during the emergence. Inability to maintain airway and effective ventilation can lead to hypoxemic cardiac arrest. Preparedness to address any situation like laryngospasm is essential. Frequently, applying a manual seal around the mouth along with nose occlusion, with an assistant providing positive pressure ventilation is adequate (Fig. 9). One should be prepared with the necessary drugs (propofol, succinylcholine) and equipment (laryngoscope, endotracheal tube, airways) during the emergence.

## Conclusions

Providing sedation and anesthesia for patients undergoing bronchoscope requires a good understanding of pulmonary anatomy and physiology. Constant communication with pulmonologist is important. With the increasing complexity of the procedures, role of anesthesiologist is likely to increase in this setting.

**Conflict of interest** None.

## References

- Gonzalez R, De-La-Rosa-Ramirez I, Maldonado-Hernandez A, Dominguez-Cherit G (2003) Should patients undergoing a bronchoscopy be sedated? *Acta Anaesthesiol Scand* 47(4):411–415
- Colt HG, Morris JF (1990) Fiberoptic bronchoscopy without premedication. A retrospective study. *Chest* 98(6):1327–1330

3. Maltais F, Laberge F, Laviolette M (1996) A randomized, double-blind, placebo-controlled study of lorazepam as premedication for bronchoscopy. *Chest* 109(5):1195–1198
4. Ni Y-L, Lo Y-L, Lin T-Y, Fang Y-F, Kuo H-P (2010) Conscious sedation reduces patient discomfort and improves satisfaction in flexible bronchoscopy. *Chang Gung Med J* 33(4):443–452
5. Hatton MQ, Allen MB, Vathenen AS, Mellor E, Cooke NJ (1994) Does sedation help in fibreoptic bronchoscopy? *BMJ* 309(6963):1206–1207
6. Pickles J, Jeffrey M, Datta A, Jeffrey AA (2003) Is preparation for bronchoscopy optimal? *Eur Respir J* 22(2):203–206
7. Prakash UB, Offord KP, Stubbs SE (1991) Bronchoscopy in North America: the ACCP survey. *Chest* 100(6):1668–1675
8. Maguire GP, Rubinfeld AR, Trembath PW, Pain MC (1998) Patients prefer sedation for fibreoptic bronchoscopy. *Respirol Carlton Vic* 3(2):81–85
9. Cases Viedma E, Pérez Pallarés J, Martínez García MA, López Reyes R, Sanchís Moret F, Sanchís Aldás JL (2010) A randomised study of midazolam for sedation in flexible bronchoscopy. *Arch Bronconeumol* 6(6):302–309
10. Goudra BG, Singh PM, Sinha AC (2013) Anesthesia for ERCP: impact of anesthesiologist's experience on outcome and cost. *Anesthesiol Res Pract [Internet]* 2013 May 28 [cited 2013 Jun 7]; Available from <http://www.hindawi.com/journals/arp/2013/570518/abs/>
11. British Thoracic Society (2001) British Thoracic Society guidelines on diagnostic flexible bronchoscopy. *Thorax* 56(Suppl 1):i1–i21
12. Stolz D, Kurer G, Meyer A, Chhajed PN, Pflimlin E, Strobel W et al (2009) Propofol versus combined sedation in flexible bronchoscopy: a randomised non-inferiority trial. *Eur Respir J* 34(5):1024–1030
13. Moore TJ, Walsh CS, Cohen MR (2004) Reported adverse event cases of methemoglobinemia associated with benzocaine products. *Arch Intern Med* 164(11):1192–1196
14. Graham DR, Hay JG, Clague J, Nisar M, Earis JE (1992) Comparison of three different methods used to achieve local anesthesia for fiberoptic bronchoscopy. *Chest* 102(3):704–707
15. Gasparini S (2011) It is time for patients to undergo bronchoscopy without discomfort. *Eur Respir J* 38(3):507–509
16. Brown D, Young JVI (1959) Nitrous oxide anaesthesia for bronchoscopy. *Br Med J* 1(5123):692–695
17. Williamson JP, Armstrong JJ, McLaughlin RA, Noble PB, West AR, Becker S et al (2010) Measuring airway dimensions during bronchoscopy using anatomical optical coherence tomography. *Eur Respir J* 35(1):34–41
18. Oh Y, Kobayashi T, Morikawa A, Nakano T, Matsuda S, Sakai T et al (2007) Utility of virtual bronchoscopy in congenital tracheomalacia. *Tokai J Exp Clin Med* 32(2):67–69
19. Tellides G, Ugurlu BS, Kim RW, Hammond GL (1998) Pathogenesis of systemic air embolism during bronchoscopic Nd:YAG laser operations. *Ann Thorac Surg* 65(4):930–934
20. De Blic J, Marchac V, Scheinmann P (2002) Complications of flexible bronchoscopy in children: prospective study of 1328 procedures. *Eur Respir J* 20(5):1271–1276
21. Hasdiraz L, Oguzkaya F, Bilgin M, Bicer C (2006) Complications of bronchoscopy for foreign body removal: experience in 1035 cases. *Ann Saudi Med* 26(4):283–287
22. Chhajed PN, Glanville AR (2003) Management of hypoxemia during flexible bronchoscopy. *Clin Chest Med* 24(3):511–516
23. Salisbury BG, Metzger LF, Altose MD, Stanley NN, Cherniack NS (1975) Effect of fiberoptic bronchoscopy on respiratory performance in patients with chronic airways obstruction. *Thorax* 30(4):441–446
24. Dolan AM, Moore MF (2013) Anaesthesia for tracheobronchial stent insertion using an laryngeal mask airway and high-frequency jet ventilation. *Case Rep Med* 2013:950437
25. Thorburn JR, James MF, Feldman C, Moyes DG, Du Toit PS (1986) Comparison of the effects of atropine and glycopyrrolate on pulmonary mechanics in patients undergoing fiberoptic bronchoscopy. *Anesth Analg* 65(12):1285–1289
26. Williams T, Brooks T, Ward C (1998) The role of atropine premedication in fiberoptic bronchoscopy using intravenous midazolam sedation. *Chest* 113(5):1394–1398
27. Wahidi MM, Jain P, Jantz M, Lee P, Mackensen GB, Barbour SY et al (2011) American College of Chest Physicians consensus statement on the use of topical anesthesia, analgesia, and sedation during flexible bronchoscopy in adult patients. *Chest* 140(5):1342–1350
28. Clark G, Licker M, Younosian AB, Soccia PM, Frey J-G, Rochat T et al (2009) Titrated sedation with propofol or midazolam for flexible bronchoscopy: a randomised trial. *Eur Respir J* 34(6):1277–1283
29. Carmi U, Kramer MR, Zemtsov D, Rosengarten D, Fruchter O (2011) Propofol safety in bronchoscopy: prospective randomized trial using transcutaneous carbon dioxide tension monitoring. *Respiration* 82(6):515–521
30. Prakash N, McLeod T (2001) Gao Smith F. The effects of remifentanyl on haemodynamic stability during rigid bronchoscopy. *Anaesthesia* 56(6):576–580
31. Singh P (2012) Remifentanyl—was it only respiratory arrest? *Anaesthesia* 67(9):1044
32. Chalumeau-Lemoine L, Stoelin A, Billard V, Laplanche A, Raynard B, Blot F (2013) Flexible fiberoptic bronchoscopy and remifentanyl target-controlled infusion in ICU: a preliminary study. *Intensive Care Med* 39(1):53–58
33. Goudra BG, Singh PM, Manjunath AK, Reihmer JW, Lanfranco AR, Sinha AC, Harris K (2014) Effectiveness of high dose remifentanyl in preventing coughing and laryngospasm in non-paralyzed patients for advanced bronchoscopic procedures. *Ann Thorac Med* 9:23–28
34. Ledowski T, Bein B, Hanss R, Paris A, Fudickar W, Scholz J et al (2005) Neuroendocrine stress response and heart rate variability: a comparison of total intravenous versus balanced anesthesia. *Anesth Analg* 101(6):1700–1705
35. McKeating K, Bali IM, Dundee JW (1988) The effects of thiopentone and propofol on upper airway integrity. *Anaesthesia* 43(8):638–640
36. Batra YK, Ivanova M, Ali SS, Shamsah M, Al Qattan AR, Belani KG (2005) The efficacy of a subhypnotic dose of propofol in preventing laryngospasm following tonsillectomy and adenoidectomy in children. *Paediatr Anaesth* 15(12):1094–1097
37. Berzin TM, Sanaka S, Barnett SR, Sundar E, Sepe PS, Jakubowski M et al (2011) A prospective assessment of sedation-related adverse events and patient and endoscopist satisfaction in ERCP with anesthesiologist-administered sedation. *Gastrointest Endosc* 73(4):710–717
38. Shukry M, Miller JA (2010) Update on dexmedetomidine: use in nonintubated patients requiring sedation for surgical procedures. *Ther Clin Risk Manag* 6:111–121
39. Barton KP, Munoz R, Morell VO, Chrysostomou C (2008) Dexmedetomidine as the primary sedative during invasive procedures in infants and toddlers with congenital heart disease. *Pediatr Crit Care Med J Soc Crit Care Med World Fed Pediatr Intensive Crit Care Soc* 9(6):612–615
40. Liao W, Ma G, Su Q, Fang Y, Gu B, Zou X (2012) Dexmedetomidine versus midazolam for conscious sedation in postoperative patients undergoing flexible bronchoscopy: a randomized study. *J Int Med Res* 40(4):1371–1380
41. José RJ, Shaefi S, Navani N (2013) Sedation for flexible bronchoscopy: current and emerging evidence. *Eur Respir Rev* 22(128):106–116
42. Rogers WK, McDowell TS (2010) Remimazolam, a short-acting GABA(A) receptor agonist for intravenous sedation and/or

- anesthesia in day-case surgical and non-surgical procedures. *IDrugs Investig Drugs J* 13(12):929–937
43. Sneyd JR (2012) Remimazolam: new beginnings or just a me-too? *Anesth Analg* 115(2):217–219
  44. Brimacombe J, Tucker P, Simons S (1995) The laryngeal mask airway for awake diagnostic bronchoscopy. A retrospective study of 200 consecutive patients. *Eur J Anaesthesiol* 12(4):357–361
  45. Murgu SD, Pecson J, Colt HG (2011) Flexible bronchoscopy assisted by noninvasive positive pressure ventilation. *Crit Care Nurse* 31(3):70–76
  46. Wadhwa A, Singh PM, Sinha AC (2013) Airway management in patients with morbid obesity. *Int Anesthesiol Clin* 51(3):26–40
  47. Palazzo FF, Allen JG, Greatorex RA (2000) Laryngeal mask airway and fibre-optic tracheal inspection in thyroid surgery: a method for timely identification of tracheomalacia requiring tracheostomy. *Ann R Coll Surg Engl* 82(2):141–142
  48. Goudra B, Chandramouli M, Singh P, Sandur V (2014) Goudra ventilating bite block to reduce hypoxemia during endoscopic retrograde cholangiopancreatography. *Saudi J Anaesth* 8(2):299
  49. Goudra BGG, Mouli C, Singh PM, Sandur V (2014) Novel bite block for upper gastrointestinal endoscopy. *J Res Med Sci [Internet]*. 2014 Nov 30 [cited 2015 Jan 2] 19(11). Available from <http://jrms.mui.ac.ir/index.php/jrms/article/view/10089>
  50. Cai Y, Li W, Chen K (2013) Efficacy and safety of spontaneous ventilation technique using dexmedetomidine for rigid bronchoscopic airway foreign body removal in children. *Paediatr Anaesth* 23(11):1048–1053
  51. Baumann HJ, Klose H, Simon M, Ghadban T, Braune SA, Hennigs JK et al (2011) Fiber optic bronchoscopy in patients with acute hypoxemic respiratory failure requiring noninvasive ventilation - a feasibility study. *Crit Care* 15(4):R179
  52. Cracco C, Fartoukh M, Prodanovic H, Azoulay E, Chenivresse C, Lorut C et al (2013) Safety of performing fiberoptic bronchoscopy in critically ill hypoxemic patients with acute respiratory failure. *Intensive Care Med* 39(1):45–52
  53. Carr IM, Koegelenberg CFN, von Groote-Bidlingmaier F, Mowlana A, Silos K, Haverman T et al (2012) Blood loss during flexible bronchoscopy: a prospective observational study. *Respir Int Rev Thorac Dis* 84(4):312–318
  54. Iannoli ED, Litman RS (2002) Tension pneumothorax during flexible fiberoptic bronchoscopy in a newborn. *Anesth Analg* 94(3):512–513. table of contents
  55. Lee J, Park YS, Yang S-C (2011) The Endoscopic cryotherapy of lung and bronchial tumors: a systematic review—can we expect a new era of cryotherapy in lung cancer? *Korean J Intern Med* 26(2):132–134
  56. Schneider T, Storz K, Dienemann H, Hoffmann H (2007) Management of iatrogenic tracheobronchial injuries: a retrospective analysis of 29 cases. *Ann Thorac Surg* 83(6):1960–1964
  57. Lee J-Y, Park CB, Cho E-J, Kim CJ, Chea JS, Lee BH et al (2012) Airway fire injury during rigid bronchoscopy in a patient with a silicon stent—A case report-. *Korean J Anesthesiol* 62(2):184–187
  58. Scherer TA (2000) Nd-YAG laser ignition of silicone endobronchial stents. *Chest* 117(5):1449–1454
  59. Brutinel WM, Cortese DA, McDougall JC, Gillio RG, Bergstralh EJ (1987) A two-year experience with the neodymium-YAG laser in endobronchial obstruction. *Chest* 91(2):159–165
  60. Pathak V, Welsby I, Mahmood K, Wahidi M, MacIntyre N, Shofer S (2014) Ventilation and anesthetic approaches for rigid bronchoscopy. *Ann Am Thorac Soc* 11(4):628–634
  61. Sarkiss M (2011) Anesthesia for bronchoscopy and interventional pulmonology: from moderate sedation to jet ventilation. *Curr Opin Pulm Med* 17(4):274–278
  62. Hautmann H, Gamarra F, Henke M, Diehm S, Huber RM (2000) High frequency jet ventilation in interventional fiberoptic bronchoscopy. *Anesth Analg* 90(6):1436–1440
  63. Fernandez-Bustamante A, Ibañez V, Alfaro JJ, de Miguel E, Germán MJ, Mayo A et al (2006) High-frequency jet ventilation in interventional bronchoscopy: factors with predictive value on high-frequency jet ventilation complications. *J Clin Anesth* 18(5):349–356
  64. MacIntyre NR (2002) Setting the frequency-tidal volume pattern. *Respir Care* 47(3): 266–74; discussion 274–8
  65. Jirapaet KS, Kiatchuskul P, Kolatat T, Srisuparb P (2001) Comparison of high-frequency flow interruption ventilation and hyperventilation in persistent pulmonary hypertension of the newborn. *Respir Care* 46(6):586–594
  66. Principi T, Pantanetti S, Elisei D, Strovegli D, Gasparini S, Pelaia P (2003) Carbon dioxide monitoring during high-frequency jet ventilation for rigid bronchoscopy. *Crit Care* 7(Suppl 2):P159
  67. Singh-Radcliff N (ed) (2012) 5 min Anesthesia Consult. Har/Psc edition. LWW, Philadelphia, pp 501–502