

## Proposal for revision of the European Laryngological Society classification of endoscopic cordectomies

Marc Remacle · Christophe Van Haverbeke · Hans Eckel · Patrick Bradley ·  
Dominique Chevalier · Votko Djukic · Marco de Vicentiis · Gerhard Friedrich ·  
Jan Olofsson · Giorgio Peretti · Miquel Quer · Jochen Werner

Received: 4 September 2006 / Accepted: 11 December 2006 / Published online: 22 March 2007  
© Springer-Verlag 2007

**Abstract** A classification of laryngeal endoscopic cordectomies, which included eight different types, was first proposed by the European Laryngological Society in 2000. The purpose of this proposal of classification was an attempt to reach better consensus amongst clinicians and agree on uniformity in reporting the extent and depth of resection of cordectomy procedures, to allow relevant comparisons within the literature when presenting/publishing the results of surgery, and to recommend the use of guidelines to allow for reproducibility amongst practicing laryngologists. A total of 24 article citations of this classification have been found through the science citation index, as well as 3 book chapters on larynx cancer surgery, confirming its acceptance. However, on reflection, and with the passage of time, lesions originating at the

anterior commissure have not been clearly described and, for that reason, a new endoscopic cordectomy (type VI) for cancers of the anterior commissure, which have extended or not to one or both of the vocal folds, without infiltration of the thyroid cartilage is now being proposed by the European Laryngological Society Committee on Nomenclature to revise and complete the initially reported classification.

**Keywords** Endoscopic cordectomies classification · European Laryngological Society · Glottic cancer

### Introduction

The European Laryngological Society (ELS) Working Committee on Nomenclature proposed in 2000 [35] a classification

---

M. Remacle (✉) · C. Van Haverbeke  
Department of Oto–rhino–laryngology and Head & Neck Surgery,  
University Hospital of Louvain at Mont-Godinne,  
Dr G. Therasse Avenue, 1, 5530 Yvoir, Belgium  
e-mail: remacle@orlo.ucl.ac.be

H. Eckel  
Department of Oto–rhino–laryngology and Head & Neck  
Surgery, Regional Hospital, Klagenfurt, Austria

P. Bradley  
Department of Oto–rhino–laryngology and Head & Neck  
Surgery, Queens Medical Centre, Nottingham, NG7 5EU, UK

D. Chevalier  
Department of Oto–rhino–laryngology and Head & Neck  
Surgery, Hospital Claude Huriez, University of Lille, Lille, France

V. Djukic  
Department of Oto–rhino–laryngology and Head & Neck  
Surgery Medical Center, University of Belgrade, Belgrade,  
Yugoslavia

M. de Vicentiis  
Hospital La Sapienza, University of Rome, Rome, Italy

G. Friedrich  
Department of Oto–rhino–laryngology and Head & Neck  
Surgery, University Hospital of Graz, Graz, Austria

J. Olofsson  
Department of Oto–rhino–laryngology and Head & Neck  
Surgery, University Hospital of Brescia, Brescia, Italy

G. Peretti  
Department of Oto–rhino–laryngology and Head & Neck  
Surgery, University Hospital of Bergen, Bergen, Norway

M. Quer  
Department of Oto–rhino–laryngology and Head & Neck  
Surgery, Hospital Sant Pau, Barcelona, Spain

J. Werner  
Department of Oto–rhino–laryngology and Head & Neck  
Surgery, University Hospital of Marburg, Marburg, Germany

of different laryngeal endoscopic cordectomies, so as to reach better agreement and uniformity concerning the extent and depth of resection of cordectomy procedures (guidelines) and to offer reproducibility to the majority of laryngologists to allow relevant comparisons with the literature when presenting/publishing the results of cordectomies. The classification described eight types of cordectomies: a subepithelial cordectomy (type I), which is the resection of the vocal fold epithelium passing through the superficial layer of the lamina propria; a sublignamental cordectomy (type II), which is the resection of the epithelium, Reinke's space and the vocal ligament; transmuscular cordectomy (type III), which proceeds through the vocalis muscle; total cordectomy (type IV), which extends from the vocal process to the anterior commissure. The depth of the surgical margins reaches the internal perichondrium of the thyroid ala, and sometimes the perichondrium is included in the resection. Type Va cordectomy is an extended cordectomy encompassing the contralateral vocal fold and the anterior commissure. Type Vb is an extended cordectomy, which includes the arytenoids; type Vc encompasses the subglottis; and type Vd includes the ventricle.

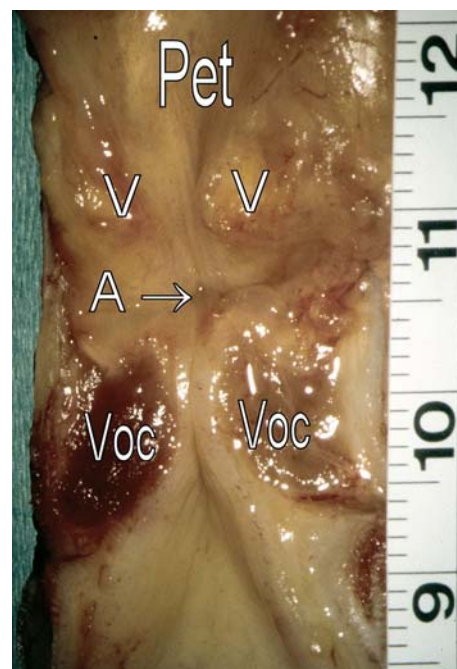
This classification has been well received and is currently used by many authors: 24 articles making references to the ELS classification of cordectomy were found through the science citation index [1, 4, 6, 13, 14, 24, 25, 27–34, 36–39, 41, 42, 49–51], as well as 3 chapters of major books on larynx cancer surgery [3, 15, 16].

However, this classification did not propose any specific management for lesions originating in the anterior commissure, which have been included so far among the indications for type Va cordectomy (extended cordectomy encompassing the contralateral vocal fold and the anterior commissure). This situation was a source of discussion and possible confusion when comparing results from different studies.

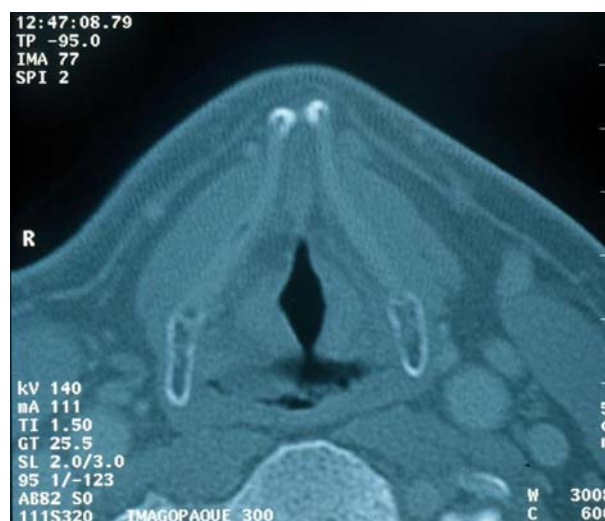As a means to resolve this problem, a new cordectomy, encompassing the anterior commissure and the anterior part of both vocal folds, or type VI cordectomy is proposed by the ELS Working Committee on Nomenclature.

### Description of the type VI cordectomy

Type VI cordectomy is indicated for cancer originating in the anterior commissure (Figs. 1, 2), extended or not to one or both vocal folds, without infiltration of the thyroid cartilage (Fig. 1a, b). This is an anterior commissurectomy with bilateral anterior cordectomy (Fig. 3a, b). If the tumor is in close contact with the cartilage, resection can encompass the anterior angle of the thyroid cartilage. To remove the Broyle's ligament, the incision has to be started above the insertion plane of the vocal folds, at the base of the epiglottic

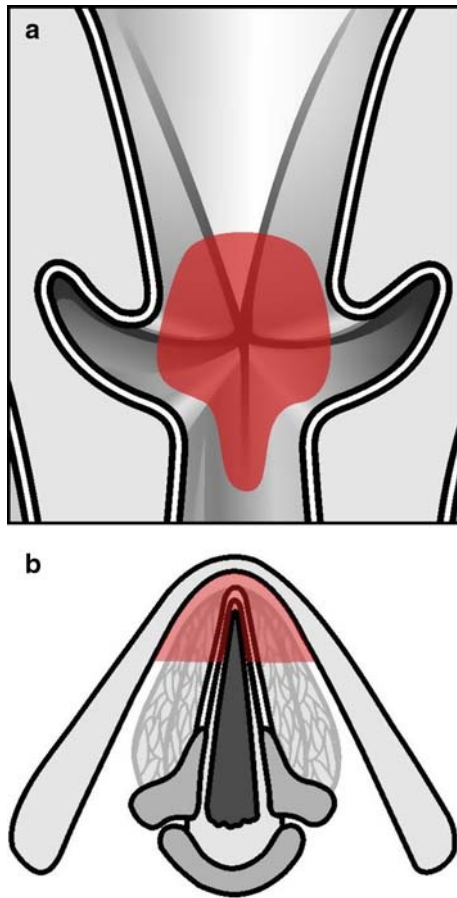


**Fig. 1** View of the anterior commissure—frontal plane, human specimen larynx; *Pet* petiole, *V* ventricular fold, *A* anterior commissure, *Voc* vocal fold



**Fig. 2** CT scan—axial plane—glottic level

insertion, and is extended through the Broyle's ligament. To achieve this resection, it may be necessary to resect the petiole of the epiglottis to ensure sufficient visualization (Figs. 4, 5a, b). Resection of the anterior commissure may include the subglottic mucosa and the cricothyroid membrane [10], because cancers of the anterior commissure tend to spread towards the lymphatic vessels of the subglottic area [18]. In order to expose properly the anterior part of the vocal folds, partial resection of the ventricular folds may be necessary.

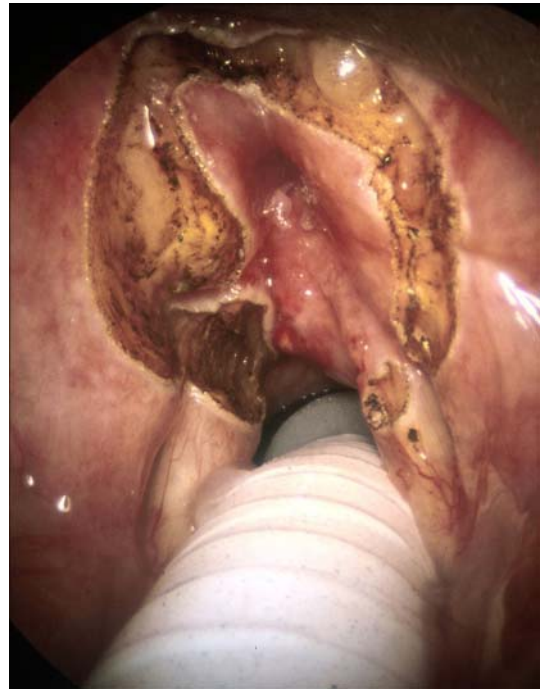

**Fig. 3** **a** Type VI cordectomy: anterior bilateral cordectomy and commissurectomy. **b** Resection commissure

## Discussion

The anterior commissure has been recognized as the sub site in the larynx that is more frequently at risk to give rise to local treatment failures than others. This holds true for initial radiotherapy as well as for some conventional partial laryngectomies and transoral laser surgery. Therefore, it is not surprising that local recurrences were more frequently noted at the anterior commissure than at any other sub site of the larynx. In a series of 252 patients treated with transoral laser surgery alone, the anterior commissure was most frequently affected when local recurrences occurred in the larynx. It was involved in 13 (37.1 %) of the 35 cases of local recurrence [9]. For this reason, endoscopic laser resection, usually, has repeatedly been discouraged for anterior commissure carcinoma, because of inadequate exposure and close proximity to underlying cartilage.

Anatomically, the anterior commissure is characterized by the lack of perichondrium on the inner surface of the

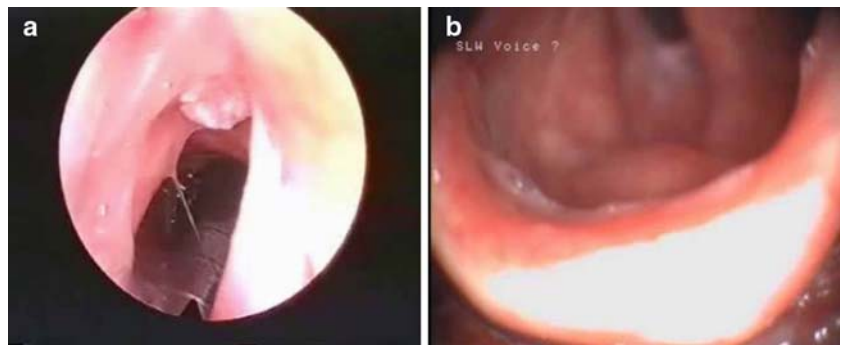


**Fig. 4** Endoscopic view: carcinoma of the anterior commissure—limits of resection

thyroid cartilage. Traditionally, it has been thought that this anatomical feature facilitates the spread of carcinoma arising from the anterior commissure into the thyroid cartilage and beyond the laryngeal framework. However, the tight fibrous tissue of the anterior commissure tendon, known as Broyle's ligament, should be as solid a barrier to the spread of cancer as a layer of perichondrium. The main peculiarity of the anterior commissure probably is that the supraglottic, glottic and subglottic compartments of the larynx are only 2–4 mm apart from one another (Figs. 1, 2, 3a, b). Therefore, even very small tumors of the anterior commissure gain access to the lymphatic system of the supraglottic and the subglottis, allowing a further spread of cancer cells within these lymphatic vessels [46]. In endolaryngeal surgery, proper and complete exposition of the anterior commissure can be particularly difficult due to the narrow-angled and V-shaped configuration of the thyroid alae (particularly in male patients, Fig. 2). In addition, the petiole of the epiglottis frequently obstructs a complete visualization of the most anterior portion of the anterior commissure. These peculiarities of tumors originating from the anterior commissure has prompted the authors to revise the ELS classification of different laryngeal endoscopic cordectomies first published in 2000.

The aim of this classification is not to define or set indications. In fact, as previously reported by the co-authors of this article, the indications may vary [11]. However, we believe that a common classification of cordectomies is necessary in order to understand and compare postoperative

**Fig. 5** **a** Limited cancer of the anterior commissure. **b** Postoperative control



results following different types of cordectomies that are based on each surgeon's own indications. Furthermore, this system serves another purpose: to improve the teaching and training of inexperienced laryngologists. We believe that non-standardized surgery, which requires years of training to understand its limits, offers little reproducibility to the majority of laryngologists. All reproducible techniques have guidelines.

Indications for performing those cordectomies may vary from surgeon to surgeon. Gallo et al. [13] concluded that less local recurrences and less evolution to microinvasive carcinoma are obtained after type III cordectomy, in comparison with type I cordectomy, in case of laryngeal intraepithelial neoplasia, LIN 2 and LIN 3 [5, 12]. In another study, Gallo et al. [14] performed 15 type III cordectomies (12Tis, 3T1a), 102 type IV cordectomies (T1a) and 39 type Va cordectomies (15 T1a and 24 T1b). Peretti et al. [29, 31, 32] treated selected cases according to the ELS classification: type III cordectomy was indicated for lesions after previous biopsy, type IV cordectomy for tumors involving the anterior part of the vocal cord and type V cordectomy for lesions involving the anterior commissure and the contralateral vocal cord. Krengli et al. [19] performed 10 type III cordectomies and 20 type IV cordectomies for T1a lesions. In a recent study, Peretti et al. [33] performed 11 type IV cordectomies and 44 type V cordectomies for 55 cT2 glottic lesions. According to these studies, type Va cordectomy was used for very different lesions ranging from T1a to T2.

Type V cordectomies addressed so far lesions arising in the anterior commissure as well as lesions from one vocal cord extended to the anterior commissure, possibly encompassing a part of the contralateral vocal cord.

Procedures too different in extension were performed to address these lesions too different in their presentation, possibly inducing bias when comparing the oncological and voice results [17]. Type VI cordectomy should clarify this situation.

It must be remembered that what is performed is a resection, providing a good specimen for histological assessment, and not a tissue vaporization [23].

Peretti et al. [31] confirmed, as previously observed [7–10, 26, 28, 29, 40, 47, 53], that anterior commissural involvement at the glottic level does not negatively influence oncologic outcomes after endoscopic resection and does not require a two-staged surgery as it was proposed [6].

However, phonatory outcome following transoral laser surgery for cancer, at the anterior commissure, may be unsatisfactory and require additional phonosurgery in individual patients [44, 45].

Assessment of the anterior commissure is based on angled rigid telescopes [2] and CT examination to exclude a possible tumoral infiltration through the thyroid cartilage.

In this regard, Zeitels [52] recommends a microlaryngoscopic infra-petiole exploration of the supraglottis for exposure of the anterior commissure. Steiner [48] removed a part of the thyroid cartilage by endoscopic approach in case of any cartilage infiltration. But for the majority, tumoral infiltration of the thyroid cartilage is a contraindication to endoscopic approach [20]. In this case, an open neck partial laryngectomy (fronto-anterior laryngectomy with epiglottoplasty [22] or crico-hyo-epiglottopexy [21]) can be indicated.

A “window” laryngoplasty with resection of the anterior angle of the thyroid cartilage, according to Shapshay, is a possible option [43].

## Conclusion

Type VI cordectomy, specially designed for anterior commissure carcinoma, is a useful addition to the ELS classification of endoscopic cordectomies. It should allow better comparison of oncological and functional results after endoscopic surgery in this indication.

## References

1. Altuna X, Zulueta A, Algaba J (2005) CO<sub>2</sub> laser cordectomy as a day-case procedure. *J Laryngol Otol* 119(10):770–773

2. Andrea M, Dias O (1995) Atlas of rigid and contact endoscopy in microlaryngeal surgery. Lippincott-Raven, Philadelphia
3. Ambrosch P (2005) Ch 6 Lasers for malignant lesions of the upper aerodigestive tract in Lasers on Otorhinolaryngology. In: Hüttenbrink KB (eds) Thieme, Stuttgart, pp 113–141
4. Beitler JJ, Johnson JT (2003) Transoral laser excision for early glottic cancer. *Int J Radiat Oncol Biol Phys* 56(4):1063–1066
5. Crissman JD, Fu YS (1986) Intraepithelial neoplasia of the larynx A clinicopathologic study of six cases with DNA analysis. *Arch Otolaryngol Head Neck Surg* 112:522–528
6. Damm M, Sittel C, Streppel M, Eckel HE (2000) Transoral CO<sub>2</sub> laser for surgical management of glottic carcinoma in situ. *Laryngoscope* 110(7):1215–1221
7. Davis RK, Hadley K, Smith ME (2004) Endoscopic vertical partial laryngectomy. *Laryngoscope* 114(2):236–240
8. Desloge RB, Zeitels SM (2000) Endolaryngeal microsurgery at the anterior glottal commissure: controversies and observations. *Ann Otol Rhinol Laryngol* 109(4):385–392
9. Eckel HE (2001) Local recurrences following transoral laser surgery for early glottic carcinoma: frequency, management and outcome. *Ann Otol Rhinol Laryngol* 110:7–15
10. Eckel HE, Thumfart WF (1992) Laser surgery for the treatment of larynx carcinomas: indications, techniques and preliminary results. *Ann Otol Rhinol Laryngol* 101(2Pt1):113–118
11. Eckel HE, Thumfart WF, Jungehülsing M, Sittel C, Stennert E (2000) Transoral laser surgery for early glottic carcinoma. *Eur Arch Otorhinolaryngol* 257:221–226
12. Friedman I (1986) Nose, throat and ears. Churchill Livingstone, Edinburgh
13. Gallo A, de Vincentiis M, Della Rocca C, Moi R, Simonelli M, Minni A, Shaha AR (2001) Evolution of precancerous laryngeal lesions: a clinicopathologic study with long-term follow-up on 259 patients. *Head Neck* 23(1):42–47
14. Gallo A, de Vincentiis M, Manciooco V, Simonelli M, Fiorella ML, Shah JP (2002) CO<sub>2</sub> laser cordectomy for early-stage glottic carcinoma: a long-term follow-up of 156 cases. *Laryngoscope* 112(2):370–374
15. Guerrier B, Giovanni A, Remacle M, Chevalier D, Lacau St Guily J, Lefebvre JL, Marie JP, Rey E, Wagner I, Woisard V (2004) Troisième partie, Pathologie tumorale des cordes vocales. ch III. Les cordectomies endoscopiques in Pathologie de corde vocale chez l'adulte. In: Guerrier B, Giovanni A, Remacle M (eds) Soc Française d'Orl et Chirurgie cervico-faciale, Paris, pp 359–373
16. Kacker A, Wolden S, Pfister DG, Kraus DH (2003) Ch 15 cancer of the larynx in cancer of the head and neck. In: Myers EN, Suen JY, Myers JN, Hanna EYN (eds) 4th edn. Saunders, Philadelphia, pp 333–377
17. Kaiser TN, Sessions DG, Harvey JE (1989) Natural history of treated T1N0 squamous carcinoma of the glottis. *Ann Otol Rhinol Laryngol* 98(3):217–219
18. Kirschner JA (1984) Invasion of the framework by laryngeal cancer. Surgical and radiological implications. *Acta Otolaryngol (Stockh)* 97(5–6):392–397
19. Krengli M, Policarpo M, Manfreda I, Aluffi P, Gambaro G, Pannella M, Pia F (2004) Voice quality after treatment for T1a glottic carcinoma—radiotherapy versus laser cordectomy. *Acta Oncol* 43(3):284–289
20. Krespi YP, Meltzer CJ (1989) Laser surgery for vocal cord carcinoma involving the anterior commissure. *Ann Otol Rhinol Laryngol* 98(2):105–109
21. Laccourreye O, Muscatello L, Laccourreye L, Naudo P, Brasnu D, Weinstein G (1997) Supracricoid partial laryngectomy with cricohyoidopiglottopexy for “early” glottic carcinoma classified as T1-T2N0 invading the anterior commissure. *Am J Otolaryngol* 18(6):385–390
22. Lawson G, Jamart J, Remacle M (2001) Improving the functional outcome of Tucker's reconstructive laryngectomy. *Head Neck* 23(10):871–878
23. Mahieu HF, Patel P, Annys AA, van der Laan T (1994) carbon dioxide laser vaporization in early glottic carcinoma. *Arch Otolaryngol Head Neck Surg* 120(4):383–387
24. Maurizi M, Almadori G, Plaudetti G, De Corso E, Galli J (2005) Laser carbon dioxide cordectomy versus open surgery in the treatment of glottic carcinoma: our results. *Otolaryngol Head Neck Surg* 132(6):857–861
25. McWhorter AJ, Hoffman HT (2005) Transoral laser microsurgery for laryngeal malignancies. *Curr Probl Cancer* 29(4):180–189
26. Pearson BW, Salassa JR (2003) Transoral laser microresection for cancer of the larynx involving the anterior commissure. *Laryngoscope* 113(7):1104–1112
27. Peeters AJ, van Gogh CD, Goor KM, Verdonck-de Leeuw IM, Langendijk JA, Mahieu HF (2004) Health status and voice outcome after treatment for T1a glottic carcinoma. *Eur Arch Otorhinolaryngol* 261(10):534–540
28. Peretti G, Nicolai P, Piazza C, Redaelli de Zinis LO, Valentini S, Antonelli AR (2001) Oncological results of endoscopic resections of Tis and T1 glottic carcinomas by carbon dioxide laser. *Ann Otol Rhinol Laryngol* 110(9):820–826
29. Peretti G, Piazza C, Balzanelli C, Cantarella G, Nicolai P (2003) Vocal outcome after endoscopic cordectomies for Tis and T1 glottic carcinomas. *Ann Otol Rhinol Laryngol* 112(2):174–179
30. Peretti G, Piazza C, Berlucchi M, Cappiello J, Giudice M, Nicolai P (2003) Pre- and intraoperative assessment of mid-cord erythro-leukoplakias: a prospective study on 52 patients. *Eur Arch Otorhinolaryngol* 260(10):525–528
31. Peretti G, Piazza C, Balzanelli C, Mensi MC, Rossini M, Antonelli AR (2003) Preoperative and postoperative voice in Tis-T1 glottic cancer treated by endoscopic cordectomy: an additional issue for patient counseling. *Ann Otol Rhinol Laryngol* 112(9Pt1):759–763
32. Peretti G, Piazza C, Bolzoni A, Mensi MC, Rossini M, Parrinello G, Shapshay SM, Antonelli AR (2004) Analysis of recurrences in 322 Tis, T1, or T2 glottic carcinomas treated by carbon dioxide laser. *Ann Otol Rhinol Laryngol* 113(11):853–858
33. Peretti G, Piazza C, Mensi MC, Magnoni L, Bolzoni A (2005) Endoscopic treatment of cT2 glottic carcinoma: prognostic impact of different pT subcategories. *Ann Otol Rhinol Laryngol* 114(8):579–586
34. Puxeddu R, Piazza C, Mensi MC, Ledda GP, Argiolas F, Peretti G (2004) Carbon dioxide laser salvage surgery after radiotherapy failure in T1 and T2 glottic carcinoma. *Otolaryngol Head Neck Surg* 130(1):84–88
35. Remacle M, Eckel HE, Antonelli A, Brasnu D, Chevalier D, Friedrich G, Olofsson J, Rudert HH, Thumfart W, de Vincentiis M, Wustrow TP (2000) Endoscopic cordectomy. A proposal for a classification by the Working Committee, European Laryngological Society. *Eur Arch Otorhinolaryngol* 257(4):227–231
36. Remacle M, Lawson G, Hedayat A, Trussart T, Jamart J (2001) Medialization framework surgery for voice improvement after endoscopic cordectomy. *Eur Arch Otorhinolaryngol* 258(6):267–271
37. Remacle M, Friedrich G, Dikkers FG, de Jong F (2003) Phonosurgery of the vocal folds: a classification proposal. *Eur Arch Otorhinolaryngol* 260(1):1–6
38. Remacle M, Hassan F, Cohen D, Lawson G, Delos M (2005) New computer-guided scanner for improving CO<sub>2</sub> laser-assisted microincision. *Eur Arch Otorhinolaryngol* 262(2):113–119
39. Roh JL, Yoon YH (2005) Prevention of anterior glottic stenosis after bilateral vocal fold stripping with mitomycin C. *Arch Otolaryngol Head Neck Surg* 131(8):690–695
40. Rudert HH, Werner JA (1995) Endoscopic resections of glottic and supraglottic carcinomas with the CO<sub>2</sub> laser. *Eur Arch Otorhinolaryngol* 252(3):146–148

41. Rucci L, Romagnoli P, Casucci A, Ferlito A (2004) Embryological study of the glottic site and clinical implications. *Oral Oncol* 40(10):1017–1025
42. Schindler A, Palonta F, Preti G, Ottaviani F, Schindler O, Cavalot AL (2004) Voice quality after carbon dioxide laser and conventional surgery for T1A glottic carcinoma. *J Voice* 18(4):545–550
43. Shapshay SM, Wang Z, Rebeiz EE, Perrault DF Jr, Pankratov MM (1994) Window” laryngoplasty: a new combined laser endoscopic and open technique for conservation surgery. *Ann Otol Rhinol Laryngol* 103(9):679–685
44. Sittel C, Eckel HE (1998) Eschenburg: phonatory results following laser surgery for glottic carcinoma. *Otolaryngol Head Neck Surg* 119:418–424
45. Sittel C, Friedrich G, Zorowka P, Eckel HE (2002) Surgical voice rehabilitation after laser surgery for glottic carcinoma. *Ann Otol Rhinol Laryngol* 111:493–499
46. Sprinzl GM, Eckel HE, Sittel C, Potoschnig C, Koebke J (1999) Morphometric measurements of the cartilaginous larynx: an anatomic correlate of laryngeal surgery. *Head Neck* 21:743–750
47. Steiner W (1993) Results of curative laser microsurgery of laryngeal carcinomas. *Am J Otolaryngol* 14(2):116–121
48. Steiner W, Ambrosch P, Rodel RM, Kron M (2004) Impact of anterior commissure involvement on local control of early glottic carcinoma treated by laser microresection. *Laryngoscope* 114(8):1485–1491
49. Su CY, Chuang HC, Tsai SS, Chiu JF (2005) Bipedicled strap muscle transposition for vocal fold deficit after laser cordectomy in early glottic cancer patients. *Laryngoscope* 115(3):528–533
50. Tamura E, Kitahara S, Ogura M, Kohno N (2003) Voice quality after laser surgery or radiotherapy for T1a glottic carcinoma. *Laryngoscope* 113(5):910–914
51. Wedman J, Heimdal JH, Elstad I, Olofsson J (2002) Voice results in patients with T1 glottic cancer treated by radiotherapy or endoscopic measures. *Eur Arch Otorhinolaryngol* 259(10):547–550
52. Zeitels SM (1998) Infrapetiole exploration of the supraglottis for exposure of the anterior glottal commissure. *J Voice* 12(1):117–122
53. Zeitels SM, Dailey SH, Burns JA (2004) Technique of en block laser endoscopic frontolateral laryngectomy for glottic cancer. *Laryngoscope* 114(1):175–180