



# Five-year polyethylene cup migration and PE wear of the Anatomic Dual Mobility acetabular construct

Peter Bo Jørgensen<sup>1</sup> · Bart L. Kaptein<sup>2</sup> · Kjeld Søballe<sup>1,3</sup> · Stig S. Jakobsen<sup>3</sup> · Maiken Stilling<sup>1,3</sup>

Received: 23 August 2022 / Accepted: 7 January 2023 / Published online: 21 February 2023  
© The Author(s), under exclusive licence to Springer-Verlag GmbH Germany, part of Springer Nature 2023

## Abstract

**Introduction** Dual mobility implants have been successful in reducing postoperative hip dislocation but mid-term results of cup migration and polyethylene wear are missing in the literature. Therefore, we measured migration and wear at 5-year follow-up using radiostereometric analysis (RSA).

**Materials and methods** A cohort of 44 patients (mean age 73, 36 female) with heterogeneous indications for hip arthroplasty but all with a high risk of hip dislocation received total hip replacement (THA) with The Anatomic Dual Mobility X3 monoblock acetabular construct and a highly crosslinked polyethylene liner.

RSA images and Oxford Hip Scores were obtained perioperatively and 1, 2, and 5 years postoperatively. Cup migration and polyethylene wear were calculated using RSA.

**Results** Mean 2-year proximal cup translation was 0.26 mm (95% CI 0.17; 0.36). Proximal cup translation was stable from 1- to 5-year follow-up. Mean 2-year cup inclination (z-rotation) was 0.23° (95% CI – 0.22; 0.68) and was greater in patients with osteoporosis compared to patients without osteoporosis ( $p=0.04$ ). Using 1-year follow-up as baseline, the 3D polyethylene wear rate was 0.07 mm/year (0.05; 0.10).

Oxford hip scores improved 19 (95% CI 14; 24) points from mean 21 (range 4; 39) at baseline, to 40 (9; 48) 2 years postoperatively. There were no progressive radiolucent lines > 1 mm. There was 1 revision for offset correction.

**Conclusions** Anatomic Dual Mobility monoblock cups were well-fixed, the polyethylene wear rate was low, and the clinical outcomes were good until 5-year follow-up suggesting good implant survival in patients of different age groups and with heterogeneous indications for THA.

**Keywords** Dual mobility · Hip arthroplasty · HXLPE · Polyethylene wear · Cup fixation · Radiostereometric analysis · Wear rate

## Introduction

Dislocation, aseptic loosening, and polyethylene (PE) wear are among the greatest causes for total hip arthroplasty (THA) revisions and underline the importance of a mechanically stable, well-fixed acetabular cup with low PE wear profiles [1]. Several studies have shown that dual mobility (DM) cups reduce the risk of dislocation and the associated risk of cup revision in THA [2–4]. Factors that increase the risk of THA dislocation include previous THA dislocation, hip dysplasia, old age, hip fracture, high fall-risk, and dementia. Patients at greater risk of a priori THA dislocation may have a high benefit of DM THA in particular [3, 4]. In addition, frail and elderly patients often have low bone mineral density (BMD), which has been associated with increased early cup migration of cemented as well as cementless DM

✉ Peter Bo Jørgensen  
pbjr@clin.au.dk

<sup>1</sup> AutoRSA Research Group, Orthopaedic Research Unit, Aarhus University Hospital, Palle Juul-Jensens Boulevard 165, 8200 Aarhus N, Denmark

<sup>2</sup> Biomechanics and Imaging Group, Department of Orthopaedics, Leiden University Medical Center, Leiden, The Netherlands

<sup>3</sup> Department of Orthopaedic Surgery, Aarhus University Hospital, Palle Juul-Jensens Boulevard 165, 8200 Aarhus N, Denmark

cups in patients with osteoarthritis [5, 6]. Particularly, early proximal cup translation and sagittal rotation has been associated with increased risk of later aseptic implant loosening [7, 8]. However, also the cup migration pattern has become increasingly important to evaluate lasting fixation and therefore mid-term and long-term studies are needed.

The use of highly cross-linked PE (HXLPE) has improved the mechanical PE wear properties in THA [9]. However, the in vivo liner movements and double PE articulation in DM THA may increase PE wear [10]. In addition, for cementless cups, PE wear can be accelerated by third body wear from hydroxyapatite coating particles. High PE wear may result in osteolysis, cup loosening, and risk of THA revision [11].

In this study, we evaluated the 5-year migration and PE wear of a DM acetabular construct in a patient cohort of 44 patients.

## Material and methods

### Patients

From 2015 to 2016, a consecutive cohort of 44 patients (mean age (range)73 (41–94), 36 female) was operated with an Anatomic Dual Mobility (ADM) (Stryker Orthopaedics, Warsaw, Mazovia, Poland) acetabular construct, in our institution. The patients were registered in a continuous clinical RSA database, which was registered with the Danish Data Protection Agency [1-16-02-54-14]. The Central Denmark Region Committees on Health Research Ethics did not consider the project notifiable according to Danish law number. 593 of June 14th 2011 on science ethics treatment of health science research projects.

Indications for operation were primary osteoarthritis ( $n=33$ ), hip fracture ( $n=5$ ), femoral head necrosis ( $n=1$ ), and revision of THA ( $n=5$ ). Indication for dual mobility followed an internal algorithm in the department (Table S1). All patients consented orally to 10 years of follow-up in the clinical RSA database. Oxford hip score (OHS) and DXA-scan were completed preoperatively. RSA examinations were completed postoperatively. OHS and RSA exams continued at 1-, 2-, and 5-year follow-up.

### Operation and implants

All patients were operated using the posterolateral access and all cups were ADM acetabular component with a highly crosslinked X3 liner (Stryker Orthopaedics, Warsaw, Mazovia, Poland) and 28 mm heads. The ADM cup combines the DM polyethylene concept with a cementless fixation of a monoblock cobalt chrome shell with porous titanium and hydroxyapatite plasma-sprayed coating (Stryker Orthopaedics, Warsaw, Mazovia, Poland). The femoral heads were

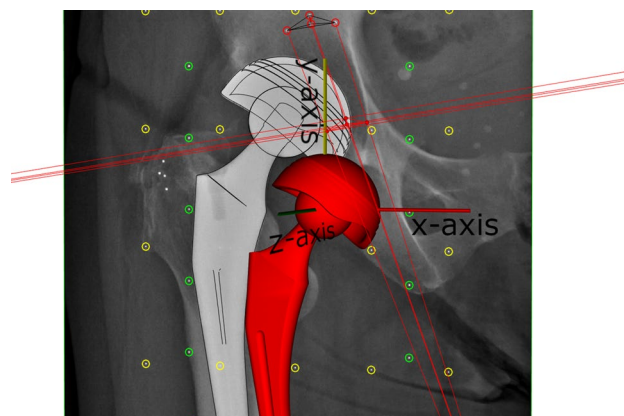
either CoCr; lift ( $n=29$ ) modular ( $n=2$ ) (Stryker Orthopaedics, Warsaw, Mazovia, Poland), Versys ( $n=5$ ) (ZimmerBiomet, Warzaw, IN) or stainless steel; Bioball ( $n=1$ ) (Merete, Berlin, Germany) or ceramic; Biolox delta ( $n=9$ ) (Stryker Orthopaedics, Warsaw, Mazovia, Poland). The stems used were: ExeterV40 ( $n=30$ ), Accolade II ( $n=5$ ) and Modular Hip System ( $n=3$ ) (Stryker Orthopaedics, Warsaw, Mazovia, Poland), CPT ( $n=4$ ), BiMetric ( $n=1$ ) (ZimmerBiomet, Warzaw, IN), and one calcar supported stem (Hipokrat, Turkey).

### DXA, RSA, and radiography

Preoperative DXA-scans were performed on a GE Lunar iDXA scanner (General Electric, Chicago, IL, USA), an analyzed using the encore software. Patients with a  $T$ -score  $< -2.5$  were diagnosed with osteoporosis and referred to a specialist for further treatment.

RSA recordings with the patient in supine position were obtained using the AdoraRSA Suite (Nordic X-ray Technique, Hasselager, Aarhus, Denmark). Two ceiling mounted X-ray tubes were angled  $40^\circ$  on each other and we used a standard calibration box (cb24, Medis Specials, Leiden, Netherlands) and digital static detectors (CXDI-70C, Canon, Tokyo, Japan) with a resolution of 4 lp/mm. Analyses of PE wear and cup migration were performed by one investigator with Model-Based RSA 4.2 (RSACore, Leiden, The Netherlands). We used CAD surface implant models for the cup, an elementary geometric shape model for the femoral head and bone markers as the reference.

Cup migration was calculated as the cup displacement and rotation relative to acetabulum markers in the coordinate system of the calibration box (Fig. 1). The axes were adjusted to the anatomical coordinates of a right-side hip. In cases with occluded bone markers, a marker configuration



**Fig. 1** The migration and wear data were presented in the coordinate system of the calibration box and adjusted to comply with right-side anatomy

model was used if possible [12]. The maximum rigid body error was set to 0.35 mm and the maximum accepted condition number was 150 (Valstar et al. 2005). Three patients had condition numbers between 150 and 155. All three were included after examining the positions for linearity of the bone markers. One was analyzed using CM-model with mean fitting error of 0,15 and the mean error of rigid body fitting for the other two were 0.16. Cup migration of the three patients did not deviate from the group migrations. Reference marker configurations with condition numbers > 155 ( $n=4$ ) or migration in the reference markers ( $n=2$ ) were categorized as inadequate and the data excluded from the migration analysis. The average CN was 102 (95% CI 92; 112).

Wear measurements were given in the coordinate system of the calibration box. Wear was defined as displacement of the femoral head relative to the cup which includes wear of both the small and large articulation. Wear from postop to 1-year follow-up was defined as bedding-in, femoral head penetration was defined as wear from postop to last follow-up, and wear rate was the PE wear per year from 1-year to last follow-up. All three PE wear parameters were calculated for: proximal wear defined as wear in the  $y$ -direction, 2D wear defined as the length of the vectorial sum of  $x$ - and  $y$ -wear (frontal plane wear), and 3D wear defined by the length of the vectorial sum of  $x$ -,  $y$ - and  $z$ -wear.

Cup orientation (anteversion and inclination) was derived from the RSA recordings. We used the median value of all accessible RSA recordings. This was because the shape of the ADM shell would expectedly affect orientation measurement on standard radiographs.

Osteolysis and radiolucent lines were investigated using the final follow-up plain AP radiographs with reference to the postoperative radiograph [13]. In cases without final follow-up plain radiograph, the RSA radiographs were used.

## Patient-reported outcomes

The Oxford hip score measures the patient perceived hip pain and function. It is a validated tool for tracking changes over time and was filled out by the patients prior to operation and at 1-, 2- and 5-year follow-up. The minimal important change was set to 10 [14].

## Statistics

Migration, wear data, and OHS were evaluated for normal distribution using qq-plots.

Migration was dichotomized on patients with osteoporosis ( $T$ -score <  $-2.5$ ) and patients without osteoporosis ( $T$ -score >  $-2.5$ ) and compared using multivariate repeated measurement analysis with  $T$ -score and follow-up time as factors. Equality of standard deviation and

correlation was tested using multivariate test and residuals were examined using scatterplots. In addition, subgroup analysis on indications was performed using  $t$  test to evaluate eventual effect on migration. Correlation between wear and migration at 2- and 5-year follow-up was tested using Spearman's rank correlation. The cohort was dichotomized on femoral head material (metal/ceramic) in evaluation of polyethylene wear.

RSA precision was calculated on 33 double examinations [15]. The baseline recording formed the reference for migration in each of the double examination RSA analyses, and both the patient and the RSA equipment were repositioned between the two RSA recordings. The mean difference from the first to the second recording was the systematic difference (bias), and the variation between the two recordings (precision) was given as Coefficient of repeatability (CR) =  $1.96 \cdot \text{sd}$  of the differences.

Statistical significance was assumed at  $p < 0.05$ . Statistical calculations were performed using Stata (Stata/IC 16.1, StataCorp, College Station, TX, USA).

## Results

Of 44 patients originally operated, 24 completed the 5-year follow-up. The reasons for loss to follow-up were mainly health issues or death for reasons unrelated to the hip arthroplasty (Fig. 2). The baseline patient demographics are given in Table 1.

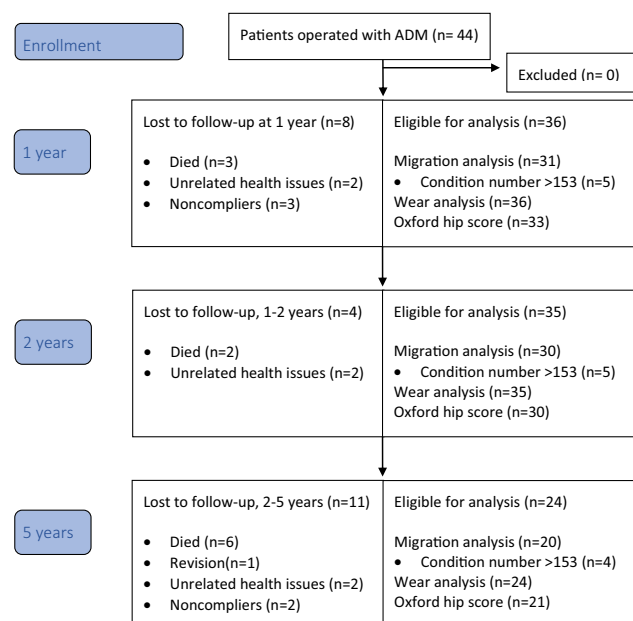


Fig. 2 Flowchart

**Table 1** Baseline demographics

	Patients (n = 44)
Age, mean (range)	73 (41–94)
Gender, male/female	8/36
T-score, mean (95% CI) (n = 42)	- 1.5 (- 1.9; - 1.2)
BMI, mean (range)	25 (16–39)
Oxford Hip Score, mean (95% CI) (n = 33)	21 (18;24)
Cup size, mean (range)	51 (46–56)
Side (right/left)	26/18
Cup anteversion (°), mean (range)	24 (6–46)
Cup inclination (°), mean (range)	43 (20–56)

**RSA precision**

Bias was < 0.01 mm for cup translations and < 0.1° for cup rotations. Precision (CR) was 0.1 mm for cup y-translations and 0.2 mm for cup x- and z-translation. CR was < 1° for cup z-rotations and < 2° for x- and y-rotations. For PE wear, the bias was < 0.03 mm for all PE wear parameters. CR was 0.1 mm for proximal and 2D wear measurements, and 0.3 mm for 3D wear measurements (Table 2).

**Cup migration**

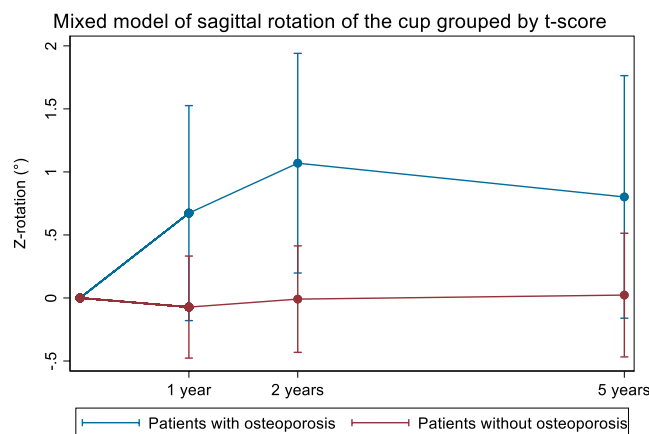
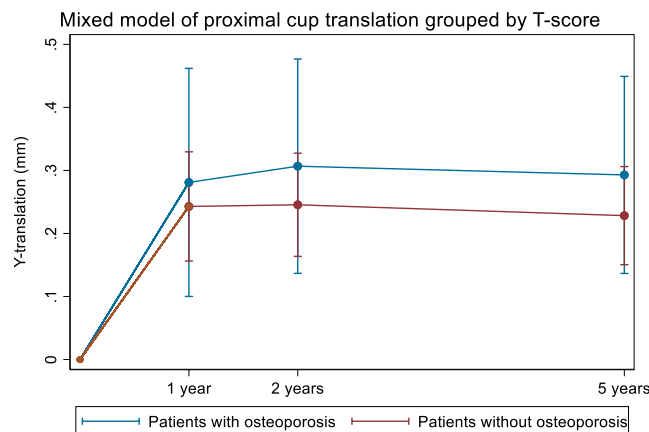
In the first year, the ADM cup had proximal translation of 0.28 mm (95% CI 0.19; 0.38 mm) and internal rotation of 0.48° (95% CI 0.06; 0.90). Hereafter, the translation and rotation stabilized (Figs. 3, 4, 5, Table 3).

At 2-year follow-up, patients with osteoporosis (n = 6) showed similar proximal migration; 0.06 mm (95% CI -0.14; 0.25, p = 0.55) and 1.1° (95% CI 0.1; 2.1, p = 0.04) more sagittal rotation than patients without osteoporosis (n = 26) (Fig. 3). The difference in sagittal rotation was no longer statistically significantly different at 5-year follow-up (p = 0.17). Subgroup analysis of osteoarthritis and other indications for THA showed no statistically differences in

**Table 2** Clinical precision of measurements

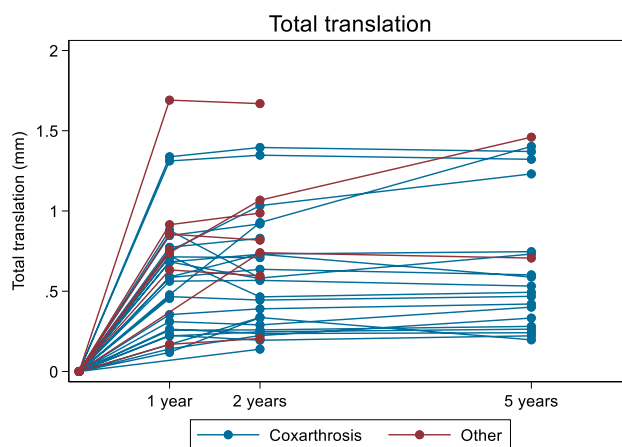
Cup migration	Bias	CR	PE wear	Bias	CR
tx (mm)	0	0.17	wx (mm)	-0.02	0.13
ty (mm)	0	0.09	wy (mm)	0.01	0.13
tz (mm)	0.01	0.2	wz (mm)	-0.03	0.32
rx (°)	-0.05	1.44			
ry (°)	-0.09	1.51	w2D (mm)	0	0.11
rz (°)	-0.02	0.75	w3D (mm)	-0.03	0.29

CR coefficient of repeatability



**Fig. 3** Multivariate repeated measures model of proximal cup migration and sagittal cup rotation grouped by T-score for each follow-up time

proximal migration or sagittal rotation at any timepoint (p > 0.23).



**Fig. 4** Total translation of the cup (vector sum of x-, y-, and z-translation)

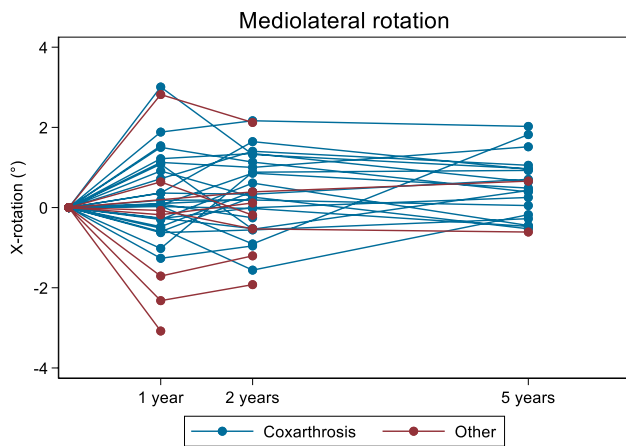


Fig. 5 Mediolateral rotation

**PE wear**

All wear parameters are reported in table 4. Bedding-in was 0.3 mm (95% CI 0.20 mm; 0.38 mm) in 3D, which also affected femoral head penetration in the PE (Fig. 6). Bedding-in was above one mm in two patients. These patients did not diverge from the cohort in terms of *t*-score (−0.4, 1.5) or age (80, 76). One was overweight (BMI 29) and one obese class II (BMI 39). A possible explanation may be impingement of soft-tissue at the time of the post-operative RSA. After 1 year, the 2D PE wear rate was 0.04 mm/year (95% CI 0.03; 0.06) and the 3D PE wear rate was 0.07 mm/year (95% CI 0.05; 0.09). Linear regression showed no correlation between BMI and 3D wear rate (slope 0.003, *p* = 0.2) or age and 3D wear rate (slope 0, *p* = 0.9). The 3D PE wear rate of 0.06 mm (95% CI 0; 0.11)

**Table 3** Mean (95%CI) cup migration relative to the reference markers in the acetabulum bone: x-translation (+medial/−lateral), y-translation (+proximal/−distal), z-translation (+anterior/−posterior), x-rotation (+anterior tilt/−posterior tilt), y-rotation (+internal/−external) and z-rotation (+increased/−decreased inclination)

	1 year	2 years	5 years
x-translation (mm)	0.08 (−0.10; 0.26)	0.11 (−0.07; 0.28)	0.26 (0.05; 0.47)
y-translation (mm)	0.28 (0.19; 0.38)	0.26 (0.17; 0.36)	0.27 (0.17; 0.37)
z-translation (mm)	0.06 (−0.08; 0.20)	0.10 (−0.05; 0.25)	0.15 (−0.06; 0.36)
x-rotation (°)	0.17 (−0.32; 0.65)	0.23 (−0.13; 0.59)	0.49 (0.15; 0.84)
y-rotation (°)	0.48 (0.06; 0.90)	0.65 (0.28; 1.02)	0.49 (−0.00; 0.99)
z-rotation (°)	0.16 (−0.25; 0.58)	0.23 (−0.22; 0.68)	0.25 (−0.24; 0.75)

**Table 4** Mean (95%CI) wear measures in 1, 2, and 3 dimensions

	Bedding-in	Femoral head penetration	Wear rate (annual)
Proximal (mm)	0.08 (0.02; 0.13)	0.08 (0.03; 0.14)	0.01 (−0.01; 0.02)
2D (mm)	0.18 (0.12; 0.25)	0.20 (0.13; 0.26)	0.05 (0.03; 0.06)
3D (mm)	0.30 (0.21; 0.38)	0.32 (0.24; 0.40)	0.07 (0.05; 0.10)

Bedding-in: postop to 1-year, femoral head penetration: postop to endpoint, and wear rate: 1-year to endpoint

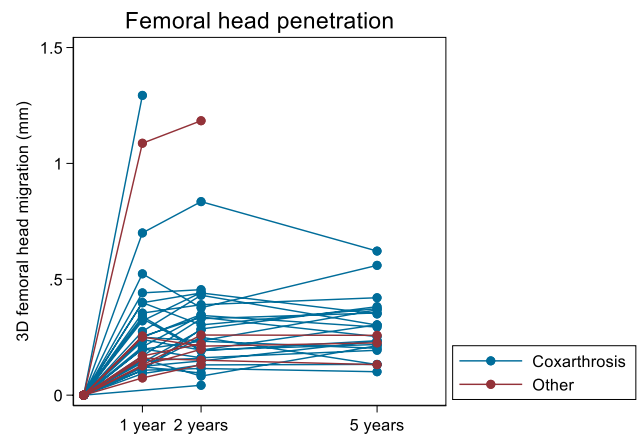


Fig. 6 3D femoral head penetration grouped by indication for operation

for ceramic femoral heads and of 0.08 mm (95% CI 0.05; 0.011) for metal femoral heads was similar (*p* = 0.38). PE wear rate > 0.1 mm was measured in 11 metal and 1 ceramic femoral head. Patients operated for osteoarthritis (*n* = 26) had a 3D wear rate of 0.06 mm/year (95% CI: 0.04; 0.09), while patients operated for other reasons (*n* = 6) had 3D wear rate of 0.11 mm/year (95% CI 0.05; 0.1) with no statistically significant difference (*p* = 0.08). Linear regression of PE wear rate neither correlated with cup proximal translation or cup sagittal rotation at 2- or 5-year follow-up nor with anteversion and inclination angle of the shell (slope < 0.3, *p* > 0.12).

Radiographic evaluation showed three patients with radiolucent lines in zone one or two. All of these were



reduced or unchanged compared to baseline evaluation. Two patients had radiolucent lines of 0.5 mm in zone one. One was reduced from 0.75 mm at baseline and one was not seen on baseline evaluation. No patients had sign of osteolysis at final follow-up.

### Clinical outcomes

OHS increased from mean 21 (range 4; 39) at baseline to mean 40 (range 9; 48) at 2-year follow-up and mean 43 (range 25; 48) at 5-year follow-up, which exceeded the minimal important difference of 10 points. The overall questionnaire response rate was 84%.

One patient received revision shortly after 2-year follow-up to correct for offset (−4 corrected to 0). During the 5-year period there were no incidents of dislocation or aseptic implant loosening.

### Discussion

This is the first study to present PE wear and cup migration of the ADM construct at mid-term follow-up. We found (1) low 3D PE wear rates with no association to BMI, age, operation indication, femoral head material (ceramics/metal) and cup position and (2) higher early cup proximal translation and sagittal rotation in patients with osteoporosis with stabilization of all cups after 1 year, but no difference in cup migration for patients with osteoarthritis versus other indications for THA.

### ADM cup migration

We found that cup migration mainly occurred within the first year and that the migration pattern stabilized between 1-year and 5-year follow-up. The 2-year proximal cup migration of 0.26 mm was higher than the 0.18 mm reported by Laende et al. for the same cup type (ADM) in younger patients (mean 63 years) [16]. It was also higher than the 0.09 mm reported by Tabori-Jensen et al. for the cementless Avantage dual mobility cup in a cohort of similar age (mean 75 years) and systemic BMD as in the present study [17]. The sagittal rotation of 0.23° (95% CI −0.22; 0.68) was similar to the 0.21° reported by Laende et al. but higher than the −0.01° reported by Tabori-Jensen et al. [6, 16]. We were unable to find migration studies on dual mobility cups with cohort composition of better similarity with the present study. The main reason for the slightly higher proximal cup migration in the present study is likely that we studied the patients in the target group for dual mobility THA, older patients with osteoporosis and heterogeneous indications for THA including primary

osteoarthritis, hip fracture, osteonecrosis, and revision THA. Importantly, cup migration stabilized in all patients 1 year after surgery despite the variation in BMD and indications for operation. This is very important since the use of dual mobility cups to protect for dislocation is preferred in patients with various indications for THA. We were unable to find migration studies on dual mobility cups with better similarity in the composition of the cohort.

### PE wear of the X3 liner

Patients were positioned supine for all recordings. Standing recording could potentially have caused the liner to move into another position and perhaps reveal a different measure of wear. However, the difference caused by patient position is likely small [18, 19]. Standing recordings introduce other difficulties like postoperative pain and soft tissue overlay, leading to poor image quality.

Wear in dual mobility cups may occur in the small articulation between the head and liner or in the large articulation between the liner and shell. The site of wear will greatly affect the volumetric wear (scaled by implant size). Therefore, wear of dual mobility cups cannot be directly compared to wear of single mobility cups. We found low 2D and 3D wear rates of the highly crosslinked X3 PE liner. We found a 2D wear rate of 0.05 mm/year for the X3 liner, which is lower than the 0.27 mm/year reported for the X3 HXLPE liner in another dual mobility (MDM, Stryker) cup measured with Martells method (hip analysis suite) [20] but close to the 0.009 mm/year reported on the ×3 liner in single mobility hip (Trident, Stryker) by Campbell et al. [21]. Deckard et al. reported mean cup inclination 54.6° which is also higher than the mean inclination of 43° reported in our study. This could indicate that dual mobility constructs do not necessarily protect against excessive wear due to high cup inclination as reported by Loving et al. [22].

Low wear rates of the X3 liner material have been supported in long-term studies in single mobility THA [21, 23, 24]. Laende et al. studied PE wear of the X3 liner in the ADM cup until 3-year follow-up, and found a 3D wear rate of 0.09 mm/year comparable to the 0.07 mm/year in our study, and like us concluded that most of the femoral head penetration took place in the bedding-in period before 1-year follow-up [16].

Ceramic femoral heads have been used for decades to decrease PE wear in articulation with ultra-high molecular weight polyethylene (UHMWPE) [25]. However, different femoral head materials in articulation with HXLPE have not yet been shown to affect the wear rate [26, 27]. The results of the present study are in line with these findings.

PE particles cause inflammation and activation of macrophages and osteoclasts, which leads to periprosthetic

osteolysis. Particles from first generations of crosslinked PE has been shown to have a larger percentage of debris of bioactive size  $< 1 \mu\text{m}$  compared to non-crosslinked [28]. The particle size of second generation HXLPE is similar to the particle size of conventional UHMWPE [29]; however, the particle load is lower in HXLPE. In single mobility THA, long-term PE wear of HXLPE liners has been associated with reduced osteolysis and aseptic cup loosening [30]. The combination of only one progressing radiolucent line and no osteolysis correlates well with the low wear found in this study.

## PE wear measurement

Dual mobility PE liner wears both in the large and the small articulation. The small articulation typically has a 28-mm femoral head size, which has been known to produce low wear rates in single mobility THA [31, 32]. The size of the large articulation between the liner and the cup depends on the cup size. In addition, the liner moves during function in both articulations [33]. Consequently, calculation of volumetric PE wear in DM THA is complicated. It has been suggested that the three-dimensional distance between the acetabular cup center and the femoral head center is the best measure for PE wear in DM constructs [34]. In this study, we presented proximal as well as 2D and 3D wear rates for comparison with the literature.

We calculated the PE wear rate using 1-year follow-up RSA images as baseline for the subsequent follow-ups. Thereby, we measured PE wear in any direction and the measures were not affected by PE bedding-in. We found 3D wear rates to be consistently higher than 2D wear rates using RSA for measurements. While 3D wear may be the most accurate way to measure wear, it also comes with a lower precision both in an RSA setup and in plain radiographs [35].

## Strengths and limitations

The precision of DM cup migration and PE wear in our study of corresponds well with the precision of proximal wear (range 0.02–0.11 mm) and 3D wear (range 0.16–0.28 mm) reported by Callary et al. [9] but is somewhat poorer than the precision of PE wear and cup translation ( $z$ -axis) presented by Laende et al. [16]. Especially, the PE wear and cup migration measured in the  $z$ -axis have higher precision in Laende et al.'s study. The reason may be found in the angulation of the X-ray tubes where Laende et al. used  $30^\circ$  and our setup used  $20^\circ$ . Furthermore, we accepted condition numbers for the acetabular bone reference up to 155, which may jeopardize precision. On the other hand, the anatomical cup shape improved model fitting and increased precision of the ADM cup compared to earlier findings CR of 0.35,

0.21, and 0.65 mm in  $x$ -,  $y$ - and  $z$ -translation and 1.56, 1.49  $0.36^\circ$  in  $x$ -,  $z$ - and  $y$ -rotation for single-mobility cup brands recorded on same equipment with the same analyst [36].

We included all consecutive patients operated in our institution in the period from March 2015 to October 2016 with an ADM acetabular construct. Thereby, the surgical indication for DM THA was representative for the great variety of patients in our hip department and included patients with hip fracture, osteoporosis, and THA revision—indications that are well known to cause higher risk of THA dislocation and migration. Patients with osteoporosis were referred to a specialist preoperatively. Any treatment given could have improved the cup fixation for patients with osteoporosis and reduced differences between patients with and without osteoporosis. Due to the Covid-19 pandemic and patient fragility, we only had a moderate compliance with questionnaires and follow-ups. Although, long-term implant survival may not be needed for frail elderly patients there is a continuously increasing lifetime expectancy and patients are quite active even at high-age wherefore good implant fixation, low PE wear and great function should be a priority, even for older patients, whom may not tolerate revision surgery.

## Conclusions

Anatomic Dual Mobility monoblock cups were well-fixed, the polyethylene wear rate was low, and the clinical outcomes were good until 5-year follow-up suggesting good implant survival in patients of different age groups and with heterogeneous indications for THA.

**Supplementary Information** The online version contains supplementary material available at <https://doi.org/10.1007/s00402-023-04774-5>.

**Author contributions** PBJ, KS, and MS formulated the study hypothesis and design. PBJ, SSJ, and MS ensured inclusion and data collection. PBJ and BLK performed RSA analysis. SSJ performed the radiographic evaluation. PBJ and MS performed the statistical data analysis. PBJ, BLK, SSJ, and MS interpreted the data. All authors were involved in the revision of the final manuscript.

**Funding** No funding was received for conducting this study.

**Availability of data and materials** The datasets generated and/or analyzed during the current study are not publicly available due to the sensitive nature of radiographic images, but are available from the corresponding author on reasonable request.

## Declarations

**Conflict of interest** The authors have no financial interests to disclose. BLK and MS are on the board of the International Radiostereometry Society.

**Ethics approval** The study was registered with the Danish Data Protection Agency [1-16-02-54-14]. The Central Denmark Region Commit-

tees on Health Research Ethics was approached and did not consider the project notifiable.

**Consent for publication** Not applicable.

## References

- DHR The Danish Hip Arthroplasty Register. National annual report. 2020.
- Kreipke R, Rogmark C, Pedersen AB, Karrholm J, Hallan G, Havelin LI, Makela K, Overgaard S (2019) Dual Mobility cups: effect on risk of revision of primary total hip arthroplasty due to osteoarthritis: a matched population-based study using the nordic arthroplasty register association database. *J Bone Jt Surg Am* 101(2):169. <https://doi.org/10.2106/JBJS.17.00841>
- Romagnoli M, Grassi A, Costa GG, Lazaro LE, Lo Presti M, Zaffagnini S (2019) The efficacy of dual-mobility cup in preventing dislocation after total hip arthroplasty: a systematic review and meta-analysis of comparative studies. *Int Orthop* 43(5):1071. <https://doi.org/10.1007/s00264-018-4062-0>
- Jonker RC, van Beers L, van der Wal BCH, Vogely HC, Parratte S, Castelein RM, Poolman RW (2020) Can dual mobility cups prevent dislocation without increasing revision rates in primary total hip arthroplasty? A systematic review. *Orthop Traumatol Surg Res* 106(3):509. <https://doi.org/10.1016/j.otsr.2019.12.019>
- Finnila S, Moritz N, Svedstro ME, Alm JJ, Aro HT (2016) Increased migration of uncemented acetabular cups in female total hip arthroplasty patients with low systemic bone mineral density. A 2-year RSA and 8-year radiographic follow-up study of 34 patients. *Acta Orthop* 87(1):48. <https://doi.org/10.3109/17453674.2015.1115312>
- Tabori-Jensen S, Mosegaard SB, Hansen TB, Stilling M (2020) Inferior stabilization of cementless compared with cemented dual-mobility cups in elderly osteoarthritis patients: a randomized controlled radiostereometry study on 60 patients with 2 years' follow-up. *Acta Orthop* 91(3):246. <https://doi.org/10.1080/17453674.2020.1720978>
- Nieuwenhuijse MJ, Valstar ER, Kaptein BL, Nelissen RG (2012) Good diagnostic performance of early migration as a predictor of late aseptic loosening of acetabular cups: results from ten years of follow-up with Roentgen stereophotogrammetric analysis (RSA). *J Bone Jt Surg Am* 94(10):874. <https://doi.org/10.2106/JBJS.K.00305>
- Pijls BG, Nieuwenhuijse MJ, Fiocco M, Plevier JW, Middeldorp S, Nelissen RG, Valstar ER (2012) Early proximal migration of cups is associated with late revision in THA: a systematic review and meta-analysis of 26 RSA studies and 49 survival studies. *Acta Orthop* 83(6):583. <https://doi.org/10.3109/17453674.2012.745353>
- Callary SA, Solomon LB, Holubowycz OT, Campbell DG, Munn Z, Howie DW (2015) Wear of highly crosslinked polyethylene acetabular components. *Acta Orthop* 86(2):159. <https://doi.org/10.3109/17453674.2014.972890>
- Jørgensen PB, Kaptein BL, Søballe K, Jakobsen SS, Stilling M (2022) Polyethylene liner motion in dual-mobility hip prostheses: static and dynamic radiostereometry in 16 patients 1 year after operation. *Acta Orthop* 93:375. <https://doi.org/10.2340/17453674.2022.2253>
- Stilling M, Rahbek O, Soballe K (2009) Inferior survival of hydroxyapatite versus titanium-coated cups at 15 years. *Clin Orthop Relat Res* 467(11):2872. <https://doi.org/10.1007/s11999-009-0796-8>
- Kaptein BL, Valstar ER, Stoel BC, Rozing PM, Reiber JH (2005) A new type of model-based Roentgen stereophotogrammetric analysis for solving the occluded marker problem. *J Biomech* 38(11):2330. <https://doi.org/10.1016/j.jbiomech.2004.09.018>
- De Lee JG, Charnley J (1976) Radiological demarcation of cemented sockets in total hip replacement. *Clin Orthop Relat Res* 121:20
- Beard DJ, Harris K, Dawson J, Doll H, Murray DW, Carr AJ, Price AJ (2015) Meaningful changes for the Oxford hip and knee scores after joint replacement surgery. *J Clin Epidemiol* 68(1):73. <https://doi.org/10.1016/j.jclinepi.2014.08.009>
- Valstar ER, Gill R, Ryd L, Flivik G, Borlin N, Karrholm J (2005) Guidelines for standardization of radiostereometry (RSA) of implants. *Acta Orthop* 76(4):563. <https://doi.org/10.1080/17453670510041574>
- Laende EK, Richardson CG, Dunbar MJ (2020) Migration and wear of a dual mobility acetabular construct at 3 years measured by radiostereometric analysis. *J Arthroplasty* 35(4):1109. <https://doi.org/10.1016/j.arth.2019.11.010>
- Tabori-Jensen S, Frolich C, Hansen TB, Bovling S, Homilius M, Stilling M (2018) Higher UHMWPE wear-rate in cementless compared with cemented cups with the Saturne(R) Dual-Mobility acetabular system. *Hip Int* 28(2):125. <https://doi.org/10.1177/1120700018768615>
- Digas G, Kärrholm J, Thanner J, Malchau H, Herberts P (2003) Highly cross-linked polyethylene in cemented THA: randomized study of 61 hips. *Clin Orthop Relat Res* 417:126. <https://doi.org/10.1097/01.blo.0000096802.78689.45>
- von Schewelov T, Onsten I, Markusson P, Carlsson A (2006) Weight bearing radiographs are not necessary for measurement of polyethylene penetration in total hip prostheses: a radiostereometric study of 111 patients examined in weight-bearing and supine position. *Acta Orthop* 77(1):104. <https://doi.org/10.1080/17453670610045768>
- Deckard ER, Azzam KA, Meneghini RM (2018) Contemporary dual mobility head penetration at five years: concern for the additional convex bearing surface? *J Arthroplasty* 33(7S):S280. <https://doi.org/10.1016/j.arth.2018.02.061>
- Campbell DG, Field JR, Callary SA (2010) Second-generation highly cross-linked X3 polyethylene wear: a preliminary radiostereometric analysis study. *Clin Orthop Relat Res* 468(10):2704. <https://doi.org/10.1007/s11999-010-1259-y>
- Loving L, Herrera L, Banerjee S, Heffernan C, Nevelos J, Markel DC, Mont MA (2015) Dual mobility bearings withstand loading from steeper cup-inclinations without substantial wear. *J Orthop Res* 33(3):398. <https://doi.org/10.1002/jor.22774>
- Lindalen E, Thoen PS, Nordsletten L, Høvik Ø, Röhrli SM (2019) Low wear rate at 6-year follow-up of vitamin E-infused cross-linked polyethylene: a randomised trial using 32- and 36-mm heads. *Hip Int* 29(4):355. <https://doi.org/10.1177/1120700018798790>
- Rames RD, Stambough JB, Pashos GE, Maloney WJ, Martell JM, Clohisey JC (2019) Fifteen-year results of total hip arthroplasty with cobalt-chromium femoral heads on highly cross-linked polyethylene in patients 50 years and less. *J Arthroplasty* 34(6):1143. <https://doi.org/10.1016/j.arth.2019.01.071>
- Stilling M, Nielsen KA, Soballe K, Rahbek O (2009) Clinical comparison of polyethylene wear with zirconia or cobalt-chromium femoral heads. *Clin Orthop Relat Res* 467(10):2644. <https://doi.org/10.1007/s11999-009-0799-5>
- Teeter MG, MacLean CJ, Somerville LE, Howard JL, McCalden RW, Lanting BA, Vasarhelyi EM (2018) Wear performance of cobalt chromium, ceramic, and oxidized zirconium on highly crosslinked polyethylene at mid-term follow-up. *J Orthop* 15(2):620. <https://doi.org/10.1016/j.jor.2018.05.018>
- Bergvinsson H, Sundberg M, Flivik G (2020) Polyethylene wear with ceramic and metal femoral heads at 5 years: a randomized



- controlled trial with radiostereometric analysis. *J Arthroplasty* 35(12):3769. <https://doi.org/10.1016/j.arth.2020.06.057>
28. Fisher J, McEwen HM, Tipper JL, Galvin AL, Ingram J, Kamali A, Stone MH, Ingham E (2004) Wear, debris, and biologic activity of cross-linked polyethylene in the knee: benefits and potential concerns. *Clin Orthop Relat Res* 428:114. <https://doi.org/10.1097/01.blo.0000148783.20469.4c>
  29. Dumbleton JH, D'Antonio JA, Manley MT, Capello WN, Wang A (2006) The basis for a second-generation highly cross-linked UHMWPE. *Clin Orthop Relat Res* 453:265. <https://doi.org/10.1097/01.blo.0000238856.61862.7d>
  30. Prock-Gibbs H, Pumilia CA, Meckmongkol T, Lovejoy J, Mumith A, Coathup M (2021) Incidence of osteolysis and aseptic loosening following metal-on-highly cross-linked polyethylene hip arthroplasty: a systematic review of studies with up to 15-year follow-up. *J Bone Jt Surg Am* 103(8):728. <https://doi.org/10.2106/jbjs.20.01086>
  31. Livermore J, Ilstrup D, Morrey B (1990) Effect of femoral head size on wear of the polyethylene acetabular component. *J Bone Jt Surg Am* 72(4):518
  32. Tarasevicius S, Robertsson O, Kesteris U, Kalesinskas RJ, Wingstrand H (2008) Effect of femoral head size on polyethylene wear and synovitis after total hip arthroplasty: a sonographic and radiographic study of 39 patients. *Acta Orthop* 79(4):489. <https://doi.org/10.1080/17453670710015472>
  33. Jørgensen PB, Kaptein BL, Søballe K, Jakobsen SS, Stilling M (2022) Polyethylene liner motion in dual mobility hip prostheses measured with static and dynamic RSA one year after operation. *Acta Orthop*. <https://doi.org/10.2340/17453674.2022.2253>
  34. Boyer B, Neri T, Di Iorio A, Geringer J, Philippot R, Farizon F (2017) The linear penetration rate is not relevant for evaluating wear of dual mobility cups: an explant study. *Int Orthop* 41(3):599. <https://doi.org/10.1007/s00264-017-3406-5>
  35. Stilling M, Kold S, de Raedt S, Andersen NT, Rahbek O, Soballe K (2012) Superior accuracy of model-based radiostereometric analysis for measurement of polyethylene wear: a phantom study. *Bone Jt Res* 1(8):180. <https://doi.org/10.1302/2046-3758.18.2000041>
  36. Jørgensen PB, Daugaard H, Jakobsen SS, Lamm M, Soballe K, Stilling M (2020) Higher early proximal migration of hemispherical cups with electrochemically applied hydroxyapatite (Bone-Master) on a porous surface compared with porous surface alone: a randomized RSA study with 53 patients. *Acta Orthop* 91(1):26. <https://doi.org/10.1080/17453674.2019.1687860>

**Publisher's Note** Springer Nature remains neutral with regard to jurisdictional claims in published maps and institutional affiliations.

Springer Nature or its licensor (e.g. a society or other partner) holds exclusive rights to this article under a publishing agreement with the author(s) or other rightsholder(s); author self-archiving of the accepted manuscript version of this article is solely governed by the terms of such publishing agreement and applicable law.