

Preoperative planning of total hip replacement using the TraumaCad™ system

Ely Liviu Steinberg · Nadav Shasha ·
Aharon Menahem · Shmuel Dekel

Received: 18 August 2009 / Published online: 13 January 2010
© Springer-Verlag 2010

Abstract

Introduction Templating is now the standard approach for preoperative planning of total joint replacement and fracture fixation. The aim of this study was to assess the accuracy of new software, TraumaCad™, for preoperative planning for total hip replacement.

Methods This software enables the import and export of all picture archiving communication system (PACS) files from local working stations. It can integrate with all PACS systems. We retrospectively reviewed TraumaCad™-generated templates of digitalized preoperative radiographs of 73 consecutive patients.

Results The acetabular component, measured within ± 1 size, was accurate in 65 patients (89%), and the femoral stem design component was accurate in 70 patients (97%). The accuracy of the femoral size was predicted in 57 patients within 1 size (87%) and in 65 patients within 2 sizes (96%) out of 68 patients in the Corail femoral component group. TraumaCad™ successfully predicts the sizes of femoral and acetabular component and easily integrates with all PACS files.

Keywords Preoperative planning · Templates · Total hip replacement · TraumaCad

Introduction

Preoperative planning and templating currently comprise standard stages for total joint replacement and fracture fixation [2, 4, 5, 7, 13]. Surgical planning had traditionally been performed by means of conventional radiography with a consistent radiographic magnification which allows templating for the selected prosthesis with prepared component overlays [3]. Computerized tomographic (CT) scanning is another option for improving preoperative planning accuracy, but at the cost of the patient's exposure to a higher dose of ionized irradiation [9, 12]. Questions have been raised about the accuracy of the standard templating system in terms of magnification mismatches between the radiograph and the templates [5]. A number of factors may affect this mismatch, such as the patient's body size, the tube-to-film distance and the accuracy of the template's magnification. Accurate preoperative planning requires calibration of the digitalized radiography [1, 10] and versatile templating software that can be adapted to accommodate various types and sizes of prostheses. Digitalized radiography has become the standard modality in most orthopedic centers over the past decade, creating the need for digitalized templating for the purposes of surgical planning.

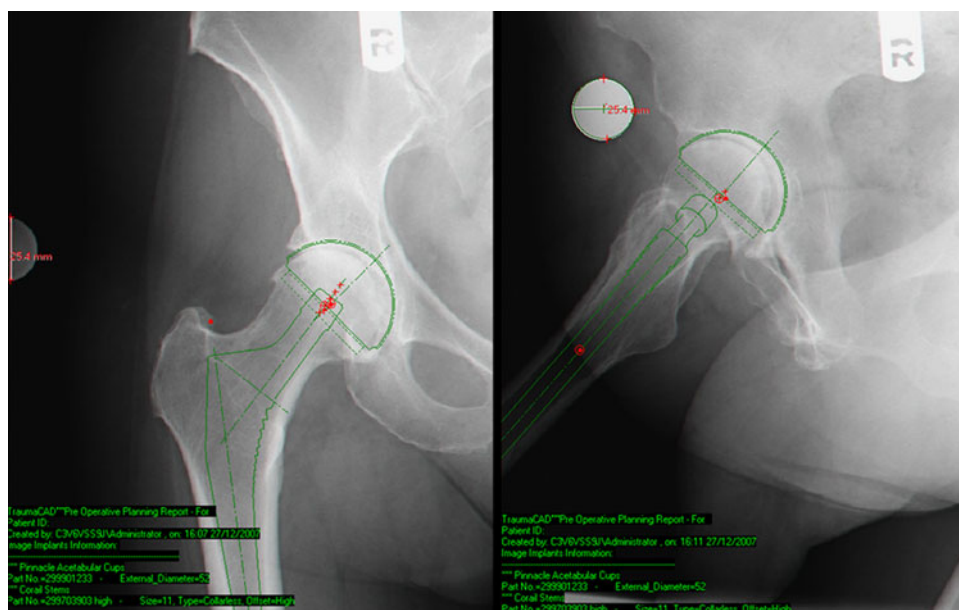
In the present study, we review our 1-year experience of preoperative planning for total joint replacement using a new software system.

Patients and methods

The digital radiographs were retrieved from the medical records of all consecutive patients that underwent total hip replacement between October 2006 and November 2007 in our department, and they provided the data for this

E. L. Steinberg (✉) · N. Shasha · A. Menahem · S. Dekel
Department of Orthopedic Surgery "B",
Tel-Aviv Sourasky Medical Center,
Sackler Faculty of Medicine, Tel-Aviv University,
6 Weizmann St., Tel-Aviv 64239, Israel
e-mail: steinberge@tasmc.health.gov.il; eli_st@netvision.net.il

Fig. 1 Preoperative planning using TraumaCad™ software. Anteroposterior and axial views of the hip joint with a calibration marker placed close to the greater trochanter are shown. The software superimposed the templates on the digitalized radiograph with all image annotations



retrospective study that was approved by the institutional ethics committee. All pre- and postoperative radiographs were obtained with a standard source-to-object of 1 m using a calibration metal ball of 1 in. (2.54 cm) at the level of the greater trochanter. Anteroposterior and axial projections of the hip were used, and all of the radiographs were processed using the TraumaCad™ software system (TraumaCad, Petach-Tikva, Israel). The digital planning was performed on a 17 in. LCD screen with a resolution of at least $1,024 \times 768$ pixels. After adjustment of the magnification, the template of the desired implant was applied and manipulated over the hip joint to the satisfaction of the surgeon in terms of size and orientation (Fig. 1). The operative data were stored and used during the actual surgery.

Results

Patients

This series of 73 patients were comprised of 52 females and 21 males with an average age of 67 (range 19–86) years. Primary total hip replacement for an osteoarthritic hip was performed in 68 patients and revision surgery in 5 patients. The femoral prosthetic stems included 68 Corails, 2 Mayos, 1 Kar, and 1 S-Rom, while 1 patient did not need revision of the stem after having undergone a bipolar hemiarthroplasty. Thirty-seven ASR (De Puy), 32 Pinnacle (De Puy), 3 Zimmer and 1 Biomet acetabular cups were used. There was a 1 mm difference between the sizes for the femur and a 2 mm difference for the acetabulum. The posterior was the preferred surgical approach, and it was used in 55 operations, while the anterolateral approach was used in the other 18 operations.

The acetabular component

The average measurements were 51.5 ± 3.3 (range 44–60) mm for the cup, and 52 ± 2.9 (range 44–60) mm for the implanted cup. The exact acetabular cup was predicted in 50.7% of hips (37 out of 73): a one-size up or down agreement was found in 38.3% (28 ± 2 mm) of the hips and a two-size up or down agreement was found in 11% (8 out of 73) of the hips. There was agreement within ± 1 size in 65 cases (89%).

The femoral component

The accuracy of the femoral component was 97% (70 out of 72) for the stem design (i.e., regular or high offset). One femoral stem did not need to be revised. Forty-eight regular and 24 high offset stems were planned, and 46 regular and 26 high offset stems were implanted. Femoral stems measuring 11 ± 2 (range 8–20) mm were planned and 68 Corail femoral stems measuring 11.6 ± 2.2 (range 8–20) mm were implanted. Agreement for the Corail group alone showed that the exact component was predicted in 32 cases (47%), and that there was agreement within ± 1 size in 27 cases (40%), within ± 2 sizes in 6 cases (9%), within ± 3 sizes in 2 cases and within ± 4 sizes in 1 case. Agreement for the entire study group was within ± 1 size in 87% (57 of 68) of the cases and within ± 2 sizes in 96% (65 of 68) of the cases.

Discussion

Digitalized radiography has become the preferred method for preoperative planning of orthopedic procedures in most

Table 1 Results of the accuracy of measurements using various templating techniques as reported in different studies and in the current analysis

	Acetabulum (%)	Femur (%)
Knight and Atwater (film and transparent templates)	62 (± 1)	78 (± 1)
Della Valle et al. (film and transparent templates)	99 (± 1)	99 (± 2)
Eggli et al. (scanned films and software)	90 (± 1)	92 (± 1)
Davila et al. (digitalized radiographs and software)	86 (± 1)	96 (± 2)
Wedemeyer et al. (digitalized radiographs and software)	92 (± 2)	95 (± 1)
Present series (digitalized radiographs and software)	87 (± 1)	96 (± 2)

The accuracy of the components within sizes is given in parentheses

modern medical centers [11]. This new technology, however, was associated with mismatching between the transparent templates and the printed images of various magnifications received from the computer, prompting the development of software programs to overcome this problem [2]. Errors in magnification could now be minimized with the use of a calibration tool [1, 10]. One great advantage of the new digitalized programs is the possibility of storing patients' data as well as those of various components, such as types and sizes, and this information can be used as necessary for planning surgery. Training for applying the programs is short, and the system is user-friendly and requires only a PC workstation.

The TraumaCad™ software system was developed for the orthopedic community to be used in a filmless working environment. This software enables the import and export of all picture archiving communication system (PACS) files (i.e., X-rays, CTs, magnetic resonance images) from the local working station or from any remote PACS system. The image is retrieved by a spherical marker placed at the level of the bone so that it can be automatically detected in the image by the software for scale calibration. The next step is template positioning in a way that mimics the intended procedure. These data are stored in each patient's file.

Our experience showed that the TraumaCad™ program predicted the designed femoral stem with an accuracy of 97%. The predicted femoral stem was 87% within one size and 96% within two sizes. The predicted acetabular component was 50.7% within one size and 89% within two sizes.

In the past, the common practice was to use transparent templates applied on a standard non-digital film. Knight and Atwater [5] accurately predicted 62% of the acetabular cups, 78% of the cement stems and 42% of the cementless stems. They found that magnification differences affected the choice of the implant in 17% of cases. Della Valle et al. [3] found very good prediction (99%) within one size for the acetabular component and 99% within two sizes for the femoral component. Studies that used scanned radiographic films and template software showed a 92% agreement on the femoral side and 90% on the acetabular side. Davila et al. [2] used the EndoMap software in 36 patients

undergoing primary total hip replacement: 86% were accurate within one size on the acetabular component and 96% were accurate within two sizes on the femoral component. A similar study was conducted by Wedemeyer et al. [13] who used MediCad software in 40 patients with the following results: 92% accuracy within two sizes for the acetabular component and 95% accuracy within one size for the femoral component. Another study concluded that digitalized preoperative templating is as reliable as conventional templating techniques [6].

Some authors recommended the use of three-dimensional CT as being superior to the two-dimensional templates that can provide an in-depth view of the fit of the components [8, 9, 12]. This method, however, exposes the patient to a high level of irradiation. Moreover, it is probably not necessary for a simple osteoarthritic hip, and can be used mostly for planning dysplastic hip procedures. Prediction by the TraumaCad™ software system was very satisfactory and produced results that were similar to those of the above-mentioned studies, whether transparent templates on plain film or template software on scanned films or software on digitalized images had been used (Table 1). Whatever program is chosen, the surgeon should mainly rely on the intraoperative measurements for determining the correct prosthetic size.

The transition from hard-copy radiographic films to a digital technique has brought with it increasing numbers of software programs, some using similar applications as the TraumaCad™ and others using three-dimensional CT-based software. The short learning curve, user-friendly features, and low-cost maintenance make TraumaCad™ software an attractive option among them. The program can integrate with all PACS files, and it predicts the size of the required implant for a full hip replacement procedure with a high level of accuracy.

Acknowledgments Esther Eshkol is thanked for editorial assistance.

References

1. Conn KS, Clarke MT, Hallet JP (2002) A simple guide to determine the magnification of radiographs and to improve the

- accuracy of preoperative templating. *J Bone Joint Surg [Br]* 84:269–272
2. Davila JA, Kransdorf MJ, Duffy GP (2006) Surgical planning of total hip arthroplasty: accuracy of computer-assisted EndoMap software in predicting component size. *Skeletal Radiol* 35:390–393
 3. Della Valle AG, Slullitel G, Piccaluga F, Salvati EA (2005) The precision and usefulness of preoperative planning for cemented and hybrid primary total hip arthroplasty. *J Arthroplasty* 20:51–58
 4. Egli S, Pisan M, Müller ME (1998) The value of preoperative planning for total hip arthroplasty. *J Bone Joint Surg [Br]* 80:382–390
 5. Knight JL, Atwater RD (1992) Preoperative planning for total hip arthroplasty. Quantitating its utility and precision. *J Arthroplasty* 7(Suppl):403–409
 6. Kosashvili Y, Shasha N, Olschewski E, Safir O, White L, Gross A, Beckstein D (2009) Digital versus conventional templating techniques in preoperative planning for total hip arthroplasty. *Can J Surg* 52:6–11
 7. Krettek C, Blauth M, Mielau T, Rudolf J, Könemann B, Schandelmair P (1996) Accuracy of intramedullary templates in femoral and tibial radiographs. *J Bone Joint Surg [Br]* 78:963–964
 8. Lattanzi R, Viceconti M, Zannoni C, Quadroni P, Toni A (2002) Hip-Op: an innovative software to plan total hip replacement surgery. *Med Inform* 27:71–83
 9. Noble PC, Sugano N, Johnston JD, Thompson MT, Condit MA, Engh CA, Mathis KB (2003) Computer simulation: how can it help the surgeon optimize implant position? *Clin Orthop Relat Res* 417:242–252
 10. Oddy MJ, Jones MJ, Pendegrass CJ, Pilling JR, Wimhurst JA (2006) Assessment of reproducibility and accuracy in templating hybrid total hip arthroplasty using digital radiograph. *J Bone Joint Surg [Br]* 88:581–585
 11. Reiner BI, Siegel EL, Flagle C, Hooper FJ, Scanlon (2005) Effect of filmless imaging on the utilization of radiographic services. *Radiology* 215:163–167
 12. Viceconti M, Lattanzi R, Antonietti B, Paderni S, Olmi R, Sudanese A, Toni A (2003) CT-based surgical planning software improves the accuracy of total hip replacement preoperative planning. *Med Eng Phys* 25:371–377
 13. Wedemeyer C, Quitmann H, Xu J, Hepp H, Von Knoch M, Saxler G (2008) Digital templating in total hip arthroplasty with the Mayo stem. *Arch Orthop Trauma Surg* 128:1023–1029