

IDH1 mutation can be present in diffuse astrocytomas and giant cell glioblastomas of young children under 10 years of age

Sean P. Ferris¹ · Benjamin Goode¹ · Nancy M. Joseph² · Cassie N. Kline³ ·
David Samuel⁴ · Nalin Gupta⁵ · Andrew Bollen¹ · Arie Perry^{1,5} · Sabine Mueller^{3,5,6} ·
David A. Solomon^{1,2}

Received: 13 April 2016 / Revised: 4 May 2016 / Accepted: 4 May 2016 / Published online: 9 May 2016
© Springer-Verlag Berlin Heidelberg 2016

A recurrent arginine-to-histidine missense mutation in either *IDH1* or *IDH2* genes (at codons R132 and R172, respectively) is present in >80 % of lower grade (WHO II–III) diffuse gliomas and secondary glioblastomas arising within the cerebral hemispheres in adult patients [1]. In contrast, *IDH1/2* mutations are not found in most pediatric counterparts, where a different set of genetic alterations have been identified, including *MYB* or *MYBL1* rearrangement, *FGFR1* alterations, *BRAF-V600E* mutation, and mutations in the histone H3 variants *H3F3A* or *HIST1H3B* [4, 5]. The earliest age at which *IDH1/2* mutation contributes to gliomagenesis is unknown, but was previously thought to be during mid-to-late teenage years, as diffuse gliomas in older teenagers sometimes harbor *IDH1/2*

mutation, whereas diffuse gliomas in children and younger teenagers are virtually always *IDH1/2* wild-type [2, 3]. Here, we report three children less than 10 years of age with diffuse gliomas harboring *IDH1* mutation, suggesting that such mutations can also be oncogenic drivers in this age group, and therefore, that IDH testing is warranted in diffuse gliomas from all patients regardless of age.

The first patient is a previously healthy, 9-year-old boy who first presented with headaches, emesis, gait instability, and incontinence. Examination revealed facial nerve palsy, left arm weakness, and blindness of the right eye. Head imaging demonstrated a large enhancing mass within the right frontal lobe with extensive surrounding FLAIR hyperintensity extending into the right basal ganglia, midbrain, and across the corpus callosum (Fig. 1, Supplemental Fig. 1). He initially underwent decompressive craniotomy and subtotal resection followed by an additional resection of the residual enhancing portion of the tumor 2 weeks later. Pathology demonstrated giant cell glioblastoma (WHO grade IV), characterized by numerous multinucleated and bizarre tumor cells, extensive infiltrative growth, high mitotic index, palisading necrosis, and microvascular proliferation. The tumor cells were immunopositive for IDH1-R132H mutant protein, had strong nuclear p53 immunoreactivity, and showed loss of ATRX expression. Fluorescence in situ hybridization (FISH) revealed disomy 10 and polysomy 7 without *EGFR* amplification. Sequencing of *H3F3A* codon 34 and *BRAF* exon 15 was wild-type. Post-operatively, the patient underwent radiation with concurrent vorinostat therapy, followed by adjuvant lomustine and bevacizumab. Follow-up imaging at 10 months post-resection demonstrated tumor progression, and therapy was switched to everolimus. He died of progressive disease 13 months after initial diagnosis.

Electronic supplementary material The online version of this article (doi:10.1007/s00401-016-1579-4) contains supplementary material, which is available to authorized users.

✉ David A. Solomon
david.solomon@ucsf.edu

- ¹ Division of Neuropathology, Department of Pathology, University of California, 513 Parnassus Ave, Health Sciences West 451, Box 0102, San Francisco, CA 94143, USA
- ² Clinical Cancer Genomics Laboratory, University of California, San Francisco, CA 94143, USA
- ³ Division of Pediatric Hematology/Oncology, Department of Pediatrics, University of California, San Francisco, CA 94143, USA
- ⁴ Division of Hematology/Oncology, Valley Children's Hospital, Madera, CA 93636, USA
- ⁵ Department of Neurological Surgery, University of California, San Francisco, CA 94143, USA
- ⁶ Department of Neurology, University of California, San Francisco, CA 94143, USA

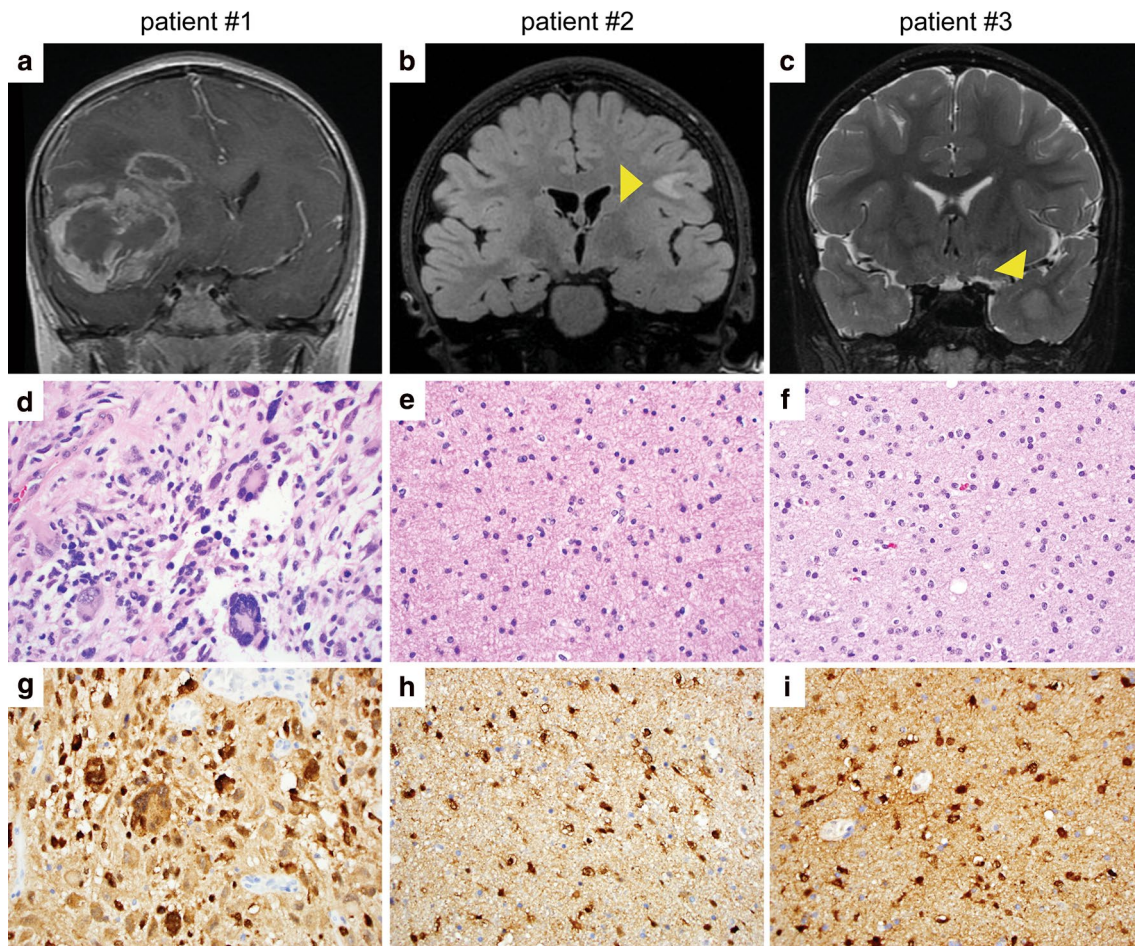


Fig. 1 Diffuse gliomas with *IDH1* mutation in young children. **a–c** Coronal MR imaging from the three patients: T1-weighted post-gadolinium injection in patient #1 at 9 years of age (**a**), T2-weighted fluid attenuated inversion recovery in patient #2 at 9 years of age (**b**), and T2-weighted in patient #3 at 10 years of age (**c**). **d–f** H&E stained

sections demonstrating giant cell glioblastoma in patient #1 and low-grade diffuse astrocytoma in patients #2 and #3. **g–i** Immunopositivity of the neoplastic astrocytes for *IDH1*-R132H mutant protein in the three tumors

The second patient is a 9-year-old girl with a history of autism spectrum disorder. Behavioral changes possibly due to headaches triggered neuroimaging. On head MRI, the patient was noted to have an area of mass-like FLAIR hyperintensity within the subcortical white matter of the left posterior frontal lobe (Fig. 1, Supplemental Fig. 2). Review of imaging performed at 5 years of age revealed that this lesion had already been present and had expanded over the four-year interval between MR imaging. Near total resection of the lesion was achieved with pathology demonstrating diffuse astrocytoma (WHO grade II), characterized by infiltrative glioma cells with irregular ovoid nuclei, coarse chromatin, and minimal cytoplasm without significant mitotic activity. The tumor cells were immunopositive for *IDH1*-R132H mutant protein and lacked p53 immunoreactivity. The patient did not receive adjuvant therapy and was monitored by serial MR imaging. Imaging at 2 years

post-resection demonstrated increasing FLAIR hyperintensity adjacent to the prior resection cavity. She was subsequently enrolled on a phase 2 clinical trial (PNOC001) and received 12 cycles of everolimus. She exhibited disease progression while on everolimus and underwent repeat resection 4 years after her initial surgery. Pathology was consistent with a low-grade diffuse glioma with rounded nuclear morphology, initially suggestive of oligodendroglioma. The tumor cells were immunopositive for *IDH1*-R132H mutant protein, had intact *ATRX* expression, lacked p53 immunoreactivity, and had intact chromosomes 1p and 19q by FISH. Targeted next-generation sequencing revealed *IDH1*-R132H mutation and a *TP53* frameshift mutation, molecularly consistent with a diffuse astrocytoma. Alterations in other known glioma genes, including *ATRX*, *TERT* promoter, *CIC*, *H3F3A*, *HIST1H3B*, *SETD2*, *MYB*, *MYBL1*, and *BRAF* were not identified. She is currently receiving

adjuvant radiation therapy and showed no new areas of disease on most recent imaging at 3 months after the second resection.

The third patient is an otherwise healthy boy who underwent a brain MRI at 8 years of age for headaches that had been ongoing since early childhood. A small focus of T2/FLAIR hyperintensity was noted within the anterior left temporal lobe (Fig. 1, Supplemental Fig. 3). Serial imaging over the next 4 years demonstrated expansion into a space-occupying lesion. Subtotal resection was performed at 12 years of age with pathology demonstrating diffuse astrocytoma (WHO grade II), characterized by infiltrative glioma cells with irregular ovoid nuclei with coarse chromatin and minimal cytoplasm without significant mitotic activity. The patient underwent repeat surgery 1 month later, and a gross total resection was achieved. The tumor cells were immunopositive for IDH1-R132H mutant protein, had intact ATRX expression, had strong nuclear p53 immunoreactivity within a subset of cells, and had intact chromosomes 1p and 19q by FISH. Targeted next-generation sequencing revealed *IDH1-R132H* and *TP53-R273C* missense mutations. Alterations in other known glioma genes, including *ATRX*, *TERT* promoter, *H3F3A*, *HIST1H3B*, *SETD2*, *MYB*, *MYBL1*, and *BRAF* were not identified. This patient continues to be followed with close surveillance imaging at 2 months post-resection.

Together, these three patients demonstrate that *IDH1* mutation is a pathogenic driver within a subset of gliomas arising in the cerebral hemispheres of young pediatric patients under 10 years of age. The pathology of these tumors ranged from low-grade diffuse astrocytoma to giant cell glioblastoma. Interestingly, the low-grade tumors in the

second and third patients had intact ATRX expression and lacked mutations in *ATRX* or *TERT* promoter, suggesting that some of these *IDH*-mutant diffuse gliomas in children may be molecularly distinct from diffuse gliomas in adults. The significance of *IDH1* mutation on the clinical behavior of gliomas in young children remains an open question, but these cases demonstrate that *IDH1* mutant gliomas may be seen in children as young as 5 years of age.

Acknowledgments C. N. K. is supported by NIH T32 Grant (CA128583) and UCSF-CTSI Strategic Opportunities Support Program (A119683). S. M. is supported by the NIH National Center for Advancing Translational Sciences through UCSF-CTSI (KL2TR000143). D. A. S. is supported by NIH Director's Early Independence Award (DP5 OD021403) and Career Development Award from the UCSF Brain Tumor SPORE (P50 CA097257).

References

1. Cancer Genome Atlas Research Network (2015) Comprehensive, integrative genomic analysis of diffuse lower-grade gliomas. *N Engl J Med* 372:2481–2498
2. Korshunov A, Ryzhova M, Hovestadt V et al (2015) Integrated analysis of pediatric glioblastoma reveals a subset of biologically favorable tumors with associated molecular prognostic markers. *Acta Neuropathol* 129:669–678
3. Pollack IF, Hamilton RL, Sobol RW et al (2011) IDH1 mutations are common in malignant gliomas arising in adolescents: a report from the Children's Oncology Group. *Childs Nerv Syst* 27:87–94
4. Wu G, Diaz AK, Paugh BS et al (2014) The genomic landscape of diffuse intrinsic pontine glioma and pediatric non-brainstem high-grade glioma. *Nat Genet* 46:444–450
5. Zhang J, Wu G, Miller CP et al (2013) Whole-genome sequencing identifies genetic alterations in pediatric low-grade gliomas. *Nat Genet* 45:602–612