Acta Neuropathol (2005) 109: 387–392
DOI 10.1007/s00401-004-0976-2

REGULAR PAPER

Portia A. Kreiger · Yoshifumi Okada · Scott Simon
Lucy B. Rorke · David N. Louis · Jeffrey A. Golden

Losses of chromosomes 1p and 19q are rare in pediatric oligodendrogliomas

Received: 23 July 2004 / Revised: 11 December 2004 / Accepted: 13 December 2004 / Published online: 1 March 2005
© Springer-Verlag 2005

Abstract Pediatric oligodendrogliomas are rare neoplasms and have not been characterized extensively either pathologically or genetically. Given the recent interest in the significance of chromosomal losses in predicting the clinical course and in establishing uniform diagnoses of adult oligodendrogliomas, we reviewed the pathological and clinical features of a series of pediatric oligodendrogliomas and determined their 1p and 19q status using fluorescence in situ hybridization. Of 19 tumors originally diagnosed as oligodendroglioma, 7 were oligodendroglioma, 3 were anaplastic oligodendroglioma, 3 were oligoastrocytoma, and 6 were reclassified. Only one tumor, an anaplastic oligodendroglioma, had 1p loss; none had 19q loss. The single patient whose tumor had 1p loss did not have a particularly favorable clinical course. These results suggest that pediatric oligodendrogliomas arise by molecular alterations distinct from adult oligodendrogliomas, and such molecular alterations do not hold immediate promise as an adjunct to the diagnosis of pediatric oligodendrogliomas.

Keywords Chromosome 1p · Chromosome 19q · Fluorescence in situ hybridization · Oligodendroglioma · Pediatric

P. A. Kreiger · L. B. Rorke · J. A. Golden (✉)
Department of Pathology, Abramson Research Center,
The Children's Hospital of Philadelphia,
University of Pennsylvania School of Medicine,
Rm. 516, 3400 Civic Center Blvd.,
Philadelphia, PA 19104, USA
E-mail: goldenj@mail.med.upenn.edu
Tel.: +1-215-5904307
Fax: +1-215-5903709

Y. Okada · D. N. Louis
Department of Pathology,
Cancer Center and Neurosurgical Service,
Massachusetts General Hospital,
Harvard Medical School, Boston, Massachusetts, USA

S. Simon
Department of Neurosurgery,
The Children's Hospital of Philadelphia,
University of Pennsylvania School of Medicine, Philadelphia,
Pennsylvania, USA

Introduction

Central nervous system tumors are the second most common form of childhood cancer. The most common histological types are primitive neuroectodermal tumors (PNETs) (including medulloblastomas), astrocytomas, gangliogliomas, and ependymomas. Pediatric oligodendrogliomas are rare tumors and only comprise about 1–3% of pediatric central nervous system neoplasms [5, 13]. Recent advances in the molecular diagnosis and treatment of adult oligodendrogliomas prompted us to examine whether similar molecular anomalies exist in pediatric oligodendrogliomas and whether these changes might also correlate with prognosis.

Molecular genetic analysis has an emerging role in the diagnosis, treatment, and prognostic assessment of adult patients with oligodendrogliomas [3, 6, 15]. A subset of adult oligodendrogliomas exhibit isolated deletions of chromosomes 1p and/or 19q [3]. Anaplastic oligodendrogliomas with deletions of 1p or 1p/19q have been associated with increased overall patient survival and chemosensitivity, especially to PCV [procarbazine, chloroethylcyclohexylnitrosurea (CCNU), vincristine] chemotherapy [3, 6, 15]. In addition, oligodendrogliomas with deletions of 1p have longer recurrence-free survivals after radiation therapy, independent of PCV chemotherapy [1]. Oligodendrogliomas with 1p and 19q loss also conform generally to the histologically classic forms of oligodendroglioma, allowing the molecular signature to act as a guide for standardizing histopathological definitions of oligodendroglioma [2, 14]. Thus, loss of chromosomes 1p or 1p/19q has been associated with a favorable therapeutic response and prognostic outcome in adult patients and can be used to guide pathological diagnoses.

Few studies have focused on the histopathology and behavior of pediatric oligodendrogliomas [9], largely because the relatively low incidence of oligodendrogliomas in children renders their study difficult. Only one study has specifically investigated childhood

oligodendrogliomas. They found losses of 1p and 19q to be rare in childhood tumors, particularly in the first decade [12]. A second study, focused on astrocytomas in children, mentions a loss of 1p in one of eight children with an oligodendroglioma, who had a rapid progression of disease; however, no other details were provided [11]. Thus, relatively few data exist on the genetic alterations and behavior of pediatric oligodendrogliomas. The aim of this study was to characterize a series of childhood oligodendrogliomas histologically and to evaluate these tumors for the signature molecular genetic abnormalities of chromosomes 1p and 19q loss. We hypothesized that childhood oligodendrogliomas would demonstrate similar histological and molecular features to those observed in adult oligodendrogliomas. However, our data, similar to those reported by Raghavan et al. [12], suggest pediatric oligodendrogliomas have a distinct molecular pathogenesis.

Materials and methods

Tumor samples

Nineteen pediatric patients, including 11 males and 8 females, with the diagnosis of oligodendroglioma were identified in the files of the Children's Hospital of Philadelphia between the years 1979–2001. A pediatric age group was defined as less than 21 years. These patients had undergone surgical resection, autopsy, or surgical pathology consultation at the Children's Hospital of Philadelphia. Twenty tumor specimens were obtained from these 19 patients; one patient had both surgical and autopsy material available for review (case 13). Diagnostic, therapeutic and clinical status was retrospectively obtained by chart review where available.

Light microscopy and immunohistochemistry

The histological features of each case were reviewed on hematoxylin and eosin-stained sections. In addition, immunohistochemistry was performed with antibodies directed against neurofilament protein (NFP; RMDO20, kindly provided by Dr. V. Lee), and glial fibrillary acid protein (GFAP; Sigma), as well as Ki-67, vimentin, epithelial membrane antigen (EMA), leukocyte common antigen (LCA), CD20, smooth muscle actin, and synaptophysin (all DAKO) using standard avidin-biotin-complex protocol [7]. Mitotic indices were calculated by counting the number of Ki-67-positive tumor cells per 10 high power fields (hpf, ×400).

Fluorescence in situ hybridization

Molecular genetic studies were performed on formalin-fixed or bouins-fixed paraffin-embedded tumor samples using fluorescence in situ hybridization (FISH). FISH was performed as previously described [8]. Control and detecting probes were made from plasmids D1Z1 (1q12) and D1Z2 (1p36.3) for chromosome 1 study, and from BACs RP11–413M18 (19p13) and CTD-2571L23 (19q13.3) for chromosome 19 study, respectively. D1Z1 was provided by Dr. Tsuda (Pathology Division, National Cancer Center Research Institute, Tokyo, Japan). D1Z2 was purchased from American Type Culture Collection (Rockville, MD) and the BACs were purchased from Research Genetics (Huntsville, AL). Dual-colored probes against chromosomes 1p and 19q were used to detect chromosomal loss at these loci, with a single fluorescent signal in a nucleus interpreted as chromosomal arm loss if two signals were found for the control probe.

Results

We reviewed the pathology and the clinical history from the 19 patients originally diagnosed with oligodendrogliomas. Based upon our review, including additional immunohistochemical staining for tumors diagnosed before 1990, 6 cases were reclassified: 2 as PNETs, 3 as atypical teratoid/rhabdoid tumors, and 1 as an astrocytoma. Of the remaining 13 patients, 7 were classified as oligodendroglioma grade II, 3 as anaplastic oligodendroglioma grade III, and 3 as oligoastrocytoma, including 2 grade II and 1 anaplastic grade III. The patient with the anaplastic oligoastrocytoma grade III died (case 13); an autopsy showed a similar anaplastic tumor.

Of the 13 patients identified with oligodendrogliomas or oligoastrocytomas, 9 were male and 4 were female (Table 1). The average age of these patients at diagnosis was 12.3 years. Six of the tumors were located in the cerebral hemispheres, six in the posterior fossa (including one in the pons and one in the tectum), and one in the lateral and third ventricles. Of the six cerebral tumors, four were right-sided, one was left-sided, and one was bilateral (Table 1).

The presenting symptoms for 11 of the 13 patients was headache. The duration of first symptoms to treatment was 0–1 months for 8 of the 11 patients, several years for 2 patients, and 1 patient with a congenital tumor received no treatment and died at 7 h of age (case 1).

Twelve of the 13 patients underwent a surgical procedure; as previously stated, the patient with a congenital tumor received no treatment. Six of the surgical procedures were subtotal resections, two were gross total resections, and one was a biopsy only. A description of the surgery was unavailable for the remaining 3 cases. Only 2 of these 12 patients were known to have received adjuvant chemotherapy, and 6 of these 12 patients were known to have received radiation treatment. Recurrence or progression of disease was documented in 5 of these 12 patients. Five of the total 13 patients were known to have had tumor-related deaths; other than the one patient who died shortly after birth, the average

Table 1 Diagnosis: oligodendroglioma grade II (*OL-II*), anaplastic oligodendroglioma grade III (*AO-III*), mixed oligoastrocytoma grade II (*MOA-II*), mixed oligoastrocytoma grade III (*MOA-III*)

Case	Diagnosis	Age at diagnosis	Gender	Presenting symptoms	Site	Interval to treatment	Surgical procedure	Adjuvant chemotherapy	Adjuvant radiotherapy	Follow-up duration	Recurrence or progression	Final status
1	OL-II	Newborn (full term)	F	Respiratory failure	Right cerebrum	No treatment	None	None	None	Died at 7 h	Yes	Deceased
2	OL-II	8 years	M	Headache, visual defects	Cerebellum	Less than 1 month	Subtotal resection	None	5,580 cGy total	7 years	No	Alive
3	OL-II	8 years	M	Weakness, ataxia	Pons	Less than 1 month	Subtotal resection	None	7,200 cGy total	2 years 4 months	Yes	Deceased
4	OL-II	11 years	F	Tremor	Lateral and 3rd ventricles	3 days	Subtotal resection	None	None	3 years 10 months	Yes	Deceased
5	OL-II	15 years	F	Seizures	Left fronto-parietal region	1 month	Total resection	None	None	2 years 7 months	No	Alive
6	OL-II	17 years	F	Headache, personality changes	Frontal lobes	Less than 1 month	Subtotal resection	None	Yes, dose unknown	4 months	No	Alive
7	OL-II	17 years	M	Unknown	Right temporal lobe	Unknown	Unknown	Unknown	Unknown	Lost to follow-up	Unknown	Unknown
8	AO-III	10 years	M	Headache, ataxia, vomiting	Posterior fossa	2 weeks	Unknown	Unknown	Unknown	Lost to follow-up	Unknown	Unknown
9	AO-III	15 years	M	Headache, nausea, vomiting, weakness	Right fronto-temporal region	Less than 1 month	Subtotal resection	Vincristine /CCNU	5,940 cGy total	1 year 1 month	Yes	Deceased
10	AO-III	18 years	M	Headache, vomiting	Posterior fossa	9 years	Total resection	Vincristine /CCNU	5,400 rads	4 years	Yes	Unknown
11	MOA-II	17 years	M	Unknown	Right parietal lobe	Unknown	Unknown	Unknown	Unknown	Lost to follow-up	Unknown	Unknown
12	MOA-II	19 years	M	Headache, blurry vision	Tectum	1 week	Subtotal resection	None	None	2.5 months	No	Unknown
13	MOA-III	5 years	M	Tremor, developmental delay, seizures	Posterior fossa	2 years 11 months	Biopsy	None	Yes, dose unknown	1 year 6 months	Yes	Deceased

duration of survival was 2 years 2 months. For the remaining 8 patients, 3 were lost to follow-up and 5 had an average duration of follow-up post-surgery of 2 years 10 months.

Seven of the 13 patients had tumor specimens showing classical histology for oligodendroglioma [14] with virtually the entire tumor demonstrating round monotonous nuclei and cleared cytoplasm (Fig. 1). In addition, most of these tumors also contained areas demonstrating fine "chickenwire" type vasculature and microgemistocytes. These tumors showed no expression of NFP, EMA, or GFAP by immunohistochemistry (data not shown). Synaptophysin was negative in 4 of the cases. One case showed moderate (1–2+) synaptophysin labeling in the parenchyma but not around individual cells, one case showed 3+ synaptophysin positivity within tumor cells but repeat NFP was again negative, and one case could not be done due to lack of material. Based upon the histological appearance and Ki-67 labeling, these seven specimens were graded as WHO grade II. Three cases showed relatively low Ki-67 labeling indices (2–134 Ki-67-labeled cells/10 hpf); 2 cases were not adequate to evaluate. However, 2 additional cases considered to otherwise be grade II tumors had high Ki-67 labeling indices (>500/10 hpf; >10%) (Fig. 2).

Three tumors were malignant neoplasms with the characteristics of anaplastic oligodendroglioma. Case 9 appeared typical for an oligodendroglioma; however, some regions showed nuclear pleomorphism, a high mitotic rate, endothelial proliferation, and foci of necrosis, consistent with anaplastic oligodendroglioma (grade III). Immunostains for GFAP, NFP, and synaptophysin were negative in this case. Cases 8 and 10 on the other hand did not show classic histology, but appeared to demonstrate an oligodendroglioma-like pattern. Immunohistochemical markers for NFP, GFAP, EMA, and LCA were negative in both cases. Synaptophysin was negative in case 8, but could not be performed on case 10 due to lack of material. These tumors showed a high mitotic index and marked pleomorphism (Fig. 3), together warranting a diagnosis of anaplastic oligodendroglioma (grade III) for each case.

The remaining three patients had tumor specimens showing the histopathological features of oligoastrocytomas. Two of these (cases 11 and 12) demonstrated two distinct histological regions, one compatible with oligodendroglioma, the other with astrocytoma. These components were clearly defined by immunohistochemical staining with an antibody to GFAP; the

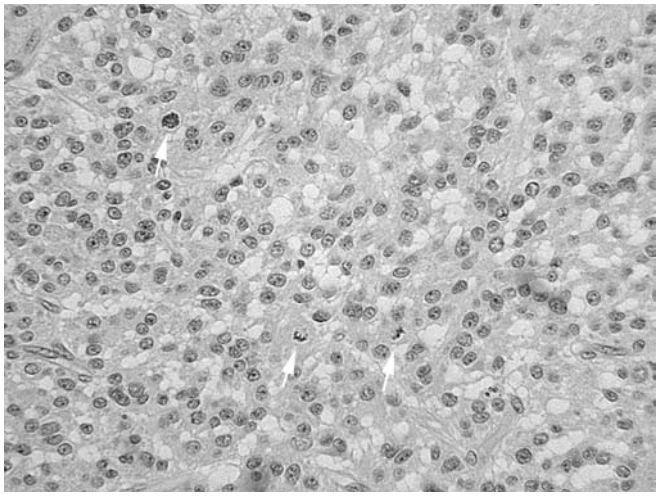

Fig. 2 Case 13 shows the typical histopathology of an oligodendroglioma (other regions showed astrocytoma in this mixed oligoastrocytoma); however, numerous mitotic figures were seen (*arrows*) along with a high Ki67 labeling index (data not shown, see text)

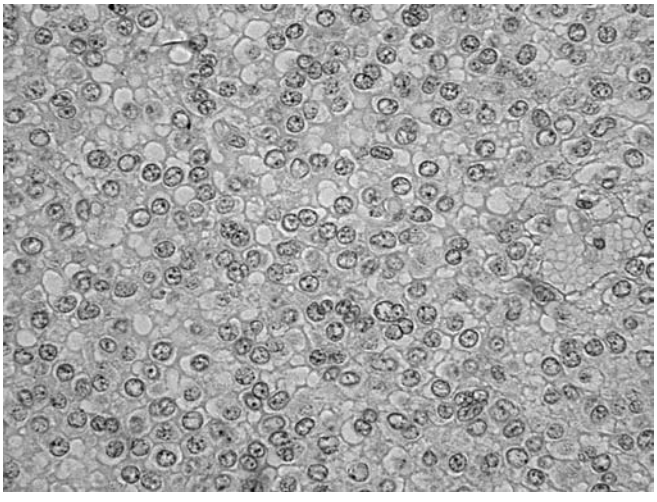

Fig. 1 Representative section from case 7 showing the typical morphology of a grade II tumor with regular nuclei and some perinuclear halos

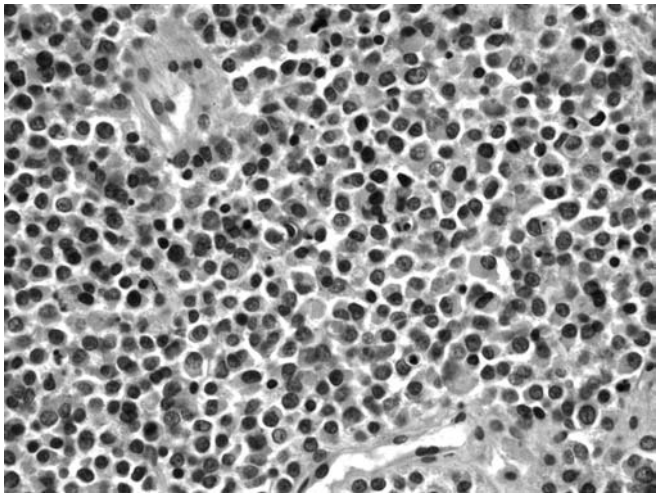

Fig. 3 The histopathology of case 8 (like case 10, data not shown) shows a malignant neoplasm with pleomorphism and anaplasia. As described in the text, these tumors have oligodendroglioma-like morphology and cytology, prompting the diagnosis of anaplastic oligodendroglioma, grade III

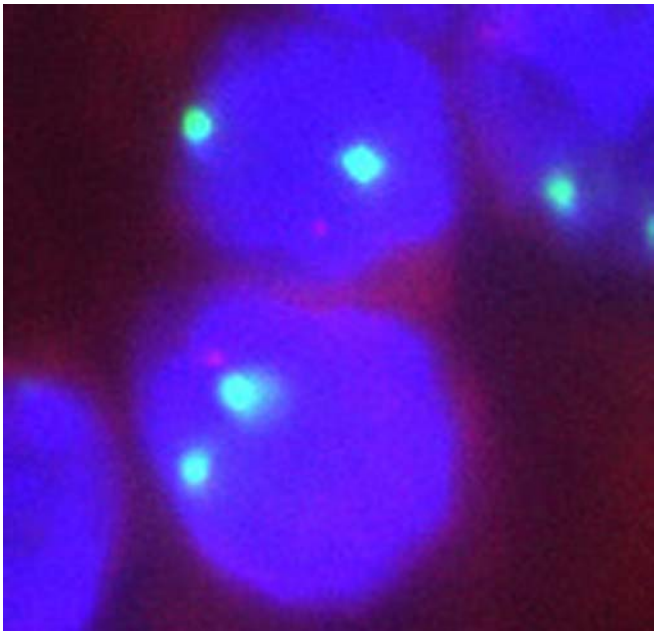

Fig. 4 Fluorescence in situ hybridization results in case 9 show two *green* control signals (1q12) and *one* red signal (1p36), indicating 1p deletion

oligodendroglioma areas were negative, while the astrocytoma regions showed strong labeling. Both tumors were considered grade II. Synaptophysin staining was negative in both cases. Case 13 was an anaplastic tumor with a high degree of pleomorphism and karyorrhexis. There were areas characteristic of oligodendroglioma and areas resembling astrocytoma, suggesting an oligoastrocytoma, although the astrocytoma areas did not label with GFAP in either the biopsy or the autopsy specimens. The autopsy specimen demonstrated a relatively low mitotic index; however, the biopsy and autopsy specimens were deemed high grade based upon cellular anaplasia and the high Ki-67 labeling index (>500 labeled cells/10 hpf; >10%) in the biopsy. Immunohistochemistry for synaptophysin was negative in both the biopsy and autopsy material.

Genetic analysis for losses of 1p and 19q was performed on all 20 tumor specimens (representing 19 patients) using FISH. Only 1 specimen (case 9, an anaplastic oligodendroglioma) demonstrated a deletion of 1p within tumor cells; 19q remained intact in this case (Fig. 4). The 13 specimens from the remaining 12 oligodendroglioma/oligoastrocytoma patients each demonstrated two copies of 1p and 19q. The 6 excluded cases (2 PNETs, 3 AT/RTs, and 1 astrocytoma) showed no losses of 1p or 19q.

Discussion

Diagnosis of oligodendrogliomas remains problematic in part because of the lack of a specific marker. Recent studies indicate that a subset of anaplastic oligodendrogliomas in adults have losses of 1p and/or 19q and that such genetic changes predict a better response to therapy and longer survival [1, 3, 6, 15]. In addition, a clear relationship exists between the classic histological appearance and the presence of 1p and 19q loss [2, 14]. However, similar to the only other study of oligodendrogliomas in childhood [12], our results demonstrate that similar genetic alterations are significantly less common in pediatric oligodendrogliomas when compared with adults. These data have several important implications.

Although oligodendrogliomas are relatively rare pediatric neoplasms, they can be confused with other neoplasms commonly seen in children. In particular pilocytic astrocytomas and dysembryoplastic neuroepithelial tumors may contain oligodendroglioma-like components. Lack of specific immunohistochemical markers has necessitated diagnoses of oligodendrogliomas on routine hematoxylin and eosin-stained sections. For this reason, a molecular genetic marker for pediatric oligodendrogliomas could be diagnostically useful. Our data, in combination with those from Raghavan et al. [12], indicate that 1p and 19q status unfortunately cannot be used as a marker for oligodendrogliomas in the pediatric population.

Despite the lack of molecular genetic similarities between adult and pediatric oligodendrogliomas, the histopathological and immunohistochemical features of the tumors are similar. Both the low- and high-grade neoplasms, with the exceptions of cases 8 and 10 as previously stated, showed the classic light microscopic features characteristic of oligodendrogliomas. This included round to oval nuclei, prominent fine-branching vasculature, and microgemistocytes in most cases. Two of the three mixed tumors showed GFAP immunoreactivity in the astrocytic component but not in the oligodendroglioma regions; one was entirely negative for GFAP. Given the lack of available molecular markers, light microscopy remains as the only diagnostic criteria for oligodendroglioma in children.

Furthermore, because there have been close correlations noted in adult oligodendrogliomas between histological appearance and genotype that encourage a stricter definition of oligodendroglioma (see above), we would encourage similarly strict histological definitions for the diagnosis of pediatric oligodendroglioma. Indeed, our review of cases diagnosed at a single institution over three decades suggests that recognition of new entities such as dysembryoplastic neuroepithelial tumor and atypical teratoid/rhabdoid tumor has already served to narrow the definition of oligodendroglioma in the pediatric population.

In adult patients with anaplastic oligodendrogliomas, the therapeutic and prognostic influence of 1p and 19q loss presumably reflects alterations in specific regulatory pathways that may include the putative tumor suppressor genes that map to 1p and 19q. Rarity of these molecular changes in pediatric oligodendrogliomas

suggests one of several possibilities. Childhood oligodendrogliomas may arise via distinct molecular pathways, involving different genomic events and different growth regulatory pathways. Alternatively, pediatric oligodendrogliomas may inactivate the same regulatory pathways but in different ways, i.e., by different genomic or transcriptional defects. For instance, mouse models of oligodendrogliomas, which appear histologically identical to their human counterparts, do not lose the syntenic regions of 1p or 19q but may dysregulate similar signal transduction pathways [4]. The lack of 1p and 19q loss in these tumors also raises the question of whether pediatric oligodendrogliomas will demonstrate similar dramatic responses to therapy as are seen in adult anaplastic oligodendrogliomas. Large studies that directly test the responsiveness of these tumors in children are obviously required, although they will require multicenter trials given the low incidence of the tumor. If similar therapeutic responses are noted, such tumors should be studied with expression profiling, to determine if therapeutically responsive oligodendrogliomas in children have similar gene expression profiles to responsive adult tumors.

FISH analyses for 1p and 19q showed one tumor with 1p loss, but this tumor had both copies of 19q. This patient was a teenager. Similar to that seen in the cases reported by Raghavan et al. [12], none of the patients from the first decade showed a defect. Although the small number of cases prevents a determination of whether losses begin to occur more commonly in older children, such an age correlation has been noted for TP53 mutations in children with only rare mutations in children under the age of 4, but similar percentages to those in adults being found in older children [10]. Raghavan et al. [12] detected losses of chromosomes 1p and/or 19q in 5 of 26 childhood oligodendroglial neoplasms; however, we found only 1 in 13 cases to harbor a loss of 1p and none of 19q, suggesting such alterations may be even less common than previously suggested. It is also impossible to draw any conclusions regarding 1p status and clinical outcome or response to therapy. The one patient whose tumor had 1p loss was treated with subtotal resection, vincristine, CCNU, and radiation therapy. The tumor recurred 1 year following initial therapy and the patient died about 4 months post-recurrence.

In conclusion, despite having histological features similar to those of adult oligodendrogliomas, pediatric oligodendrogliomas rarely demonstrate losses of 1p and 19q, suggesting that pediatric oligodendrogliomas have a distinct molecular pathogenesis. The findings argue that 1p and 19q loss cannot be used as a molecular diagnostic marker for oligodendrogliomas in children, and raise the challenge of identifying other genetic alterations that might characterize these tumors.

Acknowledgments Supported in part by NIH CA57683. We would like to thank Ravi Raghavan for kindly sharing their unpublished data prior to submitting their manuscript.

References

1. Bauman GS, Ino Y, Ueki K, Zlatescu MC, Fisher BJ, Macdonald DR, Stitt L, Louis DN, Cairncross JG (2000) Allelic loss of chromosome 1p and radiotherapy plus chemotherapy in patients with oligodendrogliomas. Int J Radiat Oncol Biol Phys 48:825–830
2. Burger PC, Minn AY, Smith JS, Borell TJ, Jedlicka AE, Huntley BK, Goldthwaite PT, Jenkins RB, Feuerstein BG (2001) Losses of chromosomal arms 1p and 19q in the diagnosis of oligodendroglioma. A study of paraffin-embedded sections. Mod Pathol 14:842–853
3. Cairncross JG, Ueki K, Zlatescu MC, Lisle DK, Finkelstein DM, Hammond RR, Silver JS, Stark PC, Macdonald DR, Ino Y, Ramsay DA, Louis DN (1998) Specific genetic predictors of chemotherapeutic response and survival in patients with anaplastic oligodendrogliomas. J Natl Cancer Inst 90:1473–1479
4. Da C, Celestino JC, Okada Y, Louis DN, Fuller GN, Holland EC (2001) PDGF autocrine stimulation dedifferentiates cultured astrocytes and induces oligodendrogliomas and oligoastrocytomas from neural progenitors and astrocytes in vivo. Genes Dev 15:1913–1925
5. Dohrmann GJ, Farwell JR, Flannery JT (1978) Oligodendrogliomas in children. Surg Neurol 10:21–25
6. Ino Y, Betensky RA, Zlatescu MC, Sasaki H, Macdonald DR, Stemmer-Rachamimov AO, Ramsay DA, Cairncross JG, Louis DN (2001) Molecular subtypes of anaplastic oligodendroglioma: implications for patient management at diagnosis. Clin Cancer Res 7:839–845
7. Kendler A, Golden JA (1996) Progenitor cell proliferation outside the ventricular and subventricular zones during human brain development. J Neuropathol Exp Neurol 55:1253–1258
8. Okada Y, Nishikawa R, Matsutani M, Louis DN (2002) Hypomethylated X chromosome gain and rare isochromosome 12p in diverse intracranial germ cell tumors. J Neuropathol Exp Neurol 61:531–538
9. Packer RJ, Sutton LN, Rorke LB, Zimmerman RA, Littman P, Bruce DA, Schut L (1985) Oligodendroglioma of the posterior fossa in childhood. Cancer 56:195–199
10. Pollack IF, Hamilton RL, Finkelstein SD, Campbell JW, Martinez AJ, Sherwin RN, Bozik ME, Gollin SM (1997) The relationship between TP53 mutations and overexpression of p53 and prognosis in malignant gliomas of childhood. Cancer Res 57:304–309
11. Pollack IF, Finkelstein SD, Burnham J, Hamilton RL, Yates AJ, Holmes EJ, Boyett JM, Finlay JL (2003) Association between chromosome 1p and 19q loss and outcome in pediatric malignant gliomas: results from the CCG-945 cohort. Pediatr Neurosurg 39:114–121
12. Raghavan R, Balani J, Perry A, Margraf L, Vono MB, Cai DX, Wyatt RE, Rushing EJ, Bowers DC, Hynan LS, White CL 3rd (2003) Pediatric oligodendrogliomas: a study of molecular alterations on 1p and 19q using fluorescence in situ hybridization. J Neuropathol Exp Neurol 62:530–537
13. Razack N, Baumgartner J, Bruner J (1998) Pediatric oligodendrogliomas. Pediatr Neurosurg 28:121–129
14. Sasaki H, Zlatescu MC, Betensky RA, Johnk LB, Cutone AN, Cairncross JG, Louis DN (2002) Histopathological-molecular genetic correlations in referral pathologist-diagnosed low-grade "oligodendroglioma". J Neuropathol Exp Neurol 61:58–63
15. Smith JS, Perry A, Borell TJ, Lee HK, O'Fallon J, Hosek SM, Kimmel D, Yates A, Burger PC, Scheithauer BW, Jenkins RB (2000) Alterations of chromosome arms 1p and 19q as predictors of survival in oligodendrogliomas, astrocytomas, and mixed oligoastrocytomas. J Clin Oncol 18:636–645