



MRI texture analysis of T2-weighted images is preferred over magnetization transfer imaging for readily longitudinal quantification of gut fibrosis

Isabelle De Kock¹ · Simon Bos^{2,3} · Louke Delrue¹ · Sophie Van Welden^{2,3} · Peter Bunyard⁴ · Pieter Hindryckx⁵ · Martine De Vos⁵ · Geert Villeirs¹ · Debby Laukens^{2,3}

Received: 12 December 2022 / Revised: 10 February 2023 / Accepted: 17 February 2023 / Published online: 18 April 2023
© The Author(s), under exclusive licence to European Society of Radiology 2023

Abstract

Objectives To investigate the value of magnetization transfer (MT) MRI and texture analysis (TA) of T2-weighted MR images (T2WI) in the assessment of intestinal fibrosis in a mouse model.

Methods Chronic colitis was induced in mice by cyclic administration of dextran sodium sulphate (DSS) resulting in chronic inflammation and progressive bowel fibrosis. Mice underwent 7-T MR imaging at various time points. Bowel wall MT ratio (MTR) and textural features (skewness, kurtosis, entropy), extracted by a filtration histogram technique, were correlated with histopathology. Performance of both techniques were validated using antifibrotic therapy. Finally, a retrospective study was conducted in five patients with Crohn's disease (CD) who underwent bowel surgery.

Results MTR and texture entropy correlated with histopathological fibrosis ($r = .85$ and $.81$, respectively). Entropy was superior to MTR for monitoring bowel fibrosis in the presence of coexisting inflammation (linear regression $R^2 = .93$ versus $R^2 = .01$). Furthermore, texture entropy was able to assess antifibrotic therapy response (placebo mice versus treated mice at endpoint scan; $\Delta mean = 0.128$, $p < .0001$). An increase in entropy was indicative of fibrosis accumulation in human CD strictures (inflammation: 1.29; mixed strictures: 1.4 and 1.48; fibrosis: 1.73 and 1.9).

Conclusion MT imaging and TA of T2WI can both noninvasively detect established intestinal fibrosis in a mouse model. However, TA is especially useful for the longitudinal quantification of fibrosis in mixed inflammatory-fibrotic tissue, as well as for antifibrotic treatment response evaluation. This accessible post-processing technique merits further validation as the benefits for clinical practice as well as antifibrotic trial design would be numerous.

Key Points

- Magnetization transfer MRI and texture analysis of T2-weighted MR images can detect established bowel fibrosis in an animal model of gut fibrosis.
- Texture entropy is able to identify and monitor bowel fibrosis progression in an inflammatory context and can assess the response to antifibrotic treatment.
- A proof-of-concept study in five patients with Crohn's disease suggests that texture entropy can detect and grade fibrosis in human intestinal strictures.

Keywords Magnetic resonance imaging · Colitis · Inflammation · Fibrosis · Entropy

Isabelle De Kock and Simon Bos share equal first authorship contribution.

Geert Villeirs and Debby Laukens share equal senior authorship contribution.

✉ Debby Laukens
debby.laukens@UGent.be

¹ Department of Radiology and Medical Imaging, Ghent University Hospital, Ghent, Belgium

² Department of Internal Medicine and Pediatrics, Ghent University, Corneel Heymanslaan 10, 0MRB2, B-9000 Ghent, Belgium

³ VIB Center for Inflammation Research, Ghent, Belgium

⁴ Redx Pharma Plc, Macclesfield, UK

⁵ Department of Gastroenterology, Ghent University Hospital, Ghent, Belgium

Abbreviations

CD	Crohn's disease
DAI	Disease Activity Index
DSS	Dextran sulfate sodium
IncrEn	Incremental entropy
MRE	MR enterography
MT	Magnetization transfer
MTR	Magnetization transfer ratio
NormEn	Normalized entropy
T2WI	T2-weighted images
TA	Texture analysis
TI	Terminal ileum

Introduction

Crohn's disease (CD) is a multifactorial disease characterized by transmural bowel inflammation that may progress to fibrosis with intestinal strictures and obstruction. Differentiating fibrotic strictures from inflammatory narrowing of the bowel lumen is clinically important because symptomatic fibrotic strictures are currently an indication for endoscopic balloon dilatation or surgery, while inflammatory strictures may benefit from conventional anti-inflammatory therapy. As stricturing bowel segments contain variable proportions of inflammatory and fibrotic tissue, fibrosis quantification is challenging [1, 2]. Conventional cross-sectional imaging modalities, such as US, CT, and MR enterography (MRE), have high accuracy for detecting bowel inflammation but are still insufficient for quantification of fibrosis in a stricture [1, 3–5].

MRI has gained broad acceptance as the reference technique for assessing the disease extent and activity in CD [5]. Routinely used MR sequences have also been used to quantify intestinal fibrosis in CD but inconsistent data have been reported, as superimposed inflammation can mask transmural fibrosis [1, 4, 6]. Emerging imaging modalities, such as magnetization transfer (MT) MRI and texture analysis (TA), demonstrate great potential to evaluate intestinal strictures in CD [7–16]. MT-MRI is a noninvasive imaging method that enables the indirect measurement of large, immobile macromolecules, such as collagen, in an aqueous physiological environment. MT-MRI has been reported to accurately detect and quantify intestinal fibrosis in animal (rat) studies and small cohort human studies [7–13]. This technique seems sensitive to changes in bowel fibrosis and not to changes in inflammation; however, most reported studies have included one specific timepoint with no longitudinal assessment [7, 10, 11, 13].

TA is a post-processing technique applied to cross-sectional images to characterize tissue composition. It quantitatively assesses patterns of MRI-signal intensity distribution within a selected image region, producing textural parameters

that provide indirect tissue heterogeneity information not visible to the human eye [17]. TA has been successfully applied to cross-sectional cancer imaging and may aid in prognosis and treatment response [18, 19]. The use of TA on non-contrast MR images in intestinal fibrosis has not yet been studied. Furthermore, the ability of TA to detect changes in intestinal fibrosis over time also remains to be investigated.

The majority of studies investigating imaging techniques for fibrosis in CD patients use histopathology of surgical specimens as the reference standard [4]. However, surgery is usually performed in an advanced disease stage, and therefore this approach is not suitable in the long-term assessment of the development of intestinal fibrosis. As recent studies have shown that early intestinal fibrosis in CD can be reversed, imaging of early lesions harbours most clinical diagnostic value [20, 21]. The use of experimental animal models of CD can address this shortcoming. Therefore, the purpose of this study was to evaluate the role of MT imaging and TA of T2-weighted MR images (T2WI) for the longitudinal assessment of intestinal fibrosis in a mouse model of gut fibrosis and the effect of an experimental anti-fibrotic therapy.

Materials and methods

Ethics

The Institutional Review Board of Ghent University approved all animal studies (ECD/19–68 and ECD/20–67aanv). Mice were housed at Ghent University Hospital (Ghent, Belgium) according to the institutional animal healthcare guidelines. The retrospective proof-of-concept study was approved by the Ethics Committee of Ghent University Hospital (EC/2018/1493, Belgian study registration number B670201838339). Informed consent was waived because of the retrospective nature of the study.

Animal model of gut fibrosis

2.5% dextran sulfate sodium (DSS) (molecular weight = 36,000 to 50,000; MP Biomedicals) was supplemented to the drinking water of 7-week-old male C57BL/6 J mice (Janvier Labs) for seven consecutive days to induce inflammation followed by a 2-week recovery period during which mice received normal drinking water. This cycle was repeated twice, which typically results in chronic inflammation and structural bowel damage characterized by fibrotic tissue. Induction of intestinal inflammation caused by DSS was followed up using the Disease Activity Index (DAI), a combinational score of the weight evolution, stool consistency, and presence of blood in the stool [22].

In a first experiment, 16 mice were subjected to DSS administration, and two control mice were included,

receiving normal drinking water. The control mice underwent an MR examination at the baseline and endpoint (weeks 0 and 9). Mice receiving DSS treatment were scanned after each DSS-induced inflammation peak (weeks 1, 4, and 7) and after each 2-week recovery period (weeks 3, 6, and 9) (Fig. 1A). Intermediate tissue sampling was performed after scanning at week 1 ($n=5$ out of 16), week 6 ($n=5$ out of the remaining 11), and week 9 ($n=6$) for histological inflammation and fibrosis scoring. Control animals were sacrificed at week 9.

A second experiment was conducted to investigate the ability of the best performing MRI parameter from the first experiment as a surrogate marker for antifibrotic therapy response. Mice were randomized into three groups (control mice, DSS-treated mice receiving placebo, DSS-treated mice receiving an antifibrotic compound) each containing 12 animals (Fig. 1B). Control mice were scanned at the baseline and end of the experiment (week 9). Intestinal fibrosis was induced by DSS administration and these animals underwent MRI at the baseline and after each 2-week recovery period (weeks 3, 6, and 9). Mice in the treated group ($n=12$) daily received an antifibrotic compound (REDX08397, p.o. gavage, 10 mg/kg; Redx Pharma Plc) suspended in an aqueous 0.5% (hydroxypropyl) methylcellulose solution (Sigma-Aldrich) [23]. All mice were sacrificed after the final MR examination (week 9).

Imaging protocol

All details of the scanning protocol are available in Supplementary Table 1. MRI was performed on a 7-T MRI scanner (PharmaScan, Bruker). Axial T2WI were obtained in each mouse. MT imaging was acquired using two gradient-echo data sets with and without applying an off-resonance prepulse (frequency offset 2 kHz). Two readers manually drew a ROI in consensus (an abdominal radiologist with 11 years of experience (IDK) and a research fellow with 3 years of experience (SB)) in the distal colon of each mouse on a single axial T2WI. Both readers agreed to select a particular image if the following criteria were met: (a) the distal colon was well-distended; (b) the bowel wall was well-defined; (c) there was no interference from adjunct structures. The full thickness and entire circumference of the bowel wall were included within the ROI (mean size 4 mm²). Care was taken to exclude any intraluminal or extra-enteric tissue. Once defined on the T2WI, the ROI was copied and applied to the corresponding MT-image map (Supplementary Figure 1). If necessary, to account for bowel motion, minor adjustments for the position or size of the ROI were made when the ROI was copied.

The MT value was calculated using the formula $(MT_0 - MT_{\text{sat}})/MT_0$, where MT_{sat} and MT_0 refer to the signal intensities acquired with and without the off-resonance

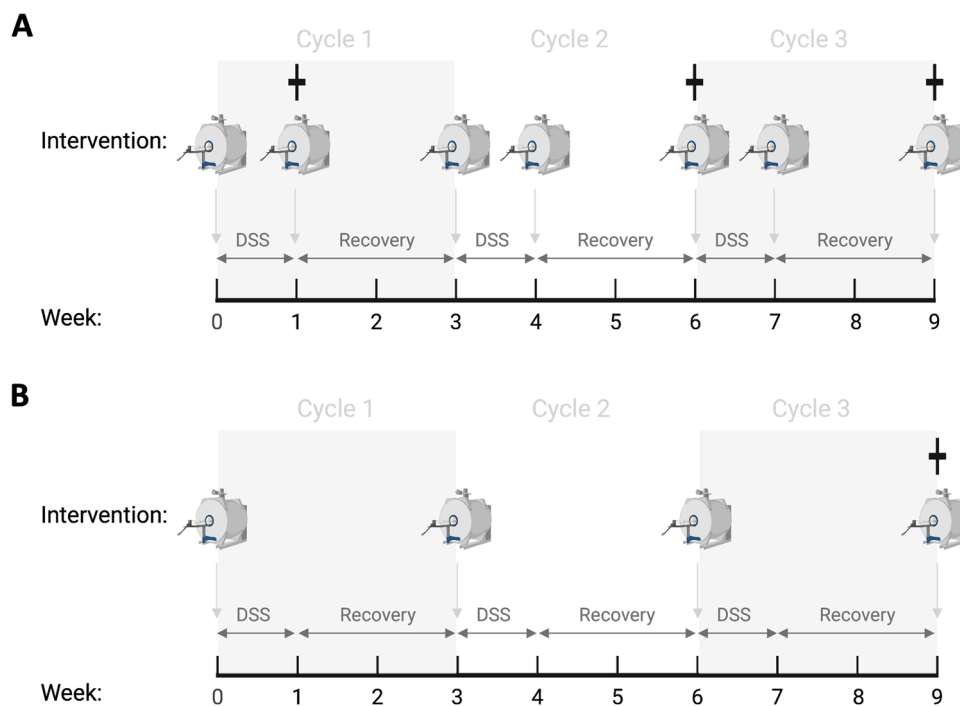


Fig. 1 Overview of the study design. Gut fibrosis was induced in mice by administering dextran sodium sulfate (DSS) to the drinking water for 1 week (acute phase) followed by 2 weeks with normal drinking water (recovery phase). This cycle was repeated twice. **A** In the first experiment, MRI was performed after every DSS week and after the recovery period in each cycle, capturing inflammatory (week 1), mixed (weeks

4 and 7), and predominantly fibrotic bowels (weeks 3, 6, and 9). Mice were sacrificed for histopathological examination at three time points (†). **B** In the second experiment, all mice were scanned at the baseline (week 0) and after each 2-week recovery period (weeks 3, 6, and 9) to monitor the effect of antifibrotic therapy. After the final MRI scan, all mice were sacrificed for histopathological analysis (†)

prepulse saturation, respectively. MT-image maps were generated using open-source image processing software (ImageJ, US National Institutes of Health). MT of the bowel wall was divided by the MT of the paraspinal muscle at the same slice in each mouse to obtain a normalized MT ratio (MTR) to minimize individual variation.

Axial T2WI were uploaded into commercially available research software (TexRAD, Feedback Plc). TA with a filtration-histogram technique was performed within the selected ROI using a previously published methodology [17]. Filtration enhances image features of different sizes (radii from 0 to 6 mm) within the ROI before subsequent histogram quantification. A spatial scale filter of 2 mm was chosen for this study, highlighting fine textural features. The heterogeneity within the ROI was quantified, and three textural parameters were obtained: kurtosis (pointiness of the pixel distribution), skewness (asymmetry of the pixel distribution), and entropy (inhomogeneity of the pixel distribution). These heterogeneity features have been previously described [17].

Regarding the entropy, we calculated the incremental entropy (IncrEn) as a relative measurement to allow a more appropriate comparison between different experiments. This parameter represents the increase in entropy in the pathologic bowel over the normal bowel. This value was calculated in experiment 1 by dividing the entropy in each mouse by the mean entropy of the two control animals at the baseline. In experiment 2, IncrEn was obtained by dividing the entropy in each mouse by its entropy value at the baseline.

Histopathologic evaluation and cytokine quantification

Details can be found in the Supplementary Text.

Proof-of-concept study in patients with Crohn's disease

Region-by-region correlations between surgical specimens and MRE were conducted by an experienced abdominal radiologist (IDK) who was blinded to the clinical and histopathological data. The most stenotic terminal ileal areas were selected for histopathological assessment and MRE correlation, and one specimen per patient was obtained. Routine clinical assessments require only a conventional MRE; thus, no MT images were available, and only TA was feasible. TA was performed by placing an ROI (mean size 150 mm²) on the pathologic small bowel wall on the axial T2WI in each patient ($n = 5$) and in a normal-appearing small bowel ($n = 5$) to calculate the normalized entropy (NormEn = $\text{entropy}_{\text{pathologic bowel}} / \text{entropy}_{\text{normal bowel}}$).

Statistical analysis

Statistical analyses were performed in SPSS (v.27; IBM). A linear mixed model assessed differences in body weight and DAI progression. The Pearson correlation test was applied to explore the relationship between MRI parameters and pathophysiological data. A one-way analysis of variance was used when comparing the normally distributed data between groups, applying Dunnett's multiple comparison correction. Linear regression and a mixed model analysis were used to evaluate the MRI parameters. The Akaike information criterion was consulted to select the best covariance structure to perform a mixed model analysis when comparing parameters between different scan timepoints. The p values from the mixed model analysis were corrected for multiple comparisons using the more stringent 99% confidence interval.

Results

MTR and texture entropy can detect bowel fibrosis during subclinical inflammation

DSS-treated mice demonstrated relapsing and remitting disease activity (Supplementary Figure 2) and a progressive increase in histopathological fibrosis scores at weeks 1, 6, and 9 compared to healthy control mice ($p = 0.0217$, $p = 0.0006$, and $p < 0.0001$, respectively; Fig. 2A). Histological inflammation was observed in DSS-treated mice sacrificed at week 1 ($p < 0.0001$), whereas inflammation was only marginally present in samples collected at weeks 6 and 9 (Fig. 2B). Histopathologic scores and imaging parameters acquired during each recovery phase were plotted to assess the performance of MTR and TA as surrogate markers for fibrosis in the presence of subclinical inflammation. MTR values were strongly correlated with the histopathological fibrosis scores ($r = 0.85$; $p = 0.0005$; Fig. 2C). Of the three textural parameters analyzed by TA (skewness, kurtosis, and entropy), only entropy correlated well with the fibrosis scores ($r = 0.81$; $p = 0.0011$; Fig. 2D).

Texture entropy, but not MTR, can monitor bowel fibrosis with coexisting inflammation

In the presence of inflammation, texture entropy outperformed MTR in quantifying the increase in fibrotic tissue after each DSS administration (week 1 vs. week 4: $\Delta \text{mean} = 0.338$, $p = 0.0010$ for entropy and $\Delta \text{mean} = -0.065$, $p = 0.1070$ for MTR; week 1 vs. week 7: $\Delta \text{mean} = 0.471$, $p = 0.0040$ for entropy and $\Delta \text{mean} = 0.051$, $p = 0.2710$ for MTR; Fig. 3A). During the sequential recovery phases with diminishing inflammation and progressive build-up of fibrosis, only MTR and texture entropy at week 9 were significantly higher compared to week 3 ($\Delta \text{mean} = 0.208$, $p < 0.0001$ and $\Delta \text{mean} = 0.366$,

Fig. 2 Correlation between histopathologic fibrosis, magnetization transfer ratio (MTR), and texture entropy in the dextran sodium sulfate (DSS) mouse model. **(A)** Intestinal fibrosis scores and **(B)** inflammation scores for healthy control mice ($n=2$) and DSS-treated mice sacrificed at weeks 1, 6, and 9 ($n=5, 5, \text{ and } 6$, respectively). **(C)** Correlation of MTR with histopathology and **(D)** texture entropy with histopathology using the fibrosis scores from each recovery phase ($n=11$). AU, arbitrary units; $*p < .05$; $***p < .001$; $****p < .0001$; data in **A** and **B** are represented as the mean \pm the standard error of the mean

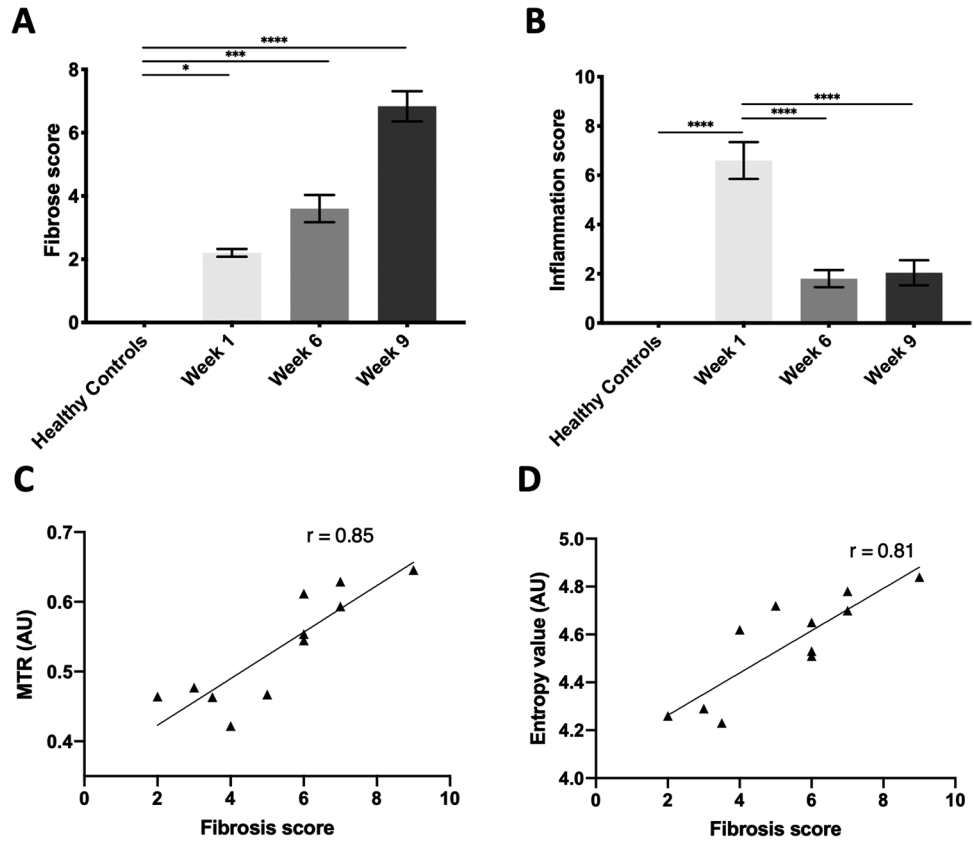
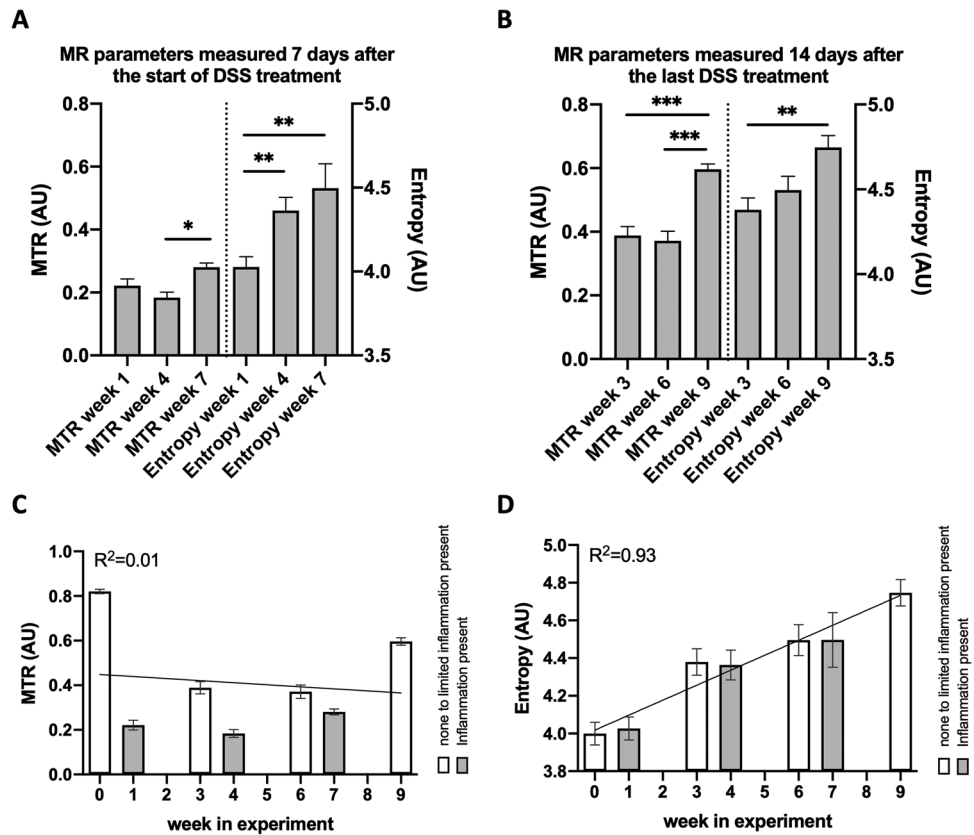


Fig. 3 MR parameters during dextran sulfate sodium (DSS)–induced inflammation and following recovery. **A** Magnetization transfer ratio (MTR) and texture entropy values acquired during the acute inflammatory phase of each DSS cycle (weeks 1, 4, and 7 ($n=16, 11, \text{ and } 6$, respectively)). **B** MTR and entropy values acquired during the recovery period for each DSS cycle (weeks 3, 6, and 9 ($n=11, 11, \text{ and } 6$, respectively)). **(C)** MTR values and **(D)** entropy values throughout the experiment with the linear regression trend line (week 0 represent the healthy control mice ($n=2$)). AU, arbitrary units; $*p < .05$, $**p < .01$, and $***p < .001$. Data are represented as the mean \pm the standard error of the mean



$p=0.0050$, respectively), indicating that only well-established fibrosis during recovery is detectable by both MRI parameters (Fig. 3B). When combining multiple scan moments, linear regression indicated that MTR could not capture the steady increase in fibrotic tissue in the presence of inflammation throughout the experiment ($p_{\text{slope}}=0.7780$, $R^2=0.01$, Fig. 3C). In contrast, texture entropy demonstrated excellent performance for monitoring fibrosis progression during periods of active inflammation as well as recovery periods ($p_{\text{slope}}=0.0004$, $R^2=0.93$, Fig. 3D). MTR values were unexpectedly high at the baseline and consistently lower in the presence of inflammation at each cycle of DSS (week 0 vs. week 1: $\Delta\text{mean}=-0.598$, $p<0.0001$; week 3 vs. week 4: $\Delta\text{mean}=-0.205$, $p<0.0001$; and week 6 vs. week 7: $\Delta\text{mean}=-0.0910$, $p=0.1010$).

An increase in texture entropy can act as a surrogate marker for assessing antifibrotic therapy response

Next, we aimed to determine the performance of MTR and texture entropy in monitoring fibrosis in mice treated with a well-established antifibrotic compound [24]. DAI demonstrated a similarly proficient induction of bowel inflammation throughout the consecutive DSS cycles between the three groups of mice (control group, placebo group, and antifibrotic treatment group), indicating that the antifibrotic compound did not alter intestinal inflammation induced by DSS (Supplementary Figure 3). At week 9, placebo mice exhibited significantly higher histopathological fibrosis compared with the treated mice ($p<0.0001$), confirming the effectiveness of the treatment (Fig. 4A). This antifibrotic effect was associated with significantly lower colonic tissue levels of the pro-fibrotic cytokines interleukin-6 and transforming growth factor $\beta 1$ ($p=0.0341$ and $p=0.0171$, respectively; Fig. 4B).

The placebo and healthy control mice exhibited MRI parameter values consistent with the first experiment. Nonetheless, with the inclusion of the antifibrotic treatment group, a negative correlation was found at week 9 between the MTR values and fibrosis grade ($r=-0.90$; $p<0.0001$; Fig. 5A). The combined MR data from both experiments demonstrated that a rise in the MTR value could theoretically indicate bowel tissue receiving treatment that develops toward normal tissue or diseased bowel tissue in which fibrosis is accumulating (Fig. 5B). Because of these unexpected findings and the inflammation-dependent drop in MTR observed in the first experiment, we further investigated the influence of inflammation on the MTR values. To this end, the DAI scores were plotted against the MTR values from all scans collected in the two experiments, resulting in a significant negative correlation ($r=-0.68$; $p<0.0001$; Supplementary Figure 4). This result confirmed that coexisting inflammation substantially affects MTR. In contrast, a strong positive correlation between fibrosis and texture entropy was confirmed, using the increase in entropy compared to the baseline entropy (IncrEn; $r=0.84$; $p<0.0001$; Fig. 5C).

As MTR values are influenced by inflammation, we focused on entropy to evaluate the effect of the antifibrotic therapy. A progressive increase in IncrEn was observed in the placebo-treated group (baseline vs. week 3: $\Delta\text{mean}=0.079$, $p<0.0001$; week 3 vs. week 6: $\Delta\text{mean}=0.039$, $p<0.05$; and week 6 vs. week 9: $\Delta\text{mean}=0.064$, $p<0.0001$). In contrast, only a significant but marginal change was noted between the baseline and week 3 in the antifibrotic treatment group ($\Delta\text{mean}=0.037$, $p<0.05$). At the endpoint scan (week 9), IncrEn values were significantly higher in the placebo mice compared with the antifibrotic treatment mice ($\Delta\text{mean}=0.128$, $p<0.0001$; Fig. 5D).

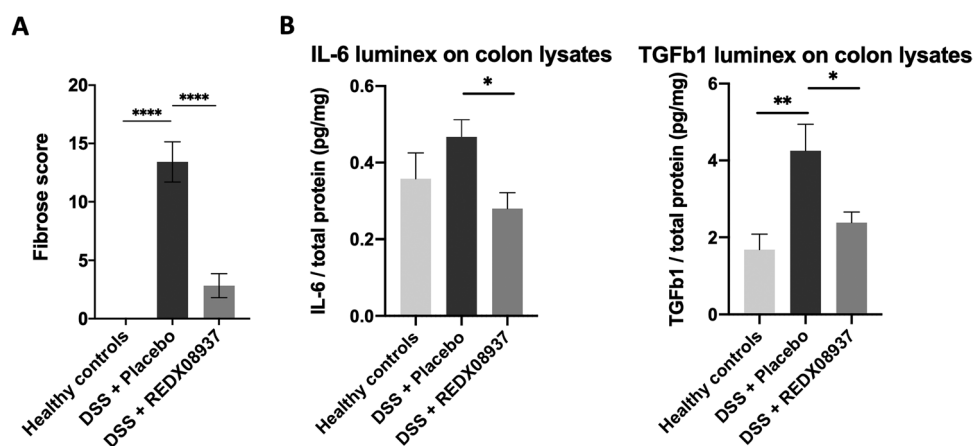


Fig. 4 Texture entropy can monitor antifibrotic therapy (REDX08937) response in chronic dextran sulfate sodium (DSS)-induced colitis. Mice were treated with an antifibrotic compound (REDX08937) or placebo ($n=12$ in each group). (A) Histopathological fibrosis analysis and (B)

interleukin-6 and transforming growth factor $\beta 1$ protein levels in the colon of healthy, REDX08937-treated, and placebo-treated DSS mice at week 9. * $p<0.05$; ** $p<0.01$; **** $p<0.0001$. Data are represented as the mean \pm the standard error of the mean; $n=12$ for all groups

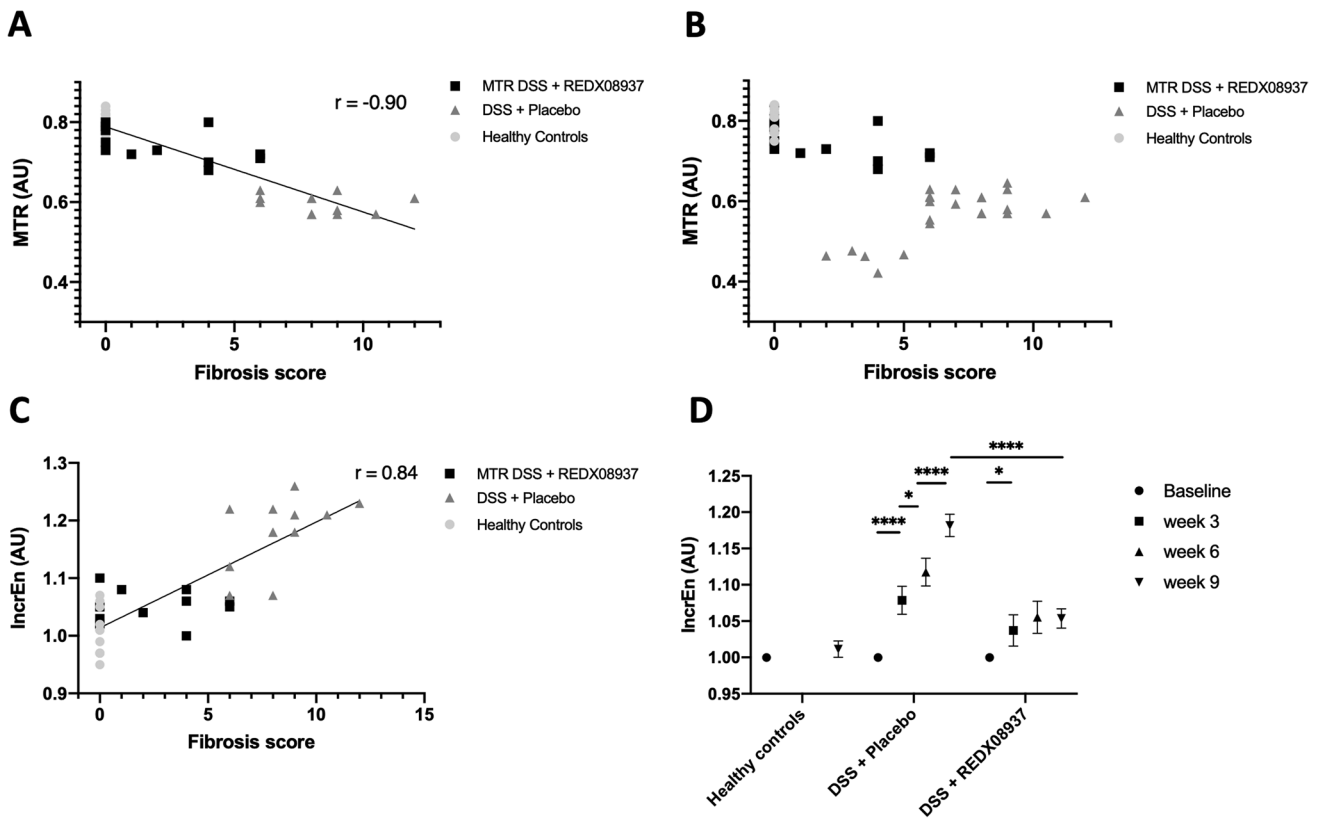


Fig. 5 Correlation between histopathology, magnetization transfer ratio (MTR), and texture entropy in the dextran sulfate sodium (DSS) mouse model treated with an antifibrotic compound. **A** Correlation of MTR with histopathologic fibrosis at week 9. **B** Combined MTR data from the first and second experiments plotted in the function of fibrosis scores determined after scarification at week 6 (experiment 1) and

week 9 (experiments 1 and 2). **C** Correlation between histopathology and incremental entropy (IncrEn) for the second experiment. **D** Evolution of grouped IncrEn values ($n = 12$ in each group) for MRI scans performed in healthy, REDX08937-treated, and placebo-treated DSS mice after each recovery phase. AU, arbitrary units. Data are represented as the mean \pm the standard error of the mean

Texture entropy shows potential for grading fibrosis in Crohn’s disease

T2WI of five patients with CD obtained before ileocecal resection were retrospectively analyzed to provide proof of concept

for translating the findings in patients with CD. Patient characteristics are summarized in Table 1. Using the histologic evaluation of the resected specimens (i.e., terminal ileum), one bowel segment was categorized as predominantly inflammatory, two segments as mixed inflammatory fibrotic, and two segments as

Table 1 Characteristics of patients with Crohn’s disease

	Patient 1	Patient 2	Patient 3	Patient 4	Patient 5
Sex	Male	Male	Female	Male	Female
Age (years)	31	41	67	27	34
Disease duration (months)	48	12	564	1	84
Medication at time of surgery	Steroids	-	Adalimumab	-	Adalimumab
Interval between MRI and surgery (days)	20	45	14	13	83
CRP (mg/L)	1.8	3.8	<1.0	7.0	1.2
Stricture location	Terminal ileum	Terminal ileum	Terminal ileum	Terminal ileum	Terminal ileum
Stricture histology	Inflammation	Mixed	Mixed	Fibrosis	Fibrosis
Entropy _{normal bowel}	2.64	2.77	2.46	2.56	2.30
Entropy _{pathologic bowel}	3.32	3.89	3.66	4.43	4.37
NormEn	1.29	1.40	1.48	1.73	1.90

CRP, C-reactive protein (normal <5.0 mg/L); NormEn, normalized entropy

predominantly fibrotic. The NormEn was 1.29 for the inflammatory bowel segment, 1.40 and 1.48 for the mixed segments, and 1.73 and 1.90 for the fibrotic segments, indicating that an increase in texture entropy can serve as a parameter to detect and grade intestinal fibrosis in human strictures (Fig. 6).

Discussion

A major need for the adequate management of CD is a non-invasive tool to diagnose and quantify intestinal fibrosis. The transmural nature of gut fibrosis does not allow endoscopic evaluation. Histology requires full-thickness biopsies or surgical resection specimens but remains the gold standard for evaluating fibrosis. However, CD patients who are referred to surgery exhibit advanced disease with major structural and probably irreversible damage. Early detection of intestinal fibrosis and noninvasive assessment of fibrosis progression remains currently inadequate. To overcome these issues, we used a chronic colitis mouse model in which intermittent sampling of progressive fibrotic tissue allows correlation with MRI findings. We found that texture entropy is able to detect the early development of intestinal fibrosis and can monitor its accumulation over

time, whereas MT-MRI could only identify advanced bowel fibrosis. These are the first data suggesting that texture entropy may become an attractive tool to monitor the natural history of CD. This result is partially in line with the study by Adler et al, who used MT-MRI to detect changes in bowel wall fibrosis over time in a rat model using cecal injections of peptidoglycan-polysaccharide [7]. A progressive increase in MTR was found until 28 days after injection; however, no significant difference existed in MTR between study and control animals until fibrosis was well-established. Of note, we performed TA of T2WI, because recent concerns regarding gadolinium tissue deposition favor the use of non-contrast MRI [24]. To our knowledge, TA of T2WI in intestinal fibrosis has not yet been investigated.

As in human CD, inflammation and fibrosis coexist in the chronic phase of DSS-induced colitis. We demonstrated that texture entropy can accurately identify intestinal fibrosis in the presence of concomitant inflammation in the murine intestine. This important finding represents a significant advantage as other quantitative MRI techniques, such as bowel wall perfusion or diffusion-weighted MRI, have shown to have limitations in detecting the fibrotic component within mixed strictures [25–27]. Conversely, we found that MTR is sensitive to intestinal inflammation and therefore seems unsuitable for

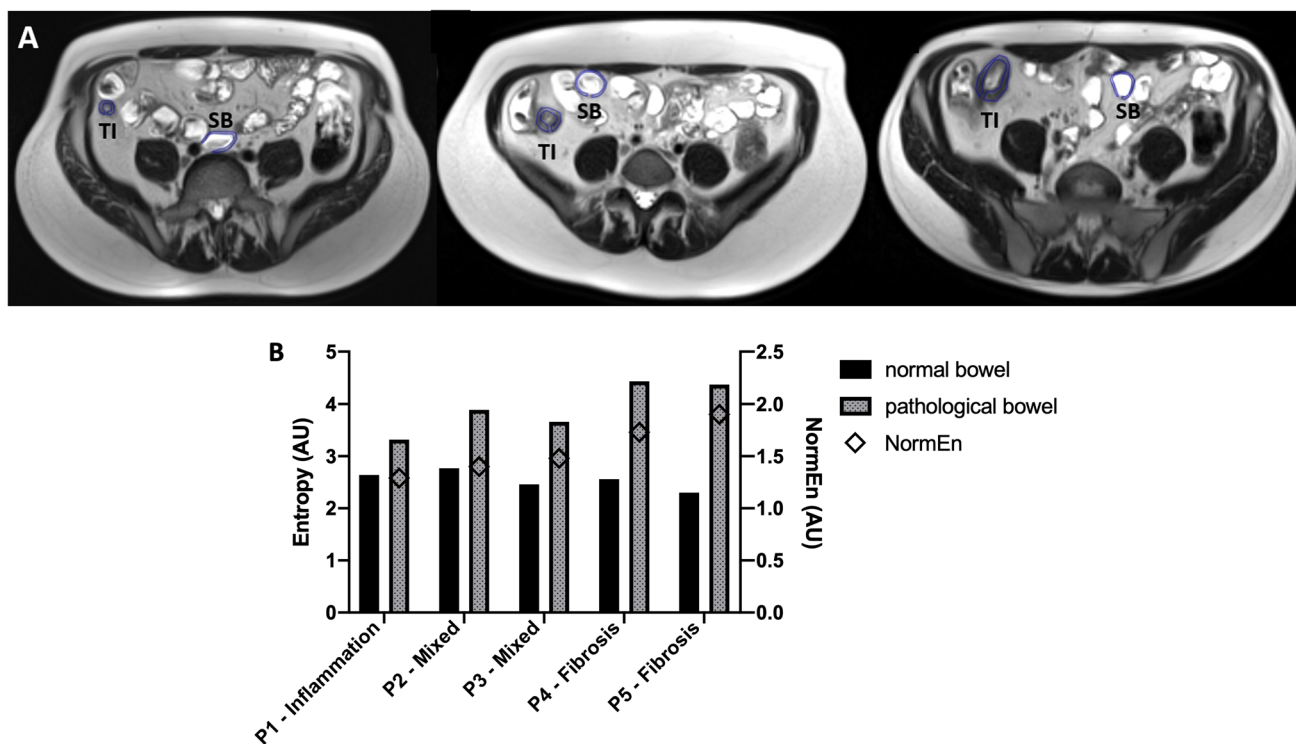


Fig. 6 Texture entropy as a surrogate marker of intestinal fibrosis in patients with Crohn’s disease (CD). **A** Axial T2-weighted MR images (T2WI) with region-of-interest placement in the affected terminal ileum (TI) and normal-appearing small bowel (SB) are depicted for three patients with different histologic subtypes: (left panel) a 31-year-old male with active inflammation in the TI without fibrosis,

(mid panel) a 41-year-old male with active inflammation and fibrosis in the TI, and (right panel) a 34-year-old female with fibrosis but no active inflammation in the TI. **B** An increase in normalized entropy values (NormEn) is seen in all five CD patients (P1–P5) when fibrotic tissue accumulates in the bowel wall, whereas these values remain at a similar level in normal SB. AU, arbitrary units

fibrosis monitoring in an inflammatory context, contradicting previous reports. Adler et al compared MT images in early-phase intestinal inflammation with late phase fibrosis in a rat model and found increasing MTR values correlating with an increase in histologic fibrosis and a decrease in histologic inflammation, suggesting that MTR is sensitive to changes in fibrosis, but not to inflammation [7]. Nonetheless, no baseline values were reported. More importantly, inflammation was induced by a single trigger; therefore, we suspect that inflammation could not have influenced MTR in this particular experimental setup. Dillman et al demonstrated that MTR can distinguish between predominantly inflammatory and mixed inflammatory-fibrotic bowel tissue in a chronic colitis rat model [10]. Again, no baseline scan parameters were reported, and only mixed strictures were investigated.

Finally, we demonstrated that texture entropy is an adequate noninvasive tool for monitoring the response to antifibrotic treatment in an experimental setup. To our knowledge, this is the first study to identify the value of this technique for the evaluation of treatment response. This could be an important finding as the lack of accurate noninvasive diagnostic methods currently hinders the roll-out of antifibrotic therapeutic clinical trials in CD.

TA has the potential to be readily implementable in clinical practice. As it is a post-processing imaging technique, it can be retrospectively applied to data acquired during routine cross-sectional imaging. Since several open-source tools are already available, there is no need for expensive software. In addition, a general advantage of TA is its intrinsic quantitative nature, which makes it well suited for developing artificial intelligence algorithms that can automatically extract imaging features from medical image data undiscernible to the human eye. Such algorithms would significantly improve radiologist interpretation of patient images, and offer great potential to derive quantitative imaging markers of disease activity and therapy response.

Although the sensitivity and specificity of TA for human use need to be confirmed in prospective human studies, our proof-of-concept data suggest that an increase in texture entropy can also determine the extent of fibrosis in human bowel segments. A limitation of this study is the use of sedation during imaging without the use of adequate antimotility agents leading to moving artifacts due to peristaltic motion. However, we excluded images that were of poor quality. Finally, ROI selection was based on manual segmentation of the bowel wall within a single axial image. Development of volumetric segmentation tools will allow evaluation of bowel segments in their entirety.

In conclusion, texture entropy holds promise to become a reliable tool for intestinal fibrosis assessment and should be explored further, since it would directly benefit patient care as well as the development of antifibrotic clinical trials. These data pave the way to prospective human studies, especially since this technique is easily accessible for most clinical centers, does not require intravenous contrast administration, and can be processed at any time.

Supplementary Information The online version contains supplementary material available at <https://doi.org/10.1007/s00330-023-09624-x>.

Acknowledgements The antifibrotic compound (REDX08397) that was used in this study was provided by Redx Pharma Plc.

Statistical analyses were performed by Dr Ellen Deschepper (Biostatistics Unit, Ghent University, Ghent, Belgium).

Histopathologic evaluation was co-executed by professor emeritus Dr Karel Geboes (University Hospital KULeuven, Leuven, Belgium).

Figures were partially created with BioRender.

Funding This study was supported by research grants from the Department of Radiology and Medical Imaging, Ghent University Hospital, Ghent, Belgium. Sophie Van Welden is supported by a fellowship from Ghent University, Ghent, Belgium [BOF20/PDO/047].

Declarations

Guarantor The scientific guarantor of this publication is Prof Dr Debby Laukens.

Conflict of interest Peter Bunyard is an employee of Redx Pharma Plc but had no control of the data nor control of information that might present a conflict of interest. The other authors of this manuscript declare no relationships with any companies, whose products or services may be related to the subject matter of the article.

Statistics and biometry Dr Ellen Deschepper provided statistical advice for this manuscript and performed statistical analyses. One of the authors, Simon Bos, has significant statistical expertise.

Informed consent Written informed consent was waived because of the retrospective nature of the proof-of-concept study.

Ethical approval The proof-of-concept study was approved by the Ethics Committee of Ghent University Hospital (EC/2018/1493, Belgian study registration number B670201838339). Approval from the institutional animal care committee was obtained.

Methodology

- Animal study: prospective; human proof-of-concept study: retrospective
- Experimental
- Performed at one institution

References

1. Zhong YK, Lu BL, Huang SY et al (2020) Cross-sectional imaging for assessing intestinal fibrosis in Crohn's disease. *J Dig Dis* 21(6):342–350
2. Higgins PD (2017) Measurement of fibrosis in Crohn's disease strictures with imaging and blood biomarkers to inform clinical decisions. *Dig Dis* 35(1–2):32–37
3. Rieder F, Latella G, Magro F et al (2016) European Crohn's and Colitis Organisation topical review on prediction, diagnosis and management of fibrostenosing Crohn's disease. *J Crohns Colitis* 10(8):873–885
4. Bettenworth D, Bokemeyer A, Baker M et al (2019) Assessment of Crohn's disease-associated small bowel strictures and fibrosis on cross-sectional imaging: a systematic review. *Gut* 68(6):1115–1126
5. Maaser C, Sturm A, Vavricka SR et al (2019) ECCO-ESGAR guideline for diagnostic assessment in IBD Part 1: Initial diagnosis, monitoring of known IBD, detection of complications. *J Crohns Colitis* 13(2):144–164

6. Rimola J, Planell N, Rodriguez S et al (2015) Characterization of inflammation and fibrosis in Crohn's disease lesions by magnetic resonance imaging. *Am J Gastroenterol* 110(3):432–440
7. Adler J, Swanson SD, Schmiedlin-Ren P et al (2011) Magnetization transfer helps detect intestinal fibrosis in an animal model of Crohn disease. *Radiology* 259(1):127–135
8. Pazahr S, Blume I, Frei P et al (2013) Magnetization transfer for the assessment of bowel fibrosis in patients with Crohn's disease: initial experience. *MAGMA* 26(3):291–301
9. Adler J, Rahal K, Swanson SD et al (2013) Anti-tumor necrosis factor alpha prevents bowel fibrosis assessed by messenger RNA, histology, and magnetization transfer MRI in rats with Crohn's disease. *Inflamm Bowel Dis* 19(4):683–690
10. Dillman JR, Swanson SD, Johnson LA et al (2015) Comparison of noncontrast MRI magnetization transfer and T2-weighted signal intensity ratios for detection of bowel wall fibrosis in a Crohn's disease animal model. *J Magn Reson Imaging* 42(3):801–810
11. Li XH, Mao R, Huang SY et al (2018) Characterization of degree of intestinal fibrosis in patients with Crohn disease by using magnetization transfer MR imaging. *Radiology* 287(2):494–503
12. Meng J, Huang S, Sun C et al (2020) Comparison of three magnetization transfer ratio parameters for assessment of intestinal fibrosis in patients with Crohn's disease. *Korean J Radiol* 21(3):290–297
13. Fang ZN, Li XH, Lin JJ et al (2020) Magnetisation transfer imaging adds information to conventional MRIs to differentiate inflammatory from fibrotic components of small intestinal strictures in Crohn's disease. *Eur Radiol* 30(4):1938–1947
14. Makanyanga J, Ganeshan B, Rodriguez-Justo M et al (2017) MRI texture analysis (MRTA) of T2-weighted images in Crohn's disease may provide information on histological and MRI disease activity in patients undergoing ileal resection. *Eur Radiol* 27(2):589–597
15. Bhatnagar G, Makanyanga J, Ganeshan B et al (2016) MRI texture analysis parameters of contrast-enhanced T1-weighted images of Crohn's disease differ according to the presence or absence of histological markers of hypoxia and angiogenesis. *Abdom Radiol (NY)* 41(7):1261–1269
16. Tabari A, Kilcoyne A, Jeck WR, Mino-Kenudson M, Gee MS (2019) Texture analysis of magnetic resonance enterography contrast enhancement can detect fibrosis in Crohn disease strictures. *J Pediatr Gastroenterol Nutr* 69(5):533–538
17. Miles KA, Ganeshan B, Hayball MP (2013) CT texture analysis using the filtration-histogram method: what do the measurements mean? *Cancer Imaging* 13(3):400–406
18. Goh V, Ganeshan B, Nathan P, Juttla JK, Vinayan A, Miles KA (2011) Assessment of response to tyrosine kinase inhibitors in metastatic renal cell cancer: CT texture as a predictive biomarker. *Radiology* 261(1):165–171
19. Ng F, Ganeshan B, Kozarski R, Miles KA, Goh V (2013) Assessment of primary colorectal cancer heterogeneity by using whole-tumor texture analysis: contrast-enhanced CT texture as a biomarker of 5-year survival. *Radiology* 266(1):177–184
20. Rieder F, Fiocchi C, Rogler G (2017) Mechanisms, management, and treatment of fibrosis in patients with inflammatory bowel diseases. *Gastroenterology* 152(2):340–50 e6
21. Jairath V, Levesque BG, Vande Casteele N et al (2017) Evolving concepts in phases I and II drug development for Crohn's disease. *J Crohns Colitis* 11(2):246–255
22. Van Welden S, De Vos M, Wielockx B et al (2017) Haematopoietic prolyl hydroxylase-1 deficiency promotes M2 macrophage polarization and is both necessary and sufficient to protect against experimental colitis. *J Pathol* 241(4):547–558
23. Holvoet T, Devriese S, Castermans K et al (2017) Treatment of intestinal fibrosis in experimental inflammatory bowel disease by the pleiotropic actions of a local Rho kinase inhibitor. *Gastroenterology* 153(4):1054–1067
24. Kanda T, Nakai Y, Oba H, Toyoda K, Kitajima K, Furui S (2016) Gadolinium deposition in the brain. *Magn Reson Imaging* 34(10):1346–1350
25. Li XH, Sun CH, Mao R et al (2015) Assessment of activity of Crohn disease by diffusion-weighted magnetic resonance imaging. *Medicine (Baltimore)* 94(43):e1819
26. Wilkens R, Hagemann-Madsen RH, Peters DA et al (2018) Validity of contrast-enhanced ultrasonography and dynamic contrast-enhanced MR enterography in the assessment of transmural activity and fibrosis in Crohn's disease. *J Crohns Colitis* 12(1):48–56
27. Catalano OA, Gee MS, Nicolai E et al (2016) Evaluation of quantitative PET/MR enterography biomarkers for discrimination of inflammatory strictures from fibrotic strictures in Crohn disease. *Radiology* 278(3):792–800

Publisher's note Springer Nature remains neutral with regard to jurisdictional claims in published maps and institutional affiliations.

Springer Nature or its licensor (e.g. a society or other partner) holds exclusive rights to this article under a publishing agreement with the author(s) or other rightsholder(s); author self-archiving of the accepted manuscript version of this article is solely governed by the terms of such publishing agreement and applicable law.