

Waleed Ajaj
Stefan G. Ruehm
Susanne C. Ladd
Guido Gerken
Mathias Goyen

Utility of dark-lumen MR colonography for the assessment of extra-colonic organs

Received: 9 May 2006
Revised: 28 September 2006
Accepted: 24 October 2006
Published online: 24 January 2007
© Springer-Verlag 2007

W. Ajaj (✉) · M. Goyen
Medical Center, University Hospital
Hamburg-Eppendorf,
Martini-Straße 52,
22046 Hamburg, Germany
e-mail: ajaj@uke.uni-hamburg.de
Tel.: +49-40-428034574
Fax: +49-40-8240312522

S. G. Ruehm
David Geffen School of Medicine,
Department of Radiology,
University of California-Los Angeles,
Los Angeles, USA

S. C. Ladd
Department of Diagnostic
and Interventional Radiology
and Neuroradiology,
University Hospital Essen,
Essen, Germany

G. Gerken
Department of Gastroenterology
and Hepatology, University Hospital
Essen,
Essen, Germany

Abstract The aim of the study was to evaluate the utility of dark-lumen MR colonography (MRC) for the assessment of extra-colonic organs. Three hundred seventy-five subjects with suspected colonic disease underwent a complete MRC examination. MRC data were evaluated by two radiologists in a blinded fashion. In addition to the large bowel, the extra-intestinal organs from the lung bases to the pelvis were assessed for the presence of pathologies. All findings were divided into known or unknown findings and therapeutically relevant or irrelevant findings. If deemed necessary, other diagnostic imaging tests to further assess those findings were performed. In total, 510 extra-colonic findings were found in 260 (69%) of the 375 subjects. Known extra-colonic findings were found in 140 subjects (54%) and unknown findings in 120 subjects (46%). Thirty-one (12%) of the 260 subjects had therapeutically relevant findings (45 findings); 229 patients (88%) had irrelevant findings (465 findings). Dark-lumen MRC is a useful tool not only for the assessment of the entire

colon, but also for the evaluation of extra-colonic organs. Thus, intra- and extra-colonic pathologies can be diagnosed within the same examination.

Keywords Conventional colonoscopy · Virtual colonoscopy · MR colonography · Colorectal pathologies · Extra-colonic findings

Introduction

Conventional colonoscopy (CC) represents the gold standard for the evaluation of the entire colon and its pathologies [1, 2]. Despite its use as a gold standard, colonoscopy is not without limitations due to invasiveness and procedure-related discomfort, which can lead to poor

patient acceptance for CC [3, 4]. In addition, the view of the endoscopist is limited to assess the colonic lumen, and thus the evaluation of the extra-colonic organs is not possible. Therefore, extra-colonic abdominal organs will not be assessed. Their presence or absence, however, might be important for further patient management. Thus, the evaluation of the extra-colonic organs can be done using

additional imaging techniques, which cause additional costs and possible waiting times for the examination. Those limitations can be compensated by the use of virtual colonoscopy. Virtual colonoscopy using computed tomography (CT) and magnetic resonance imaging (MR) is based on the acquisition of 3D data sets. Reflecting its non-invasive character, these techniques are preferred over conventional colonoscopy by a majority of patients [5–17]. Initial studies documented high diagnostic accuracies for both CT and MR colonography [5, 6, 11–17], thereby they are evolving as an attractive alternative to conventional colonoscopy (CC) for the detection of colorectal pathologies and allow the coeval assessment of the extra-colonic organs [13–21].

The aim of this study was to evaluate the utility of dark-lumen MRC for the assessment of extra-colonic organs in patients referred to MRC for various indications.

Materials and methods

The study was performed according to good clinical practice (GCP) rules and was approved by the local ethical committee. Written informed consent was obtained from all patients, who were not charged for the examination. Exclusion criteria included contraindications to MR imaging, such as the presence of a pacemaker, all metallic implants, including in the central nervous system or vessel system, and claustrophobia.

Subjects

Over a 3-year period, 380 consecutive patients (249 men; 131 women; age range, 18–76 years; mean age, 51.7 years) had been referred to MRC for various indications, including abdominal pain (n=90), screening examinations in patients >50 years (n=61), known Crohn's disease or ulcerative colitis (n=57), a positive fecal occult blood test (n=44), a positive family history of colorectal cancer (n=27), elevated hepatic enzymes (n=25), chronic diarrhea (n=25), a previous history of colorectal cancer (n=19), yearly follow-up examination after surgical treatment (n=17) and others (n=15). The indication for MRC was not pre-determined; the clinicians decided if a patient was scheduled for the respective examination.

Bowel preparation

Prior to MRC, all patients underwent a standardized bowel-cleansing procedure with 3,000 ml of a polyethylene glycol solution (Golytely: sodium chloride 1.46 g, sodium hydrogencarbonate 1.68 g, sodium sulfate 5.68 g, potassium chloride 0.75 g, polyethylen glycol 4.000 59 g, Braintree Laboratories, Braintree, MA), of which 2,000 ml

were ingested the night before and 1,000 ml in the morning of the examination day.

MR imaging

All MR examinations were performed on a 1.5-T MR system (Magnetom Sonata, Siemens Medical Solutions, Erlangen, Germany) equipped with a high-performance gradient system characterized by a maximum gradient amplitude of 40 mT/m and a slew rate of 200 mT/m/ms in the prone position. The prone position leads to a reduction of motion artifacts of the bowel due to the compression of the bowel segments. A combination of two surface coils was used in conjunction with the built-in spine array coil for signal reception to permit coverage of the entire colon. To minimize bowel peristalsis, 40 mg of scopolamine (Buscopan; Boehringer Ingelheim, Germany) were injected intravenously prior to the rectal enema. In case of contraindications for the administration of scopolamine, the minimization of the bowel peristalsis was performed using 1 mg of glucagon (Glucagen; Novo Nordisk Pharma, Mainz, Germany). Following the placement of a rectal enema tube (E-Z-Em, Westbury, NY) the colon was filled with approximately 2,000–2,500 ml of warm tap water. The filling process was performed without fluoroscopic control, as the maximum amount of water that can be administered depends only on the patient's subjective feeling. Following bowel distension, a pre-contrast T1w 3D gradient-echo data set with integrated fat suppression [VIBE sequence (volumetric interpolated breathhold examination)] was collected in the coronal plane. Sequence parameters included: TR/TE 3.1/1.1 ms, flip angle 12°, field of view (FOV) 450 × 450 mm, matrix 168 × 265 and an effective slice thickness of 1.5–2.0 mm, depending on the patient's size. The 3D data sets were collected with breath holding in 22 s. Subsequently, paramagnetic contrast (Gd-BOPTA, MultiHance, Bracco, Italy) was administered i.v. at a dosage of 0.2 mmol/kg body weight and a flow rate of 3.5 ml/s. Following a delay of 75 and 120 s, respectively, a second and third 3D data set was acquired with identical parameters. Hence, the lack of contrast enhancement between the pre- and post-contrast scans rules out the presence of a colorectal mass. The intravenous application of paramagnetic contrast technique allows the direct depiction of the colorectal wall. Thus, the bright colonic wall can be easily discriminated from the dark, water-filled colonic lumen. This form of direct visualization of all colorectal pathologies reduces the incidence of false-positive findings: residual stool. The third 3D data sets assured the receipt of diagnostic image quality of MRC in case of motion artifacts or a mistake of the patients during the second 3D data sets. Furthermore, a 2D FLASH (fast low angle shot) sequence of the entire abdomen and pelvis was acquired in the axial plane (sequence parameters included: TR/TE 125 /1.8 ms, flip angle 70° and a slice

thickness of 5 mm). After MRC the water enema was led back into the enema bag. The subjects then went to the restroom.

Data analysis

For the evaluation of the MRC data sets, the pre-contrast and both contrast-enhanced 3D VIBE and 2D FLASH images of each subject were transferred to a post-processing workstation (Virtuoso, Siemens Medical Solutions, Erlangen, Germany). The VIBE images were analyzed in the multiplanar reformation mode, which permitted scrolling through the 3D data sets in all three orthogonal planes; the 2D FLASH images were analyzed in the axial plane by two experienced radiologists (>4 years experience in MR abdominal imaging) in a blinded fashion and in consensus. The evaluation of the entire colon was based on assessing the wall thickness and contrast uptake between the pre- and post-contrast phase. In addition, all extra-colonic organs from the lung bases to the symphysis including abdominal and pelvic organs, lymph nodes, vessels, bone and soft tissues were assessed for the presence of pathologies. Employed criteria for the evaluation of the extra-colonic organs were the enhancement and/or notch of the contrast agent (hyperintense vs. hypointense), presence of masses and disorder of the regular anatomy of the organs. The required time for the data analysis, report and demonstration of the MRC examination for each patient was documented.

Image quality

The image quality of the MRC examination was assessed based on the distension of the bowel, bowel cleansing and the presence of motion and aliasing artifacts and divided into three grades: 1= good diagnostic image quality, 2= moderate diagnostic image quality and 3= poor, non-diagnostic image quality.

Image demonstration

After the examination the findings of the MRC were discussed with the patients at the post-processing workstation. All intra- and extra-colonic findings were documented and were divided into known or unknown findings and therapeutically relevant or irrelevant findings. The characterization of extra-colonic findings as therapeutically relevant or irrelevant was based on our clinical experiences. Furthermore, in cases of suspected pathologic intra- or extra-colonic findings, other diagnostic procedures like conventional colonoscopy, MRI, PET-CT, biopsy, CT of the chest or abdomen, angiography and ultrasound were recommended for further investigation.

Follow-up examinations

Recommended and performed follow-up examinations were documented by written or phone contacts with the subjects and/or with the appropriate departments in our hospital.

Separation of screening subjects and symptomatic subjects

A separation of screening and symptomatic subjects should facilitate the view of both groups.

Results

Subjects

Three hundred and seventy-five out of 380 subjects tolerated the comprehensive MRC examination well. Thus, the data of those patients were analyzed. In two patients a big part of the water enema was spilled on the scanner table. By request of the patients, the MRC examination was cancelled. In two other patients, the MRC examination was aborted due to claustrophobia, which firstly appeared immediately after the intravenous injection of the contrast agent. In these two subjects no allergic reaction was observed. In a fifth patient the MRC examination was cancelled because of minor allergic reactions (dyspnea; skin rash) after the i.v. administration of the contrast agent. An i.v. injection of 50 mg prednisolon (Solu-Decortin H 50) was given, eliminating the symptoms.

Data analysis and image quality

The mean time required for data analysis, report and demonstration of the MRC examination was 31 min (range 20–37 min). The assessment of the image quality of all MRC examinations showed a good diagnostic image quality with an average of 1.4 (range 1.0–1.8).

Colonic findings

In 318 (85%) of the 375 subjects, no relevant intra-colonic findings such as colorectal polyps, carcinomas, stenosis or inflammatory signs of the colonic wall were detected in MRC (36 subjects had colonic diverticulosis and 25 subjects sigmoid and colonic elongation; in 27 subjects the findings were already known). In the remaining 57 subjects (15%), relevant intra-colonic findings were observed. In 39 subjects 47 colorectal lesions in size groups ranging between 6 and 25 mm were detected (5 colorectal lesions were suspected to be malign). In 3 of the 39 subjects,

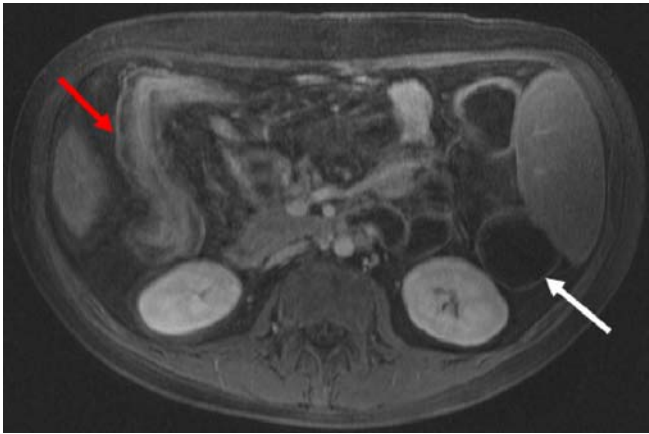

Fig. 1 Dark-lumen MRC of a 44-year-old male subject with known Crohn's disease. Axial T1-w 2D FLASH source image (TR/TE 125/1.8 ms; flip angle 70°) was acquired after i.v. application of contrast medium. Increased contrast uptake, thickness of the colonic wall and insufficiency of the colonic distension (ascending colon, red arrow) led to the diagnosis of acute inflammation of the colon. In the descending colon (bright arrow), no pathologic contrast uptake or bowel wall thickening is observed

the colorectal lesions were already known as polyps. In a further 13 subjects, signs of Crohn's disease and ulcerative colitis were detected based on wall thickness, loss of haustral folds and contrast agent uptake (Fig. 1).

In three subjects with known Crohn's disease and ulcerative colitis moderate stenosis of the colon was detected based on the narrowing of the colonic lumen (two stenoses in the transverse colon and one stenosis in the ascending colon). In one subject the moderate stenosis was

already known. In a further two patients with abdominal pain sigmoid diverticulitis was detected based on wall thickness and contrast agent uptake after i.v. administration of the contrast agent. In none of the patients were the findings known prior to the respective examinations. In all those 57 subjects, conventional colonoscopy was recommended.

Follow-up of intra-colonic findings

Based on the results of the MRC examinations, 41 subjects underwent conventional colonoscopy till the end of this study (31 subjects with colorectal lesions, 6 subjects with Crohn's disease and ulcerative colitis, 2 subjects with moderate colonic stenosis and 2 subjects with sigmoid diverticulitis). The remaining 16 subjects did not undergo CC till the end of this study. The minimum follow-up time after MRC was 1 week, the maximum 26 months (average 15.2 months). CC confirmed the colorectal lesions in the 31 subjects, and histopathology actually showed malignant signs in only 3 of the 5 subjects with suspected malignancy. In addition, CC detected 15 colorectal lesions smaller than 5 mm in diameter and 2 lesions sized 7 and 9 mm that were missed in MRC. All polypoid lesions were removed: the three subjects with colonic malignancy underwent surgery (end-to-end anastomosis).

Furthermore, CC confirmed the findings of MRC in the six subjects with Crohn's disease and ulcerative colitis and in the two subjects with moderate colonic stenosis. In the two subjects with sigmoid diverticulitis, CC confirmed the MRC findings, and the patients underwent surgery (end-to-

Table 1 Intra-colonic findings and the recommended follow-up examinations

	Intra-colonic findings	Number of subjects	Known findings	Unknown findings	Recommendation	Confirmation in CC	Performed measures
Therapeutically irrelevant findings	No colorectal pathology thereof	318	27	34			
	Colonic diverticulosis 36		16	20	Stool regulation		
	Colonic elongation 25		11	14	Fiber-rich nutrition		
Therapeutically relevant findings	Colorectal pathology thereof	57	4	53	CC		
	Colorectal lesions 39		3	36	31	31	Removed, 3 operated
	Crohn's and ulcerative colitis 13		0	13	6	6	Change of medication
	Moderate colonic stenosis 3		1	2	2	2	Change of medication
	Sigmoid diverticulitis 2		0	2	2	2	Operated
Sum		375			41		

Table 2 Segmentation of extra-colonic findings and recommended follow-up examinations

	Number of subjects	Known findings	Unknown findings	Therapeutic-irrelevant findings	Therapeutic-relevant findings	Recommendation
No extra-colonic findings	115 (31%)					
Extra-colonic findings	260 (69%)	140 subjects (54%)	120 subjects (46%)	229 subjects (88%) 465 findings (91%)	31 subjects (12%) 45 findings (9%)	Biopsy, MRI, CT, PET-CT, angiography,
Sum	375	260			510	

end anastomosis). All intra-colonic findings and the follow-up examinations are listed in Table 1.

Extra-colonic findings

The additional assessment of the MRC examination from the lung bases to the symphysis led to the detection of 510 extra-colonic findings in 260 (69%) of the 375 subjects. In the remaining 115 subjects (31%), no appreciable findings were detected. Of the 260 subjects, 140 subjects (54%) showed known extra-colonic findings and 120 subjects (46%) unknown findings. Regarding the therapeutic relevance of the findings in 229 (88%) of the 260 subjects, therapeutic-irrelevant findings (465 findings) were found, and in the remaining 31 subjects (12%), therapeutic-relevant findings (45 findings) were detected. All those 45 therapeutic-relevant findings had been unknown to the subjects prior to the examination. In 53 of the 229 subjects with therapeutic-irrelevant findings, follow-up examinations/treatments such as ultrasound (liver hemangioma) or physiotherapy (osteochondrosis) were recommended. In the 31 subjects with therapeutic-relevant findings, additional diagnostic procedures like biopsy, MRI of the abdomen, MRI of the spine, PET-CT, angiography, CT of the chest and abdomen for the explanation of those findings were recommended. All extra-colonic findings and the recommended additional procedures are listed in Table 2. These findings included, e.g., cysts (Fig. 2), a dissection of the pelvic artery (Fig. 3) or a malignant tumor (Fig. 4). All findings are listed in detail in Table 3. A separation of screening and symptomatic subjects is listed in Table 4.

Follow-up examination

Additional diagnostic procedures were performed in 27 (87%) of the 31 subjects with therapeutically relevant findings with an average time of 10 days (range, 3 to 21 days). Those procedures were: biopsy, n=10; MRI of the abdomen, n=6; MRI of the spine, n=3; CT of the abdomen, n=3; CT of the chest, n=3; angiography, n=1; PET-CT, n=1. These additional examinations confirmed

the suspected pathologic findings of MRC in all cases. The remaining four subjects did not receive any additional diagnostic procedure.

Discussion

The presented study underscores the usefulness of dark-lumen MR colonography not only for the assessment of the entire colon, but also for the evaluation of extra-colonic

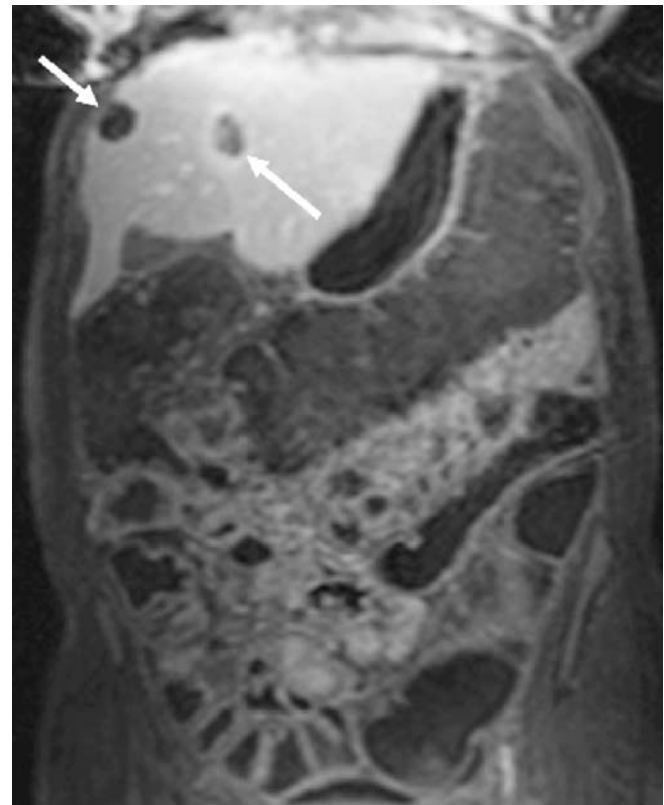


Fig. 2 Coronal T1-w 3D VIBE source image of dark-lumen MRC of a 60-year-old female subject (TR/TE 3.1/1.1 ms; flip angle 12°; matrix 168 × 256). The asymptomatic subject underwent MRC as a screening examination. MRC did not show any intra-colonic pathology. However, the assessment of the liver shows two hypointense lesions which were classified as liver cysts (arrows)

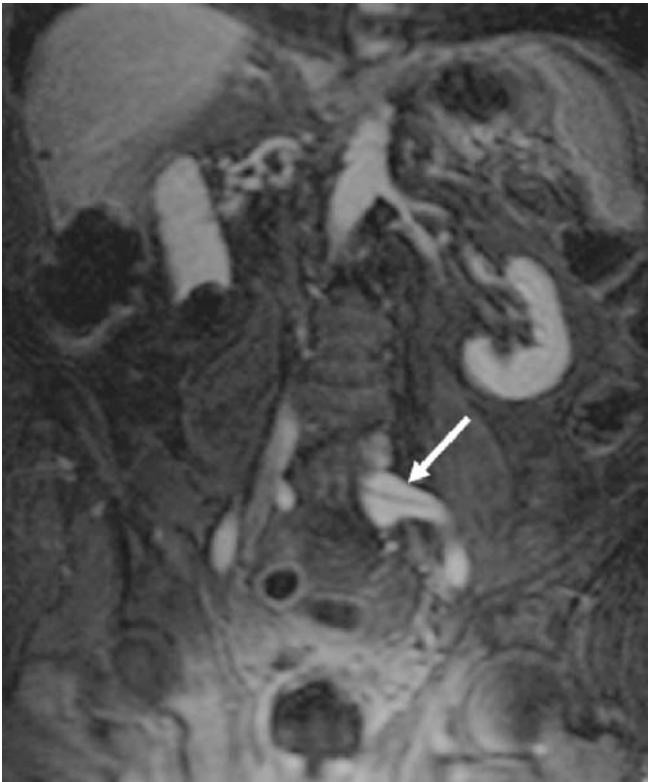


Fig. 3 Contrast-enhanced coronal 3-D VIBE sequence of a 57-year-old male patient who underwent MRC due to recurrent abdominal pain. MRC did not show colonic pathology. The assessment of the vessels showed a dissection of the left iliac artery (arrow) that was not known before

organs from the lung bases down to the symphysis in the same examination.

Fiber-optic colonoscopy performed by the gastroenterologist represents to date the gold-standard procedure for the inspection and assessment of the entire colon and the detection of its pathologies [1, 2]. The advantage of fiber-optic colonoscopy, i.e., the possibility to remove and/or biopsy colorectal pathologies, is overshadowed by its invasiveness. This leads to avoidance and fear of conventional colonoscopy in many patients. Despite its use as a gold standard, colonoscopy is not without limitations: the view of the endoscopist is limited to the colonic lumen; thus, possible extra-colonic findings cannot be assessed.

An abdominal disorder is a commonplace reason for gastroenterological consultation and is the most common symptom leading to conventional colonoscopy. However, abdominal disorders can have many causes: intestinal (bleeding, stenosis, etc.) and non-intestinal (biliary, urologic, gynecologic, etc), medical and surgical [22, 23]. Therefore, evaluation of the intestine and the extra-intestinal organs must be performed rapidly after assessment of the clinical history of the patient. Incidental findings of the extra-colonic organs are often detected with additional imaging techniques, which lead to additional

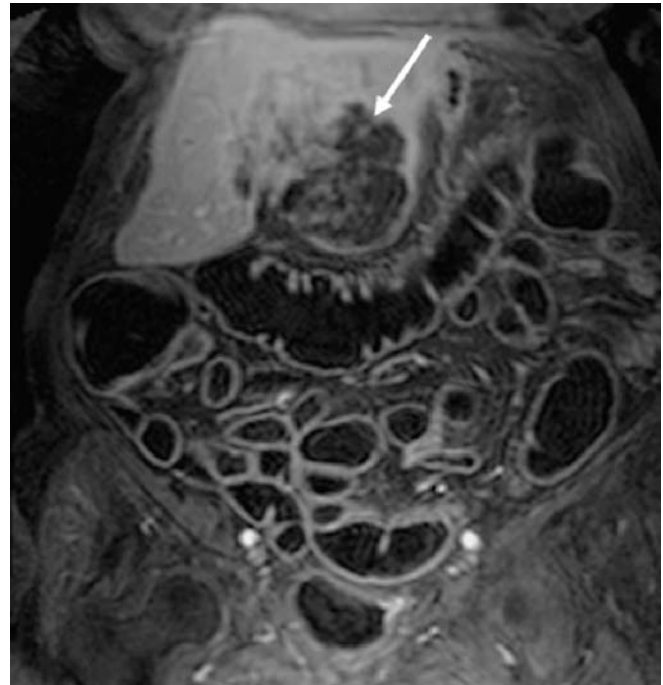


Fig. 4 Contrast-enhanced coronal 3D VIBE sequence of a 76-year-old female subject patient who underwent MRC due to abdominal pain and slight icterus. The MRC did not show any colonic pathology. However, in the left segment of the liver, a great hypointense lesion with stasis of the bile ducts was detected. The biopsy of this lesion confirmed the suspected diagnosis of cholangiocellular carcinoma

costs, waiting times and patient anxiety. In addition, incidental findings of extra-intestinal organs can influence the therapy, procedure and prognosis of the patients.

Patient discomfort, risk of perforation and other limitations of CC have motivated the evaluation of various alternative radiological imaging techniques to assess the entire colon [3, 4]. The continual and rapid development of computed tomography (CT) and magnetic resonance imaging (MRI), the development of new contrast agents as well as post-processing software paved the way for new imaging tools to assess the entire colon [6, 7, 11, 13]. The so-called virtual colonoscopy technique using CT (CT colonography) was first described by Vining et al. in 1994 and was presented as an alternative to conventional colonoscopy for the detection of colorectal pathologies [24]. In contrast to conventional colonoscopy, CT colonography includes the possibility to evaluate extra-colonic organs from the lung bases to the symphysis in the same examination.

Virtual colonography can dispose of most of the limitations of CC. So far, CT colonography has been the most frequently used examination tool for the assessment of the entire colon as an alternative to CC [6, 7, 24]. Many previous reports indicate a high sensitivity of CT colonography not only for the detection of colonic pathologies, but also for the detection of clinically relevant

Table 3 All extra-colonic findings including therapeutic-irrelevant and therapeutic relevant findings

Therapeutic-irrelevant findings	Number of subjects	Therapeutic-relevant findings	Number of subjects
Hepatic cysts	24	Hepatic metastases	5
Renal cysts	20	Hepatocellular carcinoma	2
Splenic cysts	10	Cholangiocellular carcinoma	1
Pancreatic cysts	6	Bone metastases	4
Ovarian cysts	10	Renal cell carcinoma	1
Hiatus hernia	5	Lung cancer	1
Upside-down stomach	1	Lung metastases	2
Hepatomegaly	13	Uterus carcinoma	2
Splenomegaly	7	Ovarian carcinoma	1
Atherosclerosis of the vessels	14	Prostat carcinoma	2
Doubled renal artery	5	Peritoneal carcinosis	1
Norm variant of mesenteric vessels	5	Infrarenal aortic aneurysma	3
Doubled inferior vena cava	3	Iliacal artery dissection	2
Kinking and elongation of the aorta	4	Focal cholangitis	2
Thrombosis of confluens venosum	2	Intrahepatic cholestasis	2
Retroaortal renal vein	4		
Atrophic kidney	3		
Horseshoe kidney	3		
Pelvic kidney	2		
Cystolithiasis	3		
Cholecystolithiasis	5		
Paramilt	7		
Hepatic hemangioma	7		
Splenic hemangioma	3		
Adenoma of suprarenal glands	4		
Mesenterial lymph nodes	9		
Menetrier disease	1		
Uterus myomatosis	10		
Prostate hypertrophy	7		
Minimal ascites	3		
Minimal pleural effusion	2		
Osteochondrosis	12		
Scoliosis of the spine	5		
Hemangioma of LWS	7		
Disk herniation	3		
Sum	229	Sum	31

The diagnosis of the unknown therapeutic-relevant findings was confirmed using additional diagnostic procedures. Just 4 of the 31 subjects did not receive additional diagnostic procedures (focal iliacal artery dissection, n=1; infrarenal aortic aneurysma with a diameter >4 cm, n=3).

extra-colonic pathologies [18–21]. In a study including 432 asymptomatic subjects, a total of 146 extra-colonic lesions were detected in 118 subjects (27.3%) [20]. In 32 of those 118 subjects, the extra-colonic findings were clinically relevant, and 9 subjects showed a clinical benefit from the detection of these findings within the monitored follow-up period [20]. In another study including 500 male

patients, Yee et al. found that 315 patients (63%) had extra-colonic findings that reached from benign renal cysts to renal cell carcinoma, and only 45 patients (9%) had clinically important findings [19]. Spreng et al. compared the importance of extra-colonic findings between i.v. contrast-enhanced and non-enhanced CT colonography [18]. A total of 303 extra-colonic findings were detected in

Table 4 Separation of the data of screening and symptomatic subjects

	Screening subjects (61)	Symptomatic subjects (319)	Sum
Complete MRC	61	314	375
Mean image quality	1.2	1.6	
Intra-colonic findings	7	50	57
Relevant findings	7	50	
No/irrelevant findings	54	264	
Known findings	0	3	
Unknown findings	7	47	
Extra-colonic findings	25	235	260
Relevant findings	4	27	
Irrelevant findings	21	208	
Known findings	11	129	
Unknown findings	4	106	

102 subjects. Of those, 71% were detected by means of i.v. contrast-enhanced CT colonography and 29% by non-enhanced CT colonography. In addition, extra-colonic findings led to further work-up or had an impact on therapy in 25% of the 102 subjects [18]. All these studies demonstrate the clinical relevance of the assessment of the extra-colonic organs and the importance of the injection of i.v. contrast agents [18–21].

In the early days of MR colonography, Luboldt et al. used a bright-lumen technique based on the rectal application of a gadolinium-water mixture in a concentration of 1:1,000 [25]. On T1-weighted data sets the paramagnetic contrast renders the colonic lumen bright. Hence, polypoid colonic masses appear as dark filling defects within the bright colonic lumen. This appearance may make the differentiation of polyps from residual fecal material and/or small pockets of air difficult. Furthermore, the technique requires data acquisition in both prone and supine patient positions to compensate for the presence of residual air [25, 26]. In another study, Luboldt et al. evaluated this bright-lumen MRC technique in 132 patients and reported a sensitivity rate of 93% for colorectal lesions >1 cm [27]. This study confirmed MRC to be quite reliable regarding the detection of colorectal lesions. However, the assessment of extra-colonic organs and possible pathologies was limited due to the absence of an i.v. contrast agent and the exact assessment of the extra-colonic organs.

A further progress of MRC based on a different contrast mechanism is the so-called dark-lumen MR colonography technique and was first described by Lauenstein et al. in 2001 [28]. This technique, which is only performed in the prone position, turned out to be more accurate and less time consuming compared to the bright-lumen technique [11]. Dark-lumen MRC is based on the acquisition of T1-

weighted 3D data sets following colonic distension with a water enema and the i.v. administration of paramagnetic contrast agents [13]. Thus, the colonic lumen is rendered dark due to the water enema [13]. However, the colonic wall and possible pathologies appear bright because of the high signal intensity of the bowel wall on the post-contrast data sets [13]. This form of direct visualization of the bowel wall and of all colorectal pathologies originating from it reduces the incidence of false-positive findings: residual stool or air bubbles, which might mimic small polyps in the bright-lumen technique, remain dark due to the lack of paramagnetic contrast agent uptake. In addition, dark-lumen MRC allows for a better evaluation of the extra-colonic organs due to the injected contrast agent [13]. Thus, possible incidental pathologies can be better visualized and identified. Furthermore, new dark-lumen MRC techniques without colonic cleansing to increase the patient's acceptance of MRC allow for a reliable assessment of extra-colonic organs [29, 30].

Our study has shown that a fraction of the subjects (57 subjects, 15%) had intra-colonic relevant findings like colorectal lesions or inflammatory signs, and the remaining subjects (318 subjects, 85%) did not have intra-colonic relevant findings excluding 36 subjects with colonic diverticulosis and 25 subjects with sigmoid and colonic elongation. However, our study confirmed that the majority of the 375 subjects had extra-colonic findings with a rate of 69% (260 subjects). One hundred forty subjects (54%) of those 260 subjects with extra-colonic findings had known findings and 120 subjects (46%) had unknown findings. Although most extra-colonic findings were therapeutically irrelevant (88% of the subjects), 31 subjects (12%) had therapeutically relevant findings (mainly tumors). Twenty-seven (87%) of those 31 subjects with therapeutically relevant findings underwent additional diagnostic imaging procedures; the results confirmed the findings in all cases. Thus, the suspicion of therapeutically relevant findings at dark-lumen MRC indicates a recommendation for further diagnostic procedures.

Clearly, MRC is not without limitations. First and foremost, an MRC examination is more expensive compared with other screening tools for colorectal diseases. In our hospital the cost of an MRC examination is approximately 400 Euros, that of a conventional colonoscopy 250 Euros, MRI of the abdomen approximately 400 Euros and a CT examination of the abdomen approximately 200 Euros. Thus, the performance of conventional colonoscopy will be effective when the reason for the abdominal disorders can be found using CC or CT. However, CC and other diagnostic imaging procedures cause more waiting time and costs than MRC. Dark-lumen MRC can assess the entire colon and extra-colonic organs in the same examination. Suspected findings can then be confirmed using CC and/or additional imaging techniques. In addition, we reported about a rather

heterogeneous patient cohort, including screening subjects that have less therapeutically relevant findings compared to symptomatic subjects. However, a separation of screening subjects from the remaining subjects is statistically not meaningful, and the comparison of both groups does not lead to any relevant information regarding the utility of MRC for the assessment of extra-colonic organs.

In conclusion, dark-lumen MRC has a high accuracy not only for the assessment of the entire colon, but also for the assessment of extra-colonic findings that might be unknown or clinically important and that possibly could influence further therapy and the prognosis of the patient. Thus, we can strongly recommend performing dark-lumen MRC as an alternative to CC.

References

- Liebermann DA, Smith FW (1991) Screening for colon malignancy with colonoscopy. *Am J Gastroenterol* 86:946–951
- Marshall JB, Barthel JS (1993) The frequency of total colonoscopy and terminal ileal intubation in the 1990s. *Gastrointest Endosc* 394:518–520
- Angtuaco TL, Banaad-Omiotek GD, Howden CW (2001) Differing attitudes toward virtual and conventional colonoscopy for colorectal cancer screening: surveys among primary care physicians and potential patients. *Am J Gastroenterol* 96:887–893
- Thomeer M, Bielen D, Vanbeckevoort D et al (2002) Patient acceptance for CT colonography: what is the real issue? *Eur Radiol* 12:1410–1415
- Laghi A, Iannaccone R, Carbone I et al (2003) Detection of colorectal lesions with virtual computed tomographic colonography. *Am J Surg* 183:124–131
- Laghi A, Iannaccone R, Carbone I et al (2002) Computed tomographic colonography (virtual colonoscopy): blinded prospective comparison with conventional colonoscopy for the detection of colorectal neoplasia. *Endoscopy* 34:441–446
- Johnson CD, MacCarty RL, Welch TJ et al (2004) Comparison of the relative sensitivity of CT colonography and double-contrast barium enema for screen detection of colorectal polyps. *Clin Gastroenterol Hepatol* 2:314–321
- So NM, Lam WW, Mann D, Leung KL, Metreweli C (2003) Feasibility study of using air as a contrast medium in MR colonography. *Clin Radiol* 58:555–559
- Saar B, Heverhagen JT, Obst T et al (2000) Magnetic resonance colonography and virtual magnetic resonance colonoscopy with the 1.0-T system: a feasibility study. *Invest Radiol* 35:521–526
- Lefere P, Gryspeerdt S, Baekelandt M, Dewyspelaere J, van Holsbeek B (2003) Diverticular disease in CT colonography. *Eur Radiol* 13:62–74
- Lauenstein TC, Herborn CU, Vogt FM et al (2001) Dark lumen MR-colonography: initial experience. *Rofo Fortschr Geb Rontgenstr Neuen Bildgeb Verfahr* 173:785–789
- Lauenstein TC, Goehde SC, Ruehm SG, Holtmann G, Debatin JF (2002) MR colonography with barium-based fecal tagging: initial clinical experience. *Radiology* 223:248–254
- Ajaj W, Pelster G, Treichel U et al (2003) Dark lumen magnetic resonance colonography: comparison with conventional colonoscopy for the detection of colorectal pathology. *Gut* 52:1738–1743
- Ajaj W, Lauenstein TC, Pelster G, Goehde SC, Debatin JF, Ruehm SG (2004) MR colonography: How does air compare to water for colonic distension. *JMRI* 19:216–221
- Schreyer AG, Furst A, Agha A et al (2004) Magnetic resonance imaging based colonography for diagnosis and assessment of diverticulosis and diverticulitis. *Int J Colorectal Dis* 19:474–480
- Ajaj WM, Lauenstein TC, Pelster G et al (2005) Magnetic resonance colonography for the detection of inflammatory diseases of the large bowel: quantifying the inflammatory activity. *Gut* 54:257–263
- Ajaj W, Ruehm SG, Lauenstein T et al (2005) Dark-lumen magnetic resonance colonography in patients with suspected sigmoid diverticulitis: a feasibility study. *Eur Radiol* 15:2316–2322
- Spreng A, Netzer P, Mattich J, Dinkel HP, Vock P, Hoppe H (2005) Importance of extracolonic findings at IV contrast medium-enhanced CT colonography versus those at non-enhanced CT colonography. *Eur Radiol* 15:2088–2095
- Yee J, Mumar NN, Godara S et al (2005) Extracolonic abnormalities discovered incidentally at CT colonography in a male population. *Radiology* 236:519–526
- Chin M, Mendelson R, Edwards J, Foster N, Forbes G (2005) Computed tomographic colonography: prevalence, nature, and clinical significance of extracolonic findings in a community screening program. *Am J Gastroenterol* 100:2771–2776
- Pickhardt PJ, Taylor AJ (2006) Extracolonic findings identified in asymptomatic adults at screening CT colonography. *AJR Am Roentgenol* 186:718–728
- Marincek B (2002) Nontraumatic abdominal emergencies: acute abdominal pain: diagnostic strategies. *Eur Radiol* 12:2136–2150
- Rosen MP, Siewert B, Sands DZ, Bromberg R, Edlow J, Raptopoulos V (2003) Value of abdominal CT in the emergency department for patients with abdominal pain. *Eur Radiol* 13:418–424
- Vining DJ, Gefland DW, Bechthold RE, Scharling ES, Grishaw EK, Shiffrin RY (1994) Technical feasibility of colon imaging with helical CT and virtual reality. *Am J Roentgenol* 162:104
- Luboldt W, Steiner P, Bauerfeind P, Pelkonen P, Debatin JF (1998) Detection of mass lesions with MR colonography: preliminary report. *Radiology* 207:59–65
- Luboldt W, Debatin JF (1998) Virtual endoscopic colonography based on 3D MRI. *Abdom Imaging* 23:568–572

-
27. Luboldt W, Bauerfeind P, Wildermuth S, Marincek B, Fried M, Debatin JF (2000) Colonic masses: detection with MR colonography. *Radiology* 216:383–388
 28. Lauenstein T, Holtmann G, Schoenfelder D, Bosk S, Ruehm SG, Debatin JF (2001) MR colonography without colonic cleansing: a new strategy to improve patient acceptance. *AJR Am J Roentgenol* 177:823–827
 29. Lauenstein TC (2006) MR colonography: current status. *Eur Radiol* 16:1519–1526
 30. Ajaj W, Lauenstein TC, Schneemann H et al (2005) Magnetic resonance colonography without bowel cleansing using oral and rectal stool softeners (fecal cracking)-a feasibility study. *Eur Radiol* 15:2079–2087