

Infliximab as a treatment option for patients with rheumatoid arthritis and primary biliary cirrhosis

Despoina Dimopoulou¹ · Theodoros Dimitroulas¹ · Evangelos Akriviadis¹ · Alexandros Garyfallos¹

Received: 29 July 2015 / Accepted: 17 September 2015 / Published online: 28 September 2015
© Springer-Verlag Berlin Heidelberg 2015

Abstract Rheumatoid arthritis (RA) is a chronic inflammatory systemic disease which commonly requires treatment with biologic agents targeting various inflammatory pathways. Tumor necrosis factor alpha is a proinflammatory cytokine which plays a pivotal role not only in the pathogenesis of RA but also in other autoimmune diseases such as primary biliary cirrhosis. The co-existence of more than one autoimmune disorder in the same individual is very challenging in the daily practice as therapy strategies applicable to one disease setting may cause clinical and/or biochemical relapse of the other clinical entity. As a result, treatment options able to control different diseases are highly desirable among rheumatologists and other specialties. In that respect, we present a case of a 61-year-old female patient with RA and concomitant primary biliary cirrhosis with poor clinical response to conventional disease-modifying drugs for RA. The introduction of tumor necrosis factor alpha antagonist infliximab led to significant clinical improvement of RA and to stabilization of liver function. In this case review study, we discuss aspects of pathophysiology of primary biliary cirrhosis associated with tumor necrosis alpha and we review the available data of similar published cases.

Keywords Rheumatoid arthritis · Primary biliary cirrhosis · TNF α inhibitors · Infliximab

Introduction

Primary biliary cirrhosis (PBC) is a chronic progressive liver disease which is histologically characterized by chronic non-suppurative destruction and progressive loss of intrahepatic small bile ducts, resulting in fibrosis and eventual cirrhosis. The typical serological feature of the disease is the presence of the antimitochondrial antibodies (AMA), detected at titers of 1/40 or greater [1, 2]. Autoimmune diseases—predominantly systemic sclerosis—are associated with PBC; however, autoimmune liver abnormalities may occur—to a much lesser extend—in patients with rheumatoid arthritis (RA) [1–8]. Both PBC and RA are considered immunologically mediated diseases in which the proinflammatory cytokine tumor necrosis factor alpha (TNF α) has demonstrated to play a prominent pathogenetic role [2, 9]. Infliximab is a chimeric monoclonal antibody against TNF α and has been established as a therapy for RA. We describe the effect of infliximab treatment in a patient suffering from RA and PBC.

We performed a search PubMed, Embase and Scopus up to July 2015 according to the published guidelines for narrative reviews [10]. A combination of MeSH/Thesaurus terms and free-text terms was employed, including “rheumatoid arthritis”, “primary biliary cirrhosis”, “tumor necrosis factor alpha inhibitors”, “infliximab” and “biologic agents”.

The patient consented to the publication of her case according to the declaration of Helsinki.

Case report

In January 2012, a 61-year-old woman was admitted to our hospital because of variceal hemorrhage. A diagnosis of RA was made 3 years earlier with insidious onset of

✉ Theodoros Dimitroulas
dimitroul@hotmail.com

¹ 4th Department of Internal Medicine, Hippokratio Hospital, Konstantinoupoleos 49, 54642 Thessaloniki, Greece

symmetrical inflammatory polyarthritis affecting mainly the small joints of the hands and the feet. Testing for rheumatoid factor was positive at 105 IU/L (normal values 0–20 IU/L), but anti-citrullinated protein antibodies were negative. At that stage, antinuclear antibodies were positive with titer 1/640. She did not report clinical features suggesting connective tissue disease such as sicca symptoms, Raynaud's, mouth ulcers or hair loss. X-rays of the hands and the feet revealed erosive changes compatible with RA and given the presence of acute phase response—erythrocyte sedimentation rate (ESR) at 50 mm/h and C-reactive protein (CRP) at 43 mg/L (normal values <5 mg/L)—she fulfilled not only the 1987 American College of Rheumatology ACR classification criteria [11], but also the 2010 classification criteria [12] for the diagnosis of RA. Treatment with hydroxychloroquine 200 mg twice daily and methylprednisolone 16 mg/day was begun. The steroid dose was tapered intermittently, but it could not be discontinued, because of recurrent relapses. Despite uncontrolled status of RA, the patient did not attend follow-up appointments with rheumatologists, and subsequently instead of the initiation of disease-modifying drugs, she managed her symptoms with non-steroid anti-inflammatory drugs on PRN basis. Her medical history was also notable for Hashimoto thyroiditis and osteoporosis.

At admission, she was on methylprednisolone 6 mg/day, hydroxychloroquine 200 mg twice/day, calcium and vitamin D supplements. Physical examination at that point showed active synovitis with swollen painful wrists, metacarpophalangeal and proximal interphalangeal joints alongside with elevated ESR at 65 and CRP at 40 mg/dL, translated into Disease Activity Score 28 (DAS28) of 5.8. There were no clinical signs of chronic liver disease such as ascites or lower leg edema. She did not abuse alcohol.

Laboratory data on admission showed anemia (Hb = 11 mg/dL), thrombocytopenia (PLT = 73000/mm³), elevated alkaline phosphatase (ALP) at 440 U/L (normal values 0–279 U/L) and γ -glutamyltransferase (GGT) at 240 U/L (normal values 0–35 U/L). No other liver function abnormalities were noticed. Serological evaluation for hepatitis B and C was negative. Immune serology revealed antinuclear antibody titers of 1/2500, positive rheumatoid factor and negative anti-citrullinated protein antibodies as in previous investigations, antimitochondrial antibodies (AMA) positive at 72 U/L (normal <3 U/mL) as well as anti-centromere antibodies positivity. Extractable nuclear antigen screen was negative. Serum immunoglobulin (IgA, IgG, IgM) and electrophoresis were normal too. Magnetic resonance cholangiopancreatography and ultrasonography did not show biliary tract abnormalities. A liver biopsy was performed and showed expansion of most of the portal tracts with an inflammatory infiltrate consisting primary of plasma cells. There was granulomatous destruction of

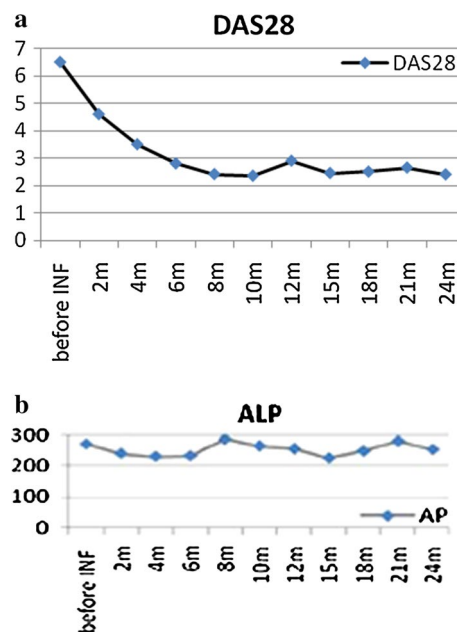


Fig. 1 Changes of disease activity score (DAS28) and stabilization of ALP over treatment with infliximab. **a** DAS28, **b** alkaline phosphatase (ALP)

the bile ducts and bile duct proliferation. Fibrous septa and bridging necrosis were also present. These findings were consistent with PBC stage III according to the Ludwig's classification [13]. On the basis of the histological features, the presence of AMA and the cholestatic biochemical pattern, patient was diagnosed with PBC [1, 14]. Treatment with ursodeoxycholic acid 13 mg/kg/day was started. Immunosuppressive therapy for RA was methylprednisolone 8 mg/day and azathioprine 100 mg/day, while hydroxychloroquine was discontinued. After a year, liver function was improved, but arthritis remained poorly controlled. Despite replacement of azathioprine by methotrexate 12.5 mg per week, RA disease activity remained high with DAS28 at 6.2 with considerable fluctuation of ALP (Fig. 1b). The escalation of immunosuppressive treatment with infliximab 3 mg/kg (at weeks 0.2 and 6 and then every 8 weeks) led to considerable RA improvement on both clinical and biochemical grounds within 4 months (Fig. 1a) without any further deterioration of ALP levels (Fig. 1b). After 24 months on infliximab, patient has managed to come off oral steroids as RA remains clinically quiescent and liver function has been stabilized.

Discussion

We describe a rare case of patient suffering with RA and PBC in whom the administration of infliximab resulted in RA remission as well as the maintenance of liver function.

The likelihood of these uncommon conditions occurring in the same patient is very rare and unusual [15]; however, the awareness of this combination is important in the daily clinical practice and rheumatologists should investigate the possibility of PBC in patients with sustained liver abnormalities after ruling out other causes such as anti-rheumatic drug-induced hepatotoxicity, hepatitis or other liver pathology [16]. The presence of positive ANA and anti-centromere antibodies at the time of the diagnosis of PBC raised the possibility of connective tissue disease or overlap syndrome, but our patient had no clinical signs such as Raynauds', sclerodactyly, telangiectasia, skin rash or muscle weakness to point towards a clinical diagnosis of other autoimmune disease; however, a high index of suspicion remains in case she manifests such symptoms in the future.

While TNF alpha inhibitors are a well established and efficacious treatment option for RA, the experience of using such regimens when inflammatory arthritis coexists with PBC is very limited and the available data—particularly for infliximab—is inconclusive. Spadaro et al. [17] reported poor clinical response of arthritis and persistence of liver function test abnormalities during infliximab therapy which returned to normality after switch to etanercept. Similarly, etanercept led to adequate control of RA and PBC in another published case [18]. It is worth noting that reversible cholestatic liver disease has been noticed in a few patients receiving infliximab with various autoimmune disorders [19, 20]. Finally, successful treatment of RA/limited systemic sclerosis overlap syndrome with concomitant PBC achieved by administration of interleukin-6 inhibitor tocilizumab has also been reported [21].

Considering this data, we acknowledge that someone can argue against the choice of infliximab as first-line treatment for our patient. Our decision was based on a number of reasons including individuals' willingness to receive intravenous therapy which was in accordance with doctors' advice to ensure compliance with treatment, diligent surveillance and close observation of biochemical parameters. This is in line with RIVIERA study which has highlighted that personal attitudes play an important role in patients' decision and preference regarding the way of administration of TNFa inhibitors [22]. In addition, our department is a tertiary referral center for north Greece and our patient is resident of a remote village where regular follow-up by rheumatologists or even general practitioners as well as biologic drugs prescription and supply are problematic.

The pathogenic role of TNFa in PBC remains unclear. Allelic variations of TNFa and of cytotoxic T-lymphocyte antigen-4 (CTLA-4), a key regulator of the adaptive immune system, have been repeatedly associated with susceptibility to different autoimmune diseases and

were also associated with PBC [23–28]. Poupon et al. confirmed a potential role of TNFa and CTLA-4 variants in the pathogenesis of PBC. A strong association of the allelic variant TNFa rs 1799724(C/T) with disease progression was shown [29]. In a previous study, Neuman et al. [30] measured the baseline levels of TNFa in 90 PBC patients and found that they were significantly higher than these of normal volunteers ($p < 0.001$). Baseline level of TNFa was also significantly higher in patients with advanced disease (stage III/IV) than in patients with early disease (stage I/II). More importantly TNFa levels were weakly associated with ALP, and improvement of ALP levels in patients treated with ursodeoxycholic acid for 2 years was paralleled by a statistically significant drop in TNFa levels [30].

An alternative explanation for the beneficial effects of infliximab on liver disease may be the potential pathogenic role of TNFa on biliary epithelial cell loss and apoptosis. Liang et al. [31] most recently measured the plasma concentrations of TNF-related apoptosis-inducing ligand [sTRAIL] and TNFa and found that both of them were significantly elevated in PBC patients compared to healthy controls. In the same study, in PBC patients the expression of TRAIL was closely associated with AP and GGT, the two important biochemical markers of cholestasis. The possible mechanism of this is that bile acids could induce expression of TRAIL-R2/DR5 in liver cells and biliary epithelial cells, rendering them susceptible to TRAIL-induced apoptosis [31, 32]. Higher levels of TNFa may also mediate liver fibrogenesis by increasing production of transforming growth factor b. Such pathogenetic pathways may represent another potential mechanism through which TNFa promotes liver injury in PBC and partially explain the stabilization and improvement of liver function in subject suffering from the disease.

On the other hand, the discrepancies observed between our case and previous ones regarding the effect of infliximab on liver function may be associated with individual differences and particularly genetic background as genetics factors have an impact on PBC pathogenesis that is stronger than that in almost any other autoimmune disease [33, 34]. We should bear in mind that clinical outcome to TNFa inhibitors is variable even between individuals with inflammatory arthritides, and there are no defined criteria or predictors for clinical response and/or therapeutic failure.

In conclusion, this single case report suggests that infliximab, which has been established as a therapy for RA, is well tolerated in the treatment of RA associated with PBC. However, more clinical experience is needed to confirm the tolerability and even efficacy of this therapeutic regimen in PBC.

Compliance with ethical standards

Conflict of interest The authors declare that they have no conflict of interest.

References

- Reshetnyak VI (2015) Primary biliary cirrhosis: clinical and laboratory criteria for its diagnosis. *World J Gastroenterol* 21:7683–7708
- Purohit T, Cappell M (2015) Primary biliary cirrhosis: pathophysiology, clinical presentation and therapy. *World J Gastroenterol* 7:926–941
- Selmi C, Meroni PL, Gershwin ME (2012) Primary biliary cirrhosis and Sjögren's syndrome: autoimmune epithelitis. *J Autoimmun* 39:34–42
- Kishor S, Turner ML, Borg BB, Kleiner DE, Cowen EW (2008) Cutaneous sarcoidosis and primary biliary cirrhosis: a chance association or related diseases? *J Am Acad Dermatol* 58:326–335
- Caramella C, Avouac J, Sogni P et al (2007) Association between rheumatoid arthritis and primary biliary cirrhosis. *Joint Bone Spine* 74:279–281
- Siegel JL, Luthra H, Donlinger J et al (2003) Association of primary biliary cirrhosis and rheumatoid arthritis. *Clin Rheumatol* 9:340–343
- Gao Jun, Qiao Liang, Wang Bingyuan (2015) Primary biliary cirrhosis is a generalized autoimmune epithelitis. *Int J Mol Sci* 16:6432–6446
- Shizuma T (2015) Clinical characteristics of concomitant systemic lupus erythematosus and primary biliary cirrhosis: a literature review. *J Immunol Res* 2015:713728
- Hohenester S, Oude-Elferink R (2009) Primary biliary cirrhosis. *Semin Immunopathol* 31:283–307
- Gasparyan AY, Aivazyan L, Blackmore H, Kitis GD (2013) Writing a narrative biomedical review: considerations for authors, peer reviewers, and editors. *Rheumatol Int* 31:1409–1417
- Aletaha D, Neogi T, Silman A et al (2010) 2010 rheumatoid arthritis classification criteria: an American College of Rheumatology/European League Against Rheumatism collaborative initiative. *Ann Rheum Dis* 69:1580–1588
- Aletaha D, Neogi T, Silman AJ et al (2010) 2010 rheumatoid arthritis classification criteria: an American College of Rheumatology/European League Against Rheumatism collaborative initiative. *Arthritis Rheum* 62:2569–2581
- Ludwig J, Dickson ER, McDonald GS (1978) Staging of chronic nonsuppurative destructive cholangitis (syndrome of primary biliary cirrhosis). *Virchows Arch A Pathol Anat Histol* 379:103–112
- Kaplan MM, Gershwin M (2005) Primary biliary cirrhosis. *N Engl J Med* 353:1261–1273
- Siegel JL, Luthra H, Donlinger J, Angulo P, Lindor K (2003) Association of primary biliary cirrhosis and rheumatoid arthritis. *J Clin Rheumatol* 9:340–343
- Smyk DS, Bogdanos DP, Mytilinaiou MG, Burroughs AK, Rigopoulou EI (2012) Rheumatoid arthritis and primary biliary cirrhosis: cause, consequence, or coincidence? *Arthritis* 2012:391567
- Spadaro A, Scrivo Riccieri V, Valesini G (2008) Effect of tumor necrosis factor alpha antagonists in a patient with rheumatoid arthritis and primary biliary cirrhosis. *Joint Bone Spine* 75:87–89
- Ogata A, Terabe F, Nakanishi K et al (2009) Etanercept improved primary biliary cirrhosis associated with rheumatoid arthritis. *Lett Ed Joint Bone Spine* 76:105–107
- Tobon GJ, Cañas C, Jaller JJ et al (2007) Serious liver disease induced by infliximab. *Clin Rheumatol* 26:578–581
- Menghini VV, Arora AS (2001) Infliximab-associated reversible cholestatic liver disease. *Mayo Clin Proc* 76:84e6
- Saito E, Sato S, Nogi S et al (2014) A case of rheumatoid arthritis and limited systemic sclerosis overlap successfully treated with tocilizumab for arthritis and concomitant generalized lymphadenopathy and primary biliary cirrhosis. *Case Rep Rheumatol* 2014:386328
- Scarpato S, Antivalle M, Favalli EG et al (2010) Patient preferences in the choice of anti-TNF therapies in rheumatoid arthritis. Results from a questionnaire survey (RIVIERA study). *Rheumatology* 49:289–294
- Agarwal K, Jones DE, Daly AK et al (2000) CTLA-4 gene polymorphism confers susceptibility to primary biliary cirrhosis. *J Hepatol* 32:538–541
- Ueda H, Howson JM, Esposito L et al (2003) Association of the T-cell regulatory gene CTLA4 with susceptibility to autoimmune disease. *Nature* 423:506–511
- Chistiakov DA, Turakulov RI (2003) CTLA-4 and its role in autoimmune thyroid disease. *J Mol Endocrinol* 31:21–36
- Krishnan S, Chowdhury B, Tsokos GC (2006) Autoimmunity in systemic lupus erythematosus: integrating genes and biology. *Semin Immunol* 18:230–243
- Jones DE, Donaldson PT (2003) Genetic factors in the pathogenesis of primary biliary cirrhosis. *Clin Liver Dis* 7:841–864
- Selmi C, Invernizzi P, Zuin M et al (2005) Genes and (auto) immunity in primary biliary cirrhosis. *Genes Immun* 6:543–556
- Poupon R, Ping C, Chrétien Y et al (2008) Genetic factors of susceptibility and of severity in primary biliary cirrhosis. *J Hepatol* 49:1038–1045
- Neuman M, Angulo P, Malkiewicz I et al (2002) Tumor necrosis factor- α and transforming growth factor- β reflect severity of liver damage in primary biliary cirrhosis. *J Gastroenterol Hepatol* 17:196–202
- Liang Y, Yang Z, Li C et al (2008) Characterisation of TNF-related apoptosis-inducing ligand in peripheral blood in patients with primary biliary cirrhosis. *Clin Exp Med* 8:1–7
- Higuchi H, Grambihler A, Canbay A et al (2004) Bile acids upregulate death receptor 5/TRAIL-receptor 2 expression via a c-N-terminal kinase-dependent pathway involving Sp1. *J Biol Chem* 279:51–60
- Rieger R, Gershwin ME (2007) The X and why of xenobiotics in primary biliary cirrhosis. *J Autoimmun* 28:76–84
- Invernizzi P, Gershwin ME (2008) The genetic basis of primary biliary cirrhosis: premises, not promises. *Gastroenterology* 135:1044–1104