

Persistent primitive olfactory artery connected with middle cerebral artery: case report

Myoung Soo Kim

Received: 17 March 2013 / Accepted: 3 June 2013 / Published online: 15 June 2013
© The Author(s) 2013. This article is published with open access at Springerlink.com

Abstract A persistent primitive olfactory artery (PPOA) is an extremely rare variation of the proximal anterior cerebral artery (ACA). The PPOA is connected to the distal ACA, ethmoidal artery, or both. I describe one patient with a PPOA connected to the middle cerebral artery (MCA). I analyzed the radiological characteristics of this anomalous vessel in this patient, who presented with headache. Computed tomography–angiography revealed an abnormal vessel in the patient, which originated from the distal ACA and ran anteromedially along the olfactory tract; it then made an abrupt turn and became the MCA. A PPOA connected to the MCA has been described in only two patients, including my own, in the English-language literature.

Keywords Anatomy · Olfactory artery · Persistent · Primitive

Introduction

Persistent primitive olfactory artery (PPOA) is extremely rare. The PPOA variant 1 originates at the terminal portion of the internal carotid artery (ICA) and runs anteriorly along the olfactory tract toward the crista galli. The distal portion of the PPOA makes an acute angle to the distal anterior cerebral artery (ACA) and supplies the normal ACA territory [6]. Whereas PPOA variant 1 involves the

ACA, variant 2 passes through the cribriform plate to supply the nasal cavity as the ethmoidal artery. The PPOA variant 2 does not involve the ACA. The PPOA is classified into these two variant forms according to its vascular territory [6]. Horie's group [2] reported another variant of PPOA that constitutes a transitional type between variants 1 and 2 that partially involves the ACA.

I experienced a patient with a PPOA connected to the distal middle cerebral artery (MCA). This type of PPOA has been reported in only one other patient [8]. Here, I describe the computed tomography (CT)–angiographic findings for this type of PPOA.

Case report

A 78-year-old woman presented with headache. CT–angiography revealed a right PPOA. The vessel originated from the right distal A1, ran along the right olfactory tract toward the olfactory bulb, and made an abrupt posterior turn, ultimately becoming the distal MCA. In this patient, I identified the normal A1 and a short anterior communicating artery (Fig. 1). Her headache was relieved with medication.

Discussion

PPOA is extremely rare. Nozaki's group [6] classified these arteries into two variants and provided an explanation of the embryological development of PPOA. Horie's group [2] reported PPOA variant 3, which is a transitional type between variants 1 and 2. I encountered yet another variant of PPOA, so I reviewed the literature and analyzed the radiological characteristics of PPOA.

M. S. Kim (✉)
Department of Neurosurgery, Seoul Paik Hospital,
Inje University College of Medicine, 85 Jeo-dong 2-ga,
Jung-gu, Seoul 100-032, Korea
e-mail: hanibalkms@hanmail.net

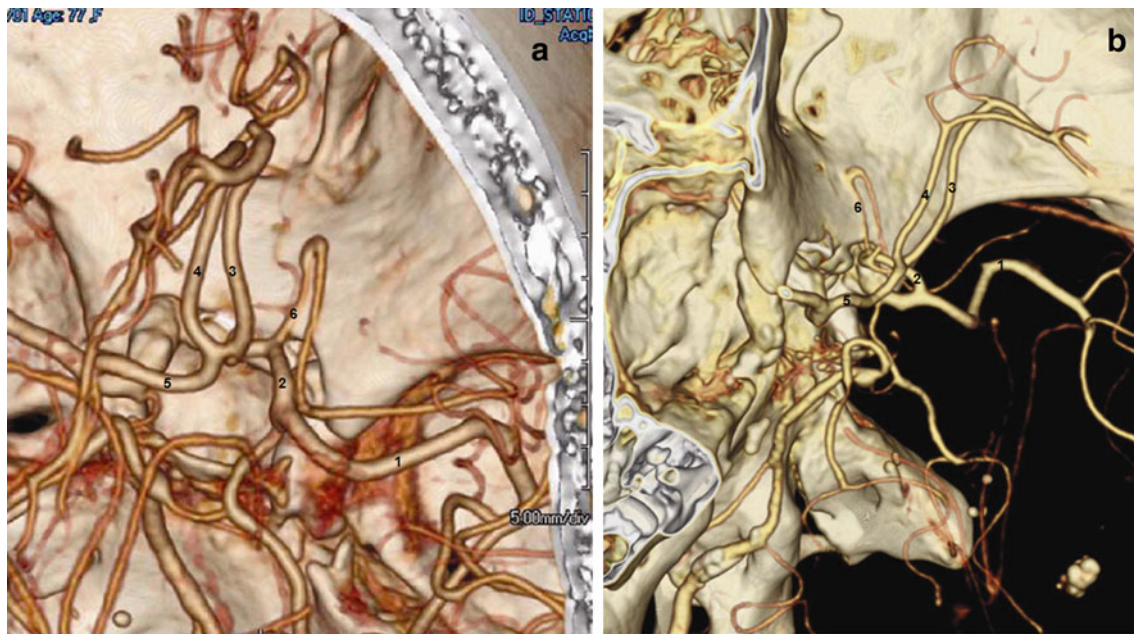


Fig. 1 Computed tomography–angiography reveals a right persistent primitive olfactory artery. This vessel is originated from the right distal anterior cerebral artery (ACA), runs in an anterior direction along the olfactory tract, and makes an abrupt posterior turn. It then becomes the distal middle cerebral artery. 1 identify a short anterior

communicating artery and a normal right proximal ACA (a). The anomalous vessel contacts the anterior cranial fossa (b). 1 Right middle cerebral artery, 2 right A1, 3 right A2, 4 left A2, 5 left A1, 6 persistent primitive olfactory artery

In PPOA variant 1, the anomalous artery arises from the ICA, runs along the olfactory tract, and makes a hairpin turn to supply the distal ACA territory. The normal A1 is absent. A long or absent anterior communicating artery is observed because of the large distance between the contralateral A1 and the PPOA. However, one patient reported to have PPOA variant 1 had a normal A1 and a normal anterior communicating artery [4].

In PPOA variant 2, the artery arises from the normal A1 and passes through the cribriform plate to supply the nasal cavity as the ethmoidal artery. Three cases of PPOA variant 2 have been reported, in all of whom a normal A1 was present [1, 5, 7].

Horie's group [2] reported PPOA variant 3, which is a transitional type between variants 1 and 2. The anomalous artery of PPOA variant 3 has two branches: the superior branch forming the callosomarginal branch of the ACA, and the anterior branch extending toward the cribriform plate, with an anastomosis with the ethmoidal artery.

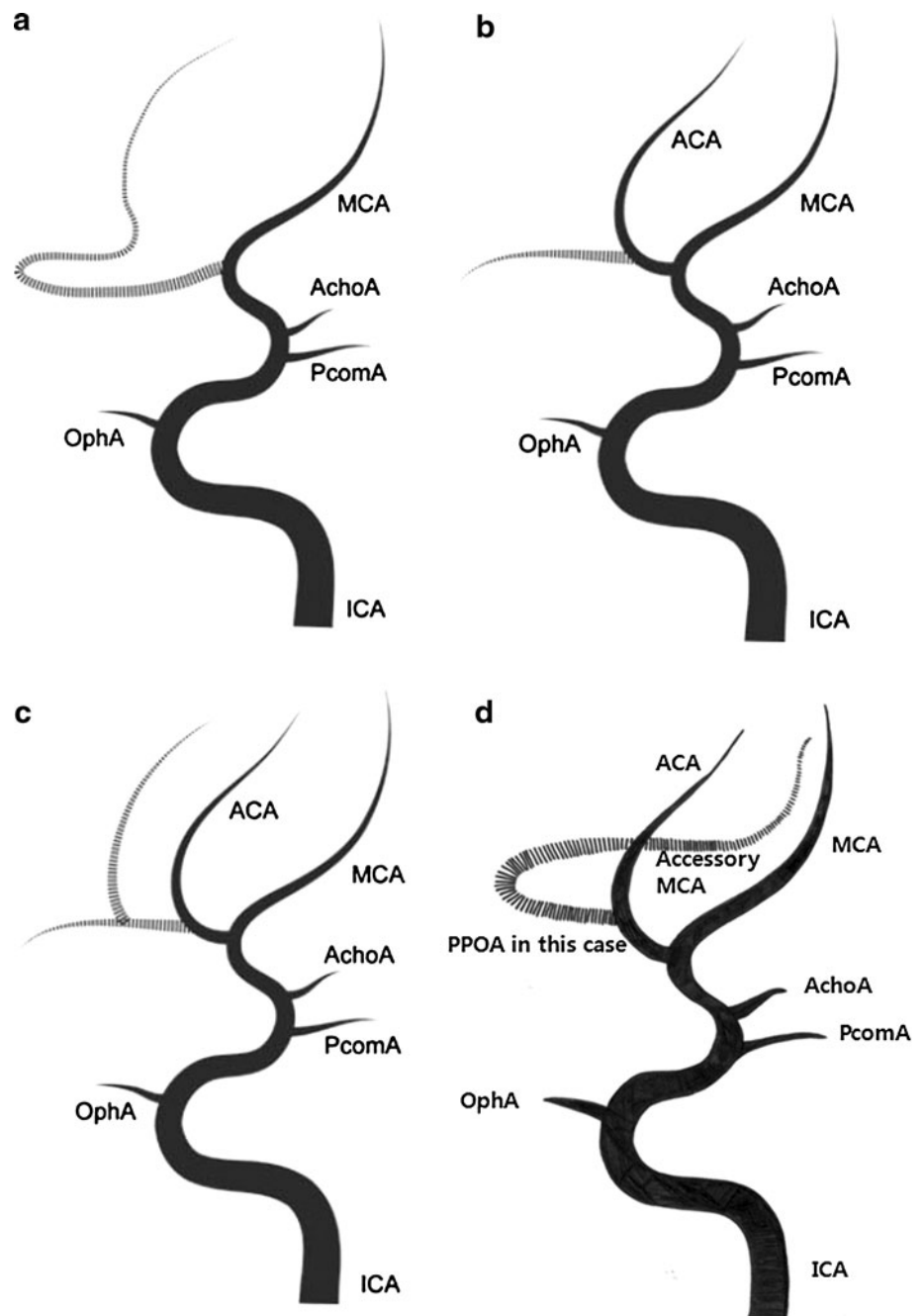
The type of PPOA observed in my patient had some interesting characteristics. The patient had a normal A1, from which the PPOA originated before running along the olfactory tract. The distal portion of the PPOA then made an abrupt acute angle and ran into the Sylvian fissure. This PPOA supplied the distal MCA territory. This variant is very similar to case 5 in Uchino's group [8] who described

14 cases of PPOA after a retrospective review of 3,626 magnetic resonance angiographies.

Embryologically, the primitive olfactory artery (POA) is the rostral division of the primitive ICA [3]. The POA terminates in the nasal fossa and the secondary artery constitutes the medial olfactory artery, which supplies the olfactory bulb. The medial olfactory artery becomes the ACA proper, whereas the terminal portion of the POA usually regresses. Lateral olfactory branches of the POA include the recurrent artery of the Heubner, anterior choroidal artery, lateral striate artery, and later MCA. Recurrent artery of Heubner is not the remnant of the POA. When the POA maintains its embryological course along the olfactory tract, it is called a 'PPOA'. The most important point in the definition of PPOA is the embryological course of the anomalous artery along the olfactory tract [3]. The PPOA vessel can be divided into four variants, according to the distal vascular territories it serves. Variant 1 supplies the distal ACA territory, variant 2 forms an anastomosis with the ethmoidal artery, and variant 3 connects with the callosomarginal and ethmoidal arteries. The new variant seen in my patient supplies the MCA territory, as an accessory MCA (Fig. 2).

Aneurysm is rarely seen at the hairpin turn of the PPOA, probably because of hemodynamic stress [8]. A follow-up study is required in patients with PPOA to determine the risk of an aneurysm at the hairpin turn of the PPOA, especially in young patients.

Fig. 2 Drawings of the four variants of persistent primitive olfactory artery (PPOA). PPOA variant 1 connects with the distal anterior cerebral artery (a); variant 2 makes an anastomosis with the ethmoidal artery (b); variant 3 supplies the callosomarginal and ethmoidal arteries (c); and the new variant observed in my patient connects to the accessory middle cerebral artery (MCA) (d). *AchoA* anterior choroidal artery, *PcomA* posterior communicating artery, *ICA* internal carotid artery, *ACA* anterior cerebral artery, *OphA* ophthalmic artery. Reproduced with permission from [2]



Acknowledgments This work was supported by research grant from an Inje University College of Medicine.

Conflict of interest The author declares no conflict of interest.

Open Access This article is distributed under the terms of the Creative Commons Attribution License which permits any use, distribution, and reproduction in any medium, provided the original author(s) and the source are credited.

References

1. Enomoto H, Goto H, Murase M (1986) A ruptured cerebral aneurysm of the fronto-orbital artery and a coexisting anastomosis with the anterior ethmoidal artery—a case report. *No Shinkei Geka* 14:203–206
2. Horie N, Morikawa M, Fukuda S, Hayashi K, Suyama K, Nagata I (2012) New variant of persistent primitive olfactory artery associated with a ruptured aneurysm. *J Neurosurg* 117:26–28
3. Komiyama M (2012) Persistent primitive olfactory artery. *Surg Radiol Anat* 34:97–98
4. Lin WC, Hsu SW, Kuo YL, Feekes JA, Wang HC (2009) Combination of olfactory course anterior cerebral artery and accessory middle cerebral artery (MCA) with occluded in situ MCA and related moyamoya phenomenon. *Brain Dev* 31: 318–321
5. Moffat DB (1967) A case of persistence of the primitive olfactory artery. *Anat Anz* 121:477–479

6. Nozaki K, Taki W, Kawakami O, Hashimoto N (1998) Cerebral aneurysm associated with persistent primitive olfactory artery aneurysm. *Acta Neurochir (Wien)* 140:397–401
7. Tsutsumi S, Shimizu Y, Nonaka Y, Abe Y, Yasumoto Y, Ito M, Oishi H (2009) Arteriovenous fistula arising from the persistent primitive olfactory artery with dual supply from the bilateral anterior ethmoidal arteries. *Neurol Med Chir (Tokyo)* 49:407–409
8. Uchino A, Saito N, Kozawa E, Mizukoshi W, Inoue K (2011) Persistent primitive olfactory artery: MR angiographic diagnosis. *Surg Radiol Anat* 33:197–201