

## Extensor carpi radialis brevis origin, nerve supply and its role in lateral epicondylitis

Soubhagya R. Nayak · Lakshmi Ramanathan · Ashwin Krishnamurthy ·  
Latha V. Prabhu · Sampath Madhyastha · Bhagath Kumar Potu ·  
Anu Vinod Ranade

Received: 16 February 2009 / Accepted: 27 May 2009 / Published online: 25 June 2009  
© Springer-Verlag 2009

**Abstract** Lateral epicondylitis (LE) or tennis elbow has been the subject of concern during the last 60 years, but the pathogenesis of the LE remains unclear. The LE can be due to the tendinogenic, articular or neurogenic reasons. Numerous theories have been put forth in the recent past, out of which one of the most popular theories is that the condition results from repeated contraction of the wrist extensor muscles, especially the extensor carpi radialis brevis (ECRB) which may compress the posterior branch of the radial nerve (PBRN) at the elbow during pronation. We studied 72 upper limbs (36 formalin-fixed cadaver) for the origin, nerve supply and the course of PBRN in relation to the ECRB as one of the goal for the present study. The possible presence of an arch of the ECRB around the PBRN was also observed and recorded. The nerve to ECRB was a

branch from the radial nerve in 11 cases (15.2%); from the PBRN in 36 cases (50%) and from the superficial branch of the radial nerve in 25 cases (34.7%), respectively. The ECRB had a tendinous arch in 21 cases (29.1%); a muscular arch in 8 (11.1%) cases and the arch was absent in 43 cases (59.7%). When the ECRB had a tendinous or muscular arch around the PBRN, it may compress the same and this condition may worsen during the repeated supination and pronation as observed in tennis and cricket players. The presence of such tendinous or muscular arch should be considered by orthopedicians and neurosurgeons, while releasing the PBRN during LE surgery.

**Keywords** Lateral epicondylitis · Tennis elbow · Extensor carpi radialis brevis · Posterior branch of radial nerve

---

S. R. Nayak (✉) · A. Krishnamurthy · L. V. Prabhu ·  
S. Madhyastha  
Department of Anatomy, Centre for Basic Sciences,  
Kasturba Medical College, Manipal University, Bejai,  
Mangalore 575004, Karnataka, India  
e-mail: ranjanbhatana@gmail.com

L. Ramanathan  
Department of Anatomy, Chettinad Hospital  
and Research Institute, Rajiv Gandhi Salai,  
Kanchipuram Dist, Kelambakkam 603103, TamilNadu, India

B. K. Potu  
Department of Anatomy, Centre for Basic Sciences,  
Kasturba Medical College, Manipal University,  
Manipal, Karnataka, India

A. V. Ranade  
Department of Anatomy, Gulf Medical University,  
P.O Box 4184, Ajman, United Arab Emirates

### Introduction

Lateral epicondylitis (LE) is a painful condition affecting the common extensor origin at the lateral humeral epicondyle. A plethora of terms has been used to describe lateral epicondylitis including tennis elbow, epicondylitis, tendinitis, tendinosis and tendinopathy [25]. Typically, LE is seen in people who are required to do repetitive gripping activities, such as tennis players, carpenters, gardeners, abattoir workers, cricket player and so on. The condition is characterized by tenderness or pain at the lateral epicondyle of humerus and pain and weakness with gripping activities. The cause of the condition is not fully understood. It appears that the amount of the force required to grip a small object (compared with a larger object that fits comfortably in to the hand) over sustained periods or with repetitive activity may contribute to the condition. There is some

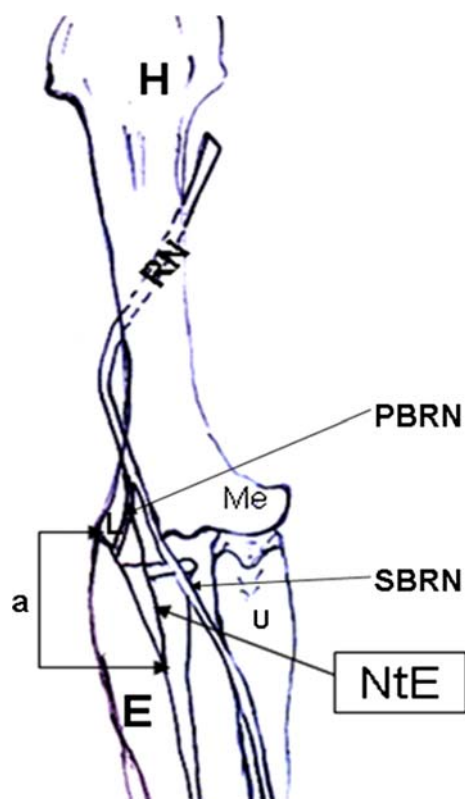
(largely anecdotal) evidence to suggest that the width of the equipment handle may affect the biomechanical pull of the forearm extensor muscles on the lateral epicondyle at the elbow. The compression of RN or PBRN is described as a neurogenic cause for the LE [10, 22, 26, 27], as the above nerves supplies the extensor muscles of the hand. Smola [23] termed LE is nothing else, but the radial tunnel syndrome (compression of RN or PBRN in the radial tunnel). The RN and PBRN mostly compressed in the forearm, at the arcade of Frohse [5, 7, 8, 18], at the dorsal edge of the supinator muscle [6]. The edge or the superomedial margin of the extensor carpi radialis brevis muscle (ECRB) may compress the PBRN before its entry to the supinator muscle [12, 19, 21, 22, 24]. Witthaut and Steffens [29] published a case report, in which they claimed PBRN entrapment under the tendinous margin of the ECRB is possible. The above fact is under estimated by the surgeons and clinicians while dealing with LE. In the present study, we observed the origin of the ECRB and its nerve supply with special attention to the presence of fibrous or tendinous arches in the superomedial aspect of elbow region.

## Materials and methods

This study was performed on 72 upper extremities of the 36 formalin-fixed human cadavers used for the routine dissection course in the Anatomy Department of the Kasturba Medical College, Manipal University, Mangalore, India during 2005–2008 Academic Sessions. All the cadavers were from the southern coastal region of Indian. The mean age of cadavers was 56 years (range 39–76 years). There were no pathological findings in the dissection region of the upper extremities. All the upper extremities were carefully dissected. The skin, superficial fascia and the antebrachial fascia from the distal part of the arm and proximal part of the forearm were excised. The RN and its two terminal branches, the origin of ECRB and its nerve supply were recorded. Specific attention was given for the possible presence of an arch (addition origin of ECRB from the superomedial aspect) of the ECRB around the PBRN. The lengths of the nerves from its origin to the ECRB and from the lateral epicondyle to ECRB were measured, with the help of a Vernier caliper (Fig. 1). The data from the left and right side were compared by the unpaired Student's *t* test. Differences were considered significant if  $P < 0.05$ .

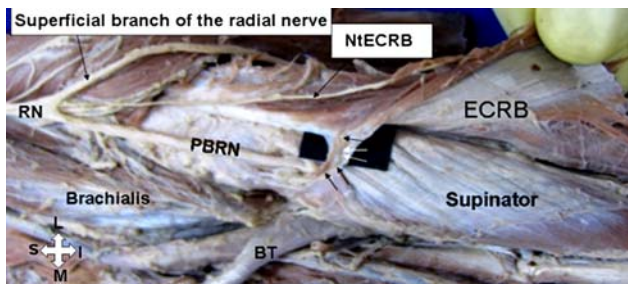
## Results

Radial nerve and its two terminal branches showed no variations. The ECRB took origin from the lateral epicondyle

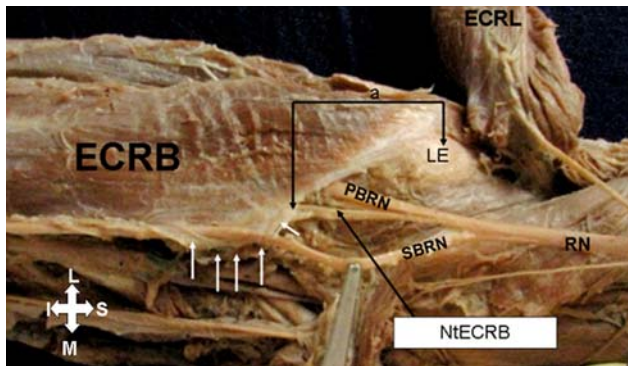


**Fig. 1** Schematic illustration of anatomical measurements. *E* extensor carpi radialis brevis muscle, *H* head of humerus, *L* lateral epicondyle of humerus, *Me* medial epicondyle of humerus, *PBRN* posterior branch of the radial nerve, *RN* radial nerve, *NtE* nerve to extensor carpi radialis brevis muscle, *SBRN* superficial branch of radial nerve, *U* ulna. The distance between the lateral epicondyle of the humerus and the entry point of the nerve to the extensor carpi radialis brevis is marked “*a*”

of the humerus, radial collateral ligament of the elbow joint and from the adjacent intermuscular septum. We did not observe any significant variation in the ECRB origin, but the above muscle had often a muscular or tendinous arch arising from its superomedial aspect and medially it attached to the deep fascia, above the near by structures (Figs. 2, 3). The ECRB had a tendinous arch in 21 cases (29.1%); a muscular arch in 8 (11.1%) cases and the arch was absent in 43 cases (59.7%) (Figs. 2, 4, 5). The nerve to the ECRB was a branch from the RN in 11 cases (15.2%); from the PBRN in 36 cases (50%) and from the SBRN in 25 cases (34.7%), respectively (Figs. 2, 3, 6). The nerve to the ECRB entered the muscle on the left and right sides at an average of 36.1 mm (min 22.7 mm; max 44.8 mm) and 38.3 mm (min 23.9 mm; max 46.4 mm), respectively, below the lateral epicondyle (Figs. 1, 3). The total length of the nerve to ECRB from its origin to the entry point of the muscle on the left and right sides were an average of 40.8 mm (max 61.8 mm; min 28.5 mm) and 43.4 mm (max 63.2 mm; min 28.9 mm) (Table 1).



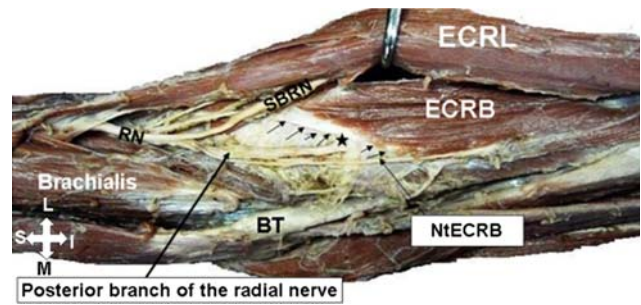
**Fig. 2** Anterior view of the left elbow region. *BT* biceps tendon, *ECRB* extensor carpi radialis brevis, *NiECRB* nerve to extensor carpi radialis brevis taking origin from the radial nerve, *PBRN* posterior branch of the radial nerve, *RN* radial nerve. Note the *arrows* indicate the arch (muscular) of the extensor carpi radialis brevis which is merging with the fascia above the supinator muscle



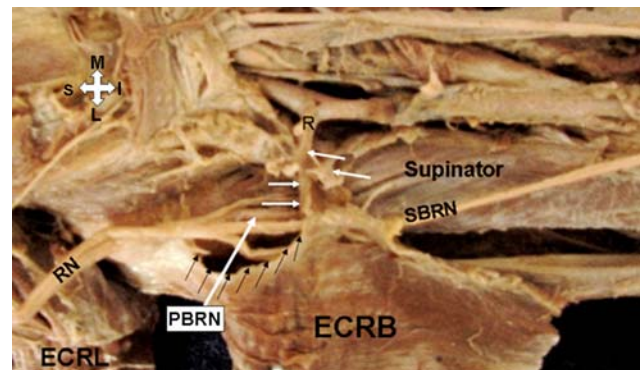
**Fig. 3** Anterior view of the right elbow region. *ECRB* extensor carpi radialis brevis, *ECRL* extensor carpi radialis longus, *LE* lateral epicondyle of the humerus, *NiECRB* nerve to extensor carpi radialis brevis taking origin from the posterior branch of the radial nerve, *PBRN* posterior branch of the radial nerve, *RN* radial nerve, *SBRN* superficial branch of the radial nerve. *Arrows* indicate fascial extension from the superomedial aspect of the extensor carpi radialis brevis muscle blending medially with the deep fascia overlying the forearm flexors and the superficial radial nerve. The distance between the lateral epicondyle of the humerus and the entry point of the nerve to the extensor carpi radialis brevis is marked “*a*”

## Discussion

The term tennis elbow has been used to describe multiple painful symptoms about the elbow. This frequent problem has a peak incidence in patients in the fourth decade of life. Tennis elbow is a misnomer because it also occurs in non-tennis players [17]. The etiology of LE is unknown; it can be due to the tendinogenic, articular, hypovascular or neurogenic reasons [3–5, 7–10, 22, 23, 27, 30]. The cause of neurogenic factor of the LE is due to the compression of RN or its branches, mainly the PBRN. The arcade of Frohse is the commonest site for the compression of PBRN [5, 7, 8], but less frequently an unusual free edge of the ECRB may compress the PBRN before it passes through the



**Fig. 4** Anterior view of the left elbow region. *BT* biceps tendon, *ECRB* extensor carpi radialis brevis, *ECRL* extensor carpi radialis longus, *NiECRB* nerve to extensor carpi radialis brevis taking origin from the posterior branch of the radial nerve, *RN* radial nerve, *SBRN* superficial branch of the radial nerve, *arrows* indicate the arch (tendinous) of the extensor carpi radialis brevis which is merging with the fascia above the supinator muscle. Note the five point star indicates the contact point of the arch of extensor carpi radialis brevis with the posterior branch of the radial nerve

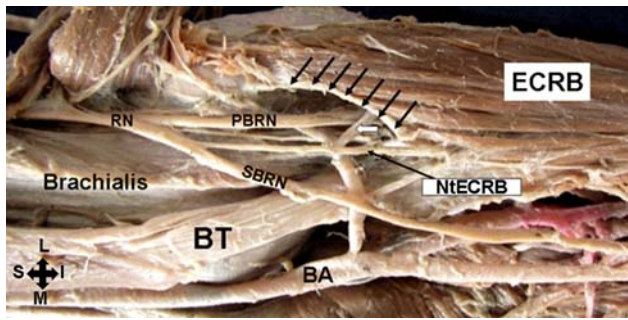


**Fig. 5** Anterior view of the right elbow region. *ECRB* extensor carpi radialis brevis, *ECRL* extensor carpi radialis longus, *PBRN* posterior branch of the radial nerve, *R* recurrent radial artery, *RN* radial nerve, *SBRN* superficial branch of the radial nerve, *black arrows* indicates the extensor carpi radialis arch. The extensor carpi radialis arch has been pulled to show its medial attachments to the deep fascia around the supinator, forearm flexors and the recurrent radial artery

supinator muscle. Kopell and Thompson [13] believed that the origin of ECRB could play an important role in the compression of PBRN. Spinner [24] mentioned the ECRB edge sometimes grooves the PBRN nerve during pronation. Roles and Maudsley [22] described that the origin of ECRB and arcade of Frohse (superficial part of supinator muscle) get tighten during extension and passive pronation of elbow, which is commonly seen in tennis players during the an improper backhand hitting technique, which can occur when the athlete attempts to increase the power by increasing forearm force rather than relying on core, rotator cuff and scapular power. This results in snapping the wrist with supination and irritation of the extensor tendons, especially the ECRB.

Papadopoulos et al. [19] found the tendinous type of ECRB arch in 90% upper limbs, which is much more when





**Fig. 6** Anterior view of the left elbow region. *BA* brachial artery, *BT* biceps tendon, *ECRB* extensor carpi radialis brevis, *NiECRB* nerve to extensor carpi radialis brevis taking origin from the superficial branch of the radial nerve, *PBRN* posterior branch of the radial nerve, *RN* radial nerve, *SBRN* superficial branch of the radial nerve, *left single arrow* indicate the leash of Henry; *multiple arrows* indicate arch (tendinous) of the extensor carpi radialis brevis. Note the posterior branch of the radial nerve is being compressed by the leash of Henry and the tendinous arch of extensor carpi radialis brevis

**Table 1** A Mean length of the nerve to ECRB from its origin to the entry point in the ECRB. B Mean length of the nerve to ECRB below the level of lateral epicondyle to the entry point in the ECRB in the left and right sides (in millimeters)

A		B	
Left (mm)	Right (mm)	Left (mm)	Right (mm)
40.8 ± 11.2	43.4 ± 11.3	36.1 ± 6.37	38.3 ± 6.49
61.8–28.5	63.2–28.9	22.7–44.8	23.9–46.4

Data expressed as mean ± standard deviation and range  
Differences were considered significant if  $P < 0.05$

compared with the present study. We observed the above variation in 29.1% cases only. Konjengbam and Elangbam [12] observed the tendinous type of ECRB arch in 78% upper limbs they studied. In the present study, we also observed muscular type of ECRB arch in eight cases (11.1%) along with the tendinous type of ECRB. Riffaud et al. [21] described when there is an ECRB arch present above the PBRN; its surgical decompression is justified. They further mentioned that the surgical approach in the above circumstances should be between the ECRB and ECRL muscles [21]. In the present study, we observed both the muscular and tendinous type of ECRB arch, which should be considered as one of the cause for PBRN compression at elbow.

Most of the standard text books of anatomy and hand surgery states that the nerve supply of ECRB is either from the RN trunk before it divides into deep and superficial branches in the proximal forearm or from the PBRN before it pierces the supinator muscle [11, 14, 15, 28]. In the recent times, it is well established that the nerve of ECRB may take origin from the SBRN [1, 2, 20]. In the present study,

we observed in 50% of cases the nerve supply of ECRB was from the PBRN, 34.7% cases the nerve supply of ECRB was from the SBRN and only 15.2% cases the nerve of ECRB was a branch from the trunk of RN. In contrast to the above Prasarthitha et al. [20] observed that the ECRB received its nerve supply from the PBRN, SBRN and RN in 2, 43 and 55%, respectively. The observations between the above studies may be attributed due to the difference in the study population. Variation in the nerve to ECRB is important in the clinical context. When the nerve to the ECRB is a branch from the SBRN, in this situation the ECRB may escape posterior interosseous nerve syndrome; mean time when the SBRN was injured in the proximal forearm it may involve the nerve to the ECRB and serve as a cause for its isolated paralysis. Recently, the ECRB has gained importance for its use in “free functional muscle transfer”; in this context the knowledge regarding ECRB nerve supply will prove handy for the surgeons.

In our study, we observed the length of the nerve to ECRB had an average of 40.8 and 43.4 mm on the left and right sides, respectively, from its origin to the entry point in the ECRB and the nerve to ECRB entered the muscle at an average of 36.1 and 38.3 mm on the left and right sides, respectively, below the lateral epicondyle. Low et al. [16] observed the above distance at an average of 39 mm, which is much similar to our finding. The data regarding the origin of the nerve to ECRB and its length from the lateral epicondyle will help the surgeons, while exploring the elbow region during the surgical decompression of the PBRN in between the ECRB and ECRL muscles.

In conclusion, the ECRB arch (tendinous and muscular) was observed in 40.2% cases in the present study. The above fact should be considered by the clinicians and surgeons as one of the neurogenic cause for LE and also in the posterior interosseous nerve syndrome, as the later is an etiologic factor in tennis elbow. Further cadaveric and clinical study will confirm its efficacy in the treatment of resistant LE.

## References

- Albrecht S, Cordis R, Kleihues H (1998) Functional neuroanatomy of the radial nerve in the region of the long wrist and finger joint extensors and the supinator groove. *Sportverletz Sportschaden* 12:1–7 (article in German)
- Al-Qattan MM (1996) The nerve supply to extensor carpi radialis brevis. *J Anat* 188:249–250
- Bales CP, Placzek JD, Malone KJ, Vaupel Z, Arnoczky SP (2007) Microvascular supply of the lateral epicondyle and common extensor origin. *J Shoulder Elbow Surg* 16:497–501
- Briggs CA, Elliott BG (1985) Lateral epicondylitis: a review of structures associated with tennis elbow. *Anat Clin* 7:149–153
- Deboucq C, Rooze M (1995) The arcade of Frohse: an anatomical study. *Surg Radiol Anat* 17:245–248
- Derkash RS, Niebauer JJ (1981) Entrapment of the posterior interosseous nerve by a fibrous band in the dorsal edge of the supinator

- muscle and erosion of a groove in the proximal radius. *J Hand Surg [Am]* 6:524–526
7. Eaton CJ, Lister GD (1992) Radial nerve compression. *Hand Clin* 8:345–357
  8. Fuss FK, Wurzl GH (1991) Radial nerve entrapment at the elbow: surgical anatomy. *J Hand Surg [Am]* 16:742–747
  9. Garden RS (1961) Tennis elbow. *J Bone Joint Surg [Br]* 43:100–106
  10. Kaplan EB (1959) Treatment of tennis elbow (epicondylitis) by denervation. *J Bone Joint Surg [Am]* 41:147–151
  11. Kaplan EB, Taleisnik J (1984) The wrist. In: Spinner M (ed) Kaplan's functional and surgical anatomy of hand, 3rd edn. J.B. Lippincott, Philadelphia, pp 153–178
  12. Konjengbam M, Elangbam J (2004) Radial nerve in the radial tunnel: anatomic sites of entrapment neuropathy. *Clin Anat* 17:21–25
  13. Kopell HP, Thompson WAL (1963) Peripheral entrapment neuropathies. Williams & Wilkins, Baltimore
  14. Last RJ (1984) *Anatomy: Regional and Applied*, 7th edn. Churchill Livingstone, Edinburgh, p 89
  15. Lister G (1984) *The hand: diagnosis and indications*, 2nd edn. Churchill Livingstone, Edinburgh, p 218
  16. Low CK, Chew JT, Mitra AK (1994) A surgical approach to the posterior interosseous branch of the radial nerve through the brachioradialis: a cadaveric study. *Singapore Med J* 35:394–396
  17. Nirschl RP, Petrone FA (1979) The surgical treatment of lateral epicondylitis. *J Bone Joint Surg [Am]* 61:832–839
  18. Ozturk A, Kutlu C, Taskara N, Kale AC, Bayraktar B, Cecen A (2005) Anatomic and morphometric study of the arcade of Frohse in cadavers. *Surg Radiol Anat* 27:171–175
  19. Papadopoulos N, Paraschos A, Pelekis P (1989) Anatomical observation on the arcade of Frohse and other structures related to the deep radial nerve: anatomical interpretation of deep radial nerve entrapment neuropathy. *Folia Morphol (Praha)* 37:319–327
  20. Prasaritha T, Liupolvanish P, Rojanakit A (1993) A study of the posterior interosseous nerve (PIN) and the radial tunnel in 30 Thai cadavers. *J Hand Surg [Am]* 18:107–112
  21. Riffaud L, Morandi X, Godey B, Brassier G, Guegan Y, Darnault P, Scarabin JM (1999) Anatomic bases for the compression and neurolysis of the deep branch of the radial nerve in the radial tunnel. *Surg Radiol Anat* 21:229–233
  22. Roles NC, Maudsley RH (1972) Radial tunnel syndrome: resistant tennis elbow as a nerve entrapment. *J Bone Joint Surg [Br]* 54:499–508
  23. Smola C (2004) About the problem of radial tunnel syndrome or “where does the tennis elbow end where does the radial tunnel syndrome begin. *Handchir Mikrochir Plast Chir* 36:241–245 (article in German)
  24. Spinner M (1968) The arcade of Frohse and its relationship to posterior interosseous nerve paralysis. *J Bone Joint Surg [Br]* 50:809–812
  25. Stasinopoulos D, Johnson MI (2006) ‘Lateral elbow tendinopathy’ is the most appropriate diagnostic term for the condition commonly referred-to as lateral epicondylitis. *Med Hypotheses* 67:1400–1402
  26. Thomas W, Tillmann B (1980) Radial nerve compression syndrome at the elbow with reference to radiohumeral epicondylosis: clinico-anatomic studies. *Z Orthop Ihre Grenzgeb* 118:41–46 (article in German)
  27. Wilhelm A (1993) Surgical treatment of resistant tennis elbow by denervation. *J Orthopaedic Surg Tech* 8:249–270
  28. Williams PL, Warwick R (1980) *Gray's Anatomy*, 36th edn. Churchill Livingstone, Edinburgh, p 579
  29. Witthaut J, Steffens K (1995) Paralysis of the interosseous nerve by a tendinous margin of the extensor carpi radialis brevis. *Handchir Mikrochir Plast Chir* 27:329–330 (article in German)
  30. Yergler B, Turner T (1985) Percutaneous extensor tenotomy for chronic tennis elbow: an office procedure. *Orthopedics* 8:1261–1263