

Hepatic Arterial Embolization with Doxorubicin-Loaded Superabsorbent Polymer Microspheres in a Rabbit Liver Tumor Model

Sanjay Gupta · Kenneth C. Wright ·
Joe Ensor · Carolyn S. Van Pelt ·
Katherine A. Dixon · Vikas Kundra

Received: 5 August 2010 / Accepted: 10 December 2010 / Published online: 9 April 2011
© Springer Science+Business Media, LLC and the Cardiovascular and Interventional Radiological Society of Europe (CIRSE) 2011

Abstract

Objectives The pharmacokinetic profile after hepatic arterial embolization with superabsorbent microspheres (QuadraSpheres) loaded with doxorubicin was studied.

Methods Rabbits with hepatic VX2 tumors were treated with intra-arterial administration of QuadraSpheres loaded with doxorubicin, or transarterial chemoembolization (TACE) using doxorubicin, Lipiodol and Embospheres, or hepatic arterial infusion (HAI) of doxorubicin. Tumor specimens were evaluated by fluorescence microscopy, and plasma and tumor concentrations of doxorubicin were measured.

Results The peak plasma concentration of doxorubicin was lower in the QuadraSphere group (309.9 ng/ml) than in the HAI (673.4 ng/ml) or TACE (360.5 ng/ml) groups, suggesting higher tumor retention in the QuadraSphere group. Intratumoral doxorubicin levels declined to negligible levels at 1 and 3 days after treatment, respectively, in the HAI and TACE groups. In the QuadraSphere groups, intratumoral doxorubicin level declined after day 1, but was still detectable at 14 days after treatment and was higher than that in the other groups at 1, 3, and 7 days.

Intratumoral doxorubicin fluorescence was detected at all time points in the QuadraSphere group, but only at 1 day after treatment in the TACE group.

Conclusions Hepatic arterial administration of doxorubicin-loaded QuadraSpheres enables the sustained release of doxorubicin to hepatic tumors.

Keywords Hepatic artery embolization · Drug-eluting microspheres · Pharmacokinetics

Introduction

Treating patients with primary or secondary liver malignancies is challenging. Surgery, the only potentially curative therapeutic option, is possible in only 5–20% of patients [1–5], and systemic chemotherapy generally has had only limited success in liver metastasis or hepatocellular carcinoma. Furthermore, patients who receive systemic chemotherapy can develop serious adverse effects. Because of the high risk of morbidity and death associated with a large tumor burden in the liver, alternative techniques based on regional delivery of chemotherapy to the liver are being used increasingly for cytoreductive or palliative purposes.

The goal of hepatic arterial infusion (HAI) of chemotherapy is to increase drug delivery to hepatic tumors while minimizing undesirable systemic toxic effects. Transarterial chemoembolization (TACE) combines regional chemotherapy and embolization to increase the time of exposure to cytotoxic agents and induce ischemia in the tumor. TACE offers a survival benefit to patients with intermediate hepatocellular carcinoma [6, 7]. Although using combinations of embolic agents and iodized oil in standard TACE therapy can potentially slow the washout

S. Gupta (✉) · K. C. Wright · K. A. Dixon · V. Kundra
Department of Diagnostic Radiology, The University of Texas
M. D. Anderson Cancer Center, 1515 Holcombe Blvd, Houston,
TX 77030, USA
e-mail: sgupta@mdanderson.org

J. Ensor
Department of Biostatistics, The University of Texas
M. D. Anderson Cancer Center, Houston, TX 77030, USA

C. S. Van Pelt
Department of Veterinary Medicine and Surgery,
The University of Texas M. D. Anderson Cancer Center,
Houston, TX 77030, USA

of the cytotoxic agent from the tumor, the drug is still rapidly released from the iodized oil solution.

One relatively new strategy for increasing the effectiveness of regional chemotherapy is the use of drug-eluting microspheres that enable the prolonged release of a chemotherapeutic agent into a tumor [8–16]. A sustained drug concentration within the tumor bed has been shown to increase the probability of cell death [17–19]. A few recent animal and clinical studies have shown that drug-eluting microspheres can be used to deliver doxorubicin to a tumor site over an extended period while minimizing the systemic release of the drug [8–16].

QuadraSpheres, a new type of nonbiodegradable, superabsorbent polymer microsphere (BioSphere Medical Inc., Rockland, MA), absorb fluid and swell when exposed to aqueous media [20]. These particles differ from previous embolic agents and drug-eluting beads in that they are soft and deformable and conform to the lumen of the embolized vessels [20–22]. Hori and colleagues first reported the successful utilization of these microspheres [23]. Superabsorbent polymer microspheres have been used clinically in humans to embolize large hepatocellular carcinomas [24]; in addition, *in vitro* studies have suggested that these microspheres can absorb several chemotherapeutic drugs that can be released from the microspheres at variable rates [25, 26]. A recently published study showed that after intra-arterial administration of doxorubicin-loaded superabsorbent polymer microspheres in an animal model, intratumoral doxorubicin concentration peaked at 3 days and remained detectable until 7 days [26]. However, to the best of our knowledge, no previous study has compared the pharmacokinetics between drug-loaded QuadraSpheres, TACE, and HAI. In this study, we evaluated the pharmacokinetic profile after hepatic arterial embolization with superabsorbent polymer microspheres loaded with doxorubicin in a rabbit liver tumor model and compared this technique with that of HAI of doxorubicin and standard TACE with iodized oil and tris-acryl gelatin microspheres (Embospheres).

Materials and Methods

Animals

All experiments involving New Zealand white rabbits were approved by the Institutional Animal Care and Use Committee at our institution. Animals were maintained in facilities approved by the Association for Assessment and Accreditation of Laboratory Animal Care International and in accordance with current U.S. Department of Agriculture, Department of Health and Human Services, and National Institutes of Health regulations and standards.

Tumor Model

The rabbit VX2 carcinoma was used for the study. Although this tumor is not human in origin, it was selected for several reasons. It is a highly malignant carcinoma that has both squamous and adenomatous characteristics. It grows rapidly at the inoculation site and metastasizes to regional lymph nodes and lungs [27, 28]. It possesses characteristics similar to those of human carcinomas, including heparin-dependent angiogenesis [27, 28], a biochemical phenotype characteristic of advanced-stage liver tumors (i.e., high glycolysis and elevated levels of mitochondrial-bound hexokinase) [27, 29], and a lack of spontaneous regression. In addition, when rabbit VX2 carcinoma is implanted in the liver, its blood supply (hepatic artery and portal vein) is similar to that of human liver tumors; lipiodol has been shown to selectively accumulate and remain in the tumor after intra-arterial administration [30–32]. Furthermore, the tumor can be readily identified by angiography, and the rabbit vasculature is large enough to allow selective hepatic arterial catheterization.

Tumor Inoculation

Single VX2 tumors were inoculated into the liver in 65 male New Zealand white rabbits (3.5–4.2 kg) in the following manner. Each rabbit was sedated with an intramuscular injection of buprenorphine (0.15 mg; Bedford Laboratories, Bedford, OH), and anesthesia was induced with 5% isoflurane/oxygen (1.5 L/min) administered via mask and maintained with 3–5% isoflurane/oxygen (1.5 L/min). Enrofloxacin antibiotic (Baytril; Bayer Corporation, Agriculture Division, Animal Health, Shawnee Mission, KS) was given intramuscularly at a dose of 5.0 mg/kg. The abdomen was shaved and prepared for aseptic surgery. A small midline incision was made, and the left lateral lobe of the liver was exteriorized and inoculated at a single site with 0.3 ml of freshly harvested and prepared VX2 tumor fragments. The fragments were placed in the liver through an 18-gauge needle attached to a 1-ml syringe. Direct inoculation of tumor fragments into a single site in the left lobe allowed the growth of a solitary, well-demarcated tumor in the liver of each recipient rabbit. After hepatic inoculation, the abdomen was closed in layers, and the animal was kept warm and monitored until it recovered from anesthesia. The tumors were allowed to grow in the rabbits' livers for 14–16 days before treatment.

Tumor Treatment

At the time of treatment, each animal was anesthetized with a 150-mg intramuscular injection of ketamine (Fort Dodge

Animal Health, Fort Dodge, IA) and 10 mg of acepromazine (Vedco, Inc., Saint Joseph, MO), and antibiotics were administered as before. A 22-gauge intravenous catheter (Insyle™ Autogard™ Winged; Becton–Dickinson Therapy Systems Inc., Sandy, UT) was placed in a marginal ear vein, and anesthesia was maintained with use of intravenous injections of 25 mg/ml of thiopental sodium (pentothal; Hospira, Inc., Lake Forest, IL) given to effect.

The right groin was shaved and prepared for aseptic surgery. The right femoral artery was isolated via a cut down, a 4-Fr introducer sheath (Cook Inc., Bloomington, IN) was placed in the artery through a small arteriotomy, and heparin sodium (100 IU/kg) was administered. A 2.8-Fr microcatheter (EmboCath Plus; BioSphere Medical) was inserted through the sheath in the femoral artery. With the help of a 0.014-in hydrophilic guidewire (Transend; Boston Scientific, Miami, FL), the microcatheter was advanced up the aorta and manipulated into the celiac axis under fluoroscopic monitoring. A digital subtraction arteriogram was obtained by hand-injecting approximately 3 ml of radiographic contrast medium (Conray® 60; Mallinckrodt Inc., St. Louis, MO) and using serial x-ray filming to document the location and size of the tumor and to delineate its blood supply. The catheter was then manipulated into the proper hepatic artery and positioned distal to the origin of the gastroduodenal artery. Blood flow around the catheter and the absence of arterial spasm were verified by hand-injection of the contrast/saline mixture.

Treatment Groups

Twenty rabbits were treated with HAI of 4 mg of doxorubicin dissolved in 2 ml of solution containing 1 ml of nonionic contrast medium (Visipaque 320; GE Healthcare, Inc., Princeton, NJ) and 1 ml of saline (the HAI group). Another 20 rabbits were treated with hepatic arterial administration of 4 mg of doxorubicin mixed with 0.4 ml of Lipiodol (Ethiodol; Savage Laboratories, Melville, NY), followed by embolization with 100- to 300- μ m of tris-acryl gelatin microspheres (Embospheres; BioSphere Medical) until stasis was achieved (the TACE group). A third group, containing 25 rabbits, was treated with hepatic arterial administration of 50- to 100- μ m of superabsorbent polymer microspheres loaded with 4 mg of doxorubicin (the QuadraSphere group). Hepatic arterial administration of respective materials in each treatment group was performed under continuous fluoroscopic monitoring to avoid any reflux into the gastroduodenal or gastric arteries.

The doxorubicin-QuadraSphere mixture was prepared by adding 15 ml of nonionic contrast medium (Visipaque 320; GE Healthcare, Inc., Princeton, NJ) to 50 mg of doxorubicin powder (Bedford Laboratories) and adding 10 ml of saline to 25 mg of 50- to 100- μ m QuadraSpheres.

After the doxorubicin powder dissolved completely (approximately 15 min), full aliquots of both solutions were drawn into a 30-ml syringe. After 2–4 h, 2 ml of the mixture (containing 4 mg of doxorubicin and 2 mg of QuadraSpheres) was injected into each rabbit. After treatment, the catheter and sheath were removed, the femoral artery was ligated, and the incision was closed in two layers with 4-0 Vicryl.

Pharmacokinetics

Blood was collected immediately before and at 10, 20, 40, 60, 120, and 180 min after treatment via a catheter inserted in the ear vein in five animals per treatment group. Blood also was collected just before euthanization in animals that were killed 1 day after treatment. Doxorubicin and doxorubicinol levels in these blood samples were analyzed with use of liquid chromatography-mass spectrometry. Blood samples also were collected to determine liver function at 1 h after treatment and just before euthanization in five animals per treatment group.

Euthanasia, Necropsy, Tissue Preparation, Histologic Analysis, and Light and Fluorescence Microscopic Analyses

Rabbits were euthanized with an intravenous overdose of Beuthanasia-D (70 mg/kg; Schering-Plough Animal Health Corp., Kenilworth, NJ), and a complete necropsy was performed at 1 h and at 1, 3, or 7 days after treatment in the HAI and TACE groups and at 1 h and at 1, 3, 7, or 14 days after treatment in the QuadraSphere group (5 animals at each time point in each treatment group). The liver tumors were removed and divided into two halves. One half was formalin-fixed for subsequent light and fluorescence microscopic examinations, and the other half was submitted for doxorubicin analysis.

After tumor fixation, liver and tumor tissue specimens from rabbits in the TACE and QuadraSphere groups were trimmed into a series of 2- to 3-mm-thick histologic blocks that were embedded in paraffin, cut at nominal 5- μ m intervals, and mounted on slides. The slides were either stained with hematoxylin and eosin (H&E) for light microscopic examination or left unstained for fluorescence microscopic examination. An experienced veterinary pathologist (C.S.V.P.) evaluated all histologic slides for the presence, size, and morphologic features of QuadraSpheres and Embospheres, the number of spheres in each vessel, and presence of perivascular inflammation. However, because VX2 tumors spontaneously necrose, we did not compare the two groups in terms of degrees of necrosis. As a pre-examination control, empty and doxorubicin-loaded QuadraSphere aliquots were placed on lens paper (Fisher

Scientific, Plano, TX) in tissue cassettes, processed similarly to the tissues on the H&E slides, and examined under light microscopy for morphologic and staining characteristics.

Fluorescence microscopy was used to visualize the distribution of doxorubicin in tumor tissue. Doxorubicin autofluorescence was detected with use of an Olympus BX51 research microscope (Olympus America Inc., Melville, NY). Images were captured with an Olympus U-MCAD-2 digital camera and were acquired with Magnafire 2.1C digital imaging software (Optronics, Goleta, CA). The depth of fluorescence penetration at the edge of the microspheres was measured by using Image-Pro Plus image analysis software (Media Cybernetics, Inc., Silver Spring, MD).

Statistical Analysis

For the plasma and tissue drug concentration data, differences in average drug concentration were assessed within each time point using a one-way analysis of variance model (ANOVA). Pairwise comparisons were accomplished using Gabriel's multiple-comparison procedure. The peak AST and ALT levels were compared between the QuadraSpheres and TACE treatment groups using the Satterthwaite's approximate two-sample two-tailed *t* test. All analyses were conducted using the SAS software package (SAS Release 9.1.3. 2002, SAS Institute, Cary, NC). A *p* value < 0.05 was considered statistically significant.

Results

Plasma and Tissue Pharmacokinetics

The plasma doxorubicin concentration peaked at 10 min in all treatment groups, returned to near baseline at approximately 60 min, and stayed low until 24 h after the procedure (Fig. 1A). The peak plasma levels of doxorubicin in the QuadraSphere group were significantly lower than those in the HAI group (309.9 ng/ml vs. 673.4 ng/ml; *P* = 0.0183). Although the plasma concentrations of doxorubicin in the QuadraSphere group were lower than those in the HAI group at 20, 40, and 60 min, these differences were not statistically significant. Similarly, plasma doxorubicin levels in the QuadraSphere group were lower than those in the TACE group at all time points, but this was not statistically significant. The plasma doxorubicin concentration in the HAI and TACE groups peaked at 10 and 60 min, respectively, followed by a steady decline (Fig. 1B). In contrast, the pharmacokinetic profile after treatment with QuadraSpheres showed constant plasma doxorubicin concentrations, starting at 10 min after

administration and lasting until the final measurement was taken (24 h after administration).

In the HAI group, the mean intratumoral doxorubicin levels were highest (153.4 ± 211.2 ng/mg) in animals euthanized 1 h after the procedure and sharply declined to negligible levels (17.1 ± 13.2 ng/mg) within 1 day after treatment (Fig. 2). In the TACE group, intratumoral doxorubicin levels were similar at 1 h (61.9 ± 41.9 ng/mg) and 1 day (61 ± 34.9 ng/mg) after treatment and declined to minimal levels within 3 days (22.9 ± 12.1 ng/mg). In the QuadraSphere group, the greatest level of intratumoral doxorubicin (196.5 ± 312.8 ng/mg) was seen at 1 day after treatment. The levels gradually declined after that, but substantial amounts (43.88 ± 23.2 ng/mg) were still detectable at 14 days after treatment. The mean intratumoral doxorubicin concentrations in the QuadraSphere group were higher than those in the other two groups at 1, 3, and 7 days after treatment. The differences in the mean tumor doxorubicin concentrations among the three delivery methods were statistically significant at 3 days (*P* = 0.0065) and 7 days (*P* = 0.023). Gabriel's pairwise comparison analysis showed that at 3 days after treatment, the mean intratumoral doxorubicin concentrations in the QuadraSphere group was significantly higher than the other two groups, whereas the differences between the TACE and HAI groups were not statistically significant.

Histologic Features of Microspheres

QuadraSpheres and Embospheres were found in intratumoral and peritumoral vessels, and variable degrees of microsphere-associated transmural and perivascular inflammation occurred at all time points. The inflammatory reaction was similar in the two groups and was mainly composed of neutrophils, macrophages, and multinucleated giant cells. QuadraSpheres were deformed and conformed to the vessel lumen and adjacent particles, whereas Embospheres retained their spherical shape (Fig. 3C). QuadraSpheres ranged from 165 to 475 μ m and Embospheres from 98 to 283 μ m. The number of QuadraSpheres in each embolized vessel ranged from 1 to 12, with a mean of 3.1; 31 of the 50 embolized vessels with microspheres (62%) contained more than one microsphere.

For the *in vitro* experiments, the empty QuadraSpheres were basophilic, whereas the doxorubicin-loaded QuadraSpheres were eosinophilic. In tumor tissue, most of the QuadraSpheres were eosinophilic with occasional clefts; however, a few of the QuadraSpheres were basophilic (Fig. 3B). The Embospheres in tumor tissue were round and eosinophilic with occasional basophilic rims (Fig. 3C). The size and morphologic features of the QuadraSpheres did not vary at different intervals after treatment. However, animals euthanized 14 days after treatment had more

Fig. 1 **A** Serum doxorubicin (ng/ml) and **B** doxorubicinol (ng/ml) levels at various times after treatment in the three treatment groups. The x-axis is on a logarithmic scale to accommodate the 1440 h time point

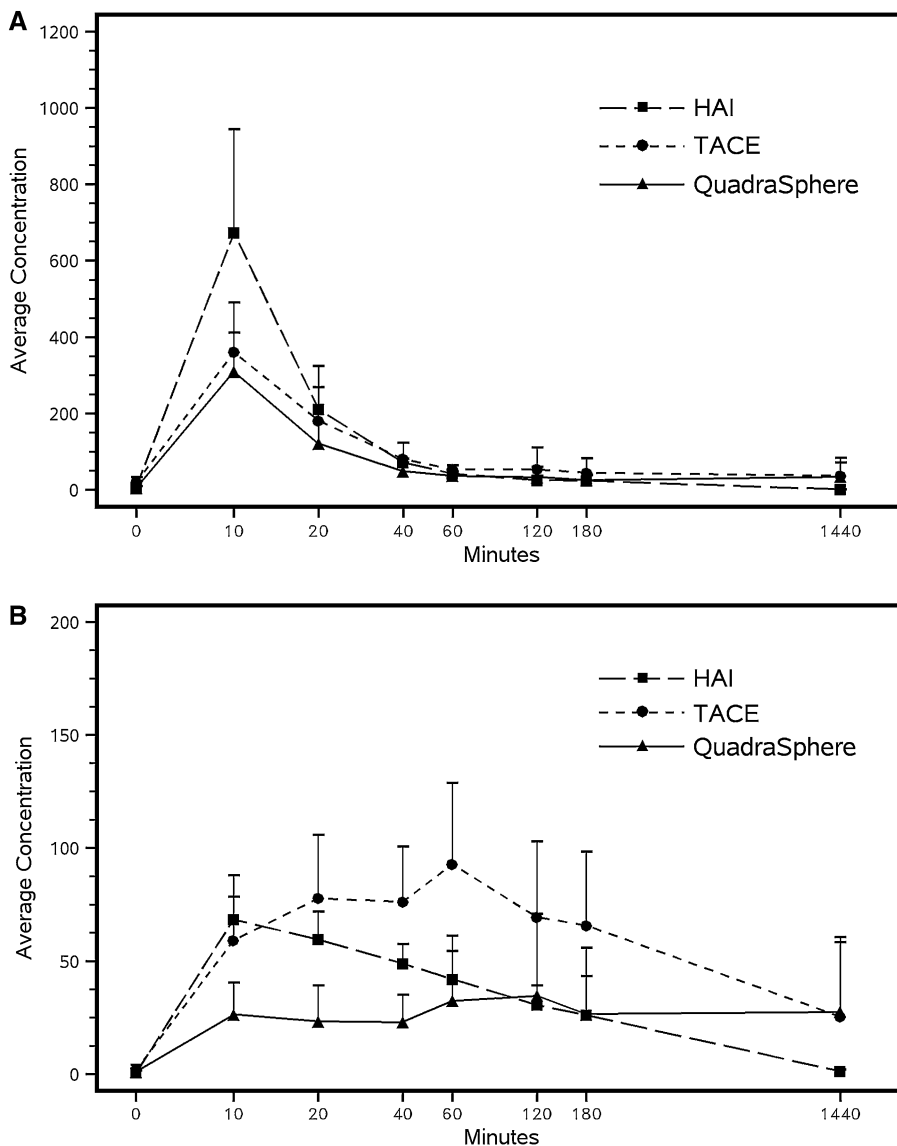
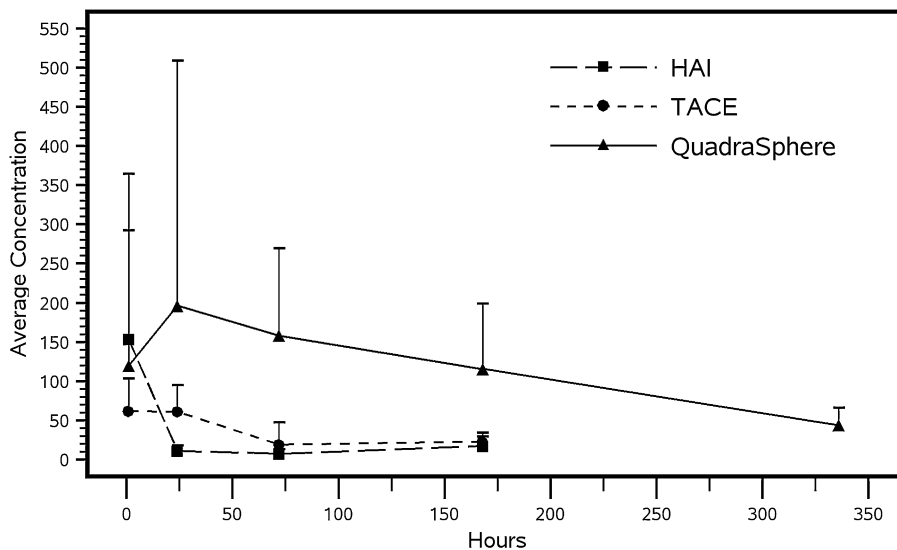


Fig. 2 Tumor doxorubicin levels (ng/mg tissue) at various times after treatment in the three treatment groups



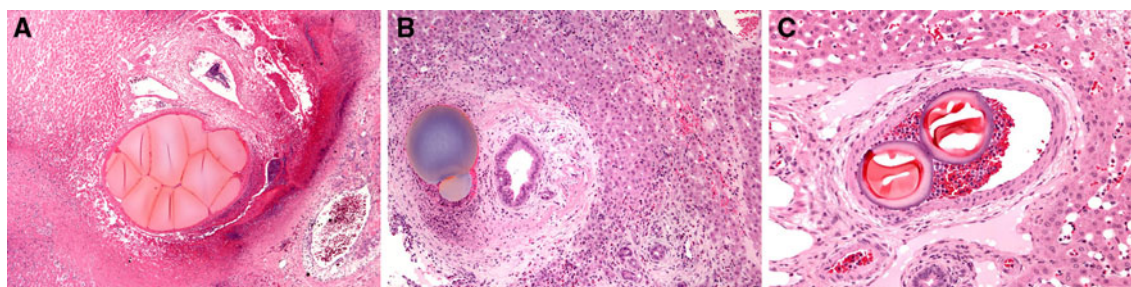


Fig. 3 Photomicrographs (all hematoxylin and eosin [H&E] stain): **A** Multiple eosinophilic QuadraSpheres occluding a vessel (original magnification, 50 \times). QuadraSpheres were deformed and conformed to the morphology of the vessel lumen and adjacent particles.

B Basophilic QuadraSphere in a peritumoral vessel in the liver (original magnification, 100 \times). **C** Two Embospheres in a vessel. These Embospheres are round, eosinophilic structures with basophilic rims (original magnification, 200 \times)

basophilic QuadraSpheres (28.6%) than did those euthanized at 1, 3, or 7 days after treatment (0%, 7.8%, and 4.6%, respectively). The size, morphologic features, and staining characteristics of the Embospheres did not vary at different intervals after treatment.

Doxorubicin Fluorescence

Animals that were euthanized 1 day after treatment in both the QuadraSphere and TACE groups showed intratumoral doxorubicin fluorescence (Figs. 4, 5, respectively). In the QuadraSphere group, fluorescence was concentrated around the microspheres and extended 400–1600 μm into the surrounding tumor tissue (Fig. 4). In the TACE group, however, doxorubicin fluorescence was randomly distributed throughout the tumor and surrounding normal liver tissue. In the QuadraSphere group, rabbits euthanized at 3, 7, or 14 days after treatment showed intratumoral doxorubicin fluorescence; the fluorescence distribution and intensity were similar to those in rabbits euthanized 1 day after treatment (Fig. 4). In comparison, minimal or no fluorescence was detected in the TACE group animals euthanized 3 or 7 days after treatment (Fig. 5), even with exposure times that were nine or ten times longer than those used for animals in the QuadraSphere group.

Liver Function Tests

In the HAI group, no appreciable changes were seen in the serum levels of aspartate aminotransferase (AST), alanine aminotransferase (ALT), and alkaline phosphatase after treatment. Rabbits in the TACE group showed transient elevation in AST and ALT levels after treatment, reaching peak concentration at 1 day after treatment. AST levels returned to baseline within 3 days after treatment and ALT levels within 7 days after treatment. In the QuadraSphere group, the AST levels peaked at 1 day after treatment and then gradually returned to baseline within 14 days after treatment. The ALT levels in this group also increased

sharply within 1 day after treatment, continued to increase until 7 days after treatment, and then returned to baseline within 14 days after treatment. The peak AST levels in the QuadraSphere group were lower than those in the TACE group ($P = 0.0251$); although the peak ALT levels also were lower, this difference did not reach statistical significance ($P = 0.1177$). Serum bilirubin levels remained normal at all time points in all three groups.

Discussion

Results of the current study suggest that hepatic arterial administration of doxorubicin-loaded QuadraSpheres results in the sustained release of doxorubicin to hepatic tumors. The plasma doxorubicin pharmacokinetic profile after HAI in the current study is in keeping with earlier studies that showed that although HAI allows drugs to be delivered to liver tumors at higher doses than those delivered in systemic administration, very little of the drug is retained in the tumor. The use of Lipiodol during standard TACE has been shown to promote drug retention in tumors [33–36]. Similar to the results of the current study, Nakamura et al. [37] showed that after administering an emulsion of an anticancer drug and Lipiodol, the level of the anticancer drug in the blood was markedly lower than that after an arterial infusion of an identical dose of the drugs alone; however, in their study, the sustained release of the emulsion was serially measured for only 30 min. In an in vitro elution study, Lewis et al. [13] found that a Lipiodol suspension that rapidly released doxorubicin had a half-life of approximately 1 h.

The temporal pharmacokinetic profile of serum doxorubicin levels after TACE in the present study, namely peak concentrations at 10 min after treatment with return to near baseline levels at 60 min after treatment, is in keeping with the above-mentioned results. Although the tumor doxorubicin levels in the TACE group remained high at 1 h and 1 day after treatment, they sharply declined to minimal

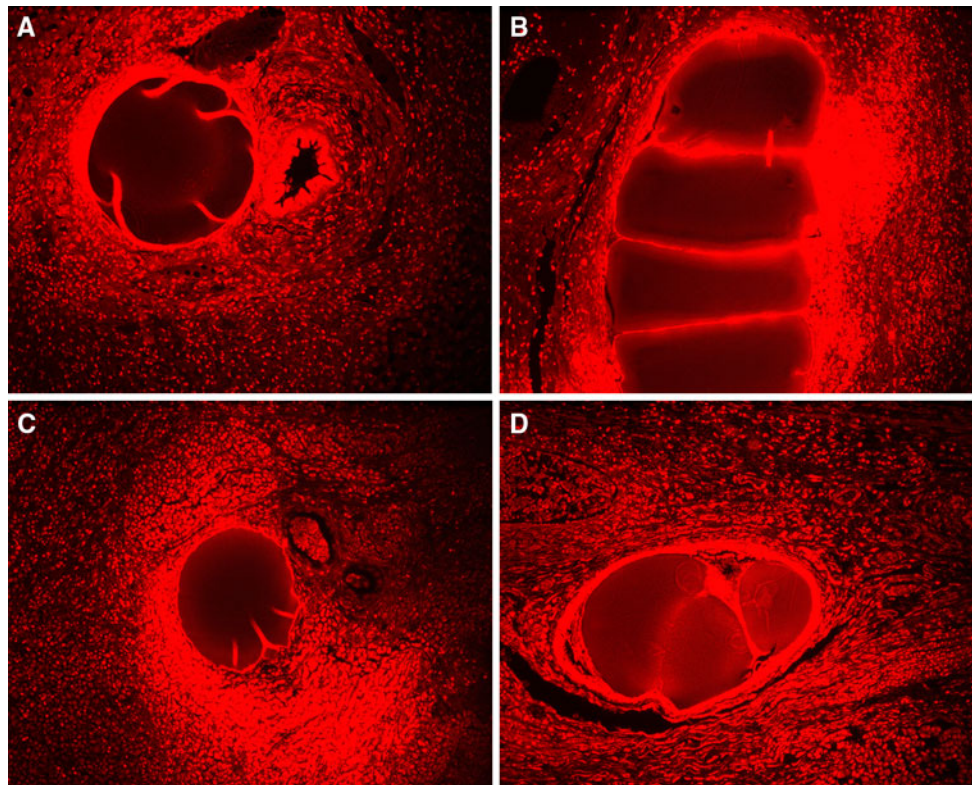


Fig. 4 Doxorubicin fluorescence in the QuadraSphere group. Photomicrographs (original magnification, 10 \times) in animals euthanized 1 (A), 3 (B), 7 (C), or 14 (D) days after treatment show fluorescence in and around the microspheres. The fluorescence intensity was similar at all times

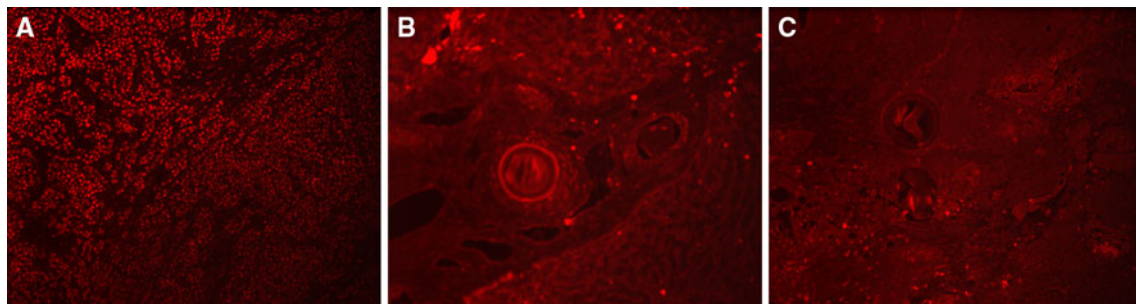


Fig. 5 Doxorubicin fluorescence in the transarterial chemoembolization (TACE) group. Intratumoral fluorescence in an animal killed 1 day (A) after treatment (original magnification, 10 \times). Minimal or

no intratumoral fluorescence is seen in animals killed at 3 days (B) or 7 days (C) after treatment. Note the Embospheres in B and C

levels at 3 days after treatment, suggesting rapid elution of doxorubicin from the tumor. This finding is further corroborated by the finding that although animals killed 1 day after TACE showed tumor fluorescence, none of the animals killed 3 or 7 days after TACE had appreciable tumor fluorescence, suggesting that very little drug remained in the tumors at these times. Based on these results, we believe that although the use of standard TACE with Lipiodol allows greater tumor doxorubicin deposition than the use of HAI, TACE plus Lipiodol does not prolong doxorubicin retention in the tumor for more than 24 h after treatment.

The lower plasma doxorubicin concentrations in the QuadraSphere group compared with other treatment groups, as seen in the current study, demonstrate higher tumor retention of the drug in the animals treated with QuadraSpheres. Lower plasma doxorubicin levels in the QuadraSphere group also has the potential benefit of reducing systemic exposure to the chemotherapeutic drug, which could allow administration of higher concentrations of doxorubicin to the tumor. The pharmacokinetic profile of plasma doxorubicin in the QuadraSphere group, i.e., sustained levels from 10 min until 24 h after treatment, also favors the slow drug-release feature of the

QuadraSpheres. These results are in keeping with those reported by Lee et al. [26], who found sustained plasma doxorubicin levels between 20 min to 120 min after hepatic arterial administration of doxorubicin-loaded QuadraSpheres. In the same study, Lee et al. [26] found that doxorubicin concentration in the tumor peaked at 3 days and remained detectable until 7 days; however, unlike the current study, Lee et al. did not evaluate the pharmacokinetic profile after HAI or standard TACE. In our study, we found that in contrast to the HAI and TACE treatment groups, animals treated with QuadraSpheres showed high intratumoral levels of doxorubicin until 14 days after treatment; these findings suggest that hepatic arterial administration of QuadraSpheres results in prolonged drug retention in the tumor. The prolonged, sustained drug-release property of QuadraSpheres is further illustrated by the presence of persistent fluorescence around the microspheres 14 days after treatment. Fluorescence microscopy also allowed us to study the spatial drug distribution, demonstrating that doxorubicin released from the microspheres extended 400–1600 μm into the surrounding tissues.

Because sustained drug release increases the possibility of tumor cell death [17–19, 38], the findings suggest that treating liver tumors with doxorubicin-loaded QuadraSpheres has potentially higher therapeutic efficacy than does standard TACE or HAI. Also, the decreased release of the drug into the systemic circulation may reduce the systemic toxicities associated with the chemotherapeutic agent.

We found that QuadraSpheres deform to conform to the morphology of the vessel lumen and adjacent particles, leaving virtually no space in the occluded vessel. The tendency of QuadraSpheres to swell and conform to the vessel wall without leaving spaces may lead to more complete occlusion of the vessels compared with the spherical particles that tend to maintain their shape. This finding is consistent with previous studies' results [20–22]. Another study also found that QuadraSpheres had a higher *in vivo* deformation rate (15%) than Embospheres did (9%); the study's authors concluded that this difference may have been attributable to the different mechanical properties of the two types of microspheres in terms of surface structure, absorption ability, and deformability [22]. In the current study, the size of QuadraSpheres in the tissue specimens ranged from 165 to 475 μm , approximately 3.5–4 times larger than the particles in their dry state (50–100 μm). Previous *in vitro* and *in vivo* studies have shown similar swelling characteristics for these particles [20, 22, 24, 39, 40].

Similar to previous reports, we found that Embospheres had an eosinophilic appearance [20, 41]. However, unlike a previous study [20] that showed that QuadraSpheres are

basophilic, most QuadraSpheres in the present study were eosinophilic on H&E staining. We believe that this eosinophilic appearance of the QuadraSpheres was due to the presence of doxorubicin within the microspheres. This was confirmed by our *in vitro* experiments, which showed that the empty QuadraSpheres were basophilic, whereas the doxorubicin-loaded QuadraSpheres were eosinophilic. The basophilic QuadraSpheres seen in tissue probably had minimal or no doxorubicin, either secondary to incomplete loading or to the release of doxorubicin into the surrounding tissues. The latter is supported by the fact that more basophilic Quadraspheres were found at 14-day time point compared with earlier time points. However, further *in vitro* studies are required to show definitely that the change in staining pattern is related to drug elution from the microspheres.

The presence of mild-to-moderate perivascular inflammation around both Embospheres and QuadraSpheres was probably a foreign body reaction [41]. Using a rabbit renal model, Khankan et al. [20] found that rabbits killed 1 week after embolization with QuadraSpheres showed a mild foreign body reaction consisting of macrophages. In another study, de Luis et al. [22] found lymphocytes and giant cells around the microspheres in pigs killed 4 weeks after renal artery embolization with QuadraSpheres. In the current study, the presence of significant perivascular inflammation in rabbits killed 1 day after treatment in the TACE group was in contrast to previous animal studies, in which inflammation was seen only much later. For example, Siskin et al. [42], in a study involving embolization of porcine kidneys, found that inflammatory response increased over time after embolization with EmboSphere and EmboGold microspheres—inflammation was not detectable at 7 days and was highest at 28 days. Derdeyn et al. [43], in an *in vivo* animal study with Embospheres, found no inflammation at 48 h but found chronic transmural and perivascular inflammation after 4 weeks. We believe that the early onset of inflammation seen in our TACE group was probably caused by Lipiodol.

One of the major limitations of this study was that we could not compare the different treatment groups in terms of therapeutic efficacy because VX2 tumors have been shown to have varying degrees of spontaneous necrosis, and it was not possible to differentiate treatment-induced necrosis from spontaneous necrosis. In addition, because we did not quantify the fluorescence intensity, the study does not provide any information related to drug concentration gradient in tumor tissue. However, findings from the current study clearly show that compared with HAI and standard TACE, hepatic arterial administration of QuadraSpheres results in prolonged tumor exposure to doxorubicin, which could translate into increased therapeutic efficacy.

Acknowledgments This work was supported in part by grants from Biosphere Medical, Inc, and the John S. Dunn Research Foundation.

Conflict of interest The authors have no other conflicts of interest.

References

- Dodd GD 3rd, Soulen MC, Kane RA et al (2000) Minimally invasive treatment of malignant hepatic tumors: at the threshold of a major breakthrough. *Radiographics* 20:9–27
- Liem MS, Poon RT, Lo CM et al (2005) Outcome of transarterial chemoembolization in patients with inoperable hepatocellular carcinoma eligible for radiofrequency ablation. *World J Gastroenterol* 11:4465–4471
- Lo CM, Ngan H, Tso WK et al (2002) Randomized controlled trial of transarterial lipiodol chemoembolization for unresectable hepatocellular carcinoma. *Hepatology* 35:1164–1171
- Maataoui A, Qian J, Vossoughi D et al (2005) Transarterial chemoembolization alone and in combination with other therapies: a comparative study in an animal HCC model. *Eur Radiol* 15:127–133
- Martin M, Tarara D, Wu YM et al (1996) Intrahepatic arterial chemoembolization for hepatocellular carcinoma and metastatic neuroendocrine tumors in the era of liver transplantation. *Am Surg* 62:724–732
- Llovet JM, Bruix J (2003) Systematic review of randomized trials for unresectable hepatocellular carcinoma: Chemoembolization improves survival. *Hepatology* 37:429–442
- Llovet JM, Real MI, Montana X et al (2002) Arterial embolisation or chemoembolisation versus symptomatic treatment in patients with unresectable hepatocellular carcinoma: a randomised controlled trial. *Lancet* 359:1734–1739
- Dhanasekaran R, Kooby DA, Staley CA et al (2010) Comparison of conventional transarterial chemoembolization (TACE) and chemoembolization with doxorubicin drug eluting beads (DEB) for unresectable hepatocellular carcinoma (HCC). *J Surg Oncol* 101:476–480
- Eyol E, Boleij A, Taylor RR et al (2008) Chemoembolisation of rat colorectal liver metastases with drug eluting beads loaded with irinotecan or doxorubicin. *Clin Exp Metastasis* 25:273–282
- Hong K, Khwaja A, Liapi E et al (2006) New intra-arterial drug delivery system for the treatment of liver cancer: preclinical assessment in a rabbit model of liver cancer. *Clin Cancer Res* 12:2563–2567
- Kettenbach J, Stadler A, Katzler IV et al (2008) Drug-loaded microspheres for the treatment of liver cancer: review of current results. *Cardiovasc Intervent Radiol* 31:468–476
- Lammer J, Malagari K, Vogl T et al. Prospective randomized study of doxorubicin-eluting-bead embolization in the treatment of hepatocellular carcinoma: results of the PRECISION V study. *Cardiovasc Intervent Radiol* 33:41–52
- Lewis AL, Gonzalez MV, Lloyd AW et al (2006) DC bead: in vitro characterization of a drug-delivery device for transarterial chemoembolization. *J Vasc Interv Radiol* 17:335–342
- Lewis AL, Taylor RR, Hall B et al (2006) Pharmacokinetic and safety study of doxorubicin-eluting beads in a porcine model of hepatic arterial embolization. *J Vasc Interv Radiol* 17:1335–1343
- Taylor RR, Tang Y, Gonzalez MV et al (2007) Irinotecan drug eluting beads for use in chemoembolization: in vitro and in vivo evaluation of drug release properties. *Eur J Pharm Sci* 30:7–14
- Varela M, Real MI, Burrell M et al (2007) Chemoembolization of hepatocellular carcinoma with drug eluting beads: efficacy and doxorubicin pharmacokinetics. *J Hepatol* 46:474–481
- Egorin MJ (1998) Overview of recent topics in clinical pharmacology of anticancer agents. *Cancer Chemother Pharmacol* 42(Suppl):S22–S30
- Emerich DF, Snodgrass P, Lafreniere D et al (2002) Sustained release chemotherapeutic microspheres provide superior efficacy over systemic therapy and local bolus infusions. *Pharm Res* 19:1052–1060
- Shapiro GI, Harper JW (1999) Anticancer drug targets: cell cycle and checkpoint control. *J Clin Invest* 104:1645–1653
- Khankan AA, Osuga K, Hori S et al (2004) Embolic effects of superabsorbent polymer microspheres in rabbit renal model: comparison with tris-acryl gelatin microspheres and polyvinyl alcohol. *Radiat Med* 22:384–390
- Bilbao JI, de Luis E, Garcia de Jalon JA et al (2008) Comparative study of four different spherical embolic particles in an animal model: a morphologic and histologic evaluation. *J Vasc Interv Radiol* 19:1625–1638
- de Luis E, Bilbao JI, de Ciercoles JA et al (2008) In vivo evaluation of a new embolic spherical particle (HepaSphere) in a kidney animal model. *Cardiovasc Intervent Radiol* 31:367–376
- Jiaqi Y, Hori S, Minamitani K et al (1996) A new embolic material: super absorbent polymer (SAP) microsphere and its embolic effects. *Nippon Igaku Hoshasen Gakkai Zasshi* 56:19–24
- Osuga K, Hori S, Hiraishi K et al (2008) Bland embolization of hepatocellular carcinoma using superabsorbent polymer microspheres. *Cardiovasc Intervent Radiol* 31:1108–1116
- Jordan O, Denys A, De Baere T et al (2010) Comparative study of chemoembolization loadable beads: in vitro drug release and physical properties of DC bead and hepasphere loaded with doxorubicin and irinotecan. *J Vasc Interv Radiol* 21(7):1084–1090
- Lee KH, Liapi EA, Cornell C et al (2010) Doxorubicin-loaded QuadraSphere microspheres: plasma pharmacokinetics and intratumoral drug concentration in an animal model of liver cancer. *Cardiovasc Intervent Radiol* 33(3):576–582
- Ko YH, Pedersen PL, Geschwind JF (2001) Glucose catabolism in the rabbit VX2 tumor model for liver cancer: characterization and targeting hexokinase. *Cancer Lett* 173:83–91
- Taylor S, Folkman J (1982) Protamine is an inhibitor of angiogenesis. *Nature* 297:307–312
- Geschwind JF, Ko YH, Torbenson MS et al (2002) Novel therapy for liver cancer: direct intraarterial injection of a potent inhibitor of ATP production. *Cancer Res* 62:3909–3913
- Furuta T, Kanematsu T, Kakizoe S et al (1983) Selective effect of doxorubicin suspended in lipiodol on VX2 carcinoma in rabbits. *J Surg Oncol* 39:229–234
- Iwai K, Maeda H, Konno T et al (1987) Tumor targeting by arterial administration of lipids: rabbit model with VX2 carcinoma in the liver. *Anticancer Res* 7:321–327
- Nagamitsu A, Konno T, Oda T et al (1993) Targeted cancer chemotherapy for VX2 tumour implanted in the colon with lipiodol as a carrier. *Eur J Cancer* 34:1764–1769
- Kan Z (1994) Iodized oil injected in the hepatic artery will enter the portal vein. *J Vasc Interv Radiol* 5:525–526
- Kan Z (1996) Dynamic study of iodized oil in the liver and blood supply to hepatic tumors. An experimental investigation in several animal species. *Acta Radiol Suppl* 408:1–25
- Kan Z, Sato M, Ivancev K et al (1993) Distribution and effect of iodized poppyseed oil in the liver after hepatic artery embolization: experimental study in several animal species. *Radiology* 186:861–866
- Kan Z, Wright K, Wallace S (1997) Ethiodized oil emulsions in hepatic microcirculation: in vivo microscopy in animal models. *Acad Radiol* 4(4):275–282
- Nakamura H, Hashimoto T, Oi H et al (1989) Transcatheter oily chemoembolization of hepatocellular carcinoma. *Radiology* 170:783–786

38. Olivi A, Brem H (1994) Interstitial chemotherapy with sustained-release polymer systems for the treatment of malignant gliomas. *Recent Results Cancer Res* 135:149–154
39. Osuga K, Hori S, Kitayoshi H et al (2002) Embolization of high flow arteriovenous malformations: experience with use of superabsorbent polymer microspheres. *J Vasc Interv Radiol* 13: 1125–1133
40. Osuga K, Khankan AA, Hori S et al (2002) Transarterial embolization for large hepatocellular carcinoma with use of superabsorbent polymer microspheres: initial experience. *J Vasc Interv Radiol* 13:929–934
41. Stampfl S, Stampfl U, Rehnitz C et al (2007) Experimental evaluation of early and long-term effects of microparticle embolization in two different mini-pig models. Part II: liver. *Cardiovasc Intervent Radiol* 30:462–468
42. Siskin GP, Dowling K, Virmani R et al (2003) Pathologic evaluation of a spherical polyvinyl alcohol embolic agent in a porcine renal model. *J Vasc Interv Radiol* 14:89–98
43. Derdeyn CP, Graves VB, Salamat MS et al (1997) Collagen-coated acrylic microspheres for embolotherapy: in vivo and in vitro characteristics. *AJNR Am J Neuroradiol* 18:647–653